



International Journal of Sciences: Basic and Applied Research (IJSBAR)

ISSN 2307-4531
(Print & Online)

<http://gssrr.org/index.php?journal=JournalOfBasicAndApplied>



Multidisciplinary Oral Management in Cancer Therapy Part III: Post Cancer Treatment

Manu Rathee^{a*}, Mohaneesh Bhorla^b, Madhuri Dua^c

^{a,b,c} Department of Prosthodontics, Post Graduate Institute of Dental sciences, Pt. B. D. Sharma University of Health Sciences, Rohtak, Haryana, India

^aEmail: ratheemanu@gmail.com

^bEmail: mohaneesh83@gmail.com

^cEmail: mdua104@gmail.com

Abstract

Post-therapy preventive and therapeutic strategies for dental management are essential. Usually most of the dental procedures that were postponed before and during oncologic therapy can be performed post therapy. This post-cancer therapy multidisciplinary oral management is directed at minimizing recurrence of disease, providing palliation, and improving the quality of life of patients. Hence, this paper provides a pathway of multidisciplinary oral management following cancer therapy.

Keywords: Continuous therapy; osteoradionecrosis; xerostomia.

1. Introduction

Patients with head and neck cancers often suffer from acute and late reactions to cancer therapy. Severity of oral complications may be based on the extent of tumor, as well as the type and extent of therapy. Some complications are transient, whereas others require a long term management as a result of permanent dysfunction. These patients are usually at high risk of recurrence or secondary malignancies, and therefore require close long term follow up.

* Corresponding author.

E-mail address: ratheemanu@gmail.com.

Hence under these case scenario pathway of management encompasses continuous therapy phase, with aim to ensure continuing oral care, monitor oral condition of children especially, during their period of growth and development, and reassessment therapy phase, with aim to review oral conditions and period of follow up which should be at least be equivalent to the period of assessment of cancer by the Oncology team. These monitoring should be focused on stabilization/elimination of etiological factors, diet analysis and counselling to control or reduce the effect of aetiological factors, prescription of neutral, sodium fluoride mouth rinses or gel for daily use, thorough oral prophylaxis, consultation with oncologic team for further referral, if required.

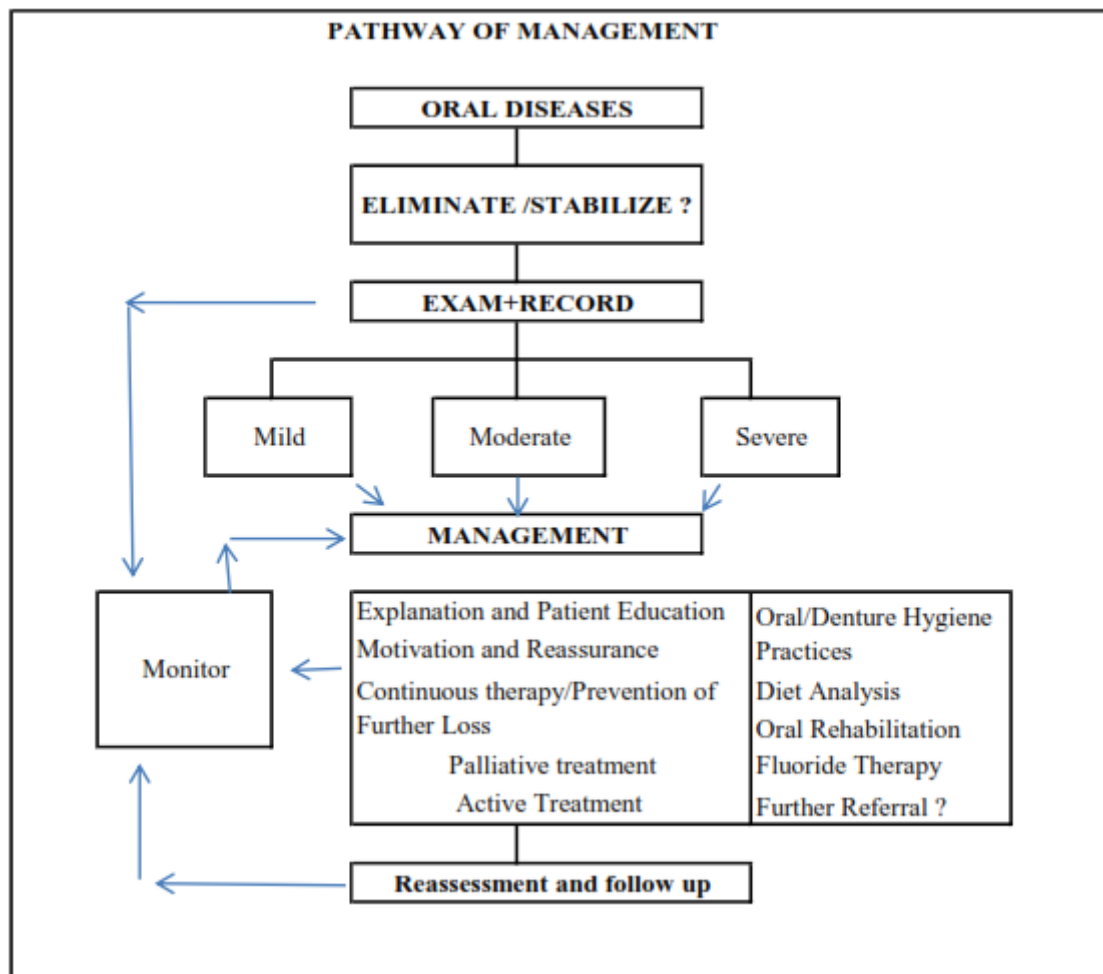


Figure1: Oral Management of Patient after Cancer Therapy.

2. Oral Management after cancer therapy

2.1. Prevention and Monitoring

- There should be at least every six months oral health review in general and a three month review is recommended for patients with xerostomia, trismus, severe mucositis.
- Regular and appropriate oral health care monitoring should include regular radiographs, oral health advice and preventive regime reinforcement.
- Strategies for handling xerostomia, fluoride supplements appropriate to age should continue. Chlorhexidine

gel can be applied with applicators every three months. In case of trismus, jaw exercises are implemented.

2.2. General Considerations

- Patients on maintenance chemotherapy should have a complete blood picture be performed within the 24-48 hour period prior to any proposed dental treatment that might result in bleeding/bacteraemia.
- Herpes labialis can be a major chronic problem. Topical acyclovir (5% cream applied five times daily for five to ten days, starting at first sign of attack) is effective [1].
- Following radiation therapy progressive jaw stiffness and limited mouth opening occurred. Various mouth exercises are advisable to minimize the problem. A wedge made by taping together tongue spatulas can be used as aid which can act both as a guide to improved opening and as a target at least 3-4 times daily. [2]. Trigger point injections, analgesics and muscle relaxants can also be used.

2.3. Orthodontic Considerations [3]

- Orthodontic treatment can start once the patient has been free of cancer for one year.
- Any developmental disturbances, extensive root damage/lack of root development that may have occurred due to their medical treatment must be assessed to decide on their suitability for orthodontics.

2.4. Periodontal Considerations

- Irradiated patients are at increased risk of progressive, uncontrolled periodontal disease and/or osteoradionecrosis [4,5].
- In the few instances of chemotherapy induced gingival hyperplasia, oral hygiene instructions, supra- and subgingival scaling, and gingival curettage should be carried out. This has been found to reduce the need for gingivectomy [6].

2.5. Restorative and Prosthetic Considerations

- Reconstructive prostheses should be simple in design, functional and provide acceptable aesthetics.
- It is recommended that the complete or partial denture should be avoided wherever possible in case patient demonstrated poor oral hygiene practice. When patient maintaining oral hygiene, dentures are essential to restore function and, by extrapolation, promote social adaptation and weight gain [7].
- Post radiation xerostomic patients showed cervical caries as a major problem. Conservative restorative management is recommended initially and if patient demonstrated good oral hygiene only then, full/partial coverage crowns should be considered. Fluoride releasing restorative materials such as conventional glass ionomer restorations has been found to perform more poorly than amalgam restorations resin modified glass ionomer and composite resin in patients who have been treated with radiotherapy. Edentulous patients, artificial saliva reservoir can be provided within the prosthesis; this may help to alleviate xerostomia temporarily [8].
- In the event of oral candida infection, antifungal therapy should be prescribed for at least two consecutive

weeks [9,10]. In case of denture wearing patient miconazole varnish or gel can be applied to fit denture surface. Nystatin powder- 500,000-1000000 units per application of Viscogel can be incorporated into a denture soft lining material. These modified relining materials require to be changed on a regular basis i.e. between seven and fourteen days [11-15]. Tea tree oil (*M. Alternifolia*) has an antifungal activity and can be mixed with the Coe Comfort tissue conditioner and could be used as an alternative therapy for denture stomatitis which is resistant to other therapies [16]. Microwave disinfection of maxillary complete dentures has also been found to be effective [17,18]. If these therapies appear ineffective, prosthesis wear should be discontinued. New dentures may be required to alleviate symptoms.

- Interim obturator should be reviewed regularly. They may require frequent adjustment. Definitive obturator should be considered only after four to six months when healing phase completed.
- Osseointegrated implants can be a useful adjunct to fixed or removable prosthesis with provision to improve prosthesis stability. Regarding zygomatic implants, there is limited high quality evidence available at present [18,19]. There is limited evidence available regarding the use of HBOT prior to implant placement in irradiated patients. Hyperbaric oxygen therapy may not offer any appreciable clinical benefits with respect to implant success. The placement of implants in patients who are being treated with bisphosphonates is not recommended with implant placement increasing the damage to the bony structures and increasing the risk of osteonecrosis.

2.6. Consideration for Osteoradionecrosis

- A recent systematic review has estimated 7 % of total incidence of osteoradionecrosis after tooth extraction in irradiated patients. However, only 4% of total incidence of osteoradionecrosis in conjunction with prophylactic hyperbaric oxygen therapy (HBOT) and 6% of total incidence in conjunction with antibiotics were noticed [19]. Patients who have received bisphosphonate therapy are also at increased risk of osteonecrosis.
- Before proceeding for any dental treatment establish the diagnosis of osteoradionecrosis and staging is must, ensuring that the bony changes are not due to malignancy. Following diagnosis of osteoradionecrosis it is recommended that oral trauma should be minimized by instigating soft diet plan, adjusting of denture contributing to trauma. Extractions are to be avoided where possible, particularly in the mandible. Local measures should be employed to relieve symptoms including topical/systemic analgesia. In most chronic cases the presence of Actinomycoses must be considered. The antibiotic of choice should be broad spectrum, sequestrectomy should be given and continued until mucosal integrity has occurred [18,19]. Localised surgical excision of exposed necrosed bone with primary mucosal closure may become necessary. At high risk of osteoradionecrosis, consideration to root canal therapy and restoration/crown amputation is must [21]. It is recommended that antibiotic treatment is initiated prior to Hyperbaric Oxygen Therapy and continued through the surgical phase and post-surgery [22-24]. However, there is an increased risk of tumour recurrence in patients who receive hyperbaric oxygen therapy [25-27]. There have been promising results with ultrasound at frequencies of 3mHz pulsed one in four at an intensity of 1W/cm² applied to the mandible for ten minutes daily for fifty days [28,29]. Hence, osteoradionecrosis can be avoided by careful oral health monitoring and ensuring prevention compliance, timely dental treatment and dealing promptly with oral trauma.

3. Conclusion

The outlook, before, during and after treatment, for malignant disease, has significantly improved in the last few decades. Appropriate preventive regimens and timely oral care can minimize complications and improve quality of life. The patient's oral care and function is an important contributor to post-treatment social adaptation and life quality.

References

- [1] Arduino PG, Porter SR. Oral and perioral herpes simplex virus type 1 (HSV-1) infection: review of its management. *Oral Dis.* Vol.12(3), pp 254-70, 2006.
- [2] Brunello, D.L., Mandikos, M.N. The use of a dynamic opening device in the treatment of radiation induced trismus. *Aust Prosthodont J.* Vol. 9, pp 45-48, 1995.
- [3] Sheller, B, Williams, B, Orthodontic management of patients with haematological malignancies. *Am.J.Orthod.Dentofac.Orthop.* Vol. 109, pp 575-80, 1996.
- [4] Galler, C, Epstein, J.B, et al. The Development of Osteoradionecrosis from sites of periodontal disease activity: Report of three cases. *J. Periodontol.* Vol. 63, pp 310-316, 1992.
- [5] Yusof, Z.W., Bakri, M.M. Severe progressive periodontal destruction due to radiation tissue injury. *J.Periodontol*, Vol. 64, pp 1253-1258, 1993.
- [6] Kantarci A, Cebeci I, Tuncer O, Carin M, Firatli E. Clinical effects of periodontal therapy on the severity of cyclosporin A induced gingival hyperplasia. *J Periodontol.* Vol.70(6), pp 587-93, 1999.
- [7] Finlay, P.M., Dawson, F. Robertson, A.G., Soutar, D.S. An evaluation of functional outcome after surgery and radiotherapy for intra-oral cancer. *British Journal of Oral & Maxillofacial Surgery*, Vol. 30, pp 14-17, 1992.
- [8] Turner M, Jahangiri L, Ship JA. Hyposalivation, xerostomia and the complete denture: a systematic review. *J Am Dent Assoc.*, Vol. 139(2), pp 146-50, 2008.
- [9] Sinclair, G.F., Frost, P.M., Walter, J.D. New design for an artificial saliva reservoir for the mandibular complete denture. *J Prosthet Dent*, Vol. 75, pp 276-80, 1996.
- [10] Mendoza AR, Tomlinson MJ. The split denture: a new technique for artificial saliva reservoirs in mandibular dentures. *Aust Dent J.* Vol. 48(3) pp190-4, 2003.
- [11] Thomas CJ, Nutt GM. The in vitro fungicidal properties of Viscogel alone and combined with Nystatin and Amphotericin B. *J. Oral Rehab.* Vol.5, pp 167-172, 1978.
- [12] Quinn DM. The effectiveness, in vitro, of miconazole and ketoconazole combined with tissue conditioners in inhibiting the growth of *Candida albicans*. *J Oral Rehabil.*, Vol.12(2), pp 177-82, 1985.
- [13] Truhlar MR, Shay K, Sohnle P. Use of a new assay technique for quantification of antifungal activity of nystatin incorporated in denture liners. *J Prosthet Dent.*, Vol.71(5), pp 517-24, 1994.
- [14] Geerts GA, Stuhlinger ME, Basson NJ. Effect of an antifungal denture liner on the saliva yeast count in patients with denture stomatitis: a pilot study. *J Oral Rehabil.*, Vol. 35(9), pp. 664-9, 2008.
- [15] Falah-Tafti A, Jafari AA, Lotfi-Kamran MH, Fallahzadeh H, Hayan RS. A Comparison of the efficacy of Nystatin and Fluconazole Incorporated into Tissue Conditioner on the In Vitro Attachment and Colonization of *Candida Albicans*. *Dent Res J (Isfahan)*. Vol. 7(1), pp 18-22, 2010.

- [16] Catalan A, Pacheco JG, Martínez A, Mondaca MA. In vitro and in vivo activity of *Melaleuca alternifolia* mixed with tissue conditioner on *Candida albicans*. *Oral Surg Oral Med Oral Pathol Oral Radiol Endod.* Vol. 105(3), pp.327-32, 2008.
- [17] Neppelenbroek KH, Pavarina AC, Palomari Spolidorio DM, Sgavioli Massucato EM, Spolidorio LC, Vergani CE. Effectiveness of microwave disinfection of complete dentures on the treatment of *Candida*-related denture stomatitis. *J Oral Rehabil.* , Vol. 35(11), pp 836-46, 2008.
- [18] Ruggiero S, Gralow J, Marx RE, Hoff AO, Schubert MM, Huryn JM, Toth B, Damato K, Valero V. Practical guidelines for the prevention, diagnosis, and treatment of osteonecrosis of the jaw in patients with cancer. *J Oncol Pract.*, Vol. 2(1), pp 7-14, 2008.
- [19] Nabil S, Samman N. Incidence and prevention of osteoradionecrosis after dental extraction in irradiated patients: a systematic review. *Int J Oral Maxillofac Surg.* Vol. 40(3), pp 229-43, 2011.
- [20] Koga DH, Salvajoli JV, Alves FA. Dental extractions and radiotherapy in head and neck oncology: review of the literature. *Oral Dis.*, Vol. 14(1), pp.40-4, 2008.
- [21] Chung EM, Sung EC. Dental management of chemoradiation patients. *J Calif Dent Assoc.*, Vol. 34(9), pp. 735-42, 2006.
- [22] Kanatas A.N., Rogers S.N., Martin M.V. A practical guide for patients undergoing exodontia following radiotherapy to the oral cavity. *Dent Update.*, Vol. 29(10), pp.498-503, 2002.
- [23] Kanatas A.N, Rogers S.N., Martin M.V. A survey of antibiotic prescribing by maxillofacial consultants for dental extractions following radiotherapy to the oral cavity. *Br Dent J.*, Vol. 192(3), pp157-60, 2002.
- [24] Stare G, Eribe ER, Olsen I DNA-DNA hybridization demonstrates multiple bacteria in osteoradionecrosis. *Int J Oral Maxillofac Surg.* Vol. 34(2), pp.193-6, 2005.
- [25] Richard J. Shaw, Jagtar Dhanda Hyperbaric oxygen in the management of late radiation injury to the head and neck. Part I: treatment. *British Journal of Oral and Maxillofacial Surgery* Vol.49, pp 2–8, 2011.
- [26] Richard J. Shaw, Christopher Butterworth Hyperbaric oxygen in the management of late radiation injury to the head and neck. Part II: prevention. *British Journal of Oral and Maxillofacial Surgery* Vol.49 pp 9–13, 2011.
- [27] Lambert, P.M., Intiere, N, Eichstaedt, R. Clinical controversies in oral and maxillofacial surgery: Part One. Management of dental extractions in irradiated jaws: a protocol with hyperbaric oxygen. *J Oral Maxillofac Surg* Vol. 55, pp 268-274, 1997.
- [28] Reher, P., Doan, N., Bradnock, B., Meghji, S., Harris, M. Therapeutic ultrasound for osteoradionecrosis: an in vitro comparison between 1 Mhz and 45kHz machines. *Eur J Cancer*, Vol.34, pp 1962-8, 1998.
- [29] Chrcanovic BR, Reher P, Sousa A, Harris M. Osteoradionecrosis of the jaws—a current overview—part 1: Physiopathology and risk and predisposing factors. *Oral Maxillofac Surg.* Vol.14(1), pp3-16, 2010.