



International Journal of Sciences:
Basic and Applied Research
(IJSBAR)

ISSN 2307-4531
(Print & Online)

<http://gssrr.org/index.php?journal=JournalOfBasicAndApplied>



The Therapeutic Potential of Human Umbilical Cord Blood Hematopoietic Stem Cells in Cyclophosphamide-Induced Ovarian Dysfunction in Rats

Mona A. Hussain^{a*}, Dalia Ibrahim^b, Noha Farag^b, Abeer Farouk^c

^aDepartment of Physiology, Faculty of Medicine, Port Said University, Egypt

^bDepartment of Physiology, Faculty of Medicine, Suez Canal University, Egypt

^cDepartment of Clinical Pathology, Faculty of Medicine, Ain Shams University, Egypt

^aEmail: mona2002dr@yahoo.com

^bEmail: daliaibrahiem@yahoo.com

Abstract

Millions of young women are rendered sterile by chemotherapy-associated oocyte loss. Recently some studies linked stem-cell transplantations to a spontaneous and unexplained return of ovarian function in some women rendered prematurely menopausal by high-dose chemotherapy or irradiation when they undergo bone marrow transplantation as part of their treatment protocol. This study was designed to investigate the therapeutic potential of human umbilical cord blood CD³⁴⁺ cells transplantation on cyclophosphamide-induced ovarian dysfunction in rats. In this paper; Twenty one Sprague-Dawley albino mature female rats were used in this study. Animals were randomly divided into three equal groups: group (1) was a normal control group, group (2) was the cyclophosphamide-treated group and group (3) was the stem cells transplanted group after cyclophosphamide administration. Measurement of serum FSH and estradiol levels and histopathological examination of ovaries were done. The Results shows that the Human umbilical cord blood CD³⁴⁺ cells transplantation significantly decreased the loss of ovarian follicles, restored the folliculogenesis and had no significant effect on serum FSH or estradiol levels. The current study suggests that transplantation of human umbilical cord blood hematopoietic CD³⁴⁺ cells into rats with cyclophosphamide-induced ovarian dysfunction improves ovarian folliculogenesis function with no significant effect on hormonal secretion function and further studies are required to clarify the role of stem cells transplantation as a cure for ovarian dysfunction.

* Corresponding author.

E-mail address: [E-mail address: mona2002dr@yahoo.com](mailto:mona2002dr@yahoo.com).

Keywords: ovarian follicles damage; chemotherapy; CD³⁴⁺ stem cells transplantation.

1. Introduction:

Each year millions of women undergo fertility treatments due to age-related loss of oocytes; these treatments offer only modest improvements in fertility. Furthermore, millions of young women are rendered sterile by chemotherapy-associated oocyte loss [1].

Gonadal failure as a result of germ cell depletion can occur at any age, and from the effects of chemical cytotoxicity, disease and infection as well as genetic predisposition [2]. There are two basic categories of gonadal failure: one in which there are few to no remaining follicles, and in the second, there are an abundant number of follicles. In the first situation, the causes include genetic disorders, chemotherapy, radiation to the pelvic region, surgery, however, in most cases, the cause is unknown. In the second case, a frequent cause is autoimmune ovarian disease, which damages maturing follicles but leaves the primordial follicles intact. Currently, there are no proven treatments that restore normal functionality to a woman's ovaries [1].

One of the most devastating adverse effects of cancer treatments is damage to the reproductive system, which in young girls and women less than 40 years old is frequently associated with premature menopause and infertility [3]. With recent advances in cancer care, more and more young women can survive but suffer from infertility as a result of cancer treatment that had to be submitted [4]. Early loss of ovarian function has significant psychosocial sequelae and major health implications; nearly 2-fold age-specific increase in mortality rate has been reported [5]. A chemical exposure that is of direct human concern is cyclophosphamide, due to its wide use in chemotherapeutic regimens against cancer and autoimmune disorders [6]. The reproductive outcomes of chemotherapy in women seem to be, in large part, a result of cytotoxic effects on oocytes housed within the ovaries and with near-universally accepted dogma that oocytes are endowed as a fixed and nonrenewing stockpile at birth, pathologic destruction of oocytes has been viewed as irreversible. Thus, experimental approaches aimed at sustaining fertility in female cancer survivors have been directed solely at preservation of existing oocytes [3].

There are a variety of methods to preserve fertility, as chemoprotection, ovariopexy, and some assisted reproductive technologies, although some of these are promising but still highly experimental techniques [4].

Recently some studies linked stem-cell transplantations to a spontaneous and unexplained return of ovarian function in some women rendered prematurely menopausal by high-dose chemotherapy or irradiation when they undergo bone marrow transplantation as part of their treatment protocol [7,8,9]. These studies raise the possibility that, stem-cell transplantation could be considered as a viable therapeutic option to revive ovarian function and restore fertility in women after chemotherapy [3].

In recent years, human umbilical cord blood (HUCB) has emerged as an attractive tool for cell-based therapy. Although at present the clinical application of HUCB is limited to the fields of hematology and oncology, a rising number of studies show potential for further application in the treatment of non-hematopoietic diseases. HUCB, with its real abundance, simple collection procedure and no serious ethical dilemmas, represents a valuable alternative to the use of other stem cell sources [10].

In our previous studies we found improvement after HUCB CD³⁴⁺ cells transplantation in carbon tetrachloride-induced liver fibrosis in mice [11], streptozotocin-induced diabetes in mice [12] and diabetic nephropathy in rats [13]. So this study was designed to investigate the therapeutic potential of HUCB CD³⁴⁺ cells transplantation on cyclophosphamide-induced ovarian dysfunction in rats.

2. Materials & Methods

2.1. Animals: Twenty one Sprague-Dawley albino mature female rats 3 months old and their weight range was 180 – 200 g were used in this study. Animals were brought from the Ophthalmic Research Institute Center for experimental animals in Giza, were acclimatized for one week and kept with free access to standard pellet animal diet and tap water under controlled conditions of room temperature.

Animals were randomly divided into three equal groups:

Group (1): this group was a normal control group.

Group (2): this group was the cyclophosphamide-treated group and it was subjected to Induction of ovarian dysfunction with cyclophosphamide without any intervention.

Group (3): this group was the stem cells transplanted group and it was subjected to:

- Induction of ovarian dysfunction with cyclophosphamide.
- Transplantation of 1×10^6 HUCB CD³⁴⁺ cells after the last injection of cyclophosphamide.

2.2. Methods

2.2.1. Type of the study: An experimental case-control study.

2.2.2. Study site: This study was carried out in Suez Canal University, Faculty of Medicine, Physiology department, Stem Cell Unit.

2.2.3. Induction of ovarian dysfunction: The rats in group 2 and 3 were injected (IP) with 50 mg/kg of cyclophosphamide, as a loading dose followed by daily IP injection of 8 mg/kg cyclophosphamide for 14 consecutive days [14]. Two rats were sacrificed at the end of this protocol for histopathological examination to confirm ovarian dysfunction but ovarian dysfunction was not confirmed in them so the daily injections of cyclophosphamide were extended for two weeks then two rats were sacrificed, and ovarian dysfunction was confirmed by histopathological examination.

2.2.4. Collection and isolation of HUCB CD34+ cells: Sterile collection tubes (50 ml), containing 5 ml citrate phosphate dextrose adenine-1 (CPDA-1) anticoagulant, were used for collection of the HUCB. Mononuclear cells were isolated by Ficoll-Hypaque density gradient centrifugation (Sigma Chemical Co., Egypt). Separation of CD34 positive progenitor cells was carried out with immunomagnetic separation technique by Dynal CD34⁺ progenitor cell selection system [12].

2.2.5. Transplantation of HUCB CD34+ cells: 0.2 ml of phosphate buffer saline solution was added to the CD³⁴⁺ cell pellet for injection in the rat tail vein in a dose of 1×10^6 cells/ rat in group (3) after the last cyclophosphamide injection. 0.2 ml of phosphate buffer saline were injected in the rat tail vein in groups (1) and (2) [12].

Eight weeks after Transplantation of HUCB CD³⁴⁺ cells, all rats were anesthetized and blood collection from retro-orbital venous plexus was done for serum follicle-stimulating hormone (FSH) and estradiol

assays then both ovaries were removed for histopathology.

2.2.6. Histopathology of the ovaries:The ovaries were collected. The rat ovaries were fixed in 4% formaldehyde, and paraffin-embedded sections were produced. The 4 μ m paraffin-embedded sections were rehydrated using xylene and a graded alcohol series and stained with hematoxylin and eosin (H&E). Histopathological examination was done by two professional pathologists.

2.2.7. Serum FSH and Estradiol assay:The serum was obtained by centrifugation (2400 rpm, for 20 minutes at 4°C) and the concentrations of estradiol(E2), and FSH were determined by (Vidas, Biomerieux). All samples were performed within the same assay to reduce interassay Variation. The respective intra-assay and interassay coefficients of variation (CVs) were as follows: E2 (4.2% and 5.1%) and FSH (4.9% and 3.5%).

2.2.8. Statistical analysis:Data are shown as means \pm SEM. The comparison of mean difference in the number of ovarian follicles, corpora lutea and degenerative cysts, levels of serum FSH and estradiol in the study groups was evaluated by using the ONE-WAY ANOVA test of variance, followed by Bonferroni post hoc test. The difference was regarded as statistically significant if the P value was < 0.05 . Statistical analysis was done with statistical package of social science (SPSS) computer software version 20 and data were presented in the form of tables and figures.

3. Results

3.1. Human umbilical cord blood hematopoietic stem cells transplantation decreased the loss of ovarian follicles, significantly restored the folliculogenesis and decreased cyst formation, edema and hemorrhage in cyclophosphamide-induced ovarian dysfunction:The number of ovarian follicles was significantly decreased in group (2) vs. group 1. HUCBCD³⁴⁺ cells transplantation in group (3) decreased this loss in ovarian follicles and there was no significant difference between group (3) and group (1) in the number of ovarian follicles (Figure1). The number of corpora lutea was significantly higher in group (3) vs. group (2) and it was not significantly different vs. group (1) (table 1) so HUCBCD³⁴⁺ cells transplantation restored folliculogenesis in cyclophosphamide-induced ovarian dysfunction. The number of degenerative cysts was significantly increased in group (2) vs. group (1) and HUCBCD³⁴⁺ cells transplantation decreased the number of degenerative cysts to reach a statistically non-significant difference vs. group (1) (table 1).Histopathological examination of ovarian sections from group (1) showed normal ovarian tissue with normal follicles at different stages of maturation (figure 2). In group (2)histopathological examination showed decreased number of follicles and corpora lutea, increased the number of degenerative cysts, edematous tissues and hemorrhage (figure 3). These previous changes were significantly ameliorated after HUCBCD³⁴⁺ cells transplantation in group (3) (figure 4).

3.2. HUCB CD³⁴⁺ cells transplantation had no significant effect on serum hormonal changes caused by cyclophosphamide-induced ovarian dysfunction:The serum level of FSH was significantly increased in groups (2) and (3) vs. group (1) (10.13 ± 0.3 and 10.037 ± 0.2 vs. 5.3 ± 0.5 , $P < 0.05$) (table 2).Cyclophosphamide injectionssignificantly increased serum estradiol level in group (2) vs. group (1). HUCB CD³⁴⁺ cells transplantation didn't change this finding and serum estradiol level was significantly higher in group (3) vs. group (1). There was no significant difference in serum FSH level or serum estradiol level in group (2) vs. group (3) (table 2).

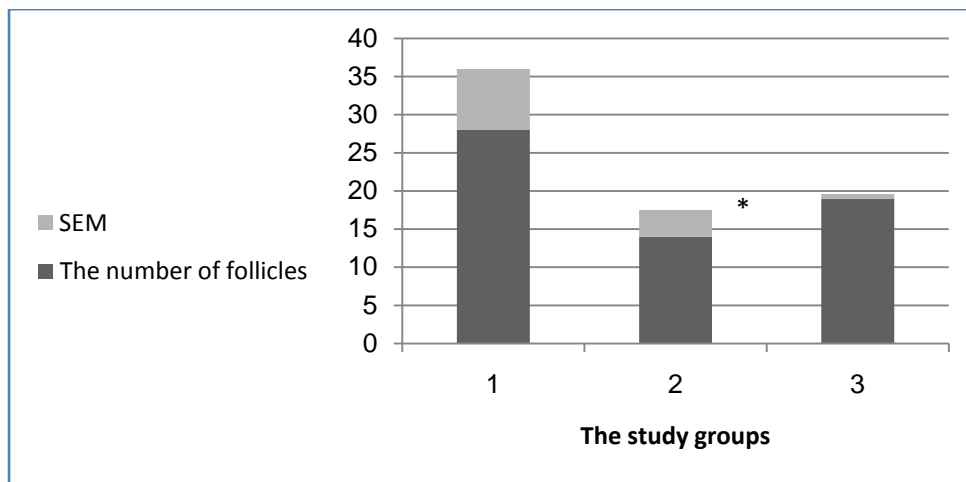


Figure 1: Comparison of ovarian follicles mean number in the study groups.

*significant difference in the mean number of the ovarian follicles between group (1) vs. group (2) (P = 0.047).

Table 1: Comparison in the number of corpora lutea and ovarian cysts among the studied groups at the end of the study

	Group (1)	Group (2)	Group (3)
Corpora lutea (Mean ± SEM)	7.7 ± 0.9	*a 2.7 ± 0.3	6.6 ± 0.4
Ovarian cysts (Mean ± SEM)	0.5 ± 0.5	*b 5.3 ± 2.2	1.1 ± 0.5

*a significant difference in the mean number of the corpora lutea between group (2) vs. groups (1) and (3) (P < 0.05).

*b significant difference in the mean number of the ovarian cysts between group (2) vs. group (1) (P < 0.05).

Table 2: Comparison in serum FSH mean levels and serum estradiol mean levels among the studied groups at the end of the study

	Group (1)	Group (2)	Group (3)
Serum FSH (mIU /ml) Mean ± SEM	* 5.3 ± 0.5	10.13 ± 0.3	10.037 ± 0.2
Serum estradiol (Pg/ml) Mean ± SEM	* 48.4 ± 10	145 ± 13	120.5 ± 12

* significant difference in the mean levels of serum FSH and serum estradiol levels in group (1) vs. groups (2) and (3).

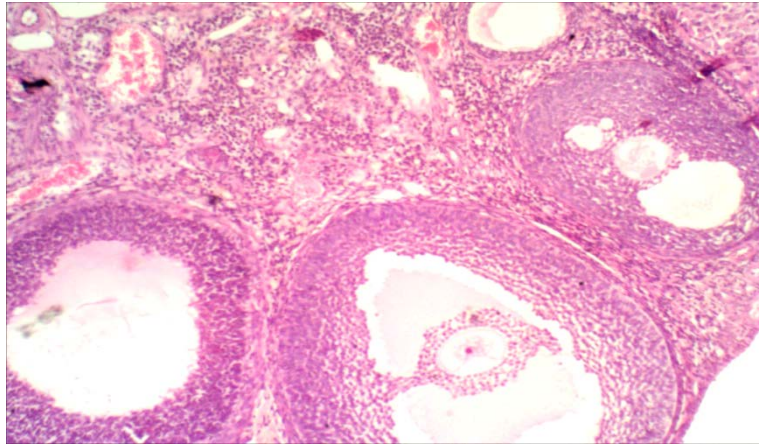


Figure 2: A Photomicrograph of a section in the ovary of group (1) showing normal ovarian follicles at different stages of maturation. H&E x10.

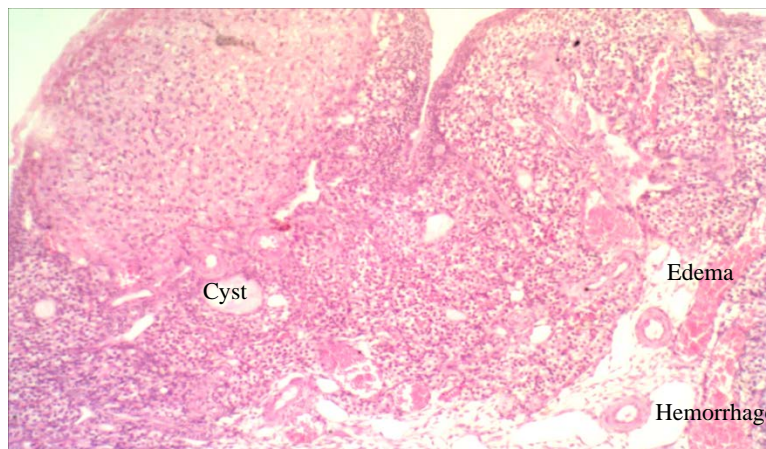


Figure 3: A Photomicrograph of a section in the ovary of group (2) showed decreased number of follicles, decreased number of corpora lutea, increased number of degenerative cysts, edema and hemorrhage. H&E X10.

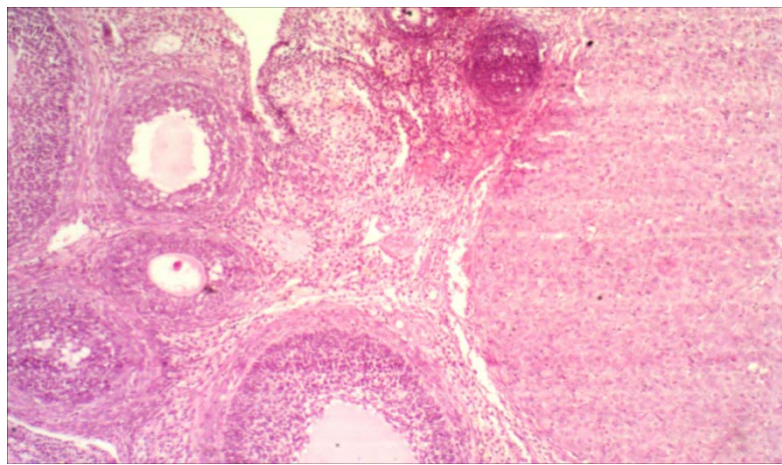


Figure 4: A Photomicrograph of a section in the ovary of group (3) showed increased number of follicles, corpora lutea and absence of degenerative cysts, edema and hemorrhage. H&E x10.

3. Discussion

In the current study the repeated administration of cyclophosphamide resulted in a significant decrease in the number of ovarian follicles and corpora lutea, a significant increase in the degenerative cyst formation and caused edema and hemorrhage. These findings were ameliorated after HUCB hematopoietic CD³⁴⁺ cells transplantation. HUCB hematopoietic CD³⁴⁺ cells decrease the loss of ovarian follicles induced by cyclophosphamide and improved folliculogenesis. These findings are in agreement with other investigators who proved that intravenously injected bone marrow stem cells restored follicular maturation in mice having a mutation in FSH receptor gene leading to elevated FSH, decreased estrogen levels, and sterility because of the absence of folliculogenesis [15]. Another study reported that ovarian activity, both hormonally and folliculogenesis, were restored after incorporation of mesenchymal stem cells derived from rats bone marrow into the ovarian stroma following cyclophosphamide-induced ovarian failure in rats [14]. Takehara et al. evaluated the effects on ovarian function after the transplantation of rat adipose tissue-mesenchymal stem cells into ovaries in rats with ovarian failure induced by cyclophosphamide. They reported that the transplantation of adipose tissue-mesenchymal stem cells resulted in an increased counts of corpora lutea and ovarian follicles [16].

The mechanism of this improvement after stem cells transplantation is controversial. In their study of the therapeutic potential of umbilical cord mesenchymal stem cells (UCMSCs) in mice premature ovarian failure induced by cyclophosphamide, authors reported that the UCMSCs didn't differentiate into follicles and they attributed the improvement in ovarian function to the ability of UCMSCs to reduce apoptosis of the granulosa cells and that UCMSCs function primarily by reactivating host oogenesis [1]. On the other hand another study reported that the return of ovarian activity after cyclophosphamide administration was the result of incorporation of the stem cells within the ovarian tissue with transformation into the proposed cells and authors supported this suggestion by finding (Sry) gene (derived from male rats stem cells) within the ovarian tissue in female rats included in their study [14]. Another mechanism may be involved is that stem cells secrete high levels of vascular endothelial cell growth factor, insulin-like growth factor-1 and hepatocyte growth factor which are known to affect follicular growth in ovaries [16]. Abd-Allah and her colleagues concluded that mesenchymal stem cells improved ovarian function by direct differentiation into specific cellular phenotypes and by secretion of vascular endothelial cell growth factor, which influence the regeneration of the ovary [17].

Another finding in this study was that HUCB hematopoietic CD³⁴⁺ cells transplantation causes no significant difference in serum FSH level or serum estradiol level when compared with cyclophosphamide -treated group. This finding was in contrast to other studies which concluded that stem cells transplantation improves folliculogenesis, decreases serum FSH level and increases serum estradiol level [14,15]. The absence of this effect in the current study may be explained by using different type and source of the stem cells. In the current study, hematopoietic CD³⁴⁺ stem cells from human umbilical cord blood were used while other studies used mesenchymal stem cells from the rat bone marrow.

It was interesting that doses of cyclophosphamide which resulted in a significant decrease in the number of ovarian follicles and corpora lutea, a significant increase in cyst formation, marked pathological changes with edema and hemorrhage and significant elevation in serum FSH level did not produce a reduction in the serum estradiol level but that doses of cyclophosphamide caused a significant elevation in serum estradiol. This paradox raises two questions; the first question is how does the level of serum estradiol increase within these experimental conditions? And the second question

is why does not the increased level of serum estradiol inhibit FSH secretion within these experimental conditions? It appeared that the increased serum level of estradiol may be caused by a decrease in its excretion by the liver and the kidneys which could be affected by cyclophosphamide toxicity [18,19,20]. "As a hormone's concentration in the plasma depends upon (1) its rate of secretion by the endocrine gland, and (2) its rate of removal from the blood. Removal of the hormone occurs either by excretion or by metabolic transformation. The liver and the kidneys are the major organs that excrete or metabolize hormones"[21]. Another explanation may be involved here is peripheral conversion of excess androgens secreted by the residual ovarian interstitial and stromal tissue to estradiol by adipose tissue [22] or both defective excretion and increased production from peripheral conversion in adipose tissues were responsible for the rise of serum estradiol.

The elevated level of serum FSH within these experimental conditions could be explained by positive feed-back effect of dramatically increased serum estradiol level or by loss of inhibin hormone secretion from cyclophosphamide-damaged ovarian follicles and consequently loss of negative feed-back inhibition effect of inhibin on FSH secretion[23] or endocrine dysfunction in hypothalamus-pituitary-ovarian Axis due to cyclophosphamide toxicity [24]. Another possibility is that all these factors may contribute to elevate serum FSH level.

4. Conclusion

The current study suggests that transplantation of HUCB hematopoietic CD³⁴⁺ cells into rats with cyclophosphamide-induced ovarian dysfunction improved ovarian folliculogenesis function with no significant effect on hormonal secretion function and further studies are required to clarify the role of stem cells transplantation as a cure for ovarian dysfunction.

References

- [1].S.Wang,L.Yu,M.Sun,S. Mu,C.Wang,D.Wanget al. "The Therapeutic Potential of Umbilical Cord Mesenchymal Stem Cells in Mice Premature Ovarian Failure".*Biomed Res Int.*[On-line]2013: 690491, 12 pages, 2013. Available:<http://dx.doi.org/10.1155/2013/690491>,[Nov.9, 2013].
- [2]. R.GosdenandM Nagano. "Preservation of fertility in nature and ART".*Reproduction*, 123, 3–11, 2002.
- [3].H. Lee, K.Selesniemi, Y.Niikura, T.Niikura, R.Klein, D.M.Dombkowski,et al. "Bone Marrow Transplantation Generates Immature Oocytes and Rescues Long-Term Fertility in a Preclinical Mouse Model of Chemotherapy-Induced Premature Ovarian Failure".*JCO*,25 (22), 3198-3204, 2007.
- [4].M.Lappi and A.Borini. "Fertility preservation in women after the cancer".*Curr Pharm Des.*18(3), 293-302, 2012.
- [5].D.Goswamiand G.S. Conway. "Premature ovarian failure".*Hum. Reprod. Update*, 11 (4),391-410, 2005.
- [6].P.Desmeules and P.J. Devine. "Characterizing the Ovotoxicity of Cyclophosphamide Metabolites on Cultured Mouse Ovaries".*Toxicol. Sci.*90 (2),500-509, 2006.
- [7].J.E.Sanders, J.Hawley, W. Levy, T.Gooley, C.D.Buckner, H.J.Deeg, et al.,: "Pregnancies following high-dose cyclophosphamide with or without high- dose busulfan or total-body irradiation and bone marrow transplantation".*Blood*, 87, 3045-3052, 1996.

- [8].L.Tauchmanová, C.Selleri, G. De-Rosa, M. Esposito, L.P.F.Orio, S.Palomba, Et al.“Gonadal status in reproductive age women after haematopoietic stem cell transplantation for haematological malignancies”. *Human Reproduction*, 18(7), 1410-1416, 2003.
- [9].J.Liu, R.Malhotra, J.Voltarelli,A.B.Stracieri, L. Oliveira, B.P.Simoes, et al.“Post-transplant events, ovarian recovery after stem cell transplantation”. *Bone Marrow Transplantation*, 41, 275–278, 2008.
- [10].T.Koblas, S.M. Harman and F.Saudek. “The application of umbilical cord blood cells in the treatment of diabetes mellitus”.*Rev Diabetic Stud.* 2, 228-234, 2005.
- [11].M.El Barbary, M.M.Awad, A.A.Kamel,A.Yousef, D.Ibrahim.“The Effect of Human Umbilical Cord Blood Stem Cells on Liver Regenerative Activity in Mice”, *Afro-Arab Liver Journal*, 6 (1-2), 5-10, 2007.
- [12]. M.A.Hasein, F.M.Attia, M.M.Awad, H.A.Abdelaal and M.Elbarabary. “Effect of human umbilical cord blood CD34⁺ progenitor cells transplantation in diabetic mice”. *Int J Diabetes DevCtries.* 31(2), 113–117, 2011.
- [13].K.D.Dissassa, M.H.M.Ali, M.A.Hussain, A.E.S.Abd Al-Hamid.“Effect of Stem Cells Injection in Adult Male Albino Rats with Streptozotocin-Induced Diabetic Nephropathy”.*Suez Canal UniversityMedical Journal*, 16 (1), 45-54, 2013.
- [14].A.Abbasy, O.Azmy, H. Atta, A. Ali, L.Rashed, Z. El-Khaiat, et al.“Stem cells restored ovarian function and folliculogenesis following cyclophosphamide-induced ovarian failure in rats”.*International Journal of Health Science*,[On-line],Jan2010. Available:<http://thefreelibrary.com>, [Oct. 9, 2013].
- [15].M.Ghadami, E.El-Demerdash, D. Zhang,S.A.Salama,A.A.Binhazim, A.E.Archibong,et al.“Bone Marrow Transplantation Restores Follicular Maturation and Steroid Hormones Production in a Mouse Model for Primary Ovarian Failure”. *PLoS One*, 7(3), e32462, 2012.
- [16].Y.Takehara, A.Yabuuchi,K.Ezoe, T. Kuroda,R.Yamadera, C.Sano, et al.“The restorative effects of adipose-derived mesenchymal stem cells on damaged ovarian function”. *Lab Invest.*93(2), 181–193, 2013.
- [17].S.H.Abd-Allah, S.M.Shalaby, H.F.Pasha, A.S.El-Shal, N.Raafat, S.M.Shabrawy, et al.“Mechanistic action of mesenchymalstem cell injection in the treatment of chemically inducedovarian failure in rabbits”. *Cytotherapy*,15 (1), 64-75, 2013.
- [18].P.D.King and M.C. Perry.“Hepatotoxicity of Chemotherapy”.*The Oncologist*,6 (2),162-176, 2001.
- [19].M.M.Gabarrón, R.Enríquez, A.E.Sirvent, M.G.Sepulcre, I.Millán and F. Amorós.“Hepatotoxicity following cyclophosphamide treatment in a patient with MPO-ANCA vasculitis”. *Nefrologia*, 31(4), 496-498, 2011.
- [20].M.U.Rehman, M.Tahir, F.Ali, W.Qamar, Abdul Lateef, R.Khan,et al.“Cyclophosphamide-induced nephrotoxicity, genotoxicity, and damage in kidney genomic DNA of Swiss albino mice: the protective effect of Ellagic acid”. *Molecular and Cellular Biochemistry An International Journal for Chemical Biology in Health and Disease*, [on-line]Jan, 2012.Available: Springer. mht, [Jan. 26, 2014].

- [21]. E.P.Widmaier, H.Raff and K.T.Strang.Vander's human physiology, The mechanisms of body function.11th ed.McGraw-Hill Companies, 2008, 324.
- [22].L.P.Mayer, P.J.Devine, C.A.Dyerand P.B.Hoyer.“The Follicle-Deplete Mouse Ovary Produces Androgen”. *Biology of Reproduction*, 71 (1) 130-138, 2004.
- [23].E.P.Widmaier, H.Raff and K.T.Strang.Vander's human physiology, The mechanisms of body function.11th ed.McGraw-Hill Companies, 2008, 621.
- [24].L.Tauchmanovà, C.Selleri, G. De-Rosa, L.P.F.Orio, G. Lombardi, Rotoli B.et al.“High prevalence of endocrine dysfunction in long-term survivors after allogeneic bone marrow transplantation for hematologic diseases”.*Cancer*, 95(5): 1076–1084, 2002.