



The Uses of Bony Mini Plate Osteosynthesis with or without Intermaxillary Fixation in Mandibular Fractures. A Comparison Study and Literature Review

Suha mohammad sami^a, Header Dakhel AL- Muala^b, Akmam H. Al-Mahdi^c,
Abbas AY Taher^{d*}

^aMaxillo facial surgeon, Lecturer kufa college of dentistry

^b Oral and Maxillo-Facial Surgeon , kufa college of dentistry ,Al- sadder teaching hospital

^c Oral and Maxillo-Facial Surgeon , Head of Arab Scientific Council of Oral and Maxillofacial Surgery in Iraq

^d Dean of College of Dentistry; Kufa University.IRAQ

^aEmail: suha.alkishwan@uokufa.edu.iq

^bEmail: hayder.almualla@uokufa.edu.iq

^cEmail: akmam65@yahoo.com

^dEmail: kufa54@gmail.com

Abstract:

This is a comparison study between two types of treatment to the mandibular fracture one group were treated with traditional intermaxillary fixation and mini plate internal fixation , and the other group were treated with internal fixation (miniplate and screws) only .We have found that the cases were treated with combined treatment were more stable and more functional than those with internal fixation only .Thus the rigid internal fixation considered promoting factor for the healing process especially for those with the unfavorable fracture.

Key words: mandibular fractures; fixation, mini plate; osteosynthesis, result .

1. Introduction.

Miniplate osteosynthesis is an internal procedure for repairing fractures to the mandible, maxilla and zygoma by using titanium or stainless steel plates and screws to stabilize the bone fragments in proper alignment [1].There are many different plates used in Maxillofacial Surgery fracture treatment.

* Corresponding author.

E-mail address: kufa54@gmail.com.

Titanium bone plates are currently used extensively for fixation of facial fractures in form of compression plates, micro plates and miniplates [2].

In the maxillofacial trauma, the mandibular fractures are the most area and frequently treated, than any other fracture of the facial skeleton. The ideal treatment of mandibular fractures ideally include, reestablishing the correct occlusion, immediate uncompromised mandibular function. Unstable fixation methods often require intermaxillary fixation, which delays functional rehabilitation. Rigid internal fixation promotes primary bone healing without extended use of maxillomandibular fixation for immobilization. It is generally accepted that reduction and fixation of the fracture to align the fragments in contact promotes bone healing.

Moreover, a direct correlation between the fracture-gap width and the healing process is given in the literature; if the fracture-gap width is larger than 2 mm, then bone healing is delayed. Large fracture gaps cause a delay in fracture healing, as demonstrated in experimental and clinical investigations [3]. A good reduction of a fracture with small interfracture gaps is important for its revascularization and healing which can be achieved by rigid fixation [4].

Although the techniques of fracture management have changed, the goals have not changed significantly. Accurate reduction of the fractures, maintenance of pre-morbid occlusion, and early return to function are the keys to successful management of these fractures. The technique of fracture repair and hardware choice will depend on the fracture pattern, fracture severity, and patient factors, such as residual dentition, coexistent lacerations, and associated injuries [2]. mandibular fracture management involved open reduction and internal fixation using wire osteosynthesis, then titanium hardware including lag screws and plates [6,7]. Methods employed in rigid fixation include lag screw technique, compression plates, reconstruction plate, non compression bone plates and external pin fixation. Fractures that follow a fairly straight course from buccal to lingual cortices lend themselves easily to compression plate osteosynthesis, but sagittal or oblique fractures should not be subjected to axial compression [8]. Sagittal and oblique fractures may be more amenable to repair with lag-screw techniques. To achieve optimal compression without displacement, a lag screw hole is drilled. Compression is not used in cases of infection or comminution [9]. This study was aimed to compare uses of miniplate 2.0mm /screw system with and with out maxillary mandibular fixation for one week in mandibular fractures.

2. Patients and methods

Forty six patients with mandibular fractures were included in this study thirty one (67.4%) were male and fifteen patients (32.6%) were female from October 2008 up to July 2013, average age of patients was between 16-57years. The management started with immediate resuscitation following the principles of advanced trauma life support (ATLS). Plain anteroposterior (AP), lateral cephalometry radiograph, Orthopantomogram (OPG) and / or CT scan were obtained for all patients. An accurate assessment of the fractures was performed including the site and type of fracture, amount of displacement, amount of pain or discomfort, paraesthesia in the distribution of inferior alveolar nerve, marginal mandibular nerve paresis, status of dental occlusion, any associated temporomandibular joint (TMJ) dislocation, or any other functional deficits. All the selected patients were entailed about the surgical procedure. They were informed about the surgical procedure including prognosis, potential hazards and complications. They gave their approval to participate in a written informed consent. The study protocol was reviewed and approved by the central regional ethics committee.

Patients were divided into two groups. Group one were twenty one cases (45.7%) which were treated with mini plate 2.0mm/screw mono cortical type system and maxillomandibular fixation was removed post operatively. Group 11 were twenty five cases (54.3%) were treated with fixation by mini plate 2.0mm/screw system mono cortical type and maxillomandibular fixation was stayed for one week post operatively.

3. Surgical technique

Miniplates are placed according to Champy's principle [10]. Champy et al refined the work of Michel et al after carefully considering the biomechanics of mandible and have described the osteosynthesis line for placing the miniplates in the mandible. In the mandible, a line drawn at the base of the alveolar process corresponds to the line of tension and monocortical plates and screws can be fixed along this line [11]. The principle of osteosynthesis according to Champy is to reestablish the mechanical qualities of the mandible, hence he advised to use of two miniplates in anterior region, one at the inferior border and second 5 mm above the lower plate [12]. Operations were performed under general anesthesia forty two patients (91.3%) by nasotracheal intubation or local anesthesia four cases (8.7%). The surgeries were performed by the same surgeon with same operating team. Erich-type arch bars were first applied to the upper and lower dentition. Preoperatively or intraoperatively arch bar was placed for fixation of fragments with miniplates. The fracture was approached through a vestibular incision (intra oral approach) except in some inaccessible and sangles fractures where transbuccal trocar was used .The segments were reduced and fixed temporarily .Once the fracture has been reduced to the anatomic position, intraoperative maxillomandibular fixation was obtained . 2.0 mm titanium mini-plates /screw monocortical system adaptation and fixation, in symphesial, para symphesial , body and angular region , two mini plate were used ,one at inferior and one at superior border, in the body only one plate was used. Once the hardware has been placed, the occlusion was checked and attention was turned to closure. After copious irrigation, the intraoral incision was closed with care taken. A watertight closure of the mucosa suturing in layers was achieved Postoperatively, Postoperative IMF was used in group 11 patients only, and all patients received postoperative antibiotics and analgesics for 7 days and were instructed to maintain a soft diet. Oral hygiene maintenance using 0.2% chlorhexidine mouthwash was advised to all the patients. The patients were assessed clinically for wound breakdown, neurosensory deficit, mobility of fractured segments occlusion discrepancy, and malunion/ non-union. Postoperative radiographs were taken to assess the gap between fracture segments. Patients were followed for 6 months to insure accurate reduction and proper occlusion during the fracture healing.

4. Results.

Patients age range from 16–57 years and mean was 36.5 years ,most cases were from 20-29 years 17(37%) followed by 30-39 years 14 (30.4%).fracture site distribution consisted of 21 angle (33.96%) , 14 body (22.54%), 20 parasymphesis (32.25%) and 7 symphesis (11.25%), with total of 62 fracture site in the 46 cases selected. Table 1, 2, 3 shows the details.

Table (1) distribution age of patients.

No	Male	Female	Total
10-19 years	2	1	3 (6.5%)
20-29 years	13	4	17 (37%)
30-39 years	8	6	14 (30.4%)
40-49 years	5	3	8 (17.4%)
50-59 years	3	1	4 (8.7%)
Total	31	15	46 (100%)

Table (2) distribution site of fracture mandible.

Site of fracture	Male	Female	Total
Angle	13	8	21(33.96%)
Body	9	5	14(22.54%)
Parasymphesis	11	9	20(32.25%)
symphesis	5	2	7(11.25%)
Total	38	24	62(100%)

Table (3) distribution site of fracture mandible with type of treatment(group 1,2)

Site of fracture	Miniplate 2.0mm/screw system (Male)	Miniplate 2.0/screw system (Female)	Miniplate 2.0mm/screw system with IMF one week (Male)	Miniplate 2.0mm/screw system with IMF one week (Female)	Total
Angle	7	5	6	3	21
Body	5	2	4	3	14
Para symphesis	5	4	6	5	20
symphesis	1	0	4	2	7
Total	18	11	20	13	62

4. Postoperative complication.

The post operative complications for both group were neuro sensory deficit (two cases from group 1 and one case from group 2) , all three cases were recovered with six month post operatively. Four patients were developed infection and slight wound dehiscence ,one of them had exposure of the plate in the 2nd week post operation was treated by continuous irrigation with normal saline, mouthwash , antibiotic and keeping good oral hygiene .The exposed area was healed in twelve days .until complete wound healing was achieved in twelve days. All patients had post operative radiograph within two days of treatment to see the fracture alignment and screw position. Table 4, Fig. 1,2

Table (4) distribution type of treatment (group 1, 2) with postoperative complication.

Type of treatment	Infection	Occlusal discrepancies	Paresthesias	Wound dehiscence	Hardware failure	Non union	Total
mini plate 2.0mm/screw system	2	0	2	2	0	0	6
Mini plate 2.0mm/screw system mono cortical with IMF	2	0	1	2	0	0	5
Total	4	0	3	4	0	0	11

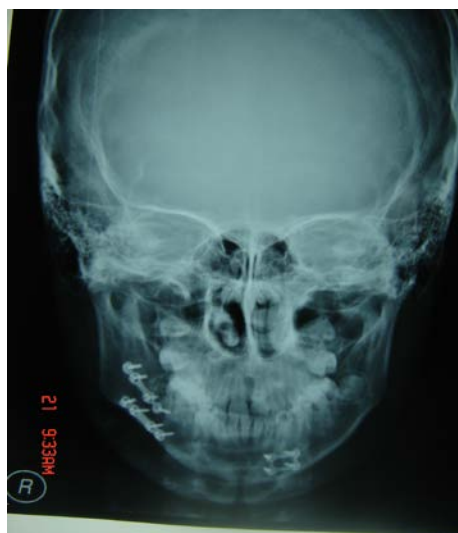

Fig. (1) PA.view ,bilateral fractures of mandible treated by mini plate 2.0mm/screw system ,group 1.

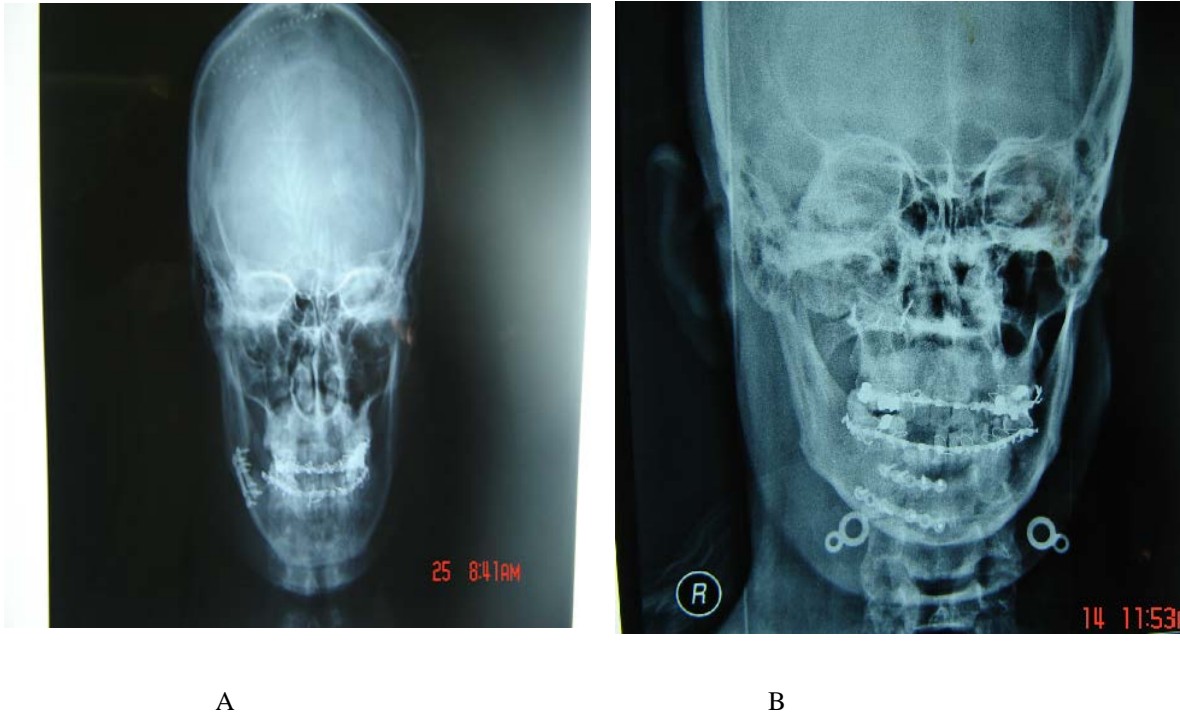


Fig. (2) PA.view, unilateral fractures of mandible treated by mini plate 2.0mm/screw system with IMF for one week A.. Angle B. Para symphysis fracture, group2.

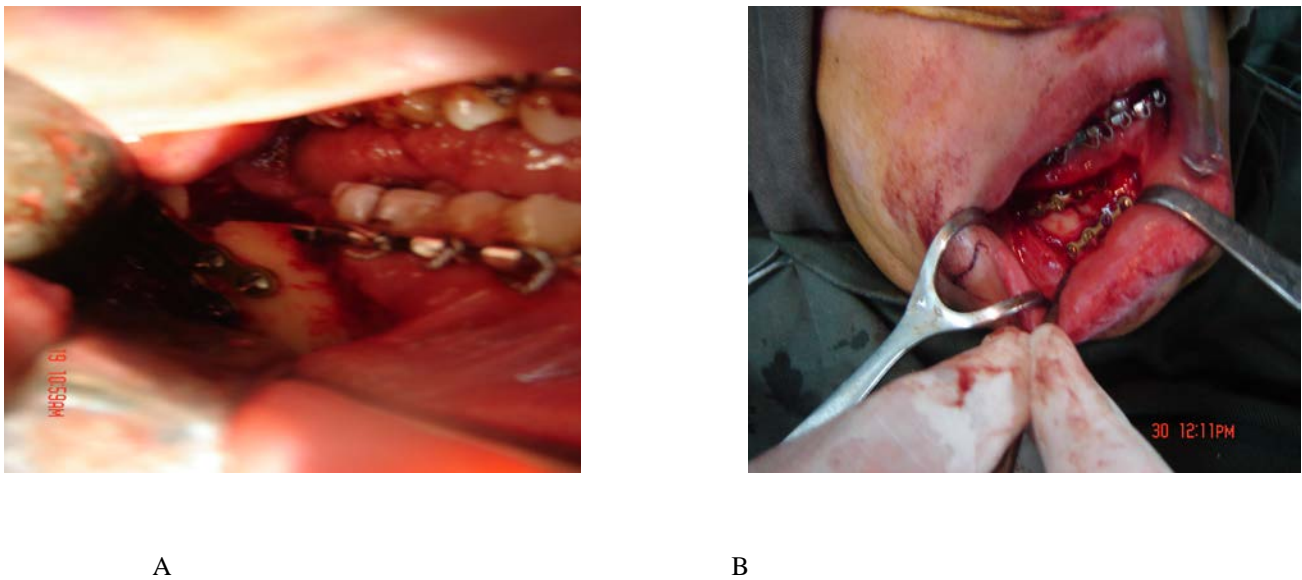


Fig. (2) Intra operative surgery, A. fracture angle of mandible treated by mini plate 2.0mm/screw system with IMF for one week, B. para symphysis fractures of mandible.

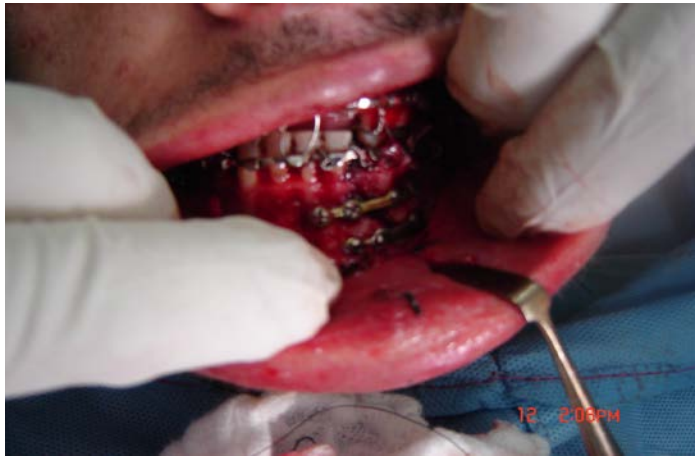

Fig. (3) Intra operative surgery, fracture symphysis of mandible treated by mini plate 2.0mm/screw system with IMF for one week,

5. Discussion

Mini plate 2.0mm / monocortical screw system.

For noncomminuted symphyseal and parasymphyseal mandible fractures, the application of 2 miniplates with monocortical screws offers good surgical outcomes in most patients with minimal complications. The advantages of using miniplates include easy plate adaptability, no need for MMF unless indicated, small screw diameter, and provision of adequate load-sharing rigid fixation for simple, noncomminuted symphyseal and parasymphyseal mandible fractures [13]. Plate osteosynthesis has become standard treatment for patients with fractures of the mandible by affording anatomic reduction, rigid fixation, and immediate function. Miniplate osteosynthesis offers several advantages over compression osteosynthesis. Intraoral plate placement eliminates facial scars and the potential for injury to the marginal mandibular branch of the facial nerve. Fixation devices have developed to achieve adequate strength, rigidity as well as biocompatibility with satisfactory bone healing at fracture site. Osteosynthesis by mini plates is a simple, logical and effective treatment compared to wire osteosynthesis as regard to stability of fracture fragments [14].

Several disadvantages persist including palpability, hardware loosening, temperature sensitivity, fretting corrosion, interference with radiographic imaging and subsequently need for a second surgery for removal of implant. Unfortunately these well established treatments have certain inherent disadvantages like foreign body sensation, tissue reaction, secondary infection, galvanic current reaction [15].

Miniplate osteosynthesis be perfectly adapted to the underlying bone to prevent alteration in the alignment of the segments and changes in the occlusal relationship [16].

It was seen that 3-D titanium miniplates were effective in the treatment of mandibular fractures and overall complication rates were lesser. In symphysis and parasymphysis regions, 3-D plating system uses lesser foreign

material than the conventional miniplates using Champy's principle [17]. There is limitation to use 3D miniplate system in cases of oblique fractures and those involving the mental nerve as well as there is excessive implant material because of the extra vertical bars incorporated for countering the torque forces [18].

Bio-degradable osteosynthesis system, Only parasymphysis fracture were treated and fractures at other sites of the body of mandible were not treated due to fact that interfragmentary contacts plays an important role during the post-operative stability, and hence these fractures were a contraindication for resorbable plates. The undisplaced favorable fractures at the parasymphysis region were plated with resorbable 2.5mm plates and screws [19].

A unique advantage of the 2.0mm locking plate/screw system is that it becomes unnecessary for the plate to have intimate contact with underlying bone, making plate adaptation easier leading to lesser alteration in the alignment of the segment and changes in the occlusal relationship upon screw tightening [20]. In the locking plate /screw system is that plates do not disrupt the underlying cortical bone perfusion, Can be use with undisplaced or minimally displaced fracture of the mandible requiring open reduction and internal fixation in symphysis ,para symphysis ,body and angle region [21].

Our results revealed that Patients' age ranged from 16–57 years, most cases were from 20-29 years 17(37%) followed by 30-39 years 14 (30.4%). Mean age was 36.5 years, the authors in [17] reported that mean age of patients in his study was 37.5 . Mean age of the patients in other studies were as follows: 28.6 years in the study of Guimond and his colleagues [22], 26 years in [23], and 33.9 years in [24].

Our results revealed Postoperative complication, Paresthesia of the lower lip before surgery, encountered in three patients one in group I and two in group II, nerve was entrapped in the fracture fragment which was retrieved during the operation. These patients were followed up until regained normal neurosensory function spontaneously after four weeks in two patients and after six weeks in the one patient. Paresthesia of inferior alveolar nerve was 6.5% in our study, When our results were compared to that reported by [20], on miniplate fixation using Champy's principle, it was found that paresthesia rate was 6% in that study [20] may be due to use of monocortical plate as compared to other types of plating system in which chances of inferior alveolar nerve injury are more due to bicortical screws. But our results were high compared to similar study [25] on Champy's principle showed paresthesia rate of 2.2%.

Our results revealed Postoperative complication, discharge were seen with positive culture test during follow-up in two patients in group 1 and two patients from group 11 showed slight wound dehiscence with exposure of the plate started at the second post-operative week. This patient were treated by continuous irrigation with warm normal saline, antiseptic mouthwash , antibiotic and keeping good oral hygiene until complete wound healing was achieved in twelve days.

The infection rate in our series was 8.6%, which was higher than 0% in [24]. whereas in other studies, the infection rates were: 5.4% in [22], 6.6% in [26], and 8.2% in [27]. May be due to mobility of Fracture which is the main cause of infection postoperatively or the wound were dirty because major etiological factors were road traffic accident or bullets injuries. The infection rate in our series was lower than 10% in [28].

wound dehiscence rate in our series was 8.6%, which was higher than Wound dehiscence was 0% in a study by [28] , whereas 6.6% was reported by [26] may be due to infection rate.

Type of treatment by using mini plate 2.0mm/ mono cortical screws system with and without one week maxillomandibular fixation. there was no difference between two modalities of treatment in healing and post operative complication, our results was in agreement with [13]. The authors in [17] used 3-D titanium miniplates were effective in the treatment of mandibular fractures without maxillomandibular fixation and overall complication rates were lesser, there is limitation to use 3D miniplate system in cases of oblique fractures and those involving the mental nerve as well as there is excessive implant material because of the extra vertical bars incorporated for countering the torque forces [18]. The authors in [21] used 2.0mm locking plate/screw system with out maxillomandibular fixation, they reported that locking plate/screw system has demonstrated higher stability across a fracture / osteotomy gap compared with the conventional non locking 2.0mm mini plate with out maxillomandibular fixation, but they used it in undisplaced or minimally displaced fracture of the mandible. The authors in [29] used tansoral 2.0mm miniplate fixation of mandibular fractures plus 2 weeks maxillomandibular fixation. A prospective study, they reported that inter maxillary fixation with the use of mini plate were needed. [30] reported that a small period post operative inter maxillary fixation with the use of mini plate were needed.

6. Conclusion

Using of 2.0mm mini plate/mono cortical screw system was easy application, simplified adaptation to the bone without distortion or displacement of the fracture, simultaneous stabilization at both superior and inferior borders as it is esthetically accepted, less traumatic and less relapse, can be used with out inter maxillary fixation except comminuted type of fractures, occlusal discrepancies , oblique fractures that inter maxillary fixation for one week was recommended.

References.

- [1] Mosby's Dental Dictionary, 2nd edition. © 2008 Elsevier, Inc. All rights reserved.
- [2] Sameer Choudhari¹, Sulabha A.N², Warad NM¹, A.P.Krishna and Salim Mujawa:Bio-degradable osteosynthesis system in treatment of mandibular parasymphysis fractures. Al Ameen J Med Sci; Volume 5, No.4, 2012.
- [3] Claes L, Grass R, Schmickal T, Kisse B, Eggers C, Gerngross H,et al. 2002. Monitoring and healing analysis of 100 tibial shaft fractures. Langenbecks Arch Surg. 387:146-152.
- [4] Claes L, Eckert-Hubner K, Augat P. 2003.The fracture gap size influences the local vascularization and tissue differentiation in callus healing. Langenbecks Arch Surg. 388:316-322.
- [5] Farwell D G: Mangement of Symphyseal and Parasymphyseal Mandibular Fractures .Operative Techniques in Otolaryngology, (2008) 19: 108-112.
- [6] Ellis E, Ghali G.: Lag screw fixation of anterior mandibular fractures. J Oral Maxillofac Surg.; (1991) 49:13-21.
- [7] Spiessl B.: Rigid internal fixation of the mandible. A manual of AO/ASIF principles. Berlin, Germany: Springer Verlag. (1989).

- [8] Ellis E. Complications of rigid internal fixation for mandible fractures. *J. Craniomaxillofac Trauma*. 1996 2:32–39.
- [9] Kearns GJ, Perrott DH, Kaban LB. 1994. Rigid fixation of mandible fractures: does operator experience reduce complications? *J. Oral Maxillofac Surg*, 52:226–231.
- [10] Champy M, Lodde JP, Schmitt R.: Mandibular osteosynthesis by a miniature Screwed plates via a buccal approach. *J. Maxillofacial surgery* 1978, 6: 14 -21.
- [11] Jones KJ, Sickels Van Ej.: A review of concepts and treatment of fractures. *Oral Surg, Oral Medici, Oral Pathilo* 1988, 65:13-18.
- [12] Harish Saluja, Vipin Dehane, Yogesh Kini, Uma Mahindra.: use of miniplates in parasymphysis fractures. A survey conducted among oral and maxillofacial surgeons of India. *International journal of head and neck surgery* ,Januar–april 2012, 3 (1) 8-10.
- [13] Lee T, Sawhney R, Ducic Y.: Miniplate fixation of fractures of the symphyseal and parasymphyseal regions of the mandible: a review of 218 patients. *JAMA Facial Plast Surg*. 2013 Mar 1;15(2):121-5.
- [14] Lakshmi N Gandi¹, Vivekanand S Kattimani^{1*}, Amit V Gupta¹, V Srinivas Chakravarthi³ and Sridhar S Meka²: Prospective blind comparative clinical study of two point fixation of zygomatic complex fracture using wire and mini plates. *Head & Face Medicine* 2012, 8:7. <http://www.head-face-med.com/content/8/1/7>.
- [15] Sameer Choudhari¹, Sulabha A.N², Warad NM¹, A.P. Krishna and Salim Mujawa : Bio-degradable osteosynthesis system in treatment of mandibular parasymphysis fractures. *Al Ameen J Med Sci*; Volume 5 , No.4, 2012. : 371-375 _ US National Library of Medicine enlisted journal _ ISSN 0974-1143.
- [16] Alpert B, Gutwald R, Schmelzeisen R.: New innovation in craniomaxillofacial fixation . the 2.0mm lock system *Keio J Med*. 2003, 52 ,120-7.
- [17] Sadhasivam Gokkulakrishnan¹, Sanjay Singh², Ashish Sharma¹, Ashish Kumar Shahi¹ :An analysis of postoperative complications and efficacy of 3-D miniplates in fixation of mandibular fractures. *Dental Research Journal / July 2012 / Vol 9 / Issue 4*.
- [18] Mahmoud E. Khalifa¹, Hesham E El-Hawary and Mohamed M. Hussein: Titanium Three Dimensional Miniplate versus Conventional Titanium Miniplate in Fixation of Anterior Mandibular Fractures. *Life Science Journal* 2012;9(2) <http://www.lifesciencesite.com> 1006.
- [19] Tams J, Otten B, Loon JVP, Bos R.R: “A computer study of fracture mobility and strain on biodegradable plates used for fixation of mandibular fractures”. *J. Oral. Maxillofac. Surg*. 1999;57:973-81.
- [20] Feller KU, Schneidet M, Hlawitschka M, Pferfer G, Lauer G, Eckeit.: Analysis of complications fractures of the mandibular angle- a study with finite element computation and evaluation of data of 277 patients *J. Cranio Maxillofac. Surg*. 2003, 31; 290-5.
- [21] Chandan Probhakar, Jayaprasad N, Shetty, Hemavathy O R, Yadavalli Guruprasad.: Efficacy of 2.0mm locking miniplates in the management of mandibular fractures with out maxillary mandibular fixation. *National Journal of Maxillofacial Surgery*. Vol.2, issue 1. Jan-June 2011, 28.
- [22] Guimond C, Johnson JV, Marchena JM. Fixation of mandibular angle fractures with a 2.0 mm 3-dimensional curved angle strut plate. *J Oral Maxillofac Surg* 2005;63:209-14.
- [23] Peter B, Nagi D, Patrick B. Infection rate in mandibular angle fracture treated with a 2.0 mm 8-hole Curved strut plate. *J Oral Maxillofac Surg* 2009;67:804-8.

- [24] Juergen Z, Olivier L, Tateyuki L. Use of straight and curved 3- dimensional titanium miiplates for fracture fixation at the mandibular angle. *J Oral Maxillofac Surg* 2007;65:1758-63.
- [25] Moreno JC, Fernández A, Ortiz JA, Montalvo JJ. Complication rates associated with different treatments for mandibular fractures. *J Oral Maxillofac Surg* 2000;58:273-80.
- [26] Parmar BS, Shailesh M, Raghani, Manish, Toral K. Three dimensional miniplate rigid fixation in fracture mandible. *J Maxillofac Oral Surg* 2007;6:14-6.
- [27] Peter B, Nagi D, Patrick B. Infection rate in mandibular angle fracture treated with a 2.0 mm 8-hole Curved strut plate. *J Oral Maxillofac Surg* 2009;67:804-8.
- [28] Kumar JM, Manjunath KS, Bhagwan BK, Shah Dipit K. Comparison of 3- dimensional and standard miniplate fixation in the management of mandibular fractures. *J Oral Maxillofac Surg* 2010;68:1568-72.
- [29] Bolurian R, rLazow S, Berger J.: Tansoral 2.0mm miniplate fixation of mandibular fractures plus 2 weeks maxillomandibular fixation. A prospective study. *J Oral Maxillofacial Surg* 2002,60; 167-70.
- [30] Al-Belasy Fouad A: A short period of maxillomandibular fixation for treatment of fractures of the mandibular tooth bearing area. *J Oral Maxillofacial Surgery* 2005,63:953-56.