

Washington University School of Medicine

Digital Commons@Becker

Open Access Publications

2019

Association between rotator cuff muscle size and glenoid deformity in primary glenohumeral osteoarthritis

Alexander W Aleem

Peter N Chalmers

Daniel Bechtold

Adam Z Khan

Robert Z Tashjian

See next page for additional authors

Follow this and additional works at: https://digitalcommons.wustl.edu/open_access_pubs

Authors

Alexander W Aleem, Peter N Chalmers, Daniel Bechtold, Adam Z Khan, Robert Z Tashjian, and Jay D Keener

Association Between Rotator Cuff Muscle Size and Glenoid Deformity in Primary Glenohumeral Osteoarthritis

Alexander W. Aleem, MD, Peter N. Chalmers, MD, Daniel Bechtold, MD, Adam Z. Khan, MD, Robert Z. Tashjian, MD, and Jay D. Keener, MD

Investigation performed at the Department of Orthopaedic Surgery, Washington University in St. Louis School of Medicine, St. Louis, Missouri, and the Department of Orthopaedics, University of Utah School of Medicine, Salt Lake City, Utah

Background: Although glenoid morphology has been associated with fatty infiltration of the rotator cuff in arthritic shoulders, the association of rotator cuff muscle area with specific patterns of glenoid wear has not been studied. The purpose of our study was to assess the associations of glenoid deformity in primary glenohumeral osteoarthritis and rotator cuff muscle area.

Methods: A retrospective study of 370 computed tomographic (CT) scans of osteoarthritic shoulders was performed. Glenoid deformity according to the modified Walch classification was determined, and retroversion, inclination, and humeral-head subluxation were calculated using automated 3-dimensional software. Rotator cuff muscle area was measured on sagittal CT scan reconstructions. A ratio of the area of the posterior rotator cuff muscles to the subscapularis was calculated to approximate axial plane potential force imbalance. Univariate and multivariate analyses to determine associations with glenoid bone deformity and rotator cuff measurements were performed.

Results: Patient age and sex were significantly related to cuff muscle area across glenoid types. Multivariate analysis did not find significant differences in individual rotator cuff cross-sectional areas across glenoid types, with the exception of a larger supraspinatus area in Type-B2 glenoids compared with Type-A glenoids (odds ratio [OR], 1.5; $p = 0.04$). An increased ratio of the posterior cuff area to the subscapularis area was associated with increased odds of a Type-B2 deformity (OR, 1.3; $p = 0.002$). Similarly, an increase in this ratio was significantly associated with increased glenoid retroversion ($\beta = 0.92$; $p = 0.01$) and humeral-head subluxation ($\beta = 1.48$; $p = 0.001$). Within the Type-B glenoids, only posterior humeral subluxation was related to the ratio of the posterior cuff to the subscapularis ($\beta = 1.15$; $p = 0.001$).

Conclusions: Age and sex are significantly associated with cuff muscle area in arthritic shoulders. Asymmetric glenoid wear and humeral-head subluxation in osteoarthritis are associated with asymmetric atrophy within the rotator cuff transverse plane. Increased posterior rotator cuff muscle area compared with anterior rotator cuff muscle area is associated with greater posterior glenoid wear and subluxation. It is unclear if the results are causative or associative; further research is required to clarify the relationship.

Level of Evidence: Prognostic Level IV. See Instructions for Authors for a complete description of levels of evidence.

Rotator cuff muscle degeneration is common in the setting of primary glenohumeral osteoarthritis, has an unclear etiology, and is associated with worse outcomes following treatment, specifically after anatomic total shoulder arthroplasty^{1,2}. Previous studies have demonstrated an associ-

ation with high-grade rotator cuff fatty atrophy and worsening glenoid deformity, with Walch Type-B glenoids being more likely to have fatty atrophy²⁻⁴. It is unclear how rotator cuff muscle volumes change in the setting of glenohumeral osteoarthritis compared with shoulders without arthritis. Also, the

Disclosure: The authors indicated that no external funding was received for any aspect of this work. On the **Disclosure of Potential Conflicts of Interest** forms, which are provided with the online version of the article, one or more of the authors checked "yes" to indicate that the author had a relevant financial relationship in the biomedical arena outside the submitted work (<http://links.lww.com/JBJS/F495>).

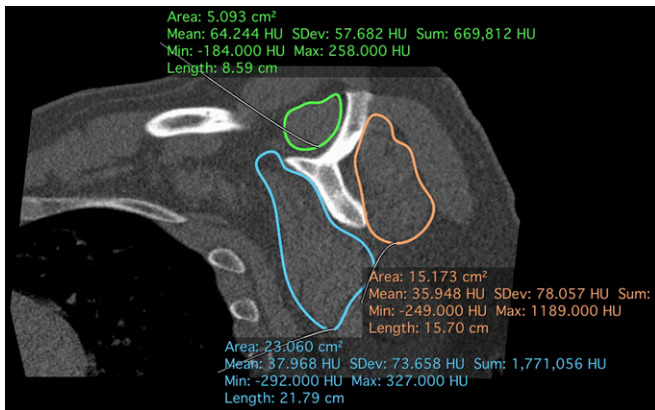


Fig. 1

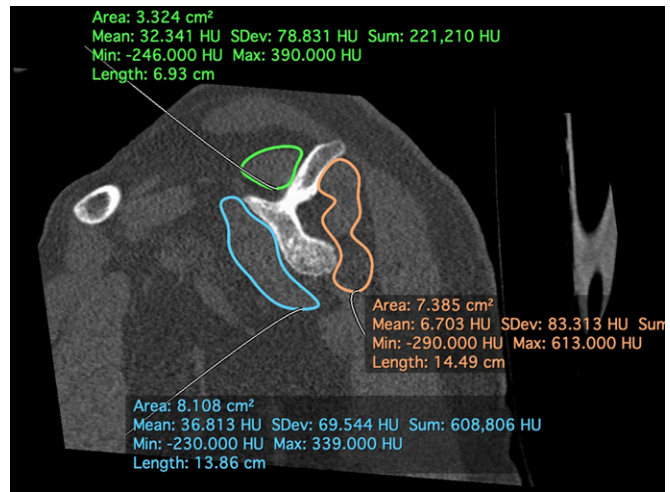


Fig. 2

Fig. 1. Select sagittal CT image of a healthy rotator cuff showing the surface area with individual muscle measurements. The parasagittal image was selected on the basis of a manual reconstruction that is relative to the body of the scapula. The location of the image was chosen to be at the most lateral point in which the scapular spine is connected to the scapular body. The outlines of each rotator cuff muscle were then traced. The infraspinatus and teres minor were hard to discern, so their areas were merged together. This figure demonstrates healthy rotator cuff muscles. HU = Hounsfield units.

Fig. 2. Select sagittal CT image using the same methodology as described in Figure 1. In this case, the rotator cuff areas are very small. HU = Hounsfield units.

relationship of muscle volumes to glenoid deformity in the setting of glenohumeral arthritis is poorly defined.

The majority of studies assess rotator cuff muscle health qualitatively (using the Goutallier classification). However, the Goutallier classification has poor interobserver reliability⁵⁻⁹. The original application of the Goutallier grading system related to the assessment of fatty muscle changes in shoulders with rotator cuff disease^{5,8,10}. The mechanism of the development of fatty infiltration has been proposed to be related to a change in the muscle pennation angle that occurs with tendon retraction seen in shoulders with rotator cuff tears¹¹. Because the majority of arthritic shoulders do not have full-thickness cuff tears, the mechanisms for the development of fatty infiltration in these shoulders remain unclear^{1,3,4,9}.

The Goutallier grading system does not allow for a quantitative assessment of rotator cuff muscle size. The muscle

cross-sectional area is directly related to force generation capacity and may represent a valuable method of assessment of clinically applicable muscle function^{12,13}. Recently, a novel method of measuring the cross-sectional area of rotator cuff muscles on sagittal computed tomographic (CT) images has been validated as a surrogate for total muscle volume^{9,14,15}. A quantitative measurement of the rotator cuff muscle volume may allow for a more precise and reliable assessment of subtle changes in the rotator cuff muscles that occur in osteoarthritic shoulders. This is in contrast to the qualitative assessment of muscle provided by the Goutallier classification, which has limited interobserver reliability.

The purpose of this study was to assess the association between glenoid deformity in primary glenohumeral osteoarthritis and the rotator cuff muscle area, as a surrogate for muscle volume. Based on prior literature³, we hypothesized that glenoid deformities with more severe posterior erosion

TABLE I Subject Demographic Characteristics Based on Walch Glenoid Type

	Total (N = 370)	A1 (N = 44)	A2 (N = 74)	B1 (N = 15)	B2 (N = 159)	B3 (N = 56)	C (N = 22)
Age* (yr)	64.8 ± 9.0	64.5 ± 7.2	67.2 ± 7.2	61.7 ± 12.4	64.1 ± 10.0	66.7 ± 7.6	60.2 ± 9.1
Right side†	207 (55.9%)	25 (56.8%)	44 (59.5%)	7 (46.7%)	81 (50.9%)	38 (67.9%)	12 (54.5%)
Male sex†	244 (65.9%)	23 (52.3%)	34 (45.9%)	7 (46.7%)	115 (72.3%)	45 (80.4%)	20 (90.9%)
Glenoid retroversion*‡ (deg)	19.4 ± 11.5	8.0 ± 7.7	9.5 ± 7.2	19.8 ± 14.0	23.1 ± 7.6	24.6 ± 8.9	36.7 ± 11.0
Glenoid inclination*§ (deg)	6.0 ± 7.9	7.4 ± 6.0	6.1 ± 8.5	8.8 ± 11.6	6.6 ± 7.5	4.9 ± 7.5	0.0 ± 7.3
Humeral-head subluxation*# (%)	75.5 ± 13.4	62.2 ± 11.9	62.9 ± 12.9	80.7 ± 9.8	81.9 ± 8.5	79.3 ± 8.7	85.7 ± 7.5

*The values are given as the mean and the standard deviation. †The values are given as the number of patients, with the percentage in parentheses. ‡In retroversion, a positive value equates to increased retroversion. §In inclination, a positive value equates to superior inclination. #In subluxation, values of >50% imply posterior humeral-head decentering relative to the formatted scapular plane.

TABLE II Univariate Rotator Cuff Cross-Sectional Area by Walch Glenoid Type

Glenoid Type	Supraspinatus Area (cm ² /m)	Infraspinatus and Teres Minor Area (cm ² /m)	Subscapularis Area (cm ² /m)	Infraspinatus and Teres Minor to Subscapularis Ratio
A1*	2.72 (2.46 to 2.97)	7.56 (6.93 to 8.20)	10.46 (9.61 to 11.30)	0.75 (0.68 to 0.80)
A2*	2.58 (2.37 to 2.80)	7.05 (6.61 to 7.49)	9.78 (9.18 to 10.38)	0.74 (0.70 to 0.78)
B1*	3.08 (2.30 to 3.65)	8.29 (6.93 to 9.64)	10.38 (8.53 to 12.24)	0.83 (0.71 to 0.96)
B2*	3.05 (2.92 to 3.17)	8.25 (7.94 to 8.59)	10.39 (9.95 to 10.82)	0.81 (0.79 to 0.84)
B3*	2.73 (2.50 to 2.95)	7.73 (7.18 to 8.27)	10.42 (9.62 to 11.22)	0.76 (0.72 to 0.81)
C*	3.13 (2.74 to 3.52)	8.93 (8.08 to 9.76)	11.50 (10.18 to 12.82)	0.80 (0.72 to 0.88)
Total†	2.87 ± 0.87	7.90 ± 2.07	10.35 ± 2.82	0.78 ± 0.18
P value‡ (among groups)	0.001	<0.001	0.24	0.02

*The values are given as the mean estimate and the 95% CI. †The values are given as the mean and the standard deviation. ‡A 1-way ANOVA test was performed to test for significance (see Appendix for the post hoc analysis between groups).

and posterior humeral-head subluxation will be associated with lower muscle area of the posterior rotator cuff compared with shoulders with no glenoid erosion and a well-centered humeral head.

Materials and Methods

A 2-center retrospective cohort study was performed. After obtaining institutional review board approval, billing databases were queried for patients who underwent a shoulder arthroplasty from 2012 to 2017 and who had a CT scan performed within 3 months prior to their surgical date. Patients were included in the study if they underwent primary shoulder arthroplasty for primary glenohumeral osteoarthritis based on radiographic and clinical examination. Patients with rotator cuff weakness were evaluated with ultrasound or magnetic resonance imaging (MRI) to assess cuff integrity. Exclusion criteria included the CT scan not being performed in the appropriate time period or in the operatively treated shoulder; a history of inflammatory arthritis, rotator cuff tear arthropathy, prior proximal humeral fracture, prior rotator cuff repair, or a known rotator cuff tear; or an inability to obtain the CT scan. The decision to obtain a CT scan was left to the discretion of the treating surgeon but was generally indicated on the basis of the presence of advanced or asymmetric glenoid wear and/or humeral-head subluxation.

During the study period, 465 CT scans were identified in shoulders that satisfied all inclusion and exclusion criteria. Patient demographic characteristics including age at the time of the surgical procedure, sex, self-reported height, self-reported weight, and the side of the surgical procedure were obtained. CT scans were analyzed using a 3-dimensional automated software program (BLUEPRINT; Wright Medical Group)¹⁶ to measure glenoid retroversion and inclination and humeral-head subluxation. If the scan could not be reformatted with the 3-dimensional software, the subject was excluded from the study. Ultimately, 370 CT scans were included in the final analysis after a review of the images.

To calculate the rotator cuff cross-sectional area, sagittal reconstructions of CT scans were evaluated using a previously

validated measurement utilizing OsiriX software (Pixmeo)⁹. First, the sagittal series was reoriented to be perpendicular to the plane of the scapula, as defined by the center of the glenoid, the inferior angle, and the trigonum. The most lateral parasagittal slice in which the scapular spine was connected to the scapular body was identified. The areas (in cm²) of the supraspinatus, infraspinatus and teres minor, and subscapularis were calculated using the closed polygon tool, providing

TABLE III ICCs for Rotator Cuff Area Measurements

Rotator Cuff Muscle Area	ICC*
Supraspinatus	0.898 (0.843 to 0.937)
Infraspinatus and teres minor	0.918 (0.873 to 0.950)
Subscapularis	0.909 (0.859 to 0.944)

*The values are given as the ICC, with the 95% CI in parentheses. The guidelines for assessment are: <0.40, poor reliability; 0.40 to 0.59, fair reliability; 0.60 to 0.74, good reliability; and 0.75 to 1.00, excellent reliability.

TABLE IV Interobserver Reliability of the Goutallier Grade Using the Cohen Kappa*

Rotator Cuff Muscle	Goutallier Grade by Observer		
	1 vs. 2	2 vs. 3	1 vs. 3
Supraspinatus	0.271	0.039	0.241
Infraspinatus	0.046	0.163	0.159
Teres minor	0.128	0.146	0.158
Subscapularis	0.224	0.286	0.113

*The guidelines for assessment are: <0.40, poor reliability; 0.40 to 0.59, fair reliability; 0.60 to 0.74, good reliability; and 0.75 to 1.00, excellent reliability.

TABLE V Pearson Correlations of Rotator Cuff Area with Age and Glenohumeral Joint Characteristics

Rotator Cuff Area	Age		Retroversion		Inclination		Subluxation	
	R Value	P Value	R Value	P Value	R Value	P Value	R Value	P Value
Supraspinatus	-0.328	<0.001	0.153	0.003	0.046	0.38	0.155	0.003
Infraspinatus and teres minor	-0.402	<0.001	0.134	0.01	0.006	0.90	0.143	0.006
Subscapularis	-0.29	<0.001	0.042	0.43	0.025	0.63	-0.007	0.90
Infraspinatus and teres minor to subscapularis ratio	-0.131	0.01	0.105	0.04	-0.035	0.50	0.177	0.001

automated measurement of the area. The infraspinatus and teres minor were measured as a single muscle area as previously described (Figs. 1 and 2). These measurements were then divided by the patient's height in meters to control for differences in the patient's osseous stature. The ratio of the infraspinatus and teres minor area to the subscapularis area was calculated to measure the potential force imbalance in the axial plane between the anterior and posterior portions of the rotator cuff. Additionally, all rotator cuff muscles were graded according the Goutallier classification⁶. All measurements were performed by 1 of 3 fellowship-trained shoulder and elbow surgeons. Of the 370 scans, the breakdown of area measurements by individual reviewer was 72, 103, and 195. Reviewers were not blinded to individual subjects' demographic characteristics, but they were blinded to their outcomes following the surgical procedure.

Finally, glenoid morphology was determined by reviewing the radiographs and 2-dimensional CT scan images based on the modified Walch classification¹⁷. Each scan was reviewed by at least 2 surgeons and, if there was disagreement among the reviewers, group consensus was obtained by collective review and agreement on the classification. Approximately 22% (82) of the 370 scans required consensus grading of the Walch classification.

Statistical Analysis

Descriptive statistics were calculated to determine the distributions of age, sex, glenoid morphology, and rotator cuff areas, using parametric and nonparametric statistics when applicable. To determine the reliability of both the rotator cuff area mea-

surements and the Goutallier classification, a random sampling of 50 CT scans were given to 3 fellowship-trained surgeons. Interobserver reliability and intraclass correlation coefficients (ICCs) were then determined for each rotator cuff grading assessment.

Univariate analysis was performed to determine the association between demographic characteristics and specific rotator cuff area measurements, glenoid retroversion, glenoid inclination, and humeral-head subluxation. Finally, a multinomial multivariate logistic regression model was performed to determine the association of rotator cuff area with Walch glenoid type, while controlling for confounders identified in univariate analysis. Similarly, multivariate linear regression models were performed to determine rotator cuff area associations with retroversion, inclination, and subluxation. A sub-analysis of all Type-B glenoids was also performed. For all analyses, significance was set at $p < 0.05$.

Results

Table I demonstrates the demographic characteristics, glenoid measurements, and muscle areas for the 370 CT scans included in the study. The distribution of the rotator cuff area based on the modified Walch classification is shown in Table II. One-way analysis of variance (ANOVA) with post hoc Tukey testing found significant differences in supraspinatus and infraspinatus plus teres minor areas as well as the ratio of the infraspinatus and teres minor to the subscapularis between Walch glenoid types. However, no differences were found in the subscapularis area between groups. The Appendix shows the complete post hoc analysis within each Walch subtype.

TABLE VI Differences Between Sexes for Rotator Cuff Area Measurements

Rotator Cuff Area	Area by Sex* (cm^2)		Difference† (cm^2)	P Value
	Male	Female		
Supraspinatus	4.16	2.29	1.87 (1.62 to 2.12)	<0.001
Infraspinatus and teres minor	8.70	6.23	2.45 (2.15 to 2.77)	<0.001
Subscapularis	11.46	8.14	3.33 (2.90 to 3.76)	<0.001

*The values are given as the mean area. †The values are given as the mean difference in the area, with the 95% CI in parentheses.

TABLE VII Multinomial Multivariate Logistic Regression Model for Walch Glenoid Type

Glenoid Type*	Factor	Beta†	P Value	OR‡
B1	Age per year	-0.03	0.37	0.97 (0.91 to 1.04)
	Supraspinatus area, per cm ² /m	0.65	0.12	1.91 (0.85 to 4.30)
	Infraspinatus and teres minor area, per cm ² /m	0.1	0.63	1.11 (0.73 to 1.67)
	Infraspinatus and teres minor to subscapularis ratio	0.23	0.19	1.26 (0.89 to 1.78)
	Male sex	-0.98	0.2	0.38 (0.08 to 1.70)
B2	Age per year	-0.004	0.83	1 (0.97 to 1.0)
	Supraspinatus area, per cm ² /m	0.42	0.04	1.5 (1.03 to 2.25)
	Infraspinatus and teres minor area, per cm ² /m	-0.04	0.66	0.96 (0.79 to 1.16)
	Infraspinatus and teres minor to subscapularis ratio	0.28	0.002	1.32 (1.11 to 1.57)
	Male sex	0.81	0.02	2.24 (1.16 to 4.33)
B3	Age per year	0.02	0.44	1.02 (0.98 to 1.06)
	Supraspinatus area, per cm ² /m	-0.15	0.58	0.87 (0.51 to 1.45)
	Infraspinatus and teres minor area, per cm ² /m	-0.09	0.48	0.91 (0.71 to 1.18)
	Infraspinatus and teres minor to subscapularis ratio	0.15	0.21	1.15 (0.92 to 1.45)
	Male sex	1.85	<0.001	6.34 (2.56 to 15.78)
C	Age per year	-0.04	0.11	0.96 (0.91 to 1.00)
	Supraspinatus area, per cm ² /m	0.04	0.91	1.04 (0.51 to 2.12)
	Infraspinatus and teres minor area, per cm ² /m	0.06	0.71	1.07 (0.76 to 1.50)
	Infraspinatus and teres minor to subscapularis ratio	0.18	0.25	1.2 (0.88 to 1.63)
	Male sex	2.06	0.02	7.84 (1.48 to 41.40)

*The Walch Type-A glenoid is the reference outcome. †Beta refers to the strength of the association between the dependent variables and the variable of interest. ‡The values are given as the OR, with the 95% CI in parentheses.

Muscle Area Validation

ICCs were high (range, 0.90 to 0.92) for all muscles using the rotator cuff area measurements (Table III). Conversely, the interobserver reliability of Goutallier grading was found to be poor (range, 0.04 to 0.29) for all muscles between all reviewers (Table IV).

Univariate Analysis

Univariate analysis with Pearson correlation coefficients (Table V) found moderate and significant negative correlations between rotator cuff area measurements and age for all rotator cuff

muscles. Similar analysis also found weak, but significant, positive correlations of both increasing glenoid retroversion ($r = 0.153$; $p = 0.003$) and posterior subluxation ($r = 0.155$; $p = 0.003$) with the supraspinatus muscle area; there was also a weak but significant positive correlation of both increasing glenoid retroversion ($r = 0.134$; $p = 0.01$) and posterior subluxation ($r = 0.143$; $p = 0.006$) with the infraspinatus plus teres minor muscle area. Glenoid inclination was not correlated with the rotator cuff muscle area. No associations were found between the subscapularis area and glenoid retroversion, inclination, or subluxation.

TABLE VIII Linear Regression Model for Glenoid Retroversion

Factor	Beta*	Standardized Beta†	P Value
Age in yr	-0.008 (-0.15 to 0.13)	-0.006	0.91
Male sex	5.8 (2.76 to 8.74)	0.238	<0.001
Supraspinatus area	1.4 (-0.31 to 3.07)	0.105	0.11
Infraspinatus and teres minor area	-0.61 (-1.46 to 0.25)	-0.109	0.17
Infraspinatus and teres minor to subscapularis ratio	0.92 (0.19 to 1.64)	0.143	0.01

*The values are given as the beta, with the 95% CI in parentheses. Beta refers to the strength of the association between the dependent variables and the variable of interest. †Standardized beta is a measurement that has been weighted to allow for comparisons of the relative strengths of individual variables in the model with each other.

TABLE IX Linear Regression Model for Humeral-Head Subluxation

Factor	Beta*	Standardized Beta†	P Value
Age in yr	0.045 (−0.12 to 0.21)	0.03	0.59
Male sex	2.61 (−0.90 to 6.11)	0.09	0.15
Supraspinatus area	2.31 (0.33 to 4.30)	0.15	0.02
Infraspinatus and teres minor area	−0.35 (−1.35 to 0.66)	−0.05	0.5
Infraspinatus and teres minor to subscapularis ratio	1.48 (0.63 to 2.34)	0.2	0.001

*The values are given as the beta, with the 95% CI in parentheses. Beta refers to the strength of the association between the dependent variables and the variable of interest. †Standardized beta is a measurement that has been weighted to allow for comparisons of the relative strengths of individual variables in the model with each other.

The resultant infraspinatus and teres minor to subscapularis ratio was positively correlated with increasing glenoid retroversion ($r = 0.105$; $p = 0.04$) and subluxation ($r = 0.177$; $p = 0.001$). Additionally, male patients had larger areas for all 3 rotator cuff measurements (Table VI).

Multivariate Analysis

Based on the findings of the univariate analysis, a multinomial multivariate logistic regression model was performed to determine the association of the muscle area with the glenoid morphology type, controlling for the confounding variables of age and sex. Type-A1 and A2 glenoids were pooled together as the reference value, as there were no differences in muscle area between these 2 subtypes, allowing a comparison of centered-wear patterns with posterior-wear patterns. Age, sex, supraspinatus area, infraspinatus and teres minor area, and the ratio of the infraspinatus and teres minor to the subscapularis were input as independent variables. Table VII shows the results of the model for each glenoid type.

Glenoids with Type-B2 wear patterns were found to have significant differences in the supraspinatus area, the ratio of the infraspinatus and teres minor to the subscapularis, and patient sex compared with Type-A glenoids (Table VII). With regard to odds ratio (OR), sex was the strongest variable (based on the largest OR) associated with the Type-B2 pattern, with male patients having a 2.2 (95% confidence interval [CI], 1.2 to 4.3;

$p = 0.02$) times higher odds of a Type-B2 glenoid compared with a Type-A glenoid. For each increase in supraspinatus area of $1 \text{ cm}^2/\text{m}$, there was an associated 1.5 (95% CI, 1.0 to 2.3; $p = 0.04$) times increase in the likelihood of a Type-B2 glenoid. There was no difference in the infraspinatus and teres minor muscle area in the Type-B2 glenoids compared with the Type-A glenoids. However, with each increase in infraspinatus and teres minor to subscapularis muscle ratio of 0.1, the odds of having a Type-B2 wear pattern increased by 32% (OR, 1.3 [95% CI, 1.1 to 1.6]; $p = 0.002$).

Multivariate linear regression models were also run to determine the variable associations with glenoid retroversion (Table VIII) and humeral-head subluxation (Table IX) across all glenoid types. For glenoid retroversion, male sex showed a significant association, as male patients had 5.8° more retroversion than female patients (beta = 5.8 [95% CI, 2.8 to 8.7]; $p < 0.001$). When controlling for confounders, the supraspinatus and infraspinatus plus teres minor muscle areas had no significant relationship with retroversion across all glenoids. An increase in the ratio of infraspinatus and teres minor to subscapularis muscle area of 0.1 was associated with 0.9° of increased retroversion (beta = 0.92 [95% CI, 0.19 to 1.6]; $p = 0.01$).

When controlling for confounders, with regard to the standardized beta, both the supraspinatus area (beta = 2.3 [95% CI, 0.33 to 4.3]; standardized beta = 0.15; $p = 0.02$) and the infraspinatus and teres minor to subscapularis ratio

TABLE X Linear Regression Model for Retroversion in Walch Type-B Glenoids

Factor	Beta*	Standardized Beta†	P Value
Age in yr	0.033 (−0.10 to 0.16)	0.038	0.61
Female sex	−2.55 (−5.47 to 0.37)	−0.134	0.09
Supraspinatus area	1.03 (−0.71 to 2.77)	0.1	0.24
Infraspinatus and teres minor area	−0.77 (−1.55 to 0.02)	−0.185	0.06
Infraspinatus and teres minor to subscapularis ratio	0.57 (−0.13 to 1.27)	0.115	0.11

*The values are given as the beta, with the 95% CI in parentheses. Beta refers to the strength of the association between the dependent variables and the variable of interest. †Standardized beta is a measurement that has been weighted to allow for comparisons of the relative strengths of individual variables in the model with each other.

TABLE XI Linear Regression Model for Humeral-Head Subluxation in Walch Type-B Glenoids

Factor	Beta*	Standardized Beta†	P Value
Age in yr	0.041 (−0.09 to 0.17)	0.046	0.53
Female sex	2 (−0.92 to 4.93)	0.103	0.18
Supraspinatus area	1.18 (−0.56 to 2.92)	0.112	0.19
Infraspinatus and teres minor area	−0.38 (−1.17 to 0.40)	−0.09	0.34
Infraspinatus and teres minor to subscapularis ratio	1.15 (0.45 to 1.85)	0.229	0.001

*The values are given as the beta, with the 95% CI in parentheses. Beta refers to the strength of the association between the dependent variables and the variable of interest. †Standardized beta is a measurement that has been weighted to allow for comparisons of the relative strengths of individual variables in the model with each other.

(beta = 1.5 [95% CI, 0.63 to 2.3]; standardized beta = 0.2; p = 0.001) had a significantly positive association with increasing posterior humeral-head subluxation, with the ratio of the infraspinatus and teres minor to the subscapularis having the strongest association, based on the smallest p value.

Type-B Subanalysis

Given the high incidence of Type-B glenoids in the cohort, linear regression models were then rerun with only the Type-B glenoids, controlling for confounding variables (Tables X and XI). Within the Type-B glenoids, the degree of retroversion was not associated with muscle area when controlling for age and sex. Finally, for humeral-head subluxation, only the ratio of the infraspinatus and teres minor to the subscapularis was found to be significant, with an increase in the ratio of 0.1 resulting in a 1.15% increase in subluxation (beta = 1.15 [95% CI, 0.45 to 1.85]; p = 0.001).

Discussion

This study described the use of a method of assessing rotator cuff muscle area in a highly reliable manner across variable glenoid morphologies in patients with glenohumeral osteoarthritis. Our analysis demonstrated that age and sex had a significant effect on the muscle cross-sectional area. This relationship may confound analysis of the effect of glenoid type on muscle area measurements and therefore should be recognized in future analyses comparing muscle volume and glenoid morphology.

Contrary to previous research performed by Donohue et al. and our hypothesis, we found almost no difference in individual rotator cuff muscle changes when controlling for age and sex between Walch Type-A and B glenoids⁴. However, the ratio of the infraspinatus and teres minor area to the subscapularis area was found to be associated with glenoid morphology, retroversion, and humeral-head subluxation, suggesting that an axial plane force imbalance is associated with glenoid deformity in shoulders with glenohumeral osteoarthritis. This association between greater posterior rotator cuff muscle area relative to anterior muscle area with posterior glenoid erosion and subluxation may be causal or simply associative and needs further investigation.

Our analysis suggests that comparisons of the rotator cuff muscle area should control for the confounding factors of age

and sex, which significantly influence the rotator cuff muscle area. When controlling for these variables, we found no difference between Type-A1 and A2 glenoids, and Type-A glenoids collectively compared with Type-B1 glenoids, unlike a prior study⁴. However, Type-B2 glenoids, when controlling for age and sex, were associated with a larger supraspinatus muscle area and a larger infraspinatus and teres minor to subscapularis ratio than Type-A glenoids. Given that the infraspinatus plus teres minor areas were similar between Type-B2 and A glenoids, these findings suggest that the subscapularis may be relatively atrophied in Type-B2 shoulders.

Comparisons of muscle areas were not significant when examining Type-B3 and C glenoids, possibly because of a lack of power given the smaller groups. Additionally, with more medialization in Type-B3 glenoids, the posterior cuff force imbalance potentially normalizes closer to that of Type-A glenoids. A clarification of this phenomenon would require a temporal analysis rather than a single-point-in-time analysis. Although our study demonstrated only association, it suggests that the dynamic anterior and posterior rotator cuff forces are not balanced in shoulders with posterior glenoid wear and humeral subluxation.

Increasing posterior humeral-head subluxation was associated with a larger infraspinatus and teres minor to subscapularis ratio among Type-B glenoids, which has not been previously described, to our knowledge. The cause of this relationship is unknown. These findings suggest that posterior subluxation may have a more substantial effect on cuff muscle changes than glenoid retroversion within the B subtype. It is possible that larger posterior musculature could promote a greater amount of posterior subluxation. Although humeral-head subluxation is thought to influence posterior glenoid erosion and the subsequent acquired glenoid version deformities in Walch Type-B glenoids^{18,19}, glenoid version and humeral subluxation are imperfectly correlated²⁰⁻²². The findings of our study may have implications for the etiology of the development of asymmetric wear. However, further research is warranted to determine the cause and effect.

Prior investigations with regard to rotator cuff muscle health in arthritic shoulders demonstrated some differences from our study. Walker et al. attempted to determine temporal relationships in glenohumeral osteoarthritis²³. In a series of 65

shoulders with CT scans at least 2 years apart and with known osteoarthritis, patients with initial posterior subluxation were more likely to progress to worsening deformity and to demonstrate a higher percentage of fatty infiltration in the rotator cuff compared with shoulders without subluxation. Although that study was limited by its sample size, it does suggest that the posterior subluxation of the glenohumeral joint is associated with degenerative muscle changes, similar to our findings. Donohue et al. performed an analysis of 190 CT scans with various glenoid morphologies⁴. They determined that higher-grade fatty infiltration, as determined by the Goutallier classification, was associated with advanced Walch Type-B deformities as well as increased glenoid retroversion and increased joint line medialization. The findings of that study, which was the basis of our hypothesis, were difficult to compare with our own. This is related to several factors. First, the studies used different methods of muscle assessment: fatty infiltration compared with muscle area. The relationship between fatty infiltration and rotator cuff muscle cross-sectional area is unknown and they may vary independently. Second, the study by Donohue et al. did not control for age (due to the limited sample size) and sex, which were shown in the present study to be important confounding variables. In our study, we did not find any associations between the isolated cuff muscle areas and glenoid morphology when controlling for confounding variables. Lastly, Donohue et al. did not examine the role of humeral-head subluxation as an independent variable affecting muscle changes. In our analysis, humeral-head subluxation was more consistently related to muscle changes than glenoid type and version, which were the emphasis of the study by Donohue et al. We believe our measurements to be accurate given the reliable and validated method of muscle assessment and the detailed control of confounding variables.

Another major difference between the current study and prior investigations is that prior studies relied heavily on the Goutallier classification rather than the muscle volume area calculation used in our current study. The Goutallier classification relies on a subjective assessment of the rotator cuff muscles and demonstrates poor reliability⁸⁻¹⁰. We also found poor inter-observer reliability, making meaningful comparisons of fatty infiltration difficult. Utilizing a cross-sectional area measurement on sagittal reconstruction of CT scans benefits from being objective and reliable, allowing for more precise analysis⁹. To further increase data reliability, we used multiple observers for the determination of Walch glenoid deformity type and an automated, validated method for the measurement of glenoid version and inclination and humeral-head subluxation.

Our study had limitations. These included the retrospective nature and inclusion of only patients who had undergone a surgical procedure for glenohumeral arthritis. There was a disproportionately high number of Type-B2 and B3 glenoids compared with Type-B1 and C glenoids, which reflects the nature of glenoid wear in shoulders with osteoarthritis. This was also a reflection of selection bias, as CT scans were usually acquired in shoulders with more severe glenoid deformities and humeral subluxation at our institutions. Approximately 20% of available cases were excluded because of segmentation errors in the CT reconstructions, which

may have limited our power to analyze less frequently encountered glenoid types. Additionally, we were not able to determine the temporal associations of muscle changes with the natural history of advancing glenohumeral osteoarthritis and glenoid deformities. Our study did not assess clinical function in these subjects. It was unclear how much muscle atrophy may have correlated with shoulder dysfunction and pain. Furthermore, muscle area can only represent a potential surrogate for muscle force and may not ideally represent the dynamic forces that the muscles actually produce. To normalize for differences in muscle force based on body size, measured rotator cuff areas were divided by individual patient height. Several different methods exist to account for differences in muscle force based on body size for various muscles, but there is no consensus about which method best approximates muscle force and no specific validation in the rotator cuff²⁴⁻²⁶. Therefore, we believed that height was an appropriate surrogate to use to account for differences in body size. Reviewers were not blinded to the demographic characteristics of individual patients but were blinded to their clinical outcome, reducing the possibility of detection bias. Finally, we were unable to adequately determine joint-line medialization in our analysis. Medialization has been shown to be related to muscle fatty infiltration in a previous study⁴.

In conclusion, we found that, in a large sample of patients with glenohumeral osteoarthritis, the cross-sectional area of the rotator cuff was significantly related to patient age and sex. We did not find any associations between isolated cuff muscle areas and glenoid morphology when controlling for confounding variables, with the exception of an increased supraspinatus area in Type-B2 glenoids compared with Type-A glenoids. For all glenoid types, when controlling for confounding variables, posterior glenoid wear and subluxation in osteoarthritis were primarily associated with asymmetric atrophy within the rotator cuff transverse plane force balance. Further investigation is needed to validate this hypothesis and to ascertain the temporal relationship between glenoid wear and rotator cuff changes.

Appendix

eA Supporting material provided by the authors is posted with the online version of this article as a data supplement at [jbjs.org \(http://links.lww.com/JBJS/F496\)](http://links.lww.com/JBJS/F496). ■

Alexander W. Aleem, MD¹
Peter N. Chalmers, MD²
Daniel Bechtold, MD¹
Adam Z. Khan, MD¹
Robert Z. Tashjian, MD²
Jay D. Keener, MD¹

¹Department of Orthopaedic Surgery, Washington University in St. Louis School of Medicine, St. Louis, Missouri

²Department of Orthopaedics, University of Utah School of Medicine, Salt Lake City, Utah

Email address for A.W. Aleem: aleema@wustl.edu

ORCID iD for A.W. Aleem: [0000-0002-2839-0501](https://orcid.org/0000-0002-2839-0501)
 ORCID iD for P.N. Chalmers: [0000-0002-1275-0285](https://orcid.org/0000-0002-1275-0285)
 ORCID iD for D. Bechtold: [0000-0003-1017-1842](https://orcid.org/0000-0003-1017-1842)

ORCID iD for A.Z. Khan: [0000-0002-7251-6503](https://orcid.org/0000-0002-7251-6503)
 ORCID iD for R.Z. Tashjian: [0000-0003-4112-0423](https://orcid.org/0000-0003-4112-0423)
 ORCID iD for J.D. Keener: [0000-0002-1665-4346](https://orcid.org/0000-0002-1665-4346)

References

- Young AA, Walch G, Pape G, Gohlke F, Favard L. Secondary rotator cuff dysfunction following total shoulder arthroplasty for primary glenohumeral osteoarthritis: results of a multicenter study with more than five years of follow-up. *J Bone Joint Surg Am.* 2012 Apr 18;94(8):685-93.
- Lapner PLC, Jiang L, Zhang T, Athwal GS. Rotator cuff fatty infiltration and atrophy are associated with functional outcomes in anatomic shoulder arthroplasty. *Clin Orthop Relat Res.* 2015 Feb;473(2):674-82. Epub 2014 Sep 30.
- Naimark M, Berliner J, Zhang AL, Davies M, Ma CB, Feeley BT. Prevalence of rotator cuff atrophy and fatty infiltration in patients undergoing total shoulder arthroplasty. *J Shoulder Elbow Arthroplasty.* 2017 Jan 1;1:247154921770832. Epub 2017 May 11.
- Donohue KW, Ricchetti ET, Ho JC, Iannotti JP. The association between rotator cuff muscle fatty infiltration and glenoid morphology in glenohumeral osteoarthritis. *J Bone Joint Surg Am.* 2018 Mar 7;100(5):381-7.
- Fuchs B, Weishaupt D, Zanetti M, Hodler J, Gerber C. Fatty degeneration of the muscles of the rotator cuff: assessment by computed tomography versus magnetic resonance imaging. *J Shoulder Elbow Surg.* 1999 Nov-Dec;8(6):599-605.
- Goutallier D, Postel JM, Bernageau J, Lavau L, Voisin MC. Fatty muscle degeneration in cuff ruptures. Pre- and postoperative evaluation by CT scan. *Clin Orthop Relat Res.* 1994 Jul;304:78-83.
- Goutallier D, Postel JM, Gleyze P, Leguilloux P, Van Driessche S. Influence of cuff muscle fatty degeneration on anatomic and functional outcomes after simple suture of full-thickness tears. *J Shoulder Elbow Surg.* 2003 Nov-Dec;12(6):550-4.
- Lee E, Choi JA, Oh JH, Ahn S, Hong SH, Chai JW, Kang HS. Fatty degeneration of the rotator cuff muscles on pre- and postoperative CT arthrography (CTA): is the Goutallier grading system reliable? *Skeletal Radiol.* 2013 Sep;42(9):1259-67. Epub 2013 Jun 21.
- Chalmers PN, Beck L, Stertz I, Aleem A, Keener JD, Henninger HB, Tashjian RZ. Do magnetic resonance imaging and computed tomography provide equivalent measures of rotator cuff muscle size in glenohumeral osteoarthritis? *J Shoulder Elbow Surg.* 2018 Oct;27(10):1877-83. Epub 2018 May 10.
- Oh JH, Kim SH, Choi JA, Kim Y, Oh CH. Reliability of the grading system for fatty degeneration of rotator cuff muscles. *Clin Orthop Relat Res.* 2010 Jun;468(6):1558-64. Epub 2009 Apr 4.
- Meyer DC, Wieser K, Farshad M, Gerber C. Retraction of supraspinatus muscle and tendon as predictors of success of rotator cuff repair. *Am J Sports Med.* 2012 Oct;40(10):2242-7. Epub 2012 Aug 27.
- Gladstone JN, Bishop JY, Lo IKY, Flatow EL. Fatty infiltration and atrophy of the rotator cuff do not improve after rotator cuff repair and correlate with poor functional outcome. *Am J Sports Med.* 2007 May;35(5):719-28. Epub 2007 Mar 2.
- Piepers I, Boudt P, Van Tongel A, De Wilde L. Evaluation of the muscle volumes of the transverse rotator cuff force couple in nonpathologic shoulders. *J Shoulder Elbow Surg.* 2014 Jul;23(7):e158-62. Epub 2013 Dec 15.
- Tingart MJ, Apreleva M, Lehtinen JT, Capell B, Palmer WE, Warner JJP. Magnetic resonance imaging in quantitative analysis of rotator cuff muscle volume. *Clin Orthop Relat Res.* 2003 Oct;415:104-10.
- Lehtinen JT, Tingart MJ, Apreleva M, Zurakowski D, Palmer W, Warner JJP. Practical assessment of rotator cuff muscle volumes using shoulder MRI. *Acta Orthop Scand.* 2003 Dec;74(6):722-9.
- Chalmers PN, Salazar D, Chamberlain A, Keener JD. Radiographic characterization of the B2 glenoid: the effect of computed tomographic axis orientation. *J Shoulder Elbow Surg.* 2017 Feb;26(2):258-64. Epub 2016 Aug 31.
- Bericik MJ, Kruse K 2nd, Yalozis M, Gauci MO, Chaoui J, Walch G. A modification to the Walch classification of the glenoid in primary glenohumeral osteoarthritis using three-dimensional imaging. *J Shoulder Elbow Surg.* 2016 Oct;25(10):1601-6. Epub 2016 Jun 6.
- Domos P, Checchia CS, Walch G. Walch B0 glenoid: pre-osteoarthritic posterior subluxation of the humeral head. *J Shoulder Elbow Surg.* 2018 Jan;27(1):181-8. Epub 2017 Sep 28.
- Walch G, Ascani C, Boulahia A, Nové-Josserand L, Edwards TB. Static posterior subluxation of the humeral head: an unrecognized entity responsible for glenohumeral osteoarthritis in the young adult. *J Shoulder Elbow Surg.* 2002 Jul-Aug;11(4):309-14.
- Walch G, Badet R, Boulahia A, Khoury A. Morphologic study of the glenoid in primary glenohumeral osteoarthritis. *J Arthroplasty.* 1999 Sep;14(6):756-60.
- Hoenecke HR Jr, Tibor LM, D'Lima DD. Glenoid morphology rather than version predicts humeral subluxation: a different perspective on the glenoid in total shoulder arthroplasty. *J Shoulder Elbow Surg.* 2012 Sep;21(9):1136-41. Epub 2011 Nov 12.
- Gerber C, Costouros JG, Sukthankar A, Fucentese SF. Static posterior humeral head subluxation and total shoulder arthroplasty. *J Shoulder Elbow Surg.* 2009 Jul-Aug;18(4):505-10. Epub 2009 May 29.
- Walker KE, Simcock XC, Jun BJ, Iannotti JP, Ricchetti ET. Progression of glenoid morphology in glenohumeral osteoarthritis. *J Bone Joint Surg Am.* 2018 Jan 3;100(1):49-56.
- Jaric S. Role of body size in the relation between muscle strength and movement performance. *Exerc Sport Sci Rev.* 2003 Jan;31(1):8-12.
- Markovic G, Jaric S. Movement performance and body size: the relationship for different groups of tests. *Eur J Appl Physiol.* 2004 Jun;92(1-2):139-49. Epub 2004 Mar 16.
- Davies MJ, Dalsky GP. Normalizing strength for body size differences in older adults. *Med Sci Sports Exerc.* 1997 May;29(5):713-7.