

# STUMP APPENDICITIS AFTER LAPAROSCOPIC APPENDECTOMY: A RARE CLINICAL ENTITY

Asmir Jonuzi, Nusret Popović, Zlatan Zvizdić, Emir Milišić

## ABSTRACT

**Background:** Stump appendicitis is an acute inflammation of the residual part of the appendix and a rare complication of incomplete appendectomy. This is a rare delayed complication after appendectomy with the reported incidence of 1 in 50,000 cases. Clinically it can be presented as acute abdomen and presents a diagnostic dilemma. Prompt recognition is important to lead to an early treatment, thus avoiding serious complications.

**Casestudy:** We present a 14-year-old girl with diagnosis of stump appendicitis, who underwent surgical treatment (open appendectomy) after having laparoscopic appendectomy a month before. Radiologically (UZV and CT scan) was diagnosed an inflammatory mass with abscess dimension 41 x 21 mm in the right iliac fossa. During operation a 1,5 cm-diameter appendiceal stump was noted in the anatomical region of the appendix. The appendiceal stump was resected and inverted into the cecal wall. Histopathology examination showed acute inflammation and patchy necrosis of the appendiceal stump. The post-operative course was uneventful. Patient was discharged on third post-operative day.

**Conclusion:** Stump appendicitis is a rare but serious complication of appendectomy. The prevalence and incidence of stump appendicitis has been increasing in the recent years. Clinical presentation of stump appendicitis mimics symptoms and signs of acute appendicitis or acute abdomen and with a previous appendectomy. So it must be considered in the differential diagnosis of acute abdomen despite the patient's open or especially laparoscopic appendectomy history.

## Keywords:

open appendectomy, stump appendicitis, acute abdomen.

## INTRODUCTION

Stump appendicitis is the inflammation of the residual appendiceal tissue after an appendectomy. It is a rare complication with a frequency that is underreported as well as underestimated. Therefore, physicians as well

as surgeons need to be aware of this clinical entity and not to assume that previous appendectomy precludes recurrent/stump appendicitis. Failure to recognize this possibility may lead to delay in treatment and may result in complications such as perforation, abscess formation, and sepsis. Aim of article was to present case of stump appendicitis in 14-year-old girl, 1 month following laparoscopic appendectomy.

## CASE STUDY

A 14-year-old girl was admitted with a complaint of right lower quadrant pain which lasted for 24 hours with vomiting and fever. Patient had undergone laparoscopic appendectomy 1 month back and had a recovery without noted problems. Positive clinical findings included a right lower quadrant tenderness and leukocytosis i.e.  $14 \times 10^9/L$  with 78% neutrophils and CRP 125,7 mg/L. Electrolytes, urinalysis, transaminases and amylase were all in the normal range. Vital signs were normal. Plain abdominal X-ray was normal. Abdominal ultrasound and abdominal computerized tomographic scan-CT (Figure 1.) revealed inflammatory, intraperitoneal collection at the right iliac fossa (radiologically was diagnosed as an inflammatory mass with abscess dimension 41 x 21 mm). IV fluid with parenteral antibiotics was included in therapy. The presumptive preoperative diagnosis was stump appendicitis. During operation a 1,5 cm-diameter appendiceal stump was noted in the anatomical region of the appendix (Figure 2.). The appendiceal stump was resected and inverted into the cecal wall with 2-0 vicryl suture. Histopathology examination showed acute inflammation and patchy necrosis of the appendiceal stump. The post-operative course went without problems. Patient was discharged on third post-operative day.

## DISCUSSION

Stump appendicitis is the re-inflammation of the residual appendiceal tissue after an appendectomy. It represents a rare delayed complication of appendectomy which is unknown to most clinicians [1,2,3]. Appendectomy is one of the most commonly performed surgical emergencies. Claudius Amyand in 1735, performed the

first appendectomy and Reginald Fitz in 1886, described the clinical features and pathological abnormalities of appendicitis. In 1945, Rose was the first to describe stump appendicitis in two patients who had undergone appendectomy for acute appendicitis in past [1].

The appendix arises from the postero-medial wall of cecum about 3 cm below the ileocecal valve. Its variable position and subserous length, combined with acute inflammation, may result in misidentification of the appendiceal-cecal junction. Dissecting the recurrent branch of the appendiceal artery and following the teniae coli on the cecum helps in identifying the true appendicular base. Generally, an appendix stump shorter than 5 mm reduces the risk of stump appendicitis [2,3]. Moreover, the incidence of this complication seems to increase until the introduction of laparoscopic approach, probably due to absence of tactile feedback [4,5]. The time of onset ranges from 2 weeks to decades after appendectomy [6].

Incomplete appendectomy leaving a stump longer than 5 mm, severe local inflammation preventing adequate identification of the appendiceal base, retrocecal or subserosal appendix, and, last but not least, the insufficient experience of the surgeon may influence the occurrence of this condition [7-9]. Moreover some sources have suggested that the growing use of laparoscopic appendectomy may increase the frequency of stump appendicitis. This may be the result of leaving a longer stump, secondary to a smaller field of vision, lack of three-dimensional perspective, and the absence of tactile feedback [10,11]. The incidence of stump appendicitis can be minimized simply by adequately visualizing the base of the appendix and creating a stump less than 3 mm in length. Therefore, if performed properly, there is no reason why laparoscopic appendectomy should lead to a higher incidence of stump appendicitis.

Clinical features of stump appendicitis do not differ from that of acute appendicitis, even though the history of a previous appendectomy can be misleading causing a delay in diagnosis. Ultrasonography can be useful in identifying inflammatory changes. The abdominal CT is the gold standard for the diagnosis and should be performed in patients with right lower quadrant symptoms after appendectomy. It allows the recognition of retained fecolith or postoperative abscess as well as cases of stump appendicitis [1]. Stump appendicitis has a higher risk of complications with perforation being reported in nearly 70% of the cases. It is therefore imperative that patients with stump appendicitis undergo complete appendectomy as soon as possible. Stump appendicitis should be considered in any patient with a previous history of appendectomy and history of acute appendicitis. Treatment by re-surgery and complete removal of the appendix will resolve the problem.

Stump appendicitis is one of the rare delayed complications after appendectomy with the reported incidence of 1 in 50,000 cases [12]. Prompt recognition is important to lead to an early treatment, thus avoiding serious complications like wound infection, intra abdominal abscess, and intestinal perforation with peritonitis, bleeding, and adhesions with sub-acute intestinal obstructions [13].

Stump appendicitis can represent a diagnostic dilemma if the treating physician is unfamiliar with this uncommon clinical entity. Clinically, patients present with sign and symptoms mimicking appendicitis or acute abdomen along with a previous history of appendectomy as seen in our case. The presence of an appendectomy scar does not rule out the possibility of stump appendicitis [14]. The incidence and prevalence of stump appendicitis has been increasing in the recent years. It has been reported following both open and laparoscopic appendectomy [4,15]. It has been suggested that no appendicular stump longer than 3mm should be left behind [16].

The common conditions leading to stump appendicitis have been broadly classified under the anatomical and surgically related factors. One common denominator is the inappropriate identification of the appendicular base i.e appendicular-cecal junction. The anatomically related factors may be a retrocecal or subserous appendix or a duplicated appendix, a rare developmental abnormality seen in about 0.004% in appendectomy patients [17]. The surgical factors predisposing for stump appendicitis may be inadequate identification of the appendicular base because of severe local inflammation, leaving long stump due to fear of cecal injury or difficult dissection and local ulcerations due to fecoliths [18]. The stump appendicitis has been reported following open appendectomy with stump ligation, open appendectomy with stump inversion, and laparoscopic appendectomy where appendiceal stump is either closed with an endoloop or by stapling. Both the surgical techniques i.e. inversion of stump or simple ligation of stump cannot prevent the possibility of stump appendicitis [19].

Radiological evaluation by ultrasound and computed tomography (CT Scan) helps in the preoperative diagnosis of stump appendicitis [6,20]. CT scan of the abdomen is more specific than ultrasound for the accurate pre-operative diagnosis of stump appendicitis because it excludes other etiologies of acute abdomen. CT findings may be similar to those seen in acute appendicitis. They include pericecal inflammatory changes, abscess formation, fluid in the right paracolic gutter, cecal wall thickening, and an ileocecal mass. In the era of laparoscopy a diagnostic laparoscopy may prove to be the next diagnostic and therapeutic option in case of ambiguity [21].

Completion appendectomy either by open or by laparoscopic intervention is the treatment of choice for stump appendicitis [22]. Very rarely, extensive surgery such as ileocolic resection may be necessary if there is significant inflammation around the ileocecal region. It is imperative to adequately visualize the appendicular base and the ileocecal region to ensure that a stump not more than 5 mm remains after appendix removed [13,17].

## CONCLUSION

Stump appendicitis is a rare but serious complication of appendectomy. The prevalence and incidence of stump appendicitis has been increasing in the recent years. Clinical presentation of stump appendicitis mimics symptoms and signs of acute appendicitis or acute abdomen and with a previous appendectomy. So it must be considered in the differential diagnosis of acute abdomen despite the patient's open or especially laparoscopic appendectomy history. The diagnosis is often missed or delayed if the clinician is unaware of this rare clinical entity. Clinical awareness and a high level of suspicion would prevent unnecessary delay in initiating treatment thus avoiding serious complications.

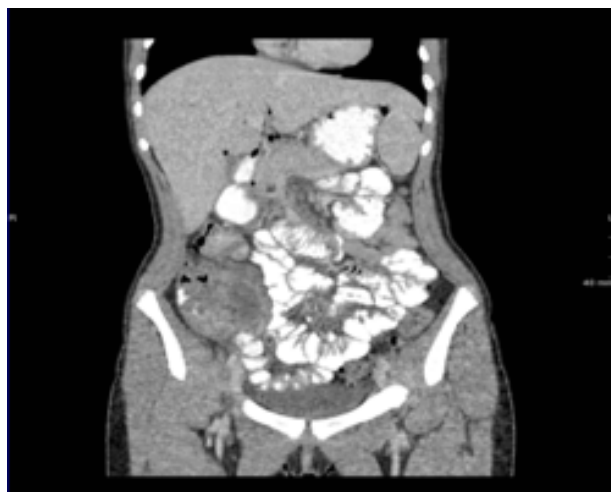**The authors declare that there is no conflict of interest.**

**Declaration of patient consent:** The authors certify that they have obtained all appropriate patient consent forms

## REFERENCES

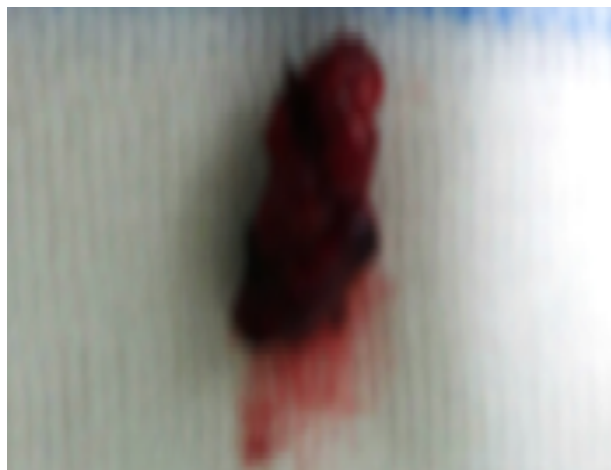
- Gupta R, Gernshiemer J, Golden J, Narra N, Haydock T: Abdominal pain secondary to stump appendicitis in a child. *J Emerg Med* 2000;18:431-433.
- Waseem M, Devas G: A child with appendicitis after appendectomy. *J Emerg Med* 2008; 34:59-61.
- Erzurum VZ, Kasirajan K, Hashmi M: Stump appendicitis: a case report. *J Laparoendosc Adv Surg Tech A* 1997; 7:389-91.
- Uludag M, Isgor A, Basak M: Stump appendicitis is a rare delayed complication of appendectomy: A case report. *World J Gastroenterol* 2006; 12:5401-5403.
- Levine CD, Aizenstein O, Wachsberg RH: Pitfalls in the CT diagnosis of appendicitis. *Br J Radiol* 2004; 77:792-9.
- Baldisserotto M, Cavazzola S, Cavazzola LT, Lopes MH, Mottin CC: Acute edematous stump appendicitis diagnosed preoperatively on sonography. *AJR* 2000:503-504.
- Aschkenasy MT, Rybicki FJ: Acute appendicitis of the appendiceal stump. *J Emerg Med*. 2005; 28:41-3.
- Simon SB, Jacqueline JC, Celia MD: Stump appendicitis af-ter open and laparoscopic appendectomies. *Am Surg*. 2012; 78:143-4.
- Kanona H, Al Samaraee A, Nice C, Bhattacharya V: Stump appendicitis: a review. *Int J Surg*. 2012; 10:425-8.
- Gasmi M, Fitouri F, Sahli S, Jemai R, Hamzaoui M: A stump appendicitis in a child: a case report. *Ital J Pediatr*. 2009; 35:35
- Patel RP, Kan JH: Stump appendicitis. *Pediatr Radiol*. 2009; 39:306.
- Liang MK, Lo HG, Marks JL: Stump appendicitis: A comprehensive review of literature. *Am Surg*. 2006;72:162-6.
- Durgun AV, Baca B, Ersoy Y, Kapan M: Stump appendicitis and generalized peritonitis due to incomplete appendectomy. *Tech Coloproctol*. 2003;7:102- 4.
- Truty MJ, Stulak JM, Utter PA, Solberg JJ, Degnim AC: Appendicitis after appendectomy. *Arch Surg*. 2008;143:413-5.
- Greenberg JJ, Esposito TJ: Appendicitis after laparoscopic appendectomy: A warning. *J Laparoendosc Surg*. 1996;6:185-7.
- Wallbridge PH: Double appendix. *Br J Surg*. 1962;50:346-7.
- Clark J, Theodorou N: Appendicitis after appendectomy. *J R Soc Med*. 2004;97:543-4.
- Mangi AA, Berger DL: Stump appendicitis. *Am Surg*. 2000;66:739-41.
- Roberts KE, Starker LF, Duffy AJ, Bell RL, Bokhari J: Stump appendicitis: A surgeon's dilemma. *JSLs*. 2011;15:373-8.
- Shin LK, Halpern D, Weston SR, Meiner EM, Katz DS: Prospective CT diagnosis of stump appendicitis. *AJR Am J Roentgenol*. 2005;184(Suppl 3):S62-4.
- Watkins BP, Kothari SN, Landercasper J: Stump appendicitis: Case report and review. *Surg Laparosc Endosc Percutan Tech*. 2004;14:167-71.
- O'Leary DP, Myers E, Coyle J, Wilson I: Case report of recurrent acute appendicitis in a residual tip. *Cases J*. 2010;3:14.

**Figure 1.**



CT scan of abdomen showing abscess in right iliac fossa dimension 41 x 21 mm

**Figure 2.**



Residual appendix after resection

