


# How many MSI-H/dMMR solid tumors could your lab be missing by using only IHC-MMR testing?



Learn about the value of performing MSI by PCR and IHC-MMR testing in parallel




[www.promega.com/CoTesting](http://www.promega.com/CoTesting)

<sup>1</sup>Dudley (2016) *Clin. Cancer Res.* **22**, 813–820.

<sup>2</sup>Funkhouser *et al.* (2012) *J. Mol. Diag.* **14**, 91–103

<sup>3</sup>Based on an internal analysis of publications comparing MSI-PCR v. IHC-dMMR in colorectal cancer from 2004–2018. Literature bundle available from Promega Medical Affairs upon request.

# Distinct genetic alterations and luminal molecular subtype in nested variant of urothelial carcinoma

Veronika Weyerer,<sup>1,\*</sup> Rebecca Weisser,<sup>1,\*</sup> Evgeny A Moskalev,<sup>1</sup>  Florian Haller,<sup>1</sup> Robert Stoehr,<sup>1</sup> Markus Eckstein,<sup>1</sup> Ulrike Zinnall,<sup>1,2</sup> Nadine T Gaisa,<sup>3</sup> Eva Compérat,<sup>4</sup> Aurel Perren,<sup>5</sup> Bastian Keck,<sup>6,7</sup> Yves Allory,<sup>8</sup> Glen Kristiansen,<sup>9</sup>  Bernd Wullich,<sup>6</sup> Abbas Agaimy,<sup>1</sup> Arndt Hartmann<sup>1</sup> & Simone Bertz<sup>1</sup> 

<sup>1</sup>Institute of Pathology, University Hospital Erlangen, Friedrich-Alexander-Universität Erlangen-Nürnberg, Erlangen, Germany, <sup>2</sup>Institute of Medical Systems Biology, Max Delbrück Center for Molecular Medicine in the Helmholtz Association, Berlin, Germany, <sup>3</sup>Department of Pathology, RWTH Aachen University, Aachen, Germany, <sup>4</sup>Department of Pathology, Pitié-Salpêtrière Hospital, UPMC, Paris, France, <sup>5</sup>Institute of Pathology, University of Bern, Bern, Switzerland, <sup>6</sup>Department of Urology and Pediatric Urology, University Hospital Erlangen, Friedrich-Alexander-Universität Erlangen-Nürnberg, Erlangen, Germany, <sup>7</sup>Private Practice for Urology, Erlangen, Germany, <sup>8</sup>Service de Pathologie, CHU Henri Mondor, Créteil, France, and <sup>9</sup>Institute of Pathology, University Hospital Bonn, Bonn, Germany

Date of submission 31 May 2019

Accepted for publication 23 July 2019

Published online Article Accepted 26 July 2019

Weyerer V, Weisser R, Moskalev E A, Haller F, Stoehr R, Eckstein M, Zinnall U, Gaisa N T, Compérat E, Perren A, Keck B, Allory Y, Kristiansen G, Wullich B, Agaimy A, Hartmann A & Bertz S (2019) *Histopathology*. <https://doi.org/10.1111/his.13958>

## Distinct genetic alterations and luminal molecular subtype in nested variant of urothelial carcinoma

**Aims:** Nested variant of urothelial carcinoma (NVUC) is rare, and only a few small series exist. Molecular characteristics and the classifying marker profile as well as therapeutic targets of this specific variant are mostly unknown. The aim of this study was to characterise NVUC at the molecular level in one of the largest cohorts to date. In addition, we applied an immunohistochemical marker panel in order to define the molecular subtype.

**Methods and results:** Sixty NVUC cases were collected from different departments. *TERT* promoter mutation analysis was carried out in all samples using SNaP-shot analysis. Targeted sequencing of 48 cancer-related genes by next-generation sequencing (NGS) analysis was performed in a subset of 26 cases.

Immunohistochemical markers CD44, CK5, CK14, EGFR, p63, FOXA1, GATA3, CD24 and CK20 were used to elucidate the molecular subtype. A total of 62.5% of NVUC cases harboured a mutation of the *TERT* promoter. Additionally, *TP53*, *JAK3* and *CTNGB1* were among the most frequently mutated genes identified by NGS analysis. Subtyping revealed that all NVUC express luminal markers such as CD24, FOXA1, GATA3 and CK20.

**Conclusions:** In summary, NVUC belong to the luminal molecular subtype. Moreover, a subset of NVUC seems to be characterised by mutations of the Wnt and inflammatory pathways, including *JAK3* mutations, indicating a different biological background compared to conventional urothelial bladder cancer.

**Keywords:** molecular subtype, nested variant, target sequencing, urothelial bladder cancer

Address for correspondence: S Bertz, Krankenhausstrasse 8–10 91054 Erlangen, Germany. e-mail: [simone.bertz@uk-erlangen.de](mailto:simone.bertz@uk-erlangen.de)

\*These authors contributed equally to this study.

© 2019 The Authors. *Histopathology* published by John Wiley & Sons Ltd.

This is an open access article under the terms of the Creative Commons Attribution-NonCommercial-NoDerivs License, which permits use and distribution in any medium, provided the original work is properly cited, the use is non-commercial and no modifications or adaptations are made.

## Introduction

Divergent differentiation resulting in distinct histomorphological features is characteristic of urothelial bladder cancer (UBC). In addition to frequent

squamous and glandular differentiation, several rare variants of urothelial differentiation are described in the 2016 World Health Organisation (WHO) classification, the nested variant (NVUC) being one of the most common<sup>1,2</sup> Since the first description of NVUC by Talbert and Young in 1989, case reports as well as very few studies with more than 30 cases have mostly been reported.<sup>2–5</sup> Histologically, small- to medium-sized, sometimes confluent nests with occasional central lumina and small tubules surrounded by a frequently myxoid stroma are characteristic. Minimal atypia and low to absent mitotic activity, especially in the superficial parts, result in the often-cited ‘deceptively bland’ appearance of NVUC, which may be hard to differentiate from benign mimics, such as hyperplasia of Von Brunn’s nests and cystitis cystica/glandularis. Diagnosis may be ensured by detection of pleomorphic cells in the deeper parts of the tumour and/or obvious invasive growth, especially in tumours infiltrating the detrusor muscle.<sup>1,6</sup> Moreover, TERT promoter mutation analysis has been reported as a helpful tool to discriminate between benign and malignant lesions with nested morphology.<sup>7</sup>

Despite its bland morphology, clinical behaviour and cancer-specific survival rates of NVUC are similar to high-grade conventional UBC.<sup>4,6,8,9</sup> Therefore, aggressive treatment including multimodal therapy with platinum-based chemotherapy is recommended.<sup>5,10</sup> Notably, there are no studies addressing molecular therapeutic targets of NVUC, and data on immunohistochemical characteristics are limited to classical markers such as p53.<sup>4,5,8</sup>

In this study we aimed at further characterisation of NVUC using targeted gene analysis of selected cancer-associated genes with a commercially available sequencing panel and by SNaPshot analysis. Additionally, an immunohistochemical marker panel was applied to classify the molecular subtype according to current molecular taxonomy proposals in the literature.<sup>11–13</sup>

## Materials and methods

### STUDY COHORT

We collected archival formalin-fixed paraffin-embedded tissue (FFPE) from transurethral resections and cystectomies of 60 NVUC from our institutional files and cooperating departments. NVUC cases included tumours with a classical NVUC component or a classical NVUC component combined with < 10% large nested variant urothelial carcinoma (LNUC). Pure LNUC were excluded from the study. Tumours with

microcystic morphology were also included if combined with a major classical NVUC component. Diagnosis was confirmed on haematoxylin and eosin-stained slides by two experienced urological pathologists (A.H., S.B.) and included semiquantitative assessment of the percentage of variant morphologies. Tumour grading was performed according to current recommendations using both the 1973 and 2016 WHO classifications, which require documentation of the worst grade in any of the tumour components, regardless of the low nuclear grade of classical NVUC areas.<sup>1</sup> Institutional Review Board approval (University Hospital Erlangen) was obtained for molecular analysis on archival material. Clinicopathological characteristics of NVUC cases are shown in Table 1 and representative images are shown in Figure 1. As the cases in our cohort were collected from several institutions, no information regarding other clinical variables is available.

### DNA ISOLATION

Tumour tissue from the NVUC component was manually microdissected from previously marked areas to achieve >80% NVUC purity. DNA isolation was performed using the DNA preparation kit (Maxwell<sup>®</sup> 16 System; Promega, Mannheim, Germany), according to the manufacturer’s instructions. Only cases with a sufficient amount of tumour and high-quality DNA were further processed.

### TERT SEQUENCING

Mutation analysis of the *TERT* promoter was performed as described recently.<sup>14</sup> In brief, SNaPshot analysis of the *TERT* core promoter was carried out using an ABI Prism 3500 Genetic Analyzer and the Snapshot-Multiplex-Kit (Applied Biosystems, Foster City, CA, USA), according to the manufacturer’s instructions. SNaPshot assays were used that addressed hotspot mutations at positions –146, –124 and –57 base pairs (bp) of the *TERT* promoter. All primers and reaction conditions are described elsewhere in detail.<sup>14</sup>

### NEXT-GENERATION SEQUENCING

Library preparation for the commercially available TruSeq Amplicon Cancer Panel (Illumina, San Diego, CA, USA) representing 48 frequently relevant cancer related genes (Table S1) was carried out according to the manufacturer’s recommendations. A total of 60 libraries were sequenced in four separate runs

**Table 1.** Study characteristics of the nested cohort

	NVUC, <i>n</i> (%)	
	Sequenced cases	All analysed cases
Total number of cases	26	60
Gender		
Male	19 (86.4)	43 (76.8)
Female	3 (13.6)	13 (23.2)
Not available	4	4
Stage		
pT1	2 (7.7)	15 (25.0)
≥pT2	24 (92.3)	45 (75.0)
Grading WHO 1973*		
G2	4 (15.4)	13 (21.2)
G3	22 (84.6)	47 (78.8)
Grading WHO 2016*		
High-grade	26 (100.0)	60 (100.0)
Nodal status		
pN0	8 (30.8)	13 (21.2)
pN+	4 (15.4)	10 (16.7)
pNx	14 (53.8)	37 (62.1)
Lymphatic invasion		
L0	13 (50.0)	35 (58.3)
L1	9 (34.6)	22 (36.7)
Lx	4 (15.4)	3 (5.0)
Variant purity		
Pure	8 (30.8)	24 (40.0)
Mixed		
Proportion of NVUC ≤ 50%	15 (57.7)	16 (26.7)
Proportion of NVUC > 50%	3 (11.5)	20 (33.3)

NVUC, Nested variant of urothelial carcinoma; WHO, World Health Organisation.

\*Tumour grading was performed according to the WHO classifications 1973 and 2016, documenting the worst grade in any of the tumour components, regardless of the low nuclear grade of classical NVUC areas.

[Illumina; Miseq System, mean coverage 9152× (±4385×; range = 1652–23 788×)]. Only non-synonymous variants with an allele frequency >10% and

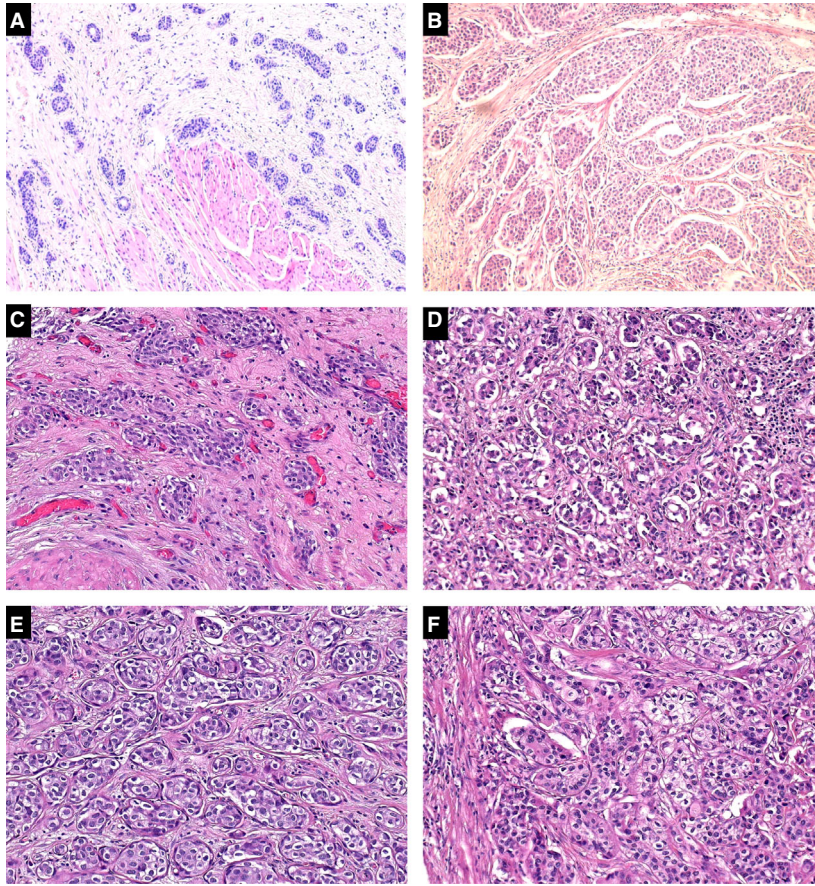
coverage >200× were reported. One exception to this rule was accepted in one case with *CTNNB1* mutation (allele frequency = 8.5%) due to confirmed nuclear β-catenin expression by immunohistochemistry supporting the observed mutation.

#### JAK3 SEQUENCING

Validation of the p.V722I of *JAK3* was performed via pyrosequencing. A 53 bp region was amplified using the multiplex polymerase chain reaction (PCR)-kit, according to the manufacturer's instructions (Qiagen, Hilden, Germany) and the following primers: forward: 5'-cggctcgggaagtgttagtg-3' and reverse: 5'-ag-gatccaggcactgatg-3' (antisense conjugated to biotin). The cycling conditions were as follows: a single cycle of denaturation at 94°C for 5 min, 45 cycles at 94°C for 1 min, 65°C for 1 min and 72°C for 1 min and a final 10-min extension at 72°C. For pyrosequencing (PyroMark Q24; Qiagen) single-stranded DNA was prepared from biotinylated PCR product with streptavidin-coated sepharose and the sequencing primer using the PSQ Vacuum Prep Tool (Qiagen). The samples were then measured with the PyroMark™ Q24 and analysed with the appropriate software (both from Qiagen).

#### IMMUNOHISTOCHEMICAL ANALYSIS

A tissue microarray (TMA) of the cohort was constructed; one tissue core was punched per each NVUC component and a marker panel was chosen to further classify the tumours following current molecular taxonomy proposals: CK5, CK14, CD44, p63 and EGFR were previously identified and used as so-called 'basal markers'.<sup>15</sup> CK5, FOXA1 and GATA3 were predicted to discriminate between luminal and basal subgroups by a consensus conference and other studies. CK20 and CD24 are predominately represented among luminal tumours.<sup>15,16</sup> Apart from a few exceptions (see below), immunohistochemistry (IHC) was performed on a BenchMark ULTRA Automated IHC/ISH Slide Staining System (Ventana®; Ventana Medical Systems, Inc., Tucson, AZ, USA) on TMA slides (Table 2). Manual staining was performed for FOXA1 (polyclonal, 1:1000; Abcam, Cambridge, UK, ab23738). CD24 IHC was performed automatically (dilution 1:5; SWA-11; Ventana Medical Systems, Inc.) by our cooperation partners at the Institute of Pathology, University Hospital Bonn, Germany. IHC was considered positive for β-catenin in the case of any nuclear staining. IHC positivity for p53 was defined in tumours with strong nuclear overexpression in at least 10% of tumour cells



**Figure 1.** A–F, Nested variant urothelial carcinoma: typical histomorphology showing small nests with occasional central lumina and bland cytology (H&E, magnification: x100 and x200).

or complete loss of p53 expression ('null phenotype').<sup>17</sup> All other immunohistochemical markers were analysed according to the immunoreactive score (IRS) by Remmele and Stegner resulting from multiplication of the percentage score (0 = 0, 1 = <10%, 2 = 10–50%, 3 = 51–80%, 4 = >80%) and intensity score (assessment of the staining intensity of positive cells: 0 = negative, 1 = weak, 2 = intermediate, 3 = strong).<sup>18</sup>

#### STATISTICAL ANALYSIS

The heatmap.2 function of the gplots package within the R version 3.2.3 statistical environment was used for non-hierarchical clustering based on immunoreactive scores of the evaluated markers.

## Results

#### HISTOPATHOLOGY

Pure NVUC was found in 24 of 60 cases. NVUC cases with mixed morphologies (36 of 60 cases) showed most frequently additional conventional UBC

**Table 2.** Antibodies used for immunohistochemistry

Antibody	Company	Clone	Dilution
Catenin, beta	BD	14/beta-catenin	1:50
p53	Dako	DO-7	1:50
CD44	Dako	DF1485	1:40
CK20	Dako	Ks20.8	1:50
CK5	Zytomed	XM26	1:50
CK14	Ventana	SP53	Ready-to-use
EGFR	Novocastra	EGFR25	1:50
GATA3	DCS	L50-823	Ready-to-use
p63	DCS	SFI-6	1:100

or micropapillary urothelial carcinoma, but also in one case sarcomatoid, plasmacytoid, clear cell, squamous and glandular UC morphological features, respectively. Eighteen of 26 nested cases used for NGS analysis were combined either with conventional UBC (11 of 26), minor (~5%) LNUC (two of

26), micropapillary (three of 26), minor plasmacytoid (one of 26) or exophytic papillary (three of 26) components.

#### TARGETED MUTATIONAL ANALYSIS

*TERT* promoter mutations were identified in 62.5% of all NVUC cases and were the most frequently observed mutations (Table 3). Of 26 tumours that were analysed by NGS, 11 cases were not mutated in any of the interrogated cancer-related genes. Among the mutations observed, *TP53* and *JAK3* were each altered in five of 26 (19%), *CTNNB1* in three of 26 (11.5%) and *PIK3CA* in two of 26 (7.7%) cases. Mutation of *FGFR2*, *FGFR3*, *PTEN*, *APC* and *KRAS* were each detected in one of 26 (3.8%) cases. No differences between mixed and pure cases were detected regarding the distribution of genetic alterations. All mutations analysed by NGS are listed in detail in Table 4.

*TP53* alterations were among the most frequent events in NVUC. Four of five *TP53* altered cases displayed p53 overexpression (Figure 2A). The remaining case showed a *TP53* frameshift mutation and weak nuclear immunoreactivity (~5%). *JAK3* mutations ( $n = 5$ ) were as frequent as *TP53* alterations, all affecting the p.Val722Ile sites. Using pyrosequencing analysis on the whole cohort, all *JAK3* mutations detected by NGS were confirmed. However, among the remaining 34 cases no further *JAK3*-mutated case could be observed (Table 3). Moreover, no differences between the various mutated tumours concerning the clinicopathological characteristics were observed (data not shown).

**Table 3.** *TERT* and *JAK3* mutational analysis

	NVUC cohort, $n$ (%)
Total number of cases	60
<i>TERT</i> mutational status	
Wild-type	18 (37.5)
Mutated	30 (62.5)
Not available	12
<i>JAK3</i> mutational status	
Wild-type	44 (89.8)
Mutated	5 (10.2)
Not available	11

NVUC, Nested variant of urothelial carcinoma.

Wnt pathway-associated genes were mutated in four of 26 (15.4%) cases (one *APC*, three *CTNNB1* – mutually exclusive). All *CTNNB1* mutations were typical hotspot mutations resulting in nuclear  $\beta$ -catenin accumulation by immunostaining (Figure 2B). One case harboured an inactivating *APC* mutation with truncation protein, which also led to nuclear  $\beta$ -catenin accumulation.

#### MOLECULAR SUBTYPE IDENTIFIED BY IMMUNOHISTOCHEMICAL MARKERS

Differential expression of basal and luminal markers by immunohistochemistry is shown in Table 5. Luminal markers CD24, FOXA1, GATA3 and CK20 were mostly expressed at a high level with frequencies up to 92.7%, whereas most cases were negative for basal markers CD44, CK5, CK14 and EGFR (high expression frequencies between 26.4% and 38.9%). P63 was expressed in almost all cases, regardless of the distribution of other markers. No differences between mixed and pure cases were observed.

Figure 3 illustrates the expression levels, and non-hierarchical clustering determined the similarity of the used luminal and basal markers. In some cases, with additional expression of basal markers, histomorphological re-evaluation showed frequent tubular differentiation with staining of the basal cell layer only.

## Discussion

Despite the reported aggressive behaviour of NVUC, their management is mainly based on radical cystectomy and peri-operative chemotherapy.<sup>5,10,19</sup> However, response to neoadjuvant chemotherapy seems to be less efficient in tumours with variant histology, and detection of potentially targetable molecular alterations may be helpful.<sup>20</sup> Therefore, we performed NGS-based molecular analysis of one of the largest cohorts, up to the present time, of NVUC, in order to find pathogenic alterations and potential therapeutic targets of this rare histological variant. In addition, we used immunohistochemical markers in order to define the molecular subtype.

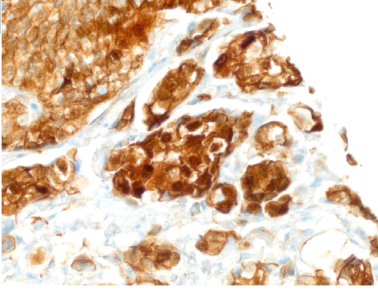
Molecular changes were not significantly different between tumours with pure nested and mixed morphology. *TERT* promoter mutations have been reported in approximately 79% conventional UBC and have been discussed as an early event in urothelial carcinogenesis.<sup>21</sup> Zhong *et al.* found *TERT* promoter mutation in 17 of 20 NVUC, but none of its benign mimickers were analysed, thus

**Table 4.** Targeted sequencing of 26 NVUC

Patient	Gene	Allele frequency (%)	Mutation	Protein variant	Location	Function
1	<i>JAK3, FGFR2</i>	63.9/34.8	c.2164G>A/c.764G>A	p.Val722Ile/p.Arg255Gln	Exonic	Missense
2	<i>PIK3CA, CTNNB1</i>	19.9/32.8	c.3012G>A/c.134C>T	p.Met1004Ile/p.Ser45Phe	Exonic	Missense
3	<i>CTNNB1</i>	8.5	c.98C>T	p.Ser33Phe	Exonic	Missense
4	No mutation identified					
5	No mutation identified					
6	No mutation identified					
7	No mutation identified					
8	<i>JAK3</i>	38.1	c.2164G>A	p.Val722Ile	Exonic	Missense
9	No mutation identified					
10	<i>JAK3</i>	55.3	c.2164G>A	p.Val722Ile	Exonic	Missense
11	No mutation identified					
12	<i>PTEN</i>	17.9	c.928G>A	p.Asp310Asn	Exonic	Missense
13	No mutation identified					
14	<i>TP53</i>	42.1	c.529_546del18	p.Pro177_Cys182del	Exonic	Deletion
15	<i>TP53</i>	25.0	c.380C>T	p.Ser127Phe	Exonic	Missense
16	No mutation identified					
17	<i>TP53, CTNNB1</i>	28.5/22.4	c.818G>A/c.133T>C	p.Arg273His/p.Ser45Pro	Exonic	Missense
18	<i>JAK3</i>	54.3/49.2	c.2164G>A	p.Val722Ile	Exonic	Missense
19	<i>PIK3CA</i>	17.8	c.1633G>A	p.Glu545Lys	Exonic	Missense
20	<i>TP53</i>	18.0	c.404G>T	p.Cys135Phe	Exonic	Missense
21	No mutation identified					
22	<i>FGFR3</i>	21.1	c.746C>G	p.Ser249Cys	Exonic	Missense
23	No mutation identified					
24	<i>KRAS</i>	31.2	c.35G>T	p.Gly12Val	Exonic	Missense
25	No mutation identified					
26	<i>TP53, JAK3, APC, FGFR2</i>	21.8/56.6/ 22.0/19.2	c.490_491insGT/ c.2164G>A/c.2673_2685 del13/c.778G>A	p.Lys164SerfsTer7/ p.Val722Ile/p.Glu892 ProfsTer20/p.Ala260Thr	Exonic	Insertion, deletion, missense

presenting a useful tool for distinguishing benign and malignant lesions.<sup>7</sup> In our cohort, we identified 62.5% *TERT* promoter mutated tumours pointing to the fact that irrespective of the histomorphological variant, *TERT* promoter mutation may occur early during tumour development and supporting cancer diagnosis, especially in non-muscle-invasive lesions.

Moreover, we found a (relatively) high frequency of *TP53* mutations (19.2%) in our NVUC cohort. Compared to our results, the recent analysis of 412 MIBC tumours in the TCGA cohort reported *TP53* mutations in 48%.<sup>12</sup> Dysregulation of *TP53* is known to be important for the development of aggressive types of bladder tumours such as MIBC, and also apparently in a subset of NVUC.<sup>22</sup>

A	NVUC n (%)	B
Total number of cases	26	
TP53 expression		
Aberrant pattern	4	
Overexpression	4 (19.0)	
Loss	0	
Wild-type pattern	17 (81.0)	
Not available	5	
β-Catenin expression		
Positive	4 (15.4)	
Negative	22 (84.6)	

NVUC: Nested variant of urothelial carcinoma

**Figure 2.** A, Results of immunohistochemical staining of TP53 and β-catenin of 26 analysed nested variant of urothelial carcinoma (NVUC) cases. B, One representative case of nested variant urothelial carcinoma harbouring a *CTNNB1* mutation resulting in nuclear β-catenin accumulation by immunostaining (β-catenin, magnification: x400).

Next-generation sequencing analysis and pyrosequencing revealed *JAK3* mutations in five of 52 analysed cases. All *JAK3* mutations in our cohort were located on p.Val722Ile and were validated by pyrosequencing. *JAK3* is a tyrosine protein kinase, usually expressed on haematopoietic cells (neutrophils, natural killer (NK) and T cells).<sup>23</sup> The p.Val722Ile mutation has been associated with a pseudo kinase domain formation resulting in activation of the *JAK3/STAT3* pathway. This nucleotide polymorphism (rs3213409) has been described with a minor allele frequency of 0.0036 in the global population.<sup>24</sup> *JAK3* deregulation by activating mutations confers an invasive growth advantage in extranodal nasal-type NK cell lymphoma.<sup>25</sup> Compared to conventional UBC, only three (1.3%) *JAK3*-mutated cases, albeit located on sites other than p.Val722Ile, were included in the TCGA cohort.<sup>12</sup> However, none of the three TCGA cases showed typical nested-variant morphology when re-analysing the representative uploaded official images.<sup>26</sup> There is an ongoing clinical trial with a *JAK3* inhibitor (CP690550), and among lung cancer patients with *JAK3* activation a long-term benefit of programmed death ligand 1 (PD-L1) blockade has been described, both indicating a potential therapeutic option in this subset of NVUC.<sup>27</sup>

The Wnt-signalling pathway plays an important role in several cancers, especially colorectal cancer.<sup>28</sup> In UBC, its functional role is controversially discussed. *APC*-promoter hypermethylation and proteins connected to the Wnt/β-catenin pathway have been associated with UBC progression.<sup>29,30</sup> Accordingly, an association of *APC* alterations or β-catenin accumulation with higher frequencies of lymph node metastasis and shorter disease-free and disease-specific survival has been described in MIBC after surgery and adjuvant chemotherapy.<sup>31</sup> In UBC there are considerable

differences regarding the reported frequencies (0–16%) for genetic alterations [mostly missense mutations, frameshift deletions and loss of heterozygosity (LOH)] of *APC* and *CTNNB1*, both responsible for β-catenin deregulation and mutually exclusive.<sup>28,31,32</sup> Five per cent of *CTNNB1* as well as eight per cent of *APC* altered tumours were detected in the TCGA cohort.<sup>12</sup> In our study, compared to conventional UBC, NGS analysis revealed *CTNNB1* and *APC* mutations at a relatively high frequency of four of 26 (15%) tested cases, all confirmed by nuclear β-catenin accumulation determined by immunohistochemistry. In summary, our findings support a potential role of the Wnt pathway in the development of a subset of NVUC, and a link between specific pathway alterations and histomorphological changes may exist.

Few alterations of receptor tyrosine kinases (RTKs) were identified in NVUC. Specifically, compared to conventional UBC (reported frequencies in the TCGA cohort = 22%) we found *PIK3CA* mutations in 7.7% NVUC.<sup>12</sup> The *PIK3CA* oncogene encodes the catalytic subunit of phosphatidylinositol 3-kinase involved in cell growth and differentiation.<sup>33,34</sup> *PIK3CA* mutations may indicate response to PI3K-, mTOR- and Akt-inhibitors.<sup>33</sup> Mutations in other downstream signalling proteins of the PI3K and MAPK pathways were only observed in two tested NVUC presenting with a *KRAS* or *PTEN* mutation.<sup>34</sup>

*FGFR3* mutations can be observed in the majority of non-muscle invasive bladder cancers (NMIBC), but also in approximately 20% of muscle-invasive bladder cancers (frequency within the TCGA cohort 14%).<sup>12</sup> We found the most common activating *FGFR3* p.Ser249Cys mutation in a single NVUC case of our cohort.<sup>12</sup> To summarise, compared to conventional UBC, especially NMIBC, *FGFR3* mutations do not seem to play a major role in this specific histological variant.



**Table 5.** Immunohistochemical markers for molecular subtyping in nested variant of urothelial carcinoma

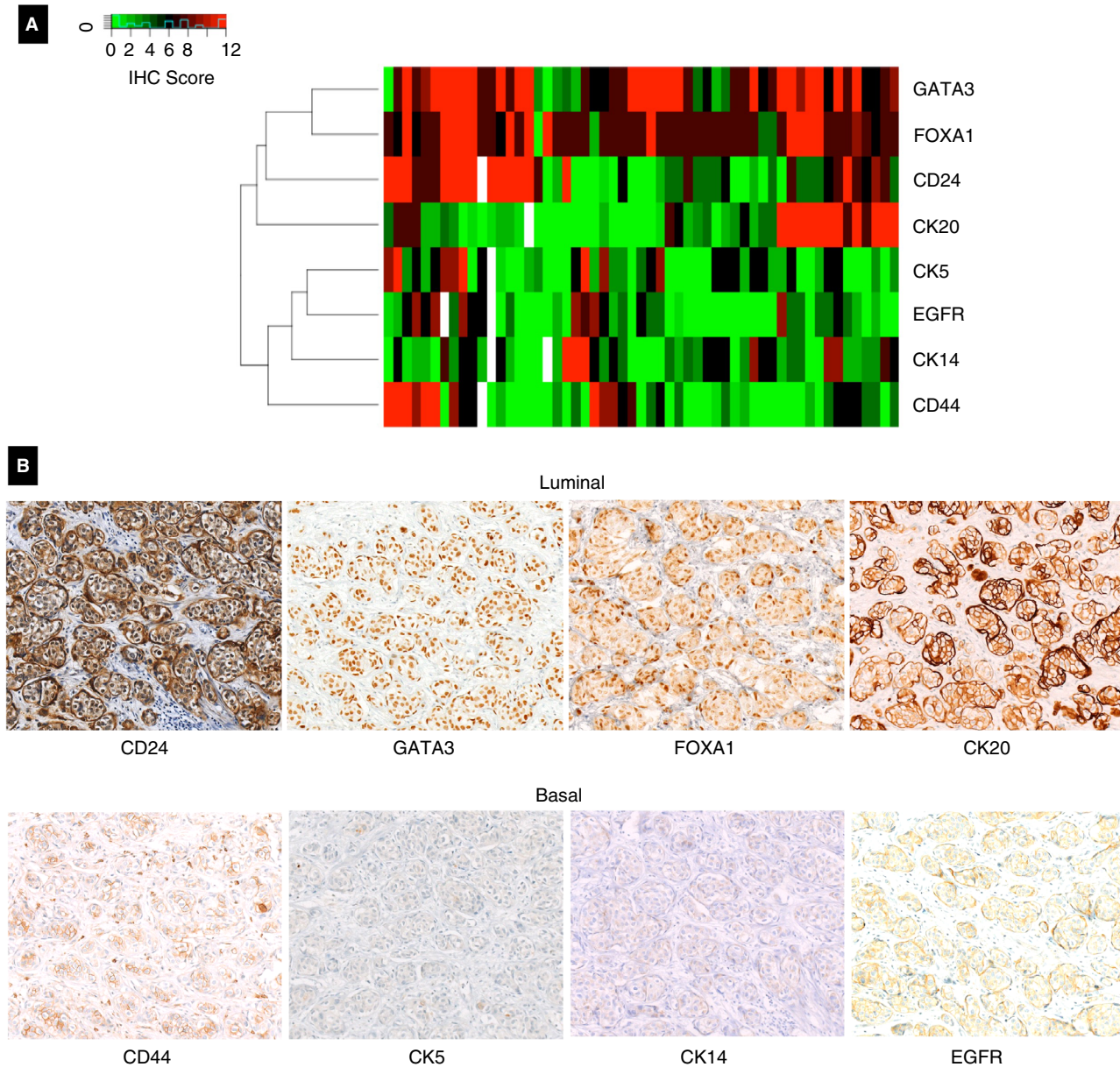
	NVUC cohort, <i>n</i> (%)
Total number of cases	60
Basal markers	
CD44	
Negative	22 (40.7)
Weak	14 (25.9)
Strong	18 (33.3)
Not available	6
CK5	
Negative	18 (33.3)
Weak	15 (27.8)
Strong	21 (38.9)
Not available	6
p63	
Negative	3 (5.7)
Weak	10 (18.9)
Strong	40 (75.5)
Not available	7
EGFR	
Negative	22 (41.5)
Weak	17 (32.1)
Strong	14 (26.4)
Not available	7
CK14	
Negative	12 (22.6)
Weak	21 (39.6)
Strong	20 (37.7)
Not available	7
Luminal markers	
CK20	
Negative	15 (27.8)
Weak	20 (37.0)
Strong	19 (35.2)
Not available	6

**Table 5.** (Continued)

	NVUC cohort, <i>n</i> (%)
GATA3	
Negative	2 (3.6)
Weak	7 (12.7)
Strong	46 (83.6)
Not available	5
FOXA1	
Negative	1 (1.8)
Weak	3 (5.5)
Strong	51 (92.7)
Not available	5
CD24	
Negative	12 (22.2)
Weak	14 (25.9)
Strong	28 (51.9)
Not available	6

NVUC, Nested variant of urothelial carcinoma.

In recent years, large-scale transcriptomic profiling studies revealed differential clusters of urothelial carcinomas, providing a relatively good correlation with the clinical behaviour of UBC.<sup>15</sup> Moreover, consensus meetings tried to translate the results gained from mRNA clustering into distinct groups, which can be roughly assigned to one of the two main subgroups of basal and luminal tumours by application of immunohistochemistry. Most reports propose CK5/CK14 as basal markers, whereas FOXA1 and GATA3 are considered luminal markers.<sup>16,35</sup> In our study, most NVUC showed an expression of luminal markers, whereas basal markers were rarely expressed. These findings are in line with three publications which categorised variant tumours (including three and seven NVUC) as luminal tumours.<sup>35–37</sup> In contrast, there is also one study classifying nested tumours to the basal subgroup; however, in this study the case number was also low ( $n = 14$ ) and immunohistochemistry was restricted to basal markers only, and therefore may not provide a comprehensive picture of this specific variant.<sup>38</sup> Among the basal markers we applied p63, which is routinely used as a basal marker in different organs (e.g. parotid gland, prostate and breast). P63 was expressed in most NVUC cases, limited to the basal lining of



**Figure 3.** A, Heatmap presenting immunohistochemistry results for luminal and basal markers. Each column represents one tissue microarray (TMA) spot; white fields represent non-available TMA spots; red fields represent high immunoreactive score (IRS) scores; green fields represent low IRS scores. B, Representative images of the different used immunohistochemical markers (Magnification:  $\times 200$ ).

tubular tumour structures, reminiscent of the basal/luminal staining pattern frequently found in (benign) salivary gland tumours. Due to these characteristics, we did not include p63 in the heatmap analysis. Moreover, p63 is commonly expressed in the majority of urothelial tumours, regardless of the grade of differentiation or molecular subtype, hence it is not deemed appropriate for molecular subtyping in urothelial carcinomas.<sup>39</sup> Of course, the utilised limited marker panel has its restrictions: Kamoun *et al.*

presented in their draft the 2018 consensus molecular classification with six different luminal subtypes based on RNA expression data.<sup>40</sup> However, with the IHC markers chosen for this study, and as translation and simplification in terms of a consensus IHC panel is still pending, we were not able to subcategorise the luminal subtype of our cohort according to the mentioned RNA expression-based proposal.

Other limitations of our study are the restricted number of explored target genes by NGS analysis as

well as the low number of sequenced NVUC. Furthermore, as most cases investigated were consultation cases, unfortunately no follow-up were data available.

In summary, this study investigated the largest cohort, to our knowledge, of NVUC to date and aimed to identify the mutational and molecular backgrounds of this rare UC variant. NVUC seems to be characterised by a high frequency of *TERT* mutations and low frequency of mutations in *FGFR3* and the mTOR, MAPK and PIK3 pathways. Mutations of Wnt and inflammatory pathways, including *JAK3* mutations, may indicate a differential mutational landscape of this specific histomorphological variant compared to conventional UBC. Moreover, we were able to assign NVUC to the luminal subtype of UC. Our findings may be of significance in understanding the pathogenesis of this rare variant and may guide further diagnostic, prognostic and therapeutic applications.

## Acknowledgements

We thank Christa Winkelmann, Verena Popp, Natascha Leicht, Rudolf Jung, Claudia Schmied and Claudia Giedl for excellent technical support. This study received no funding.

## Conflict of interest

The authors declare that they have no conflicts of interest.

## References

- Humphrey PA, Moch H, Cubilla AL, Ulbright TM, Reuter VE. The 2016 WHO classification of tumours of the urinary system and male genital organs – Part B: prostate and bladder tumours. *Eur. Urol.* 2016; **70**: 106–119.
- Lopez-Beltran A, Cheng L. Histologic variants of urothelial carcinoma: differential diagnosis and clinical implications. *Hum. Pathol.* 2006; **37**: 1371–1388.
- Talbert ML, Young RH. Carcinomas of the urinary bladder with deceptively benign-appearing foci. A report of three cases. *Am. J. Surg. Pathol.* 1989; **13**: 374–381.
- Beltran AL, Cheng L, Montironi R *et al.* Clinicopathological characteristics and outcome of nested carcinoma of the urinary bladder. *Virchows Arch.* 2014; **465**: 199–205.
- Wasco MJ, Daignault S, Bradley D, Shah RB. Nested variant of urothelial carcinoma: a clinicopathologic and immunohistochemical study of 30 pure and mixed cases. *Hum. Pathol.* 2010; **41**: 163–171.
- Murphy WM, Deana DG. The nested variant of transitional cell carcinoma: a neoplasm resembling proliferation of Brunn's nests. *Mod. Pathol.* 1992; **5**: 240–243.
- Zhong M, Tian W, Zhuge J *et al.* Distinguishing nested variants of urothelial carcinoma from benign mimickers by *TERT* promoter mutation. *Am. J. Surg. Pathol.* 2015; **39**: 127–131.
- Linder BJ, Frank I, Chevillet JC *et al.* Outcomes following radical cystectomy for nested variant of urothelial carcinoma: a matched cohort analysis. *J. Urol.* 2013; **189**: 1670–1675.
- Zucchi A, Costantini E. 'Nested type' bladder cancer: myth or reality? *Urol. Int.* 2018; **100**: 491–492.
- Lin O, Cardillo M, Dalbagni G, Linkov I, Hutchinson B, Reuter VE. Nested variant of urothelial carcinoma: a clinicopathologic and immunohistochemical study of 12 cases. *Mod. Pathol.* 2003; **16**: 1289–1298.
- Sjodahl G, Eriksson P, Liedberg F, Hoglund M. Molecular classification of urothelial carcinoma: global mRNA classification versus tumour-cell phenotype classification. *J. Pathol.* 2017; **242**: 113–125.
- Robertson AG, Kim J, Al-Ahmadie H *et al.* Comprehensive molecular characterization of muscle-invasive bladder cancer. *Cell* 2017; **171**: 540–556.
- Dadhania V, Zhang M, Zhang L *et al.* Meta-analysis of the luminal and basal subtypes of bladder cancer and the identification of signature immunohistochemical markers for clinical use. *EBioMedicine* 2016; **12**: 105–117.
- Giedl J, Rogler A, Wild A *et al.* *TERT* core promoter mutations in early-onset bladder cancer. *J. Cancer* 2016; **7**: 915–920.
- McConkey DJ, Choi W. Molecular subtypes of bladder cancer. *Curr. Oncol Rep.* 2018; **20**: 77.
- Lerner SP, McConkey DJ, Hoadley KA *et al.* Bladder cancer molecular taxonomy: summary from a Consensus Meeting. *Bladder Cancer* 2016; **2**: 37–47.
- Bertz S, Otto W, Denzinger S *et al.* Combination of CK20 and Ki-67 immunostaining analysis predicts recurrence, progression, and cancer-specific survival in pT1 urothelial bladder cancer. *Eur. Urol.* 2014; **65**: 218–226.
- Remmele W, Stegner HE. [Recommendation for uniform definition of an immunoreactive score (IRS) for immunohistochemical estrogen receptor detection (ER-ICA) in breast cancer tissue]. *Pathologe* 1987; **8**: 138–140.
- Kamat AM, Dinney CP, Gee JR *et al.* Micropapillary bladder cancer: a review of the University of Texas M. D. Anderson Cancer Center experience with 100 consecutive patients. *Cancer* 2007; **110**: 62–67.
- Pokuri VK, Syed JR, Yang Z *et al.* Predictors of complete pathologic response (pT0) to neoadjuvant chemotherapy in muscle-invasive bladder carcinoma. *Clin. Genitourin. Cancer* 2016; **14**: e59–e65.
- Allory Y, Beukers W, Sagrera A *et al.* Telomerase reverse transcriptase promoter mutations in bladder cancer: high frequency across stages, detection in urine, and lack of association with outcome. *Eur. Urol.* 2014; **65**: 360–366.
- Glaser AP, Fantini D, Shilatfard A, Schaeffer EM, Meeks JJ. The evolving genomic landscape of urothelial carcinoma. *Nat. Rev. Urol.* 2017; **14**: 215–229.
- Johnston JA, Kawamura M, Kirken RA *et al.* Phosphorylation and activation of the Jak-3 Janus kinase in response to interleukin-2. *Nature* 1994; **370**: 151–153.
- <https://www.ncbi.nlm.nih.gov/snp/?term=rs3213409> (accessed 3 April 2019).
- Boucekhoua A, Scourzic L, de Wever O *et al.* *JAK3* deregulation by activating mutations confers invasive growth advantage in extranodal nasal-type natural killer cell lymphoma. *Leukemia* 2014; **28**: 338–348.
- <http://www.cbiportal.org> (accessed 20 June 2019).

27. Van Allen EM, Golay HG, Liu Y *et al.* Long-term benefit of PD-L1 blockade in lung cancer associated with JAK3 activation. *Cancer Immunol. Res.* 2015; **3**: 855–863.
28. Polakis P. Wnt signaling and cancer. *Genes Dev.* 2000; **14**: 1837–1851.
29. Yates DR, Rehman I, Abbod MF *et al.* Promoter hypermethylation identifies progression risk in bladder cancer. *Clin. Cancer Res.* 2007; **13**: 2046–2053.
30. Stoehr R, Wissmann C, Suzuki H *et al.* Deletions of chromosome 8p and loss of sFRP1 expression are progression markers of papillary bladder cancer. *Lab. Invest.* 2004; **84**: 465–478.
31. Kastiris E, Murray S, Kyriakou F *et al.* Somatic mutations of adenomatous polyposis coli gene and nuclear b-catenin accumulation have prognostic significance in invasive urothelial carcinomas: evidence for Wnt pathway implication. *Int. J. Cancer* 2009; **124**: 103–108.
32. Stoehr R, Krieg RC, Knuechel R *et al.* No evidence for involvement of beta-catenin and APC in urothelial carcinomas. *Int. J. Oncol.* 2002; **20**: 905–911.
33. Ross JS, Wang K, Al-Rohil RN *et al.* Advanced urothelial carcinoma: next-generation sequencing reveals diverse genomic alterations and targets of therapy. *Mod. Pathol.* 2014; **27**: 271–280.
34. Knowles MA, Hurst CD. Molecular biology of bladder cancer: new insights into pathogenesis and clinical diversity. *Nat. Rev. Cancer* 2015; **15**: 25–41.
35. Eckstein M, Wirtz RM, Gross-Weege M *et al.* mRNA-expression of KRT5 and KRT20 defines distinct prognostic subgroups of muscle-invasive urothelial bladder cancer correlating with histological variants. *Int. J. Mol. Sci.* 2018; **19**: pii: E3396.
36. Warrick JI, Kaag M, Raman JD *et al.* FOXA1 and CK14 as markers of luminal and basal subtypes in histologic variants of bladder cancer and their associated conventional urothelial carcinoma. *Virchows Arch.* 2017; **471**: 337–345.
37. Warrick JI, Sjobahl G, Kaag M *et al.* Intratumoral heterogeneity of bladder cancer by molecular subtypes and histologic variants. *Eur. Urol.* 2019; **75**: 18–22.
38. Mai KT, Hakim SW, Ball CG, Flood TA, Belanger EC. Nested and microcystic variants of urothelial carcinoma displaying immunohistochemical features of basal-like urothelial cells: an immunohistochemical and histopathogenetic study. *Pathol. Int.* 2014; **64**: 375–381.
39. Chuang AY, DeMarzo AM, Veltri RW, Sharma RB, Bieberich CJ, Epstein JI. Immunohistochemical differentiation of high-grade prostate carcinoma from urothelial carcinoma. *Am. J. Surg. Pathol.* 2007; **31**: 1246–1255.
40. <https://www.biorxiv.org/content/10.1101/488460v2> (accessed 1 July 2019).

## Supporting Information

Additional Supporting Information may be found in the online version of this article:

**Table S1.** Forty-eight cancer related genes included in the commercially available sequencing kit.