

(9). The TMB-2-producing *A. soli* strain that we isolated came from a blood culture, indicating that *A. soli* is a potential cause of bloodstream infections or bacteremia. *A. soli* has also been detected in lice and keds of domestic animals (10), indicating that *A. soli* may inhabit natural environments and that injuries and bites by arthropods might present a risk for invasive infections. Isolates of *Acinetobacter* species, particularly those recovered from blood culture, should be identified to species type to enable further evaluation of the clinical significance of carbapenem-resistant *A. soli* strains.

This study was supported by the Ministry of Health, Labour and Welfare, Japan (H25-Shinko-Ippan-003 and H24-Shinko-Ippan-010).

**Hiromitsu Kitanaka,
Masa-aki Sasano,
Satoru Yokoyama,
Masahiro Suzuki, Wanchun Jin,
Masami Inayoshi,
Mitsuhiro Hori,
Jun-ichi Wachino, Kouji Kimura,
Keiko Yamada, and
Yoshichika Arakawa**

Author affiliations: Nagoya University Graduate School of Medicine, Aichi, Japan (H. Kitanaka, S. Yokoyama, W. Jin, J. Wachino, K. Kimura, K. Yamada, Y. Arakawa); Okazaki City Hospital, Aichi (M. Sasano, M. Inayoshi, M. Hori); and Aichi Prefectural Institute of Public Health, Aichi (M. Suzuki)

DOI: <http://dx.doi.org/10.3201/eid2009.140117>

References

1. Yamamoto M, Nagao M, Matsumura Y, Hotta G, Matsushima A, Ito Y, et al. Regional dissemination of *Acinetobacter* species harboring metallo- β -lactamase genes in Japan. *Clin Microbiol Infect*. 2013;19:729–36. <http://dx.doi.org/10.1111/1469-0691.12013>
2. Arakawa Y, Shibata N, Shibayama K, Kurokawa H, Yagi T, Fujiwara H, et al. Convenient test for screening metallo- β -lactamase-producing gram-negative bacteria by using thiol compounds. *J Clin Microbiol*. 2000;38:40–3.
3. Hattori T, Kawamura K, Arakawa Y. Comparison of test methods for detecting metallo- β -lactamase-producing Gram-negative bacteria. *Jpn J Infect Dis*. 2013;66:512–8.
4. Malhotra J, Anand S, Jindal S, Rajagopal R, Lal R. *Acinetobacter indicus* sp. nov., isolated from a hexachlorocyclohexane dump site. *Int J Syst Evol Microbiol*. 2012;62:2883–90. <http://dx.doi.org/10.1099/ijs.0.037721-0>
5. Kim D, Baik KS, Kim MS, Park SC, Kim SS, Rhee MS, et al. *Acinetobacter soli* sp. nov., isolated from forest soil. *J Microbiol*. 2008;46:396–401. <http://dx.doi.org/10.1007/s12275-008-0118-y>
6. Pellegrino FL, Vieira VV, Baio PV, dos Santos RM, dos Santos AL, Santos NG, et al. *Acinetobacter soli* as a cause of bloodstream infection in a neonatal intensive care unit. *J Clin Microbiol*. 2011;49:2283–5. <http://dx.doi.org/10.1128/JCM.00326-11>
7. Endo S, Yano H, Kanamori H, Inomata S, Aoyagi T, Hatta M, et al. High frequency of *Acinetobacter soli* among *Acinetobacter* isolates causing bacteremia at a Japanese tertiary hospital. *J Clin Microbiol*. 2014;52:911–5. <http://dx.doi.org/10.1128/JCM.03009-13>
8. El Salabi A, Borra PS, Toleman MA, Samuelsen Ø, Walsh TR. Genetic and biochemical characterization of a novel metallo- β -lactamase, TMB-1, from an *Achromobacter xylosoxidans* strain isolated in Tripoli, Libya. *Antimicrob Agents Chemother*. 2012;56:2241–5. <http://dx.doi.org/10.1128/AAC.05640-11>
9. Suzuki S, Matsui M, Suzuki M, Sugita A, Kosuge Y, Kodama N, et al. Detection of Tripoli metallo- β -lactamase 2 (TMB-2), a variant of *bla*_{TMB-1} in clinical isolates of *Acinetobacter* spp. in Japan. *J Antimicrob Chemother*. 2013;68:1441–2. <http://dx.doi.org/10.1093/jac/dkt031>
10. Kumsa B, Socolovschi C, Parola P, Rolain JM, Raoult D. Molecular detection of *Acinetobacter* species in lice and keds of domestic animals in Oromia Regional State, Ethiopia. *PLoS ONE*. 2012;7:e52377. <http://dx.doi.org/10.1371/journal.pone.0052377>

Address for correspondence: Yoshichika Arakawa, Department of Bacteriology, Nagoya University Graduate School of Medicine, 65 Tsurumai-cho, Showa-ku, Nagoya, Aichi 466-8550, Japan; email: arakawa@med.nagoya-u.ac.jp

The opinions expressed by the authors contributing to this journal do not necessarily reflect the opinions of the Centers for Disease Control and Prevention or the institution with which the authors are affiliated.

Spread of Vaccinia Virus to Cattle Herds, Argentina, 2011

To the Editor: Since 1999, several zoonotic outbreaks of vaccinia virus (VACV) infection have been reported in cattle and humans in rural areas of Brazil. The infections have caused exanthematous lesions on cows and persons who milk them, and thus are detrimental to the milk industry and public health services (1,2). In Brazil during the last decade, VACV outbreaks have been detected from the north to the extreme south of the country (1–4). Because Brazil shares extensive boundaries with other South American countries, humans and cattle on dairy and beef-producing farms in those countries may be at risk of exposure to VACV. To determine if VACV has spread from Brazil to Argentina, we investigated the presence of VACV in serum samples from cattle in Argentina.

During 2011, we obtained serum samples from 100 animals (50 dairy and 50 beef cattle) on farms in Córdoba, Corrientes, Entre Ríos, and Santa Fe Provinces in Argentina (online Technical Appendix, panel A, <http://wwwnc.cdc.gov/EID/article/20/9/14-0154-Techapp1.pdf>). No VACV cases had been reported in humans or cattle in these provinces. However, Corrientes Province borders the Brazilian state of Rio Grande do Sul, where VACVs (Pelotas 1 and Pelotas 2 viruses) were isolated during an outbreak affecting horses in 2008 (2).

To determine the presence of neutralizing antibodies in the serum samples, we used an orthopoxvirus 70% plaque-reduction neutralization test as described (4). On the basis of previous studies that detected viral DNA in serum samples (4–6), we used real-time PCR to amplify the highly conserved orthopoxvirus vaccinia growth factor (*vgf*) gene DNA (P.A. Alves, unpub. methods).

To amplify the hemagglutinin (HA) gene DNA from the serum samples, we used real-time PCR with primers as described by de Souza Trindade et al. 2008 (7). The HA PCR products were directly sequenced in both orientations by using specific primers and capillary electrophoresis (Genetic Analyzer 3130; Applied Biosystems, Grand Island, NY, USA). We used ClustalW (<http://www.clustal.org>) and MEGA4 software (<http://megasoftware.net/>) to align nucleotide sequences and construct a phylogenetic tree (neighbor-joining method, 1,000 bootstraps) from the obtained HA fragment.

Of the 50 dairy cattle samples, 4 (8.0%) had neutralizing antibodies against orthopoxvirus; of these, 3 (75.0%) had titers of 100 neutralizing units (NU)/mL, and 1 (25.0%) had a titer of 400 NU/mL. Of the 50 beef cattle, 8 (16.0%) had antibodies to orthopoxvirus, 1 (12.5%) of which had a titer of 800 NU/mL. Most of the positive samples were from cattle in Corrientes and Entre Ríos Provinces (Table).

Of the 100 serum samples, 5 (3 from beef and 2 from dairy cattle) were positive for *v_gf* by real-time PCR. HA DNA was amplified from 2 of the 3 *v_gf* PCR-positive beef cattle samples; plaque-reduction neutralization test results were also positive for the 2 samples (Table).

Alignment of the HA fragment nucleotide sequence of the isolates from Argentina showed that the sequence was highly similar to that of

the homologous gene of VACV isolates from Brazil. Furthermore, the sequences showed a signature deletion that is also present in the sequences of VACV isolates from Brazil. Compared with sequences for other VACV isolates, those from Argentina had 2 polymorphisms (online Technical Appendix, panel C). The HA sequences from the isolates from Argentina demonstrated 100% identity among themselves and exhibited higher identity with group 1 (98.2% identity) versus group 2 (93.6% identity) isolates from Brazil (online Technical Appendix, panel D). In the phylogenetic tree based on the HA nucleotide sequences (online Technical Appendix, panel B), the VACVs from Argentina clustered with several group 1 VACVs detected during outbreaks in Brazil.

Although no outbreaks of exanthematous VACV infection have been described in cattle or humans in Argentina, we detected neutralizing antibodies against orthopoxvirus and detected VACV DNA in serum samples from cattle in the country. Most of the seropositive samples were from cattle in Entre Ríos Province, which shares a border with Uruguay, and Corrientes Province, which shares a border with Rio Grande do Sul State in Brazil, where Pelotas VACVs have been isolated (2).

We believe that the seropositive cattle in this study may have been exposed to VACV, the only orthopoxvirus known to be circulating in South America (1–4,8–10). Despite veterinary surveillance efforts of border

control organizations, VACV control may be hampered by the circulation of infected rural workers and the misdiagnosis of VACV infection; misdiagnoses occur because VACV lesions resemble those of other exanthematous diseases. Moreover, peridomestic rodents have been hypothesized to act as VACV hosts, and could facilitate the spread of VACV in border areas (10). In addition, we could not rule out the circulation of autochthonous VACV in Argentina, but this is a less likely explanation. Our findings suggest that cattle herds in areas of Argentina near the border with Brazil may be exposed to VACV from Brazil and, thus, may be at risk for VACV infection. Further research is needed to determine the risk factors for VACV infection and to assess the circulation of VACV in South America

Acknowledgments

We thank João Rodrigues dos Santos, Ângela Sana Lopes, Ilda Gama, and colleagues from the Laboratório de Vírus for their excellent technical support.

Financial support was provided by the Conselho Nacional de Desenvolvimento Científico e Tecnológico (CNPq), Coordenação de Aperfeiçoamento de Pessoal de Nível Superior (CAPES), Fundação de Amparo à Pesquisa do Estado de Minas Gerais (FAPEMIG), and Ministério da Agricultura, Pecuária e Abastecimento (MAPA). A.P.M. F.-L. was the recipient of a fellowships from CAPES, and E.G.K., C.A.B., G.S.T., and P.C.P.F. were recipients of fellowships from CNPq.

Table. Diagnosis of *Orthopoxvirus* infection in beef and dairy cattle during a study of the spread of vaccinia virus to cattle herds, Argentina, 2011*

Province	Cattle type	No. farms sampled	No. serum samples tested	No. positive samples, by level of NU/mL against orthopoxvirus†					Total (%)	No. (%) positive by real-time PCR	
				100	200	400	800	<i>v_gf</i>		HA	
Córdoba	Dairy	1	25	0	0	1	0	1 (4.0)	2 (8.0)	0	
Santa Fe	Dairy	1	25	3	0	0	0	3 (12.0)	0	0	
Corrientes	Beef	>2‡	8	0	1	1	0	2 (25.0)	1 (12.5)§	1 (12.5)§	
Entre Ríos	Beef	5	42	2	2	1	1	6 (14.3)	2 (4.8)	1 (2.4)§	
Total	Dairy and beef	>9	100	5	3	3	1	12 (12.0)	5 (5.0)	2 (2.0)	

*HA, hemagglutinin gene DNA; NU, serum dilution at which 70% plaque reduction per mL occurs; *v_gf*, orthopoxvirus vaccinia growth factor gene DNA.

†Determined by plaque-reduction neutralization test.

‡Samples were obtained from several farms in Corrientes Province.

§Animal was also positive by plaque-reduction neutralization test.

**Ana Paula Moreira Franco-Luiz,
Alexandre Fagundes-Pereira,
Galileu Barbosa Costa,
Pedro Augusto Alves,
Danilo Bretas Oliveira,
Cláudio Antônio Bonjardim,
Paulo César Peregrino Ferreira,
Giliane de Souza Trindade,
Carlos Javier Panei,
Cecilia Mónica Galosi,
Jônatas Santos Abrahão,
and Erna Geessien Kroon**

Author affiliations: Universidade Federal de Minas Gerais, Belo Horizonte, Brazil (A.P.M. Franco-Luiz, A. Fagundes-Pereira, G.B. Costa, P.A. Alves, D.B. Oliveira, C.A. Bonjardim, P.C.P. Ferreira, G.S. Trindade, J.S. Abrahão, E.G. Kroon); Universidad Nacional de la Plata, Buenos Aires, Argentina (C.J. Panei, C.M. Galosi); Consejo Nacional Investigaciones Científicas y Técnicas, Buenos Aires (C.J. Panei); and Comisión de Investigaciones Científicas Provincia de Buenos Aires, Buenos Aires (C.M. Galosi)

DOI: <http://dx.doi.org/10.3201/eid2009.140154>

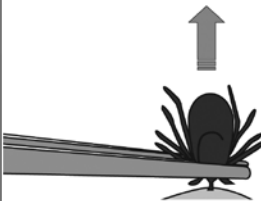
References

- Trindade GS, Lobato ZIP, Drumond BP, Leite JA, Trigueiro RC, Guedes MIMC, et al. Isolation of two vaccinia virus strains from a single bovine vaccinia outbreak in rural area from Brazil: implications on the emergence of zoonotic orthopoxviruses. *Am J Trop Med Hyg.* 2006;75:486–90.
- Campos RK, Brum MC, Nogueira CE, Drumond BP, Alves PA, Siqueira-Lima L, et al. Assessing the variability of Brazilian vaccinia virus isolates from a horse exanthematic lesion: coinfection with distinct viruses. *Arch Virol.* 2011;156:275–83. <http://dx.doi.org/10.1007/s00705-010-0857-z>
- Mota BEF, Trindade GS, Diniz TC, da Silva-Nunes M, Braga EM, Urbano-Ferreira M, et al. Seroprevalence of orthopoxvirus in an Amazonian rural village, Acre, Brazil. *Arch Virol.* 2010;155:1139–44. <http://dx.doi.org/10.1007/s00705-010-0675-3>
- Abrahão JS, Silva-Fernandes AT, Lima LS, Campos RK, Guedes MI, Cota MM, et al. Vaccinia virus infection in monkeys, Brazilian Amazon. *Emerg Infect Dis.* 2010;16:976–9. <http://dx.doi.org/10.3201/eid1606.091187>
- Cohen JI, Hohman P, Preuss JC, Li L, Fischer SH, Fedorko DP, et al. Detection of vaccinia virus DNA, but not infectious virus, in the blood of smallpox vaccine recipients. *Vaccine.* 2007;25:4571–4. <http://dx.doi.org/10.1016/j.vaccine.2007.03.044>
- Savona MR, Dela Cruz WP, Jones MS, Thornton JA, Xia D, Hadfield TL, et al. Detection of vaccinia DNA in the blood following smallpox vaccination. *JAMA.* 2006;295:1895–900. <http://dx.doi.org/10.1001/jama.295.16.1898>
- de Souza Trindade G, Li Y, Olson VA, Emerson G, Regnery RL, da Fonseca FG, et al. Real-time PCR assay to identify variants of vaccinia virus: implications for the diagnosis of bovine vaccinia in Brazil. *J Virol Methods.* 2008;152:63–71. <http://dx.doi.org/10.1016/j.jviromet.2008.05.028>
- Damon IK. Poxviruses. In: Knipe DM, Howley PM, Griffin DE, Lamb RA, Martin MA, Roizman B, et al., editors. *Fields virology.* Vol II. 5th ed. Philadelphia: Lippincott Williams and Wilkins; 2007. p. 2947–75.
- Trindade GS, Emerson GL, Carroll DS, Kroon EG, Damon IK. Brazilian vaccinia viruses and their origins. *Emerg Infect Dis.* 2007;13:965–72. <http://dx.doi.org/10.3201/eid1307.061404>
- Abrahão JS, Guedes MI, Trindade GS, Fonseca FG, Campos RK, Mota BF, et al. One more piece in the VACV ecological puzzle: could peridomestic rodents be the link between wildlife and bovine vaccinia outbreaks in Brazil? *PLoS ONE.* 2009;4:e7428. <http://dx.doi.org/10.1371/journal.pone.0007428>

Address for correspondence: Erna G. Kroon, Laboratório de Vírus, Departamento de Microbiologia, Instituto de Ciências Biológicas, Universidade Federal de Minas Gerais, Av. Antônio Carlos, 6627, Caixa Postal 486, CEP 31270-901, Belo Horizonte, Minas Gerais, Brazil; email: ernagkroon@gmail.com

How to Correctly Remove a Tick

Grasp the tick firmly and as closely to the skin as possible. With a steady motion, pull the tick's body away from the skin. Do not be alarmed if the tick's mouthparts remain in the skin. Cleanse the area with an antiseptic.



For more information please contact:
Centers for Disease Control and Prevention
1600 Clifton Road NE, Atlanta, GA 30333
Telephone: 1-800-CDC-INFO (232-4636)
TTY: 1-888-232-63548
Web: www.cdc.gov/Lyme

Cerebellitis Associated with Influenza A(H1N1)pdm09, United States, 2013

To the Editor: Central nervous system (CNS) manifestations of influenza are uncommon, especially in adults (1,2), and influenza-associated cerebellitis is exceedingly rare: 8 cases have been reported (3–7; online Technical Appendix). We describe a case of cerebellitis caused by influenza A(H1N1)pdm09 in an adult woman.

The 37-year-old female patient who sought medical care in Florida, United States, on January 5, 2013, described a 4-day history of intermittent fever of 38.5°C, generalized fatigue, diffuse headache, mild nonproductive cough, 3 episodes of vomiting, and decreased oral intake. On January 4, she experienced acute onset of ataxia and dysarthric speech with slurred pronunciation. She reported no contact with sick persons, recent travel, or exposure to pets or birds. She had a medical history of asthma since childhood, controlled by using montelukast tablets and inhaled steroids. The patient denied having ever received an influenza vaccination.

The patient appeared ill; her oral temperature was elevated at 38.3°C, but other vital signs were within normal limits (blood pressure 109/70 mm Hg; pulse rate 88 beats/minute; respiratory rate 15 breaths per minute; and oxygen saturation 98% at room air). Mucosal membranes appeared normal. No neck stiffness or palpable lymph nodes were noted. Results of heart examination were normal. Lungs were clear to auscultation, and the abdomen was soft, indicating no hepatosplenomegaly or palpable masses. No rash was seen. The neurologic examination revealed normal mental status but moderate ataxic dysarthria. Her cranial nerves were intact, and motor strength was 5/5 throughout. Results of a sensory