



Case report

Lung function improvements in emphysema following pneumonia

Kayani Kayani^{a,*}, Ravi Mahadeva^b, Sian Stinchcombe^b, Matthew Rutter^c, Judith Babar^d, Jonathan Fuld^b

^a University of Cambridge School of Clinical Medicine, Cambridge, United Kingdom

^b Respiratory Medicine, Cambridge University Hospitals NHS Foundation Trust, Hills Road, Cambridge, United Kingdom

^c Lung Function Unit, Cambridge University Hospitals NHS Foundation Trust, Hills Road, Cambridge, United Kingdom

^d Department of Radiology Cambridge University Hospitals NHS Foundation Trust, Hills Road, Cambridge, United Kingdom

ARTICLE INFO

Keywords:

COPD
Autobullectomy
Lung volume reduction

ABSTRACT

We describe two cases of patients with emphysema who, in the lead up to hyperinflation intervention, developed pneumonia with significant physiological, anatomical, functional and quality of life improvement observed following. This directly goes against the natural history of both disease processes, demonstrating the benefit resulting from infective autobullectomy.

1. Introduction

Hyperinflation results from collapsible, distended, over-compliant portions of lung trapping air. Consequently, there is a failure to effectively expire, increasing residual volume (RV). This leads to patients breathing at higher lung volumes, impinging on lung reserve. Reducing hyperinflation and restoring lung reserve has the potential to functionally and clinically improve patients' health and outcomes. This is a rapidly developing area for targeted interventions with surgery, valves and coils occupying varying positions in clinical practice. Multidisciplinary hyperinflation services are emerging, utilising physiology, imaging, functional and collateral ventilation assessments to evaluate patients. Naturally occurring improvements in the context of autobullectomy are recognised [1–3].

2. Materials and methods

Two patients were seen at a specialist respiratory centre which confirmed and managed their COPD. Neither patient has co-existent atopic conditions or known history of atopy. Both patients had full before and after pneumonic episode spirometry, chest plain radiograph, BODE scores, CAT scores and 6-min walking distances (6MWD) recorded. Case one shows significant improvement on CT scans done pre-

and post-pneumonic episodes, which are not available for case two. Case one also has a full St George's Respiratory Questionnaire for both before and after. Both were treated with co-amoxiclav and ciprofloxacin, guided by microbiology cultures and sensitivity screens.

3. Results

3.1. Case 1

A 64-year-old male presented with left upper lobe pneumonia, on a background of severe emphysema. His concurrent asthma was well controlled, as suggested by his < 25 ppb FeNO. He had completed pulmonary rehabilitation but was unsuccessful in smoking cessation. LVRS was being considered, having been excluded for EBVs due to the presence of collateral ventilation. Over the previous seven years, his lung function had progressively declined (FEV1 1.13l reduced to 0.97l). His exertion was normally limited to 90 m and he experienced recurrent exacerbations and deterioration of breathlessness. CT showed severe emphysema with pan-lobular upper lobe predominance.

Sixteen months following pneumonia, lung function showed improvement. Chest radiograph showed reduced hyperinflation (Fig. 1, recovery; Fig. 2, case 1, recovery). He described feeling he could do 'three times more than previously' and is more confident about his

Abbreviations: COPD, Chronic Obstructive Pulmonary Disease; RV, Residual Volume; BODE, Body mass index, airflow Obstruction, Dyspnea and Exercise capacity; CAT, COPD Assessment Test; 6MWD, 6 Minute Walking Distance; CT, Computed Tomography; FeNO, Fractional exhaled Nitric Oxide; LVRS, Lung Volume Reduction Surgery; EBV, Endobronchial Valves; FEV1, Forced Expiratory Volume in one second; IgE, Immunoglobulin E; SGRQ, St Georges Respiratory Questionnaire; MCID, Minimal Clinically Important Difference; GOLD, Global initiative for chronic Obstructive Lung Disease; RV, Residual Volume; VA, alveolar volume; KCO, transfer coefficient of diffusion; NICE, National Institute for Health and Care Excellence; EBC, Endobronchial Coil

* Corresponding author. The University of Cambridge School of Clinical Medicine, Box 111, Cambridge Biomedical Campus, Cambridge, CB2 0SP, UK.

E-mail address: kk515@cam.ac.uk (K. Kayani).

<https://doi.org/10.1016/j.rmcr.2018.10.025>

Received 19 December 2017; Received in revised form 24 October 2018; Accepted 25 October 2018

2213-0071/© 2018 The Authors. Published by Elsevier Ltd. This is an open access article under the CC BY-NC-ND license (<http://creativecommons.org/licenses/by-nc-nd/4.0/>).

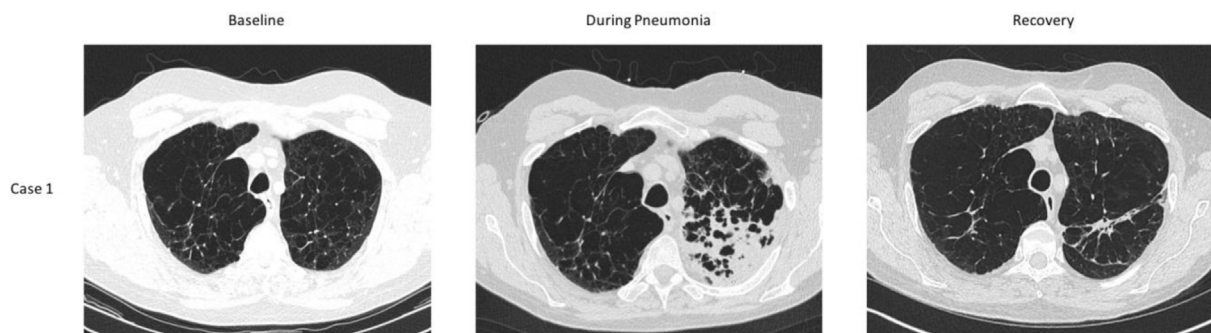

Fig. 1. Case 1 CT chest: pre- during- and post-pneumonia. There is consolidation superimposed on emphysematous changes in the left upper lobe during the acute pneumonia. The CT post recovery demonstrates scarring in the left upper lobe, with volume loss, as evidenced by anterior displacement of the left oblique fissure compared to the baseline CT.

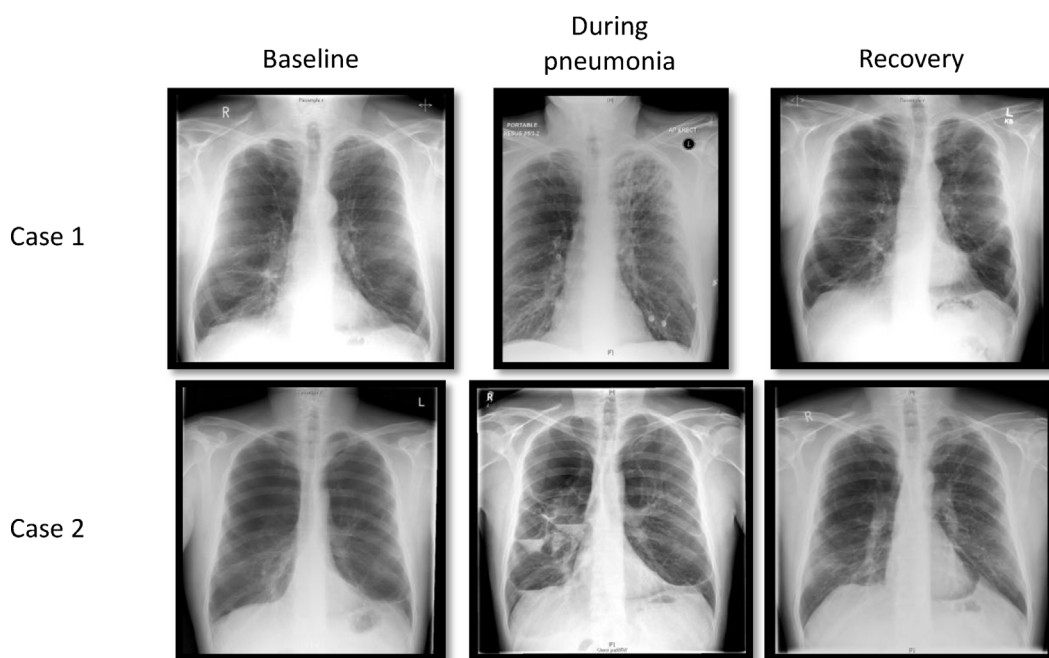


Fig. 2. Chest plain radiographs for both cases showing pre-, during- and post-pneumonia radiology. Chest plain radiographs for both cases showing pre-, during- and post-pneumonia radiology. Case 1: During-pneumonia plain radiograph demonstrates left upper lobe consolidation superimposed upon emphysema. Mild resulting volume loss on the post pneumonia image, better demonstrated by CT imaging in Fig. 1. Case 2: Multiple air fluid levels within bilateral bulla in the upper zones, with a rounded opacity in the Left upper zone representing a large fluid filled bulla during-pneumonia imaging. Post pneumonia plain radiograph demonstrates volume loss in the left upper lobe as evidenced by superior retraction of the left hilum and tenting of the left hemidiaphragm.

health, which is reflected in his CAT and 6MWD.

3.2. Case 2

A 40-year-old male presented with lung infection of his upper zones. CT showed bullae measuring up to 15cm, replacing almost the entire upper lobe, occupying approximately 50% of the lung volume. Compressive atelectasis within the middle lobe and lingula and minimal abnormalities in the lower lobes were also observed. He previously smoked cigarettes (32 pack years) and cannabis daily throughout his 20s (resin and leaf). He demonstrates normal eosinophil and IgE levels in blood tests. His fitness at presentation meant he did not stop walking throughout his 6MWD, placing him beyond the ceiling of the test. He has completed a pulmonary rehabilitation course in the past.

After 3 episodes of infection in his bullous spaces over 3 years, each requiring long term antibiotics, his lung function improved (Fig. 3, Table 1). He reports feeling ‘brilliant’ and has taken up mountain

biking. On CT, a residual opacity, 10% of the size of the bulla replaced the space of his left upper lobe bullae. Chest radiograph showed superior retraction of his left hilum, tenting of the left hemidiaphragm and reduction in the size of bullous spaces (Fig. 2, case 2, recovery).

Both patients continue to experience improved lung function, as described above, with functional improvement, and continue to be seen routinely for monitoring in clinic.

4. Discussion

Both of our patients had aspects of physiological or clinical improvement of significance following pneumonic episodes. Significantly, improvements seen in FEV1 in both cases were beyond minimal clinically important differences (MCIDs). Reported benefits included an increased walking distance in case one and case two returning to mountain biking. These cases demonstrate that in the context of diffuse emphysema, rather than discrete bullae, co-located infection can have

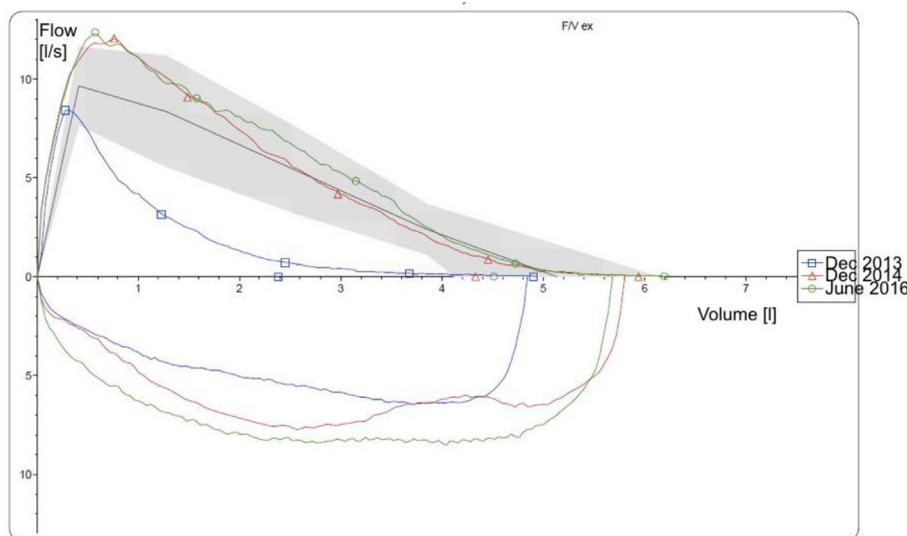


Fig. 3. Case 2's Flow-Volume loops, demonstrating improvement post pneumonic episodes.

distinct impact.

Lung function significantly improved in both. There were more varying impacts upon walking distance achieved. Interestingly, likely due to volume correction, gas transfer was also impacted. All these findings are directly against the natural history of the disease and initial measurements were all taken in the stable optimally medically treated state.

Case one demonstrated a large improvement in 6MWD and FEV1 following pneumonia, both significantly above MCIDs. His global initiative for chronic obstructive lung disease (GOLD) staging changed from stage 4 (very severe) to stage 3 (severe), a marked improvement, which is reflected in his health-related quality of life assessment (CAT score).

Case two normalised his lung function values (FEV1, FEV/FVC, RV), despite imaging showing the presence of bullous disease. The reduction in atelectasis of his middle and lower lobe is reflected in his increased VA. This, rather than a reduction in alveolar exchange efficacy, explains the decrease in KCO. As he no longer smokes cigarettes or cannabis, we anticipate his lung function will remain stable and do not expect to observe decline in the future.

Emphysema is characterised by the abnormal permanent enlargement of the air spaces distal to the terminal bronchioles, accompanied by destruction of alveolar walls. This occurs following a sequence of inflammatory processes, obstruction from mucus hypersecretion and subsequent entrapment and alveolar distension or destruction. The surrounding bronchioles are compressed, increasing airway resistance and the effort required to maintain breathing efforts.

The functional sum of this is dynamic hyperinflation; a premature inspiratory breath before end expiration. This adds to the trapping of air in the hyperinflated lung. Exertion normally raises the respiratory rate by shortening expiratory phase. Obstruction in emphysema (which is most pronounced on expiration) combined with the shortened expiratory phase causes incomplete expiration on exertion, increasing air trapping and hyperinflation.

Hyperinflation therefore has devastating clinical impacts. Newer interventions, targeting the most diseased parts of lung, have a growing evidence base and are discussed for comparison to observed post-pneumonic improvements. However, medical therapy is the mainstay of COPD management in clinic. In comparison to control, the TORCH trial demonstrated significant improvements in FEV1 with salmeterol and fluticasone respectively and further improvement with combination therapy [5]. The UPLIFT trial demonstrated the benefit of tiotropium over placebo at regular time points in 5993 patients over four years in

pre-bronchodilator FEV1 and SGRQ scores [6]. These studies and others have formed the basis of our long-term pharmacological management of COPD.

While medical therapy has impacted upon symptoms, additional core elements of effective support to people with COPD are pulmonary rehabilitation, smoking cessation and vaccination. Pulmonary rehabilitation significantly impacts upon symptoms, quality of life, exercise capacity as well as exacerbation frequency [7].

4.1. Mechanism of improvement

There are no data outside the context of case reports that describe the processes of the mechanistic reductions of hyperinflation in pneumonia. However, the pathophysiology of lung parenchymal changes in infection is well characterised.

As bacterial infections occur in emphysematous portions of lung; fibrous, non-compliant scar tissue replaces the lung tissue. This occurs after substantial tissue destruction via the inflammatory process. Connective tissue grows into the area of damage or exudate, converting it into a mass of fibrous tissue. Additionally, the Th2 immune response to bacteria is hypothesised to be a potent driver of fibrosis [8].

Bacterial toxins and inflammatory processes cause the destruction of large amounts of delicate, normal, compliant lung tissue. Inflammation involves the release of various cytokines, including those essential to organising resolution (TNF, PDGF, FGF-2 and TGF- β). TGF- β , EGF, PDGF and FGF, produced by inflammatory cells, promote fibroblast proliferation, while their migration is supported by the cytokines IL-1 and TNF. Fibroblast activity leads to collagen fibril and fibronectin deposition, in the lung parenchyma. Simultaneously, the inhibition of matrix metalloproteases by cytokines decreases extracellular matrix breakdown, leading to significant amounts of fibrous collagen dense connective tissue being laid down. As the inflammatory process terminates, healing progresses and the number of proliferating fibroblasts decrease. However, the fibroblasts assume a more synthetic phenotype, depositing extracellular matrix, maintaining this state over a period of weeks. As collagen continues to be synthesised, the tissue becomes more fibrotic in nature. Furthermore, some fibroblasts transform into myofibroblasts, acquiring features of smooth muscle, including actin filaments, causing contraction of tissue [8,9].

Thus, as bacterial infections occur in emphysematous portions of lung; fibrous, non-compliant scar tissue replaces the lung tissue. It is likely that, if co-located in the most emphysematous portions of lung, the compliance of these portions of lung would improve. If allowed to

Table 1

Table showing lung function testing and parameters for both patients at time points before and after pneumonia. Note, case 2 completed a 6MWD with no breaks, achieving a distance of 490. Thus, no further 6MWD was completed owing to his improved lung function since his last test.

	Pre-Pneumonia	Post-Pneumonia	Absolute change (Post-Pre)	% change from baseline
CASE 1				
FEV1 (L) (% pred)	0.97 (27)	1.18 (33.7)	0.21 (6.7)	21.65 (24.81)
FVC (L)	3.83	3.27	-0.56	-14.62
VC max (L)	4.23	4.79	0.56	13.24
FEV % VC max	22.93	30.94	8.01	34.93
TLC (L)	10.89	10.69	-0.2	-1.84
RV (L)	6.82	5.89	-0.93	-13.64
RV/TLC (%)	62.65	55.13	-7.52	-12.00
VC (L)	4.07	4.79	0.72	17.69
TLCO [mmol/ (min*kPa)]	3.37	4.78	1.41	41.84
KCO [mmol/ (min*kPa*L)]	0.54	0.54	0	0.00
VA (L)	6.27	8.78	2.51	40.03
6MWD (m)	120	220	100	83.33
BODE	9	8	-1	-11.11
MMRC dyspnoea scale score	4	4	0	0.00
CAT score	32	29	-3	-9.38
SGRQ health	good	poor		
symptoms	97.05	89.05	-8	8.92
activity	100	100	0	0.00
impact	84.86	89.41	4.55	5.36
total	91.66	92.6	0.94	1.03
BMI	26.73	22	-4.73	-17.70
CASE 2				
FEV1 (L) (% pred)	2.38 (56.6)	4.51 (111)	2.13 (54.4)	89.50 (96.11)
FVC (L)	4.9	6.2	1.3	26.53
VC max (L)	4.9	6.3	1.4	28.57
FEV % VC max	48.59	71.62	23.03	47.40
TLC (L)	8.31	7.77	-0.54	-6.50
RV (L)	3.68	1.76	-1.92	-52.17
RV/TLC (%)	44.23	22.59	-21.64	-48.93
VC (L)	4.64	6.01	1.37	29.53
TLCO [mmol/ (min*kPa)]	10.11	10.65	0.54	5.34
KCO [mmol/ (min*kPa*L)]	1.82	1.54	-0.28	-15.38
VA	5.56	6.93	1.37	24.64

Jones et al (2014) defined minimal clinically important differences (MCIDs) in COPD as: FEV1 change of 100 ml, health status change by 4 units in the St George's Respiratory Questionnaire (SGRQ) (health improvement giving a reduction in score) and change in exercise capacity as 26 ± 2 m in 6 minute walking distance [4].

continue further, it may even lead to shrinkage of these portions of lung as over-compliant tissue is replaced with uncompliant, contracted fibrous tissue. This fibrous tissue is less collapsible and not liable to air trapping and hyperinflation. This process is analogous to some of the surgical or endoscopic means by which attempts are made to reduce hyperinflation (discussed below).

As the most diseased portions of lung contract and recede, less diseased portions expand. Air enters portions of the lung with healthier alveoli, improving gas exchange. Reducing hyperinflation also improves lung mechanics and lung elasticity, further enhanced by the presence of new fibrous tissue.

4.2. Surgical lung volume reduction (LVRS)

LVRS removes the most diseased portions of lung, reducing hyperinflation and improving lung mechanics. Reduction in distention improves elastic lung elasticity, the position of the diaphragm and ability of intercostal muscles to increase inspiratory pressures. The NETT trial studied 1218 patients and found LVRS improves long term survival, measured at one year. However, it failed to reach its primary endpoint of mortality reduction. Instead, it was associated with a high 90-day mortality rate (7.9% vs 1.3% medically managed). Nevertheless, post hoc analysis showed, in those with predominantly upper lobe disease and low exercise tolerance, LVRS gave a significant survival advantage as opposed to usual medical management [10].

Emphasising the importance of patient selection in achieving good outcomes, a 2016 Cochrane library review of LVRS found FEV1 in LVRS treated patients to be 0.2 l higher than control groups [11]. Similarly, 6MWDs were 0.7 standard deviations higher in the LVRS group, while SGRQ scores were 13.78 points lower. NICE have since approved LVRS in select patients and despite early mortality concerns, some centres are now reporting a less than 1% 90-day mortality rate [12,13].

4.3. Endobronchial valves (EBVs)

The early mortality concerns and complexity associated with LVRS has made EBVs attractive. EBVs allow air out of a diseased lung lobe, but not in, progressively causing atelectasis, reducing hyperinflation, with similar effects to LVRS. The BeLieVer-HiFi study enrolled 50 patients with intact interlobular fissures and heterogeneous emphysema. Mean FEV1 improved by 24.8% in the EBV group (n = 25) compared with 3.9% in the sham group. However, two patients died in the intervention group and there was significant spread in the results of the intervention group. Post hoc analysis demonstrated improved responses in FEV1, 6MWD and exercise endurance in patients with no collateral ventilation on chartis assessment, which was later confirmed by the IMPACT study [14,15].

However, those considered for valves should be assessed for their ability to survive pneumothorax, the most common complication of valve insertion [16,17]. These, however, can usually be conservatively managed without incident. EBVs are currently approved by NICE for use as a means of lung volume reduction [18].

4.4. Endobronchial coils (EBCs)

EBCs are currently in Phase III trials and are a potential alternative to EBVs. The RESET trial compared 24 standard care patients with 23 coil treated patients. Directly comparing the two groups, the coil group improved in FEV1 (10.6%), RV (-0.31l), 6MWD (63.6m) and SGRQ (-8.36 points). This study demonstrated the safety of EBCs and their success in targeting homogenous emphysema, a disease form which has been unamenable to LVRS and EBVs [19].

The RENEW trial enrolled 315 patients, comparing EBCs and usual care to usual care alone. At one year, 40% of coil patients had a greater than 25m change in 6MWD (vs 26.9% of controls) and between group median differences were significantly in favour of EBC patients (FEV1: 7.0%, SGRQ: 8.9 points). Importantly, there was no excess in death. However, more instances of pneumonia (20% coils vs 4.5%) and pneumothorax (9.7% vs 0.6%) were observed. Post-hoc analysis from this study however shows that one third of the pneumonias identified were coil opacities [20]. While studies have shown promising data for EBCs in select patients, they are currently recommended by NICE only in the context of research [21].

5. Conclusions

Clinically meaningful benefits resulted following the occurrences of pneumonia in the most diseased portions of lung in varying clinical

phenotypes of emphysema.

6. Limitations

We recognise this is an isolated cases series and did not involve prospective identification of patients with emphysema and pneumonia. Furthermore, clearly pneumonia poses a significant risk to people with advanced lung disease and we do not know the prevalence of this positive phenomenon. Nevertheless, we have shown unexpected significant improvement within their own right in these cases. We recognise that quantified CT would be the gold standard for identifying change to hyperinflation, however chest radiographs are routinely performed following pneumonia and can provide indications of reductions in hyperinflation.

Declarations of interest

None.

Funding

This research did not receive any specific grant from funding agencies in the public, commercial or not-for-profit sectors.

Appendix A. Supplementary data

Supplementary data to this article can be found online at <https://doi.org/10.1016/j.rmcr.2018.10.025>.

References

- [1] R.P.J. Byrd, T.M. Roy, Spontaneous resolution of a giant pulmonary bulla: what is the role of bronchodilator and anti-inflammatory therapy? *Tenn. Med.* 106 (1) (2013) 39–42.
- [2] Z.K. Wahbi, A.G. Arnold, Spontaneous closure of a large emphysematous bulla, *Respir. Med.* 89 (5) (1995) 377–379, [https://doi.org/10.1016/0954-6111\(95\)90012-8](https://doi.org/10.1016/0954-6111(95)90012-8).
- [3] A.C. Douglas, I.W.B. Grant, Spontaneous closure of large pulmonary bullae: a report on three cases, *Br. J. Tubercul. Dis.* Chest 51 (4) (1957) 335–338, [https://doi.org/10.1016/S0366-0869\(57\)80129-4](https://doi.org/10.1016/S0366-0869(57)80129-4).
- [4] P.W. Jones, K.M. Beeh, K.R. Chapman, M. Decramer, D.A. Mahler, J.A. Wedzicha, Minimal clinically important differences in pharmacological trials, *Am. J. Respir. Crit. Care Med.* 189 (3) (2014) 250–255, <https://doi.org/10.1164/rccm.201310-1863PP>.
- [5] P.M.A. Calverley, J.A. Anderson, B. Celli, et al., Salmeterol and fluticasone propionate and survival in chronic obstructive pulmonary disease, *N. Engl. J. Med.* 356 (8) (2007) 775–789, <https://doi.org/10.1056/NEJMoa063070>.
- [6] D.P. Tashkin, B. Celli, S. Senn, et al., A 4-year trial of tiotropium in chronic obstructive pulmonary disease, *N. Engl. J. Med.* 359 (15) (2008) 1543–1554, <https://doi.org/10.1056/NEJMoa0805800>.
- [7] M.A. Spruit, S.J. Singh, C. Garvey, et al., An official American thoracic society/European respiratory society statement: key concepts and advances in pulmonary rehabilitation, *Am. J. Respir. Crit. Care Med.* 188 (8) (2013), <https://doi.org/10.1164/rccm.201309-1634ST>.
- [8] T.A. Wynn, T.R. Ramalingam, Mechanisms of fibrosis: therapeutic translation for fibrotic disease, *Nat. Med.* 18 (7) (2012) 1028–1040, <https://doi.org/10.1038/nm.2807>.
- [9] V. Kumar, A.K. Abbas, J.C. Aster, Chapter 3: inflammation and repair, in: V. Kumar, A.K. Abbas, J.C. Aster (Eds.), *Robbins and Cotran Pathologic Basis of Disease*, ninth ed., Elsevier Saunders, Philadelphia, 2015, pp. 69–111.
- [10] A. Fishman, F. Martinez, K. Naunheim, et al., A randomized trial comparing lung-volume-reduction surgery with medical therapy for severe emphysema, *N. Engl. J. Med.* 348 (21) (2003) 2059–2073, <https://doi.org/10.1056/NEJMoa030287>.
- [11] J.E. van Agteren, K.V. Carson, Tiong LU, B.J. Smith, Lung volume reduction surgery for diffuse emphysema, *Cochrane Database Syst. Rev.* 10 (2016) CD001001, <https://doi.org/10.1002/14651858.CD001001.pub3>.
- [12] S.J. Clark, Z. Zoumot, O. Bamsey, et al., Surgical approaches for lung volume reduction in emphysema, *Clin. Med.* 14 (2) (2014) 122–127, <https://doi.org/10.7861/clinmedicine.14-2-122>.
- [13] NICE, NICE Guidance: lung volume reduction surgery for advanced emphysema, *Natl. Inst. Health Clin. Excell.* (2005) 2–7 <https://www.nice.org.uk/guidance/ipg114>.
- [14] C. Davey, Z. Zoumot, S. Jordan, et al., Bronchoscopic lung volume reduction with endobronchial valves for patients with heterogeneous emphysema and intact interlobar fissures (the BeLieVeR-HIFI study): a randomised controlled trial, *Lancet (London, England)* 386 (9998) (2015) 1066–1073, [https://doi.org/10.1016/S0140-6736\(15\)60001-0](https://doi.org/10.1016/S0140-6736(15)60001-0).
- [15] A. Valipour, D.J. Slebos, F. Herth, et al., Endobronchial valve therapy in patients with homogeneous emphysema results from the IMPACT study, *Am. J. Respir. Crit. Care Med.* 194 (9) (2016) 1073–1082, <https://doi.org/10.1164/rccm.201607-1383OC>.
- [16] K. Klooster, N.H.T. ten Hacken, J.E. Hartman, H.A.M. Kerstjens, E.M. van Rikxoort, D.-J. Slebos, Endobronchial valves for emphysema without interlobar collateral ventilation, *N. Engl. J. Med.* 373 (24) (2015) 2325–2335, <https://doi.org/10.1056/NEJMoa1507807>.
- [17] P.L. Shah, F.J. Herth, W.H. van Geffen, G. Deslee, D.-J. Slebos, Lung volume reduction for emphysema, *Lancet Respir. Med.* (September 2016), [https://doi.org/10.1016/S2213-2600\(16\)30221-1](https://doi.org/10.1016/S2213-2600(16)30221-1).
- [18] NICE, Endobronchial valve insertion to reduce lung volume in emphysema, <https://www.nice.org.uk/guidance/ipg600>, (2017), Accessed date: 18 September 2018.
- [19] P.L. Shah, Z. Zoumot, S. Singh, et al., Endobronchial coils for the treatment of severe emphysema with hyperinflation (RESET): a randomised controlled trial, *Lancet Respir. Med.* 1 (3) (2013) 233–240, [https://doi.org/10.1016/S2213-2600\(13\)70047-X](https://doi.org/10.1016/S2213-2600(13)70047-X).
- [20] F.C. Sciuuba, G.J. Criner, C. Strange, et al., Effect of endobronchial coils vs usual care on exercise tolerance in patients with severe emphysema: the RENEW randomized clinical trial, *JAMA* 315 (20) (2016) 2178–2189, <https://doi.org/10.1001/jama.2016.6261>.
- [21] NICE, NICE Guidance: Insertion of Endobronchial Nitinol Coils to Improve Lung Function in Emphysema (March), (2015), pp. 2–8 <https://www.nice.org.uk/guidance/ipg517>.