

## Case Report: Highlighting Male Genital Schistosomiasis (MGS) in Fishermen from the Southwestern Shoreline of Lake Malawi, Mangochi District

Sekeleghe A. Kayuni,<sup>1,2\*</sup> E. J. LaCourse,<sup>1</sup> Peter Makaula,<sup>3</sup> Fanuel Lampiao,<sup>4</sup> Lazarus Juziwelo,<sup>5</sup> Joana Fawcett,<sup>1</sup> Alexandra Shaw,<sup>1</sup> Mohammad Alharbi,<sup>1</sup> Jaco J. Verweij,<sup>6</sup> and J. Russell Stothard<sup>1</sup>

<sup>1</sup>Department of Tropical Disease Biology, Liverpool School of Tropical Medicine, Liverpool, United Kingdom; <sup>2</sup>MASM Medi Clinics Limited, Medical Society of Malawi (MASM), Blantyre, Malawi; <sup>3</sup>Research for Health Environment and Development (RHED), Mangochi, Malawi; <sup>4</sup>Physiology Department, College of Medicine, University of Malawi, Blantyre, Malawi; <sup>5</sup>National Schistosomiasis and STH Control Program, Community Health Sciences Unit (CHSU), Ministry of Health, Lilongwe, Malawi; <sup>6</sup>Elisabeth-TweeSteden Hospital Tilburg, Laboratory for Medical Microbiology and Immunology, Tilburg, The Netherlands

**Abstract.** Urogenital schistosomiasis causes morbidity within the genitalia but is underreported and infrequently examined in men. To draw attention to male genital schistosomiasis (MGS), a longitudinal cohort study was conducted among fishermen along the southwestern shoreline of Lake Malawi. A case series of five participants is presented inclusive of questionnaire interviews, parasitological examinations, ultrasonography, and provision of a standard dose (40 mg/kg) of praziquantel (PZQ) treatment at baseline, 1-, 3-, 6-, and 12-month follow-up time points. Eggs of *Schistosoma haematobium* were observed in urine or semen across all time points; parasitological diagnostics were bolstered by real-time PCR for *Schistosoma* DNA in semen and by portable ultrasonography to document putative MGS-associated morbidity. We highlight the importance of developing standard diagnostic tests for MGS and increasing the accessibility of PZQ treatment to men, especially those in at-risk endemic areas.

### CASE SERIES

We report on five most notable and more severe cases from our longitudinal cohort study investigating male genital schistosomiasis (MGS) among fishermen along the southwestern shoreline of Lake Malawi, Mangochi district, Malawi. Fishermen were recruited and interviewed, and they submitted a midmorning urine sample for reagent strip analysis (Siemens Multistix 10 G), point-of-care circulating cathodic antigen (POC-CCA) analysis, and syringe filtration with microscopy<sup>1</sup>; a semen specimen was also provided for parasitological diagnosis.<sup>2,3</sup> Ethanol-preserved semen was also shipped to Elisabeth-TweeSteden Hospital in Tilburg, the Netherlands, for DNA extraction and real-time polymerase chain reaction (real-time PCR) detection of *Schistosoma* DNA.<sup>4</sup>

Study participants underwent transabdominal and scrotal ultrasonography examinations for genital pathologies before receiving praziquantel (PZQ) at standard dose (40 mg/kg). They were invited for follow-up studies at 1-, 3-, 6-, and 12-month time points. Research ethical clearance was granted by the LSTM Research Ethics Committee in the United Kingdom and the National Health Sciences Research Committee in Malawi.

Overall characteristics of the patient cohort at baseline include the following: prevalence of *Schistosoma haematobium* egg patency in urine was 17.1% ( $n = 210$ , mean = 14.8 eggs per 10 mL) and in semen was 10.4% ( $n = 114$ , mean = 5.9 eggs per mL), whereas on real-time PCR, it increased to 27.7%. The prevalence of intestinal schistosomiasis was 3.8%, as estimated using POC-CCA tests.

**Case 1.** LN, a 20-year-old man, weighing 66 kg, lives on Lake Malawi shores since birth and has been fishing for the past 10 years. He reported body weakness and increasing urinary frequency for a month and also noted delayed or no ejaculation during coitus, together with reduced semen volume. He reported terminal hematuria between age 9 and 14 years, which was treated. In the past year, he received PZQ as part of the annual mass drug administration campaign (MDA) in the district.

On examination, his urine sample was of normal color with no turbidity, and the reagent strip was negative for leukocytes and blood but with trace of protein. The POC-CCA test on urine was negative, and no *S. haematobium* egg was observed after filtration. In his 1.5-mL semen specimen, 14 eggs and 60 leukocytes were detected by direct clear-bag microscopy and 10 eggs after centrifugation. However, real-time PCR was subsequently negative. Ultrasonography was normal. He was given PZQ, and follow-up at 1, 3, and 12 months revealed no abnormalities or symptoms previously reported.

**Case 2.** AJ, a 44-year-old man, 57.9 kg body weight, has been fishing in the lake for 32 years, where he bathes and washes daily. He was stable on antiretroviral therapy for HIV infection for over 6 months. For a month, he experienced headache, dysuria, hematuria, blood in stool, hemospermia, and genital pain, sometimes on ejaculation. Together with his wife, he suspected sexually transmitted infection (STI) and had accessing treatment. He suspected schistosomiasis but did not access treatment.

He was unable to submit a semen specimen for examination, although his urine was of normal color and reagent strip was positive for leukocytes (1+), protein (1+), and blood (microhematuria 3+), with a positive POC-CCA test. After filtration, 744 and 488 *S. haematobium* eggs were detected in 40 mL and 50 mL urine samples, respectively, submitted on 2 alternate days. Genital ultrasonography was normal, and he was given PZQ on each of the 2 days. At 1-month follow-up, his symptoms had improved and submitted 1 mL semen which had no eggs, and real-time PCR was positive

\*Address correspondence to Sekeleghe A. Kayuni, Department of Tropical Disease Biology, Liverpool School of Tropical Medicine, University of Liverpool, 3rd floor, CTID Building, Pembroke Place, Liverpool L3 5QA, United Kingdom. E-mail: seke.kayuni@lstm.ac.uk

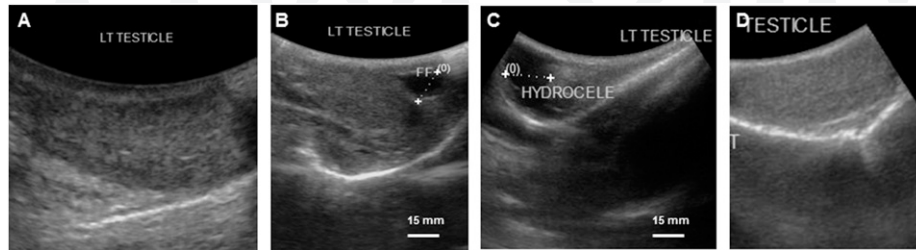


FIGURE 1. Pictorial illustration of the ultrasonography of the left testis for Case 2. (A) Normal testicular tissue at baseline; (B) left hydrocele noted at 1-month follow-up, measuring 12.7 mm; (C) left hydrocele persisted at 3-month follow-up, measuring 17.7 mm; (D) no hydrocele observed at 6-month follow-up, normal testicular tissue observed.

(Ct value = 23.7). However, his 35-mL urine sample showed 81 *S. haematobium* eggs and a negative POC-CCA test. Ultrasonography revealed a 12.7-mm left hydrocele. Praziquantel was given again.

At the 3-month follow-up, he complained of having had genital sores in the preceding month, although a venereal disease research laboratory serological test was negative for syphilis antibodies. His 160-mL urine sample contained 243 *S. haematobium* eggs, also being trace for protein and negative for POC-CCA test. In his 1-mL semen specimen, seven and four eggs were observed on bag and centrifugation methods, respectively, and was positive by real-time PCR (Ct value = 26.7). The left hydrocele was still present on genital ultrasonography (17.7 mm), and PZQ was provided again (Figure 1). At the 6-month follow-up, the only notable finding was a positive semen real-time PCR (Ct value = 32.3), although at 12 months, no abnormal results were observed, and real-time PCR was negative.

**Case 3.** SK, a 49-year-old man, 51.5 kg body weight, has lived along the lake since birth and has been fishing for the past 10 years. He had episodes of headache, dysuria, urine color changes, and blood in stool for over a month. He received PZQ in the past year during the annual MDA campaign.

His urine was of normal color with microhematuria (2+) and proteinuria (1+) but no leukocytes, and showed a negative POC-CCA test, and five *S. haematobium* eggs were observed after filtration. In his 4-mL semen specimen, two eggs and 12 leukocytes were observed using the bag method and three eggs after centrifugation. On ultrasonography, a calcified nodule in the left testis was noted (Figure 2).

Praziquantel was offered at this baseline presentation and at 1- and 3-month follow-up. No *S. haematobium* eggs were observed in urine or semen, and real-time PCR was negative, although ultrasonography showed mild bilateral hydroceles. After PZQ, he was lost to follow-up at 6- and 12-month time points.

**Case 4.** ARK, a 27-year-old man, 59 kg body weight, has been fishing daily in the lake for 5 years, where he bathes and washes his clothes regularly. He did not report any symptoms or receive PZQ during annual MDA campaigns.

His 110-mL urine sample was of normal color, and negative for leukocytes, protein, and POC-CCA, although the reagent strip test showed microhematuria (1+), and 12 *S. haematobium* eggs were observed. No eggs or leukocytes were observed on microscopy in his 2-mL semen specimen, although real-time PCR was positive (Ct value = 26.6). Ultrasonography was normal, and PZQ was given. At 1-month follow-up, where PZQ was given again, his semen remained

positive by real-time PCR (Ct value = 25.8), although no eggs were seen in the urine and ultrasonography was normal. At 3-month follow-up, 18 eggs were observed in an 80-mL urine sample and two eggs in a 2.5-mL semen specimen (centrifugation only), with positive real-time PCR (Ct value = 25.0) and abnormal bladder shape and mild wall thickness (5–10 mm) revealed on ultrasonography. Urine, semen, and ultrasonography results were normal at 6 months, with negative real-time PCR.

**Case 5.** TF, a 47-year-old man, 60.3 kg body weight, lives near the lake and has been fishing for 5 years, where he bathes and washes his clothes daily. He experienced dysuria, urine frequency, and urine color change for a month, and episodes of malaria, dysentery, worm infestation, and STI for that duration.

His urine was of normal color, and the reagent strip test detected proteinuria (2+) and microhematuria (3+); however, POC-CCA was negative, with no *S. haematobium* eggs detected. His 4-mL semen specimen revealed 11 eggs on microscopy after centrifugation and was positive by real-time PCR (Ct value = 29.7). Ultrasonography was normal, and PZQ was provided. At the 3-month follow-up, no *Schistosoma* eggs were detected in urine or semen, with his semen now negative by real-time PCR. However, ultrasonography revealed a mildly enlarged bladder wall and asymmetrical, enlarged seminal vesicles ( $\geq 15$  mm). Praziquantel was given

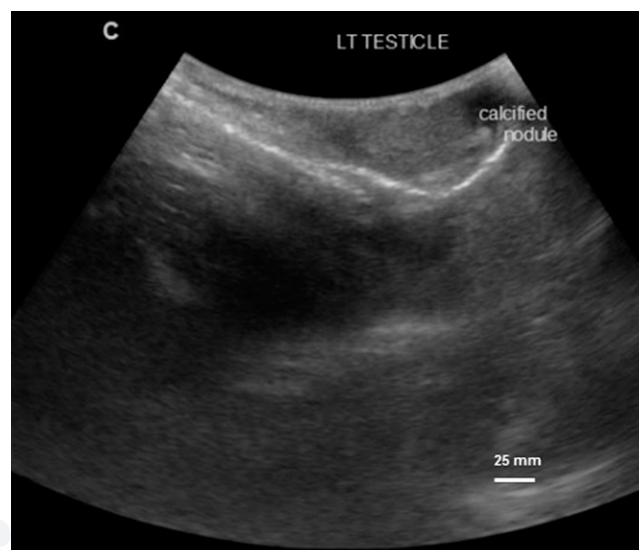


FIGURE 2. Ultrasonographic image showing genital abnormality, calcified nodule in the left testis for Case 3, observed baseline.

again, and he was lost to follow-up at 6- and 12-month time points.

## DISCUSSION

Schistosomiasis, a waterborne parasitic disease associated with poverty, is prevalent in many tropical and subtropical countries, especially those in sub-Saharan Africa (SSA). The disease afflicts over 200 million people worldwide, and in SSA, *S. haematobium* and *S. mansoni* occur, causing urogenital and intestinal schistosomiasis, respectively.<sup>5-7</sup> Male genital schistosomiasis is a gender-specific manifestation of urogenital schistosomiasis, being first reported in 1911<sup>8</sup> and associated with the presence of schistosome eggs and pathologies in genital fluids and organs. Features described include genital or ejaculatory pain, hemospemia, infertility, enlarged organs,<sup>9,10</sup> as well as abnormal organ enlargement, granulomatous infiltration, fibrosis, and calcifications on postmortem, histopathological, and radiological examinations.<sup>11-13</sup> Despite these descriptions and significant schistosomiasis burden in SSA, MGS often remains undiagnosed and underreported within endemic regions like the shoreline of Lake Malawi.<sup>14</sup> It is also of note that some of these men also have intestinal schistosomiasis as evidenced by the POC-CCA test, which is consistent with local emergence of

autochthonous transmission of *S. mansoni* in this part of the lake.<sup>15</sup>

To our knowledge, this case series from our longitudinal cohort study provides a unique description of MGS among local fishermen in an endemic setting of Lake Malawi shoreline in SSA. Our cases presented symptoms of MGS described in the literature, which can be mistaken for STI as in the example described in “Case 2,” and, thus, incorrectly received routine syndromic STI management,<sup>16</sup> highlighting the mistaken diagnosis and mismanagement of MGS treatable with PZQ.<sup>17,18</sup>

The changing clinical presentations and parasitological results of our cases highlight the challenges associated with MGS diagnosis and management, requiring the development of better, low-cost, accessible, sensitive, and specific diagnostic tests. Although real-time PCR demonstrates greater ability to incriminate most cases, it remains relatively expensive and not always available in endemic areas. The downward trend in egg count and clinical improvement of our cases after standard PZQ treatment at 1 month and later show parasitological clearance of eggs in semen and putative cure of the infection (Figure 3). Repeated or increased PZQ doses could be further beneficial in individual patient management when cases of high egg intensity infection are seen, for example, in “Case 2,” in addition to other prevention measures for schistosomiasis.

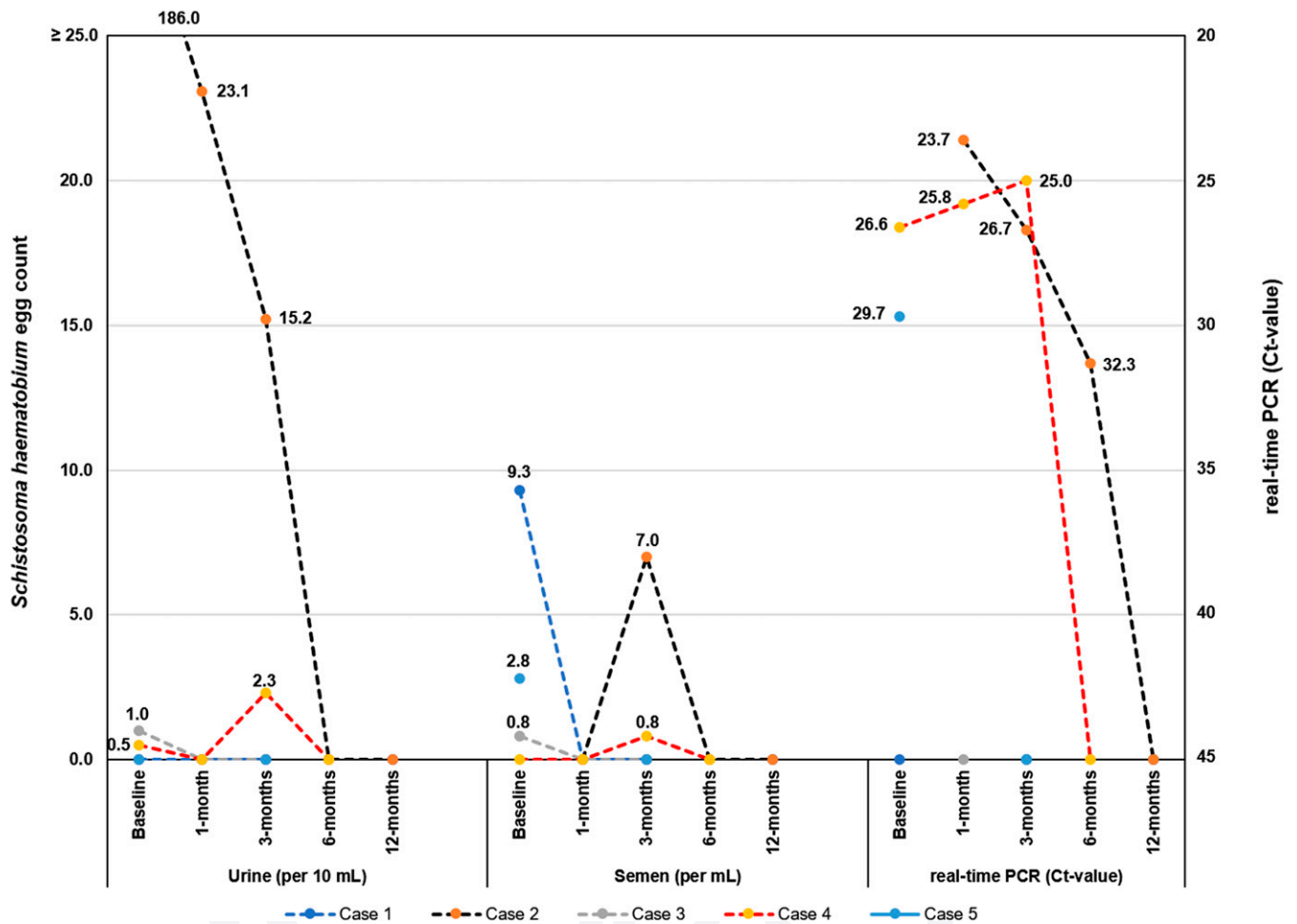


FIGURE 3. A line graph of the cases in the longitudinal cohort study showing results of *Schistosoma haematobium* egg counts in urine (per 10 mL) and semen (per mL), and Ct values for real-time polymerase chain reaction on semen at baseline, 1-, 3-, and 6-month follow-up studies. This figure appears in color at [www.ajtmh.org](http://www.ajtmh.org).

Furthermore, organ-specific pathologies in seminal vesicles, testes, and prostate alongside the urinary bladder, resulting from MGS, can be observed on ultrasonography. Encouragingly, these cases (Cases 2, 3, and 5) show a degree of some observed resolution after PZQ treatment. Comprehensive clinical assessment is essential to exclude other important diseases such as STI, tuberculosis, and malignancy which present similar symptomatology and pathologies as MGS.

Genital inflammation triggered by *Schistosoma* eggs has been shown to increase cytokine levels, such as interleukin-6 and tumor necrosis factor- $\alpha$ . These cytokines can facilitate HIV replication, resulting in increased seminal viral shedding, alluding to a plausible additional risk of HIV transmission from males infected with HIV and urogenital schistosomiasis.<sup>19–21</sup> Examples such as Case 2 describing the coinfection of these two diseases could in future provide opportunities for further virological and immunological analyses to illustrate the impact of routine preventive PZQ treatment on the potential risk of HIV transmission among dually infected fishermen and other high-risk populations in endemic areas. Furthermore, additional diagnostic investigations to exclude other diseases such as STIs, which could be present in this case, would be informative.

In conclusion, this case series better describes the occurrence of MGS among local fishermen from an area endemic for schistosomiasis along the shoreline of Lake Malawi where about just more than a fifth of all sampled men have active urogenital schistosomiasis. In Malawi, MGS has been under-reported and remains overlooked by many medical professionals, highlighting the challenges relating to awareness of MGS in both health professionals and men at risk alongside their health-seeking behaviors, point-of-contact diagnostic limitations, and clinical management strategies. It is very clear that targeted future research on MGS and its coexistence with other common diseases, such as HIV, is needed in endemic areas.

Received July 29, 2019. Accepted for publication September 11, 2019.

**Acknowledgments:** We thank the district health officer and management team of Mangochi District Health Services for their overwhelming support toward the study; Elizabeth Joeques for her assistance in training and quality control of the ultrasonography; Merck plc for donation of the portable ultrasound unit; Messrs Bright Mainga, Pilirani Mkambeni, Patrick Hussein, Mkonazi Nkhoma, Matthews Elias, and Boniface Injesi for technical assistance; and all the fishermen who participated in the longitudinal cohort study in Mangochi district. We are grateful to the head and staff of the laboratory department at Mangochi District Hospital; district ART coordinators, in-charge, and staff of Tikondane clinic; in-charges and staff of Billy Riordan Memorial Clinic; Monkey-Bay Community Hospital; Nkope and Koche Health Centres; Lumbua Katenda, Anwar, and staff of Mangochi LMJ clinic; local community health workers: Ambali Makochera, Alfred Kachikowa, Rodgers Wengawenga, Michael Tsatawe, Chikondi Mtsindula, Mambo Amin, Elias Matemba, Austin Kaluwa, Justin Mndala, Promise Mwawa, Dickson Tabu, George Matiki, Alfred Mdoka, and Charles Katandi; Brother Henry Chagoma and staff of Montfort Mission Guest House; and all traditional leaders in the hosting fishing communities and beach committee members for their enthusiasm and support during the study.

**Financial support:** S. A. K. was funded by a PhD scholarship from Commonwealth Scholarship Commission, United Kingdom, which supported the baseline and 1-month follow-up studies. He received an International Travel Fellowship from the British Society for Parasitology to conduct 3- and 6-month follow-up studies and from World

Friendship Charity to conduct 12-month follow-up studies. J. F. and A. S. were supported by LSTM Education Department MSc Degree Research Project Module funding.

**Authors' addresses:** Sekeleghe A. Kayuni, MASM Medi Clinics Limited, Medical Society of Malawi (MASM), Blantyre, Malawi, E-mail: seke.kayuni@lstmed.ac.uk. E. J. LaCourse, Joana Fawcett, Alexandra Shaw, Mohammad Alharbi, and J. Russell Stothard, Department of Parasitology, Liverpool School of Tropical Medicine, Liverpool, United Kingdom, E-mails: james.lacourse@lstmed.ac.uk, joanna.fawcett@hotmail.co.uk, alexandrashaw100@gmail.com, mohammad.alharbi@lstmed.ac.uk, and russell.stothard@lstmed.ac.uk. Peter Makaula, Research for Health Environment and Development (RHED), Mangochi, Malawi, E-mail: petmakau@yahoo.co.uk. Fanuel Lampiao, Physiology Department, College of Medicine, University of Malawi, Blantyre, Malawi, E-mail: flampiao@medcol.mw. Lazarus Juziwelo, National Schistosomiasis and STH Control Program, Community Health Sciences Unit, Ministry of Health, Lilongwe, Malawi, E-mail: juziwelol@gmail.com. Jaco J. Verweij, Elisabeth Hospital Tilburg, Laboratory for Medical Microbiology and Immunology, Tilburg, The Netherlands, E-mail: j.verweij@etz.nl.

## REFERENCES

- Cheesbrough M, 2009. *District Laboratory Practice in Tropical Countries, Part 1*, 2nd edition. Cambridge, United Kingdom: Cambridge University Press.
- WHO, 2010. *WHO Laboratory Manual for the Examination and Processing of Human Semen*, 5th edition. Geneva, Switzerland: World Health Organization.
- Kayuni SA et al., 2019. How can schistosome circulating antigen assays be best applied for diagnosing male genital schistosomiasis (MGS): an appraisal using exemplar MGS cases from a longitudinal cohort study among fishermen on the south shoreline of Lake Malawi. *Parasitology*: 1–37.
- Kenguele HM, Adegnika AA, Nkoma AM, Ateba-Ngoa U, Mbong M, Zinsou J, Lell B, Verweij JJ, 2014. Impact of short-time urine freezing on the sensitivity of an established *Schistosoma* real-time PCR assay. *Am J Trop Med Hyg* 90: 1153–1155.
- Colley DG, Bustinduy AL, Secor WE, King CH, 2014. Human schistosomiasis. *Lancet* 383: 2253–2264.
- McManus DP, Dunne DW, Sacko M, Utzinger J, Vennervald BJ, Zhou X-N, 2018. Schistosomiasis. *Nat Rev Dis Primers* 4: 13.
- WHO, 2018. *Schistosomiasis*. Available at: <http://www.who.int/en/news-room/fact-sheets/detail/schistosomiasis>. Accessed December 29, 2018.
- Madden FC, 1911. Two rare manifestations of bilharziosis. *Lancet* 178: 754–755.
- Farrar J, Hotez PJ, Junghanss T, Kang G, Lalloo D, White NJ, 2014. *Manson's Tropical Diseases*. Elsevier Health Sciences.
- Kayuni S, Lampiao F, Makaula P, Juziwelo L, Lacourse EJ, Reinhard-Rupp J, Leutscher PDC, Stothard JR, 2019. A systematic review with epidemiological update of male genital schistosomiasis (MGS): a call for integrated case management across the health system in sub-Saharan Africa. *Parasite Epidemiol Control* 4: e00077.
- Gelfand M, Ross CMD, Blair DM, Castle WM, Webber MC, 1970. Schistosomiasis of the male pelvic organs: severity of infection as determined by digestion of tissue and histologic methods in 300 cadavers. *Am J Trop Med Hyg* 19: 779–784.
- Leutscher P, Ramarokoto C-E, Reimert C, Feldmeier H, Esterre P, Vennervald BJ, 2000. Community-based study of genital schistosomiasis in men from Madagascar. *Lancet* 355: 117–118.
- Vilana R, Corachan M, Gascon J, Valls E, Bru C, 1997. Schistosomiasis of the male genital tract: transrectal sonographic findings. *J Urol* 158: 1491–1493.
- Makaula P, Sadalaki JR, Muula AS, Kayuni S, Jemu S, Bloch P, 2014. Schistosomiasis in Malawi: a systematic review. *Parasit Vectors* 7: 20.
- Alharbi MH, Condemine C, Christiansen R, LaCourse EJ, Makaula P, Stanton MC, Juziwelo L, Kayuni S, Stothard JR, 2019. *Biomphalaria pfeifferi* snails and intestinal schistosomiasis, lake Malawi, Africa, 2017–2018. *Emerg Infect Dis* 25: 613–615.

16. WHO, 2003. *Guidelines for the Management of Sexually Transmitted Infections*. Geneva, Switzerland: World Health Organization.
17. Leutscher PDC, Ramarokoto CE, Hoffmann S, Jensen JS, Ramaniraka V, Randrianasolo B, Raharisolo C, Migliani R, Christensen N, 2008. Coexistence of urogenital schistosomiasis and sexually transmitted infection in women and men living in an area where *Schistosoma haematobium* is endemic. *Clin Infect Dis* 47: 775–782.
18. Yirenya-Tawiah DR, Ackumey MM, Bosompem KM, 2016. Knowledge and awareness of genital involvement and reproductive health consequences of urogenital schistosomiasis in endemic communities in Ghana: a cross-sectional study. *Reprod Health* 13: 117.
19. Leutscher PDC, Pedersen M, Raharisolo C, Jensen JS, Hoffmann S, Lisse I, Ostrowski SR, Reimert CM, Mauciere P, Ullum H, 2005. Increased prevalence of leukocytes and elevated cytokine levels in semen from *Schistosoma haematobium*-infected individuals. *J Infect Dis* 191: 1639–1647.
20. Stecher CW, Kallestrup P, Kjetland EF, Vennervald B, Petersen E, 2015. Considering treatment of male genital schistosomiasis as a tool for future HIV prevention: a systematic review. *Int J Public Health* 60: 839–848.
21. Midzi N, Mduluzi T, Mudenge B, Foldager L, Leutscher PDC, 2017. Decrease in seminal HIV-1 RNA load after praziquantel treatment of urogenital schistosomiasis coinfection in HIV-positive men—an observational study. *Open Forum Infect Dis* 4: ofx199.