

METHOTREXATE-ASSOCIATED BIOCHEMICAL ALTERATIONS IN A PATIENT WITH CHRONIC NEUROTOXICITY

BIOHEMIJSKE PROMENE POVEZANE SA PRIMENOM METOTREKSATA KOD PACIJENTA SA HRONIČNOM NEUROTOKSIČNOSTI

Sandra Vezmar^{1,2}, Udo Bode³, Ulrich Jaehde¹

¹Institute of Pharmacy, Department of Clinical Pharmacy, University of Bonn, Germany

²Institute of Pharmacokinetics, Faculty of Pharmacy, University of Belgrade, Serbia

³Children's Hospital, Department of Paediatric Haematology and Oncology, University of Bonn, Germany

Summary: Intrathecal and/or high-dose intravenous administration of methotrexate (MTX) in the treatment of malignancies such as acute lymphoblastic leukaemia (ALL) has been associated with cases of mild to severe neurotoxicity. The pathogenic mechanism of neurotoxicity is not clear, possibly MTX-associated biochemical alterations of the folate and methyl-transfer metabolic pathways play an important role. We report a case of an adult patient treated for ALL relapse with signs of chronic leukoencephalopathy associated with MTX administration. In order to assess alterations in the folate and methyl-transfer pathway we determined 5-methyltetrahydrofolate (5-methyl-THF), S-adenosylmethionine (SAM) and S-adenosylhomocysteine (SAH) in the cerebrospinal fluid (CSF) of the patient. Three CSF samples were obtained by lumbar puncture within a four-month period. Concentrations of the metabolites were measured using validated bioanalytical methods based on HPLC with UV and fluorescence detection. The results showed two-fold lower 5-methyl-THF levels (29.3–31.8 nmol/L) in all obtained samples compared to reference values. SAM concentrations were even more than five-fold lower in two samples (5–34.2 nmol/L). SAH concentrations were in the range 7.5–14.3 nmol/L. Our patient had pronounced alterations in the folate and methyl-transfer pathway which indicate that MTX-associated biochemical alterations of these pathways may play an important role in the development of leukoencephalopathy.

Keywords: methotrexate, CSF, 5-methyltetrahydrofolate, S-adenosylmethionine, neurotoxicity

Kratak sadržaj: Primena metotreksata (MTX) u visokim dozama i/ili intratekalno u terapiji malignih oboljenja poput akutne limfoblastične leukemije (ALL) povezana je sa pojavom blagih ili teških oblika neurotoksičnosti. Patogeneza neurotoksičnosti nije u potpunosti razjašnjena, ali se važna uloga pripisuje biohemijskim promenama folatnog i metil-transfernog metaboličkog puta za koje se smatra da su uzrokovane dejstvom MTX. Opisujemo slučaj odrasle pacijentkinje na terapiji recidiva ALL sa simptomima hronične leukoencefalopatije najverovatnije uzrokovane primenom MTX. U cilju procene folatnog i metil-transfernog puta u cerebrospinalnoj tečnosti (CST) pacijentkinje merene su koncentracije 5-metiltetrahydrofolata (5-metil-THF), S-adenozilmetionina (SAM) i S-adenozilhomocisteina (SAH). Tri uzorka CST su dobijena lumbalnom punkcijom u periodu od četiri meseca. Koncentracije su merene pomoću validiranih bioanalitičkih metoda zasnovanih na primeni HPLC sa ultraljubičastom i fluorescentnom detekcijom. Rezultati su pokazali dvostruko sniženje koncentracije 5-metil-THF (29.3–31.8 nmol/L) u poređenju sa referentnim vrednostima u svim uzorcima, dok su koncentracije SAM bile pet puta manje u dva uzorka (5–34.2 nmol/L). Koncentracije SAH su bile u rasponu 7.5–14.3 nmol/L. Naša pacijentkinja je imala izražene promene u folatnom i metil-transfernom metaboličkom putu koje ukazuju na to da biohemijske promene ovih metaboličkih puteva za koje se smatra da su uzrokovane dejstvom MTX mogu igrati važnu ulogu u razvoju leukoencefalopatije.

Ključne reči: metotreksat, cerebrospinalna tečnost, 5-metiltetrahydrofolat, S-adenozilmetionin, neurotoksičnost

Address for correspondence:

Prof. Dr. Ulrich Jaehde
Institute of Pharmacy, Department of Clinical Pharmacy
University of Bonn, An der Immenburg 4
D-53121 Bonn, Germany
Phone: +49-228-73-5252; Fax: +49-228-73-9757
e-mail: u.jaehde@uni-bonn.de

Abbreviations: ALL – acute lymphoblastic leukemia; ATP – adenosine triphosphate; CNS – central nervous system; CSF – cerebrospinal fluid; CTC – common toxicity criteria; DHF – dihydrofolate; FDA – food and drug administration; HPLC – high-performance liquid chromatography; MRI – magnetic resonance imaging MTX – methotrexate; PCNSL – primary central nervous system lymphoma; SAH – S-adenosylhomocysteine; SAM – S-adenosylmethionine; THF – tetrahydrofolate; UV – ultraviolet

Case report

Intrathecal and/or high-dose ($>1 \text{ g/m}^2$) administration of methotrexate has been associated with neurotoxicity (1, 2), which in terms of severity ranges from mild and reversible to severe with possible fatal outcome (3). According to time of appearance, neurotoxicity is classified as acute, subacute and chronic. Clinical signs of chronic neurotoxicity may appear months to years following MTX administration (4). This form of neurotoxicity, although rare, is usually severe, characterized by leukoencephalopathy, demyelination, loss of cerebral parenchyma (4, 5) and clinical signs such as personality changes, progressive dementia, focal seizures, spastic quadriparesis and stupor (4). Patients may also develop learning disability, cognitive disturbances and decrease in intelligence (6, 7). Chronic MTX-associated neurotoxicity may resolve partially or fully, but it may also persist and even progress to coma and death (8, 9).

The pathogenic mechanisms of MTX-associated neurotoxicity are not fully elucidated yet (10). It was suggested that MTX-induced biochemical alterations may play an important role in the development of neurological complications (11).

MTX as an antifolate targets primarily the folate pathway (see *Figure 1*) inducing the depletion of the pool of tetrahydrofolates (THF). Accordingly, decreased levels of 5-methyl-THF were reported in the CSF of patients who received high-dose or intraventricular MTX (11, 12). However, the mechanism by which folate depletion could induce neurotoxicity is unclear. It is possible that other metabolic pathways which are altered as a consequence of folate impairment may be responsible for clinical signs of neurotoxicity.

The folate metabolic pathway is directly linked to the homocysteine-methionine conversion through 5-methyl-THF. The lack of methionine leads to a deple-

tion of the main methyl-donor S-adenosylmethionine (SAM). SAM together with the methyl-transferase inhibitor S-adenosylhomocysteine (SAH) forms the methyl-transfer pathway which is necessary for methylation and synthesis of the myelin sheath. Loss of myelin disables the normal neuronal function which could further lead to the development of cognitive decline. Since severe demyelination and white matter changes are main features of chronic MTX-associated neurotoxicity, an impairment of the methyl-transfer pathway may be involved in its pathogenesis. Moreover, decreased SAM levels in the CSF were associated with demyelination reported in patients with MTX-related subclinical and clinical leukoencephalopathy (13, 14). Furthermore, it was suggested that the SAM/SAH ratio may be a better marker for leukoencephalopathy than SAM alone (15). We report a case of a patient suffering from chronic MTX-associated neurotoxicity presenting with leukoencephalopathy, manifest signs of cognitive disorder and personality change with a severe impairment of the folate and methyl-transfer pathway.

Our patient was a 35-year old female with ALL which was first diagnosed at the age of 17. At that time she was treated with high-dose MTX accompanied by cranial irradiation. At the age of 27, the first relapse occurred and the patient was treated with high-dose MTX (1 g/m^2) and intrathecal MTX (12 mg) without cranial irradiation. A total of nine high-dose infusions and 60 mg intrathecal MTX were administered. At that time no MTX-associated neurological complications were observed. At the age of 35, she presented with the second relapse and started receiving treatment which did not include MTX. However, at this time-point, cognitive decline, memory loss, confusion, depressed level of consciousness, personality change, speech impairment and tremor were evident. The evaluation of neurotoxicity was performed according to Common Toxicity Criteria (CTC) and the results are presented in *Table 1*. Magnetic resonance imaging (MRI) revealed severe leukoencephalopathy in both brain hemispheres. Circular lesions were also present, however, associated with an overt infection.

According to a previously obtained approval of the local ethics committee we were able to obtain CSF samples when lumbar puncture was performed diagnostically or due to the treatment protocol. Three CSF samples were obtained within four months. The third sample was obtained when the patient presented with signs of toxicity probably due to a CNS infection. She had severe headache and pain followed by high fever. The CSF was yellow coloured indicating hyperbilirubinemia which was later confirmed.

In order to assess the folate pathway, 5-methyl-THF was determined using a modified method by Belz et al. (16) based on reversed-phase HPLC with simultaneous UV and fluorescence detection. Methanol was used for elution instead of acetonitrile. In brief, a SupelcosilTM column (15 x 0.46 cm, 3 μm) and a SupelguardTM precolumn (2 x 0.46 cm, 5 μm) both

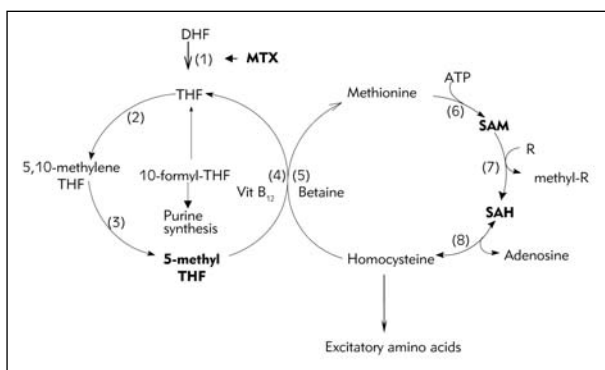


Figure 1 Metabolism of folates and methyl-transfer pathway.

Abbreviations: ATP: adenosine triphosphate; DHF: dihydrofolate; SAH: S-adenosylhomocysteine; SAM: S-adenosylmethionine; THF: tetrahydrofolate; (1) dihydrofolate reductase; (2) serine-hydroxymethyltransferase; (3) 5,10-methylenetetrahydrofolate reductase; (4) methionine synthase; (5) betaine-homocysteine methyltransferase; (6) methionine adenosyltransferase; (7) R-methyltransferase; (8) SAH hydrolase

Table I CTC evaluation of neurotoxicity symptoms in the patient with chronic neurotoxicity.

Symptom	Grade	Description of severity according to CTC
Ataxia (incoordination)	3	Moderate symptoms interfering with activities of daily living
Cognitive disturbance	3	Cognitive disability resulting in significant impairment of work performance; cognitive decline > 2 SD*
Confusion	3	Confusion or delirium interfering with activities of daily living
Depressed level of consciousness	3	Obtundation or stupor; difficult to arouse; interfering with activities of daily living
Irritability	1	Mild, easily consolable
Leukoencephalopathy-associated radiological findings	2	Moderate ventriculomegaly; and/or focal T2 hyperintensities extending into centrum ovale; or involving 1/3 to 2/3 of susceptible areas of cerebrum
Memory loss	2	Interfering with function but not with activities of daily living
Mood alteration	1	Mild mood alteration not interfering with function
Depression	2	Interfering with function but not with activities of daily living
Neuropathic pain	3	Severe pain
Personality change	2	Change but not disruptive to patient or family
Speech impairment	2	Awareness of receptive or expressive dysphasia, not impairing the ability to communicate
Tremor	2	Moderate tremor, interfering with daily function but not interfering with activities of daily living

* SD: standard deviation

Table II CSF analysis of 5-methyl-THF, SAM and SAH in the neurotoxic patient and PCNSL patients with and without neurotoxicity.

Sample	Concentration (nmol/L)		
	5-methyl-THF	SAM	SAH
Present case report with chronic neurotoxicity	31.8	Below quantification limit	10.1
	31.7	34.2	7.5
	29.3	184.5	14.3
PCNSL patient with chronic neurotoxicity	13.5–22.7	34.1–54.7	5.7–11.2
PCNSL patients without neurotoxicity	59.2–91.5	182.4–966.6	5.1–11.0

from Supelco (Bellefonte, USA) were used as stationary phase. The HPLC system was from Thermo Separation Products, Inc (Egelsbach, Germany). Fifty μ L samples were injected onto the HPLC system and separated by gradient elution which consisted of methanol and phosphate buffer (10 mmol/L, pH 2.1). Fluorescence detection (294/356 nm) was used, flow rate was 1 mL/min, retention time was 8.8 min. The method was validated according to the FDA Guideline (17). Due to the instability of reduced folates, CSF samples were collected in vials containing an ascorbic acid solution (5 mg/mL).

Determination of SAM and SAH in the CSF was performed using HPLC with fluorescence detection. An

EclipseTM AAA column (15 x 0.46 cm, 5 μ m) from Agilent Technologies Inc., (Palo Alto, USA), and a NucleosilTM precolumn (2 x 0.46 cm, 5 μ m) from Supelco (Bellefonte, USA) were used as stationary phase. Fluorescence detection of SAM and SAH was enabled by derivatisation with 5.5 mol/L chloroacetaldehyde at pH 3.5–4.0, 39 °C for 16 h as described by Wagner et al. (18). The formed 1,N⁶-etheno derivatives were eluted on a reversed phase column especially designed for separation of amino acids. Mobile phase consisted of acetonitrile and an aqueous solution (pH 4.5) containing 40 mmol/L of potassium dihydrogen phosphate and 8 mmol/L of the ion-pair reagent 1-heptanesulfonic acid. Analytes were separated by gradient elution. The injection volume was 100 μ L, at a con-

stant flow rate of 1 mL/min and detection at 270/410 nm. Retention times were 19.7 and 23.5 min for SAH and SAM, respectively. Five hundred μ L of CSF were collected with 100 μ L of perchloric acid 1.2 mol/L used to provide precipitation of proteins and to ensure stability of the compounds. Samples were centrifuged for 10 min at 15 500 \times g and frozen at -20°C . The method was validated according to the FDA Guideline for bioanalytical methods (17).

CSF concentrations of 5-methyl-THF, SAM and SAH of the patient with chronic neurotoxicity are presented in *Table II*. Our patient had approximately two-fold lower CSF 5-methyl-THF concentrations compared to normal CSF levels according to literature data (19, 20). Moreover, we previously reported CSF 5-methyl-THF concentrations in adult patients with primary central nervous system lymphoma (PCNSL) treated with high-dose and intrathecal MTX (21). Our ALL patient with chronic neurotoxicity had considerably lower CSF 5-methyl-THF concentrations compared to PCNSL patients without neurotoxicity (see *Table II*). Furthermore, in the PCNSL population we had a patient with signs of chronic neurotoxicity and leukoencephalopathy with massive demyelination revealed by MRI. Low 5-methyl-THF concentrations similar to those found in the present case were observed in this patient as well (*Table II*).

CSF SAM concentrations were at least five-fold lower in two out of three samples compared to literature reference data (22). In the last sample the level of SAM was rather high compared to the two previous measurements. However, at that time-point the patient exhibited hyperbilirubinemia and the CSF sample was intensively yellow coloured. It cannot be excluded that

there was an interference with the fluorescence determination of SAM.

CSF SAM levels in the first two samples of our present patient were also considerably lower compared to PCNSL patients without neurotoxicity. Moreover, present findings are similar to CSF SAM levels in the PCNSL patient at the time of chronic neurotoxicity. In contrast, CSF SAH levels in our patient were similar to those of PCNSL patients where the level of the methyl-transferase inhibitor ranged from 5.1–11.0 nmol/L (21). Kishi et al. (15) also reported two cases with chronic neurotoxicity who had low CSF SAM levels (74.8 and 79.3 nmol/L respectively). However, in contrast to our findings, these authors also reported increased SAH levels (27.5–34.3 nmol/L).

In conclusion, a severe biochemical alteration of the folate and methyl-transfer pathways was observed in an ALL patient with chronic MTX-associated neurotoxicity. Since SAM is the most important methyl-donor, the impairment of the methyl-transfer pathway which resulted in more-fold decreased CSF SAM levels could have played a crucial role in the pathogenesis of leukoencephalopathy. Further research is necessary to establish if monitoring of the 5-methyl-THF and SAM in the CSF may help predict patients at risk of developing signs of chronic neurotoxicity. Moreover, if the impairment of the methyl-transfer pathway is responsible for demyelination, then substitutional therapy with SAM may represent an option for preventing neuronal damage and its consequences.

Acknowledgment. This work was supported by a grant of the German Academic Exchange Service (DAAD) for Sandra Vezmar. Their help and collaboration is very much appreciated.

References

- Walker RW, Allen JC, Rosen G, Caparros B. Transient cerebral dysfunction secondary to high-dose methotrexate. *J Clin Oncol* 1986; 4: 1845–50.
- García-Tena J, López-Andreu JA, Ferris J, Menor F, Mulas F, Millet E, et al. Intrathecal chemotherapy-related myeloencephalopathy in a young child with acute lymphoblastic leukemia. *Pediatr Hematol Oncol* 1995; 12: 377–85.
- Oka M, Terae S, Kobayashi R, Sawamura Y, Kudoh K, Tha KK, et al. MRI in methotrexate-related leukoencephalopathy: Disseminated necrotising leukoencephalopathy in comparison with mild leukoencephalopathy. *Neuroradiology* 2003; 45: 493–7.
- Allen JC, Rosen G, Mehta BM, Horten B. Leukoencephalopathy following high-dose iv methotrexate chemotherapy with leucovorin rescue. *Cancer Treat Rep* 1980; 64: 1261–73.
- Meadows AT, Evans AE. Effects of chemotherapy on the central nervous system. A study of parenteral methotrexate in long-term survivors of leukemia and lymphoma in childhood. *Cancer* 1976; 37: 1079–85.
- Ochs J, Mulhern R, Fairclough D, Parvey L, Whitaker J, Chien L, et al. Comparison of neuropsychologic functioning and clinical indicators of neurotoxicity in long-term survivors of childhood leukemia given cranial radiation or parenteral methotrexate: a prospective study. *J Clin Oncol* 1991; 9: 145–51.
- Paakko E, Harila-Saari A, Vanionpaa L, Himanen S, Pyhtinen J, Lanning M. White matter changes on MRI during treatment in children with acute lymphoblastic leukemia: Correlation with neuropsychological findings. *Med Pediatr Oncol* 2000; 35: 456–61.
- Bleyer WA, Drake JC, Chabner BA. Neurotoxicity and elevated cerebrospinal-fluid methotrexate concentration in meningeal leukemia. *N Engl J Med* 1973; 289: 770–3.

9. Colamaria V, Caraballo R, Borgna-Pignatti C, Marradi P, Balter R, Mazza C, et al. Transient focal leukoencephalopathy following intraventricular methotrexate and cytarabine. A complication of the Ommaya reservoir: case report and review of the literature. *Childs Nerv Syst* 1990; 6: 231–5.
10. Vezmar S, Becker A, Bode U, Jaehde U. Biochemical and clinical aspects of methotrexate neurotoxicity. *Chemotherapy* 2003; 49: 92–104.
11. Quinn CT, Griener JC, Bottiglieri T, Hyland K, Farrow A, Kamen BA. Elevation of homocysteine and excitatory amino acid neurotransmitters in the CSF of children who receive methotrexate for the treatment of cancer. *J Clin Oncol* 1997; 15: 2800–6.
12. Quinn CT, Griener JC, Bottiglieri T, Arning E, Winick NJ. Effects of intraventricular methotrexate on folate, adenosine, and homocysteine metabolism in cerebrospinal fluid. *J Pediatr Hematol Oncol* 2004; 26: 386–8.
13. Hyland K, Smith I, Bottiglieri T, Perry J, Wendel U, Clayton PT, et al. Demyelination and decreased S-adenosylmethionine in 5,10-methylenetetrahydrofolate reductase deficiency. *Neurology* 1988; 38: 459–62.
14. Surtees R, Clelland J, Hann I. Demyelination and single-carbon transfer pathway metabolites during the treatment of acute lymphoblastic leukemia: CSF studies. *J Clin Oncol* 1998; 16: 1505–11.
15. Kishi T, Tanaka Y, Ueda K. Evidence for hypomethylation in two children with acute lymphoblastic leukemia and leukoencephalopathy. *Cancer* 2000; 89: 925–31.
16. Belz S, Frickel C, Wolfrom C, Nau H, Henze G. High-performance liquid chromatographic determination of methotrexate, 7-hydroxymethotrexate, 5-methyltetrahydrofolic acid and folinic acid in serum and cerebrospinal fluid. *J Chromatogr B* 1994; 661: 109–18.
17. US Department of Health and Human Services, Food and Drug Administration. *Guidance for Industry: Bio-analytical Method Validation*. 2001.
18. Wagner J, Hirth Y, Clavierie N, Danzin C. A sensitive high-performance liquid chromatographic procedure with fluorometric detection for the analysis of decarboxylated S-adenosylmethionine and analogs in urine samples. *Anal Biochem* 1986; 154: 604–17.
19. Surtees R, Hyland K. Cerebrospinal fluid concentrations of S-adenosylmethionine, methionine, and 5-methyltetrahydrofolate in a reference population: cerebrospinal fluid S-adenosylmethionine declines with age in humans. *Biochem Med Metab Biol* 1990; 44: 192–9.
20. Reynolds EH, Gallagher BB, Mattson RH, Bowers M, Johnson AL. Relationship between serum and cerebrospinal fluid folate. *Nature* 1972; 240: 155–7.
21. Becker A, Vezmar S, Linnebank M, Pels H, Bode U, Schlegel U, et al. Marked elevation of homocysteine and homocysteine sulfinic acid in the cerebrospinal fluid of lymphoma patients receiving intensive treatment with methotrexate. *Int J Clin Pharmacol Ther* 2007; 45: 504–15.
22. Struys EA, Jansen EEW, De Meer K, Jakobs C. Determination of S-adenosylmethionine and S-adenosylhomocysteine in plasma and cerebrospinal fluid by stable-isotope dilution tandem mass spectrometry. *Clin Chem* 2002; 46: 1650–61.

Received: September 16, 2008

Accepted: December 12, 2008