

Arh.farm 2004;54: 761 – 771

Naučni rad

IMMUNOMODULATION OF EXPERIMENTAL AUTOIMMUNE MYOCARDITIS BY PENTOXIFYLLINE

MARINA MILENKOVIĆ¹, PETAR MILOSAVLJEVIĆ²,
ZORICA STOJIĆ VUKANIĆ¹, MIROSLAVA DIMITRIJEVIĆ¹,
MIODRAG ČOLIĆ²

¹ *Department of Microbiology and Immunology, Faculty of Pharmacy, Vojvode Stepe 450,
Belgrade*

² *Institute for Medical Research, MMA, Belgrade*

Abstract

We designed the present study to provide evidence of the immunomodulatory effects of pentoxifylline (PTX) in experimental autoimmune myocarditis (EAM) in rats. PTX is xantine-derived agent known to inhibit the production of TNF- α and his beneficial effects have been reported in patients with dilated cardiomyopathy. In this study we examined the efficacy of PTX in the treatment of experimental autoimmune myocarditis as a paradigm of the autoimmune mechanisms involved in pathogenesis of dilated cardiomyopathy. Male DA rats immunized with porcine cardiac myosin were treated i.m. with PTX (200 mg/kg/day) over 7 days, beginning either on the day of immunization (early treatment group), or on day 14. postimmunization (late treatment group). Disease course and severity were evaluated by macroscopic score of the heart, heart weight/body weight ratio (Hw/Bw), histological and immunohistochemical analysis of cardiac tissue. We found in our study that PTX exhibited both preventive and therapeutical effects in EAM.

Keywords: cardiac myosine, autoimmune myocarditis,
pentoxifylline.

Introduction

Inflammatory heart disease caused by Coxsackieviruses belongs to the most frequent cardiac complications of this infection in adults. Although there is no doubt that the virus damages cardiomyocytes directly, there is compelling evidence from clinical studies, and particularly, from a variety of murine models, suggesting that the tissue injury is primarily mediated by autoimmune mechanisms (1, 2, 5).

Immunization with cardiac myosin induces severe myocarditis in genetically predisposed animals. Cardiac myosin-induced myocarditis offers a virus-free system with a defined autoantigen and possibility to study autoimmune mechanisms in postviral heart disease. The disease closely parallels with human one seen after infection with Coxsackievirus B3 and is characterized by enlargement of the heart, marked cellular infiltration consisting of mononuclear cells, neutrophils, fibroblasts and multinucleated giant cells. Extensive myocardial necrosis is also present (4,12,13).

There is accumulating evidence supporting the view that proinflammatory cytokines play a crucial role in the pathogenesis of viral myocarditis and dilated cardiomyopathy. Okura and his collaborators have demonstrated that cytokines relating to inflammation are involved in the induction and resolution of EAM.

Th1 type cytokines (IL-2 and IFN- γ) and proinflammatory cytokines (IL-1 and TNF- α) have been detected only in the inflammatory phase, while the production of a Th2 cytokines has been found in the recovery phase (4). Smith and his collaborators have demonstrated that anti-TNF- α antibody reduced severity of EAM and suggested that TNF- α is an important early mediator in the pathogenesis of inflammation (19).

In the present study the immunomodulatory potential of pentoxifylline was investigated in EAM. Pentoxifylline (3,7-dimethyl-1-(5-oxohexyl) xantine) a phosphodiesterase inhibitor, is a widely used vasoactive drug with proven clinical efficacy in microcirculatory disorders (21, 22, 23). Recently the potential use of PTX as an antiinflammatory drug has gained increasing interest because *in vitro* and *in vivo* studies have shown that PTX suppresses or reduces the production of TNF- α (24). Inhibitory effect of PTX on TNF- α production is exerted at the transcriptional level, by elevating the

intracellular level of second messenger cAMP (18, 20). It has been shown that PTX *in vitro* could suppress T-cell proliferation and production of TNF- α and IFN- γ (20).

It has been reported that PTX can inhibit the onset or severity of organ-specific autoimmune diseases such as experimental autoimmune encephalomyelitis (18).

In recent years, the potential use of PTX as an antiinflammatory drug has gained increasing interest because *in vitro* and *in vivo* studies have shown that PTX suppresses or reduces the production of TNF- α , and has beneficial effects in disorders such as graft-versus-host disease, cerebral malaria and acute hepatitis, in which TNF- α has an important role (11).

Materials and methods

Immunization and treatment

Male 8-week-old DA rats were bred and maintained at the Animal house of Military Medical Academy, Belgrade. Rats were immunized subcutaneously with 5 mg/kg of porcine cardiac myosine (Sigma, St Louis, MO, USA) emulsified with an equal volume of complete Freund's adjuvant supplemented with (0.1mg/0.1ml) *Mycobacterium tuberculosis* H37RA (Difco). Pentoxifylline (Pharma-Synthesis Department, Hoechst, Wiesbaden, Germany) was administered i.m. at a dose of 200 mg/kg either during the first 6 days (early treatment group), or starting from 14 and ending at day 20 after disease induction (late treatment). Control animals received equal volume of saline during the same periods. Efficacy of PTX treatment was determined on day 21 of EAM development.

Macroscopic findings and histological analysis

All rats were sacrificed under ether anesthesia and disease severity was evaluated by macroscopic findings of the hearts, heart weight / body weight (Hwt/Bwt) ratio, as well as by histological and immunohistochemical analysis. Macroscopic findings were scored as follows: 0-normal finding; 1-presence of focal discolored area on the cardiac surface; 2-presence of diffuse discolored areas not exceeding a total of one-third of the cardiac surface; 3-diffuse discolored areas totaling more than one-third of the cardiac surface. For microscopic grading, transverse sections through the middle of the heart were fixed in 10% buffered

formalin and embedded in paraffin according to the conventional procedure. Paraffin-embedded tissues were cut (5 μm in thickness) and stained with hematoxylin-eosin for histological examination. The severity of myocarditis was classified into 4 grades: 0, no inflammation; 1, histological cross section infiltrated up to 5%; 2, 5-10% infiltrates/section; 3, 10-20% infiltrates/section; 4, more than 20% infiltrates/section. The presence of multinucleated giant cells did not influence microscopic score.

Immunohistochemical analysis

For immunohistochemical staining heart samples were embedded in OCT (optimal cutting temperature) compound (Miles, Elkhart, IN) and rapidly frozen. Cryostat sections were cut sequentially at 7 μm in thickness, mounted on glass slides and prepared for immunoperoxidase and immunoalkaline phosphatase staining. Sections were fixed in cold acetone for 10 min. and extensively washed in 0.1 M Tris buffer solution (pH 7.6). Murine monoclonal antibodies specific for different rat molecules (Table I) were added at appropriate concentrations in sufficient amount to cover the sections. After incubation at 4°C overnight and further buffer washes, the sections were incubated with peroxidase-conjugated rabbit anti-mouse immunoglobulins (P0161, Dako, Denmark) for 60 min. Peroxidase reaction was visualized with 0.05% diaminobenzidine (DAB) in 0.01% H_2O_2 for 6-8 min. The color development was stopped by washing slides in running water. Some cryostat sections were stained by alkaline phosphatase method. After incubation with appropriate mouse anti-rat monoclonal antibodies, sections were incubated with rabbit anti-mouse immunoglobulins (Z0109, Dako, Denmark) for 60 min. at room temperature, washed and additionally incubated with APAAP (D651, Dako, Denmark) for 40 min. The alkaline phosphatase reaction was visualized by naphthol substrate containing naphthol phosphate, dimethyl formamide, 0.1M Tris pH 8.2, 1M levamisole and fast red. All samples were lightly counterstained with hematoxylin, mounted in gelatine/glycerol medium and assessed by light microscopy.

Table I Murine monoclonal antibodies specific for rat antigens
Tabela I Monoklonska antitela specifična za različite antigene
 ćelija pacova

Antibody /isotype	Specificity	Source
R73 (G1)	TCR _{αβ}	Serotec, UK
W3/25 (G1)	CD4	Serotec, UK
OX-8(G1)	CD8	Serotec, UK
WT.1 (G2a)	CD11a	Serotec, UK
OX-42 (G2a)	CD11b	Serotec, UK
WT.3 (G1)	CD18	Serotec, UK
1A.29 (G1)	CD54	Serotec, UK
ED1(G1)	Inflammatory	Serotec, UK
ED2 (G1)	macrophages	Serotec, UK
OX-6 (G2)	Resident macrophages	Serotec, UK
OX-12 (G1, kappa)	MHC II	Serotec, UK
R-MC42 (G1)	K chain, pan B	MMA *
R-MC46 (G1)	Macrophage subpopulation Granulocytes, monocytes	MMA *

* Monoclonal antibodies R-MC42 and R-MC46 were produced in the Institute of Medical Research, MMA, Belgrade

Statistical analysis

The heart macroscopic and microscopic scores were expressed as mean values. Body weights (Bwt), heart weights (Hwt) and Hwt/Bwt ratio were expressed as mean \pm 1SD. Student's t-test was used for comparison data between groups. Differences were considered significant at $p < 0.05$.

Results and discussion

Effects of PTX on experimental autoimmune myocarditis were evaluated by two treatment protocols: the first conducted within the first 6 days after induction EAM (early treatment group); and the second, started 14 days and ended 20 days after induction of EAM (late treatment group). Both groups received i.m. 200 mg/kg/day of PTX. Animals were

killed on day 21, their hearts were analyzed macroscopically and microscopically and compared with control group of rats (**Table II**).

Table II Effects of Pentoxifylline on incidence of experimental autoimmune myocarditis, body weight (Bwt), heart weight (Hwt), index Hwt/Bwt, and macroscopic and microscopic scor of disease in rats treated with PTX (200mg/kg) over 6 days from the day of immunization (A); in rats subjected to the same treatment from day 14th postimmunization (B), control immunized (C) and in unimmunized rats (D)

Tabela II Efekat pentoksifilina na incidencu eksperimentalnog autoimunog miokarditisa u DA pacova

Group	EAM/total (%)	Body weight initial (g)	Body weight last (g)	Heart weight (g)	Hwt/Bwt (g/kg)	Macros. scor	Micros. scor
A	0/7 (0)	180.0±5.0	186.0±2.0	0.66±0.03*	3.54±0.32**	0	0.2
B	2/7 (28)	188.3±1.5	193.0±4.0	0.72±0.02*	3.73±0.21**	0.2	0.4
C	14/14 (100)	186.0 ± 4.0	164.0 ± 3.0	1.34±0.08	8.19±0.57	1.9	2.4
D	0/7 (0)	195.0±6.0	230.6±8.0	0.77±0.02	3.33±0.31	0	0

* Statistical significance $p < 0.05$ between treated groups vs. C control group

** Statistical significance $p < 0.01$ between treated groups vs. C control group

Macroscopic and microscopic findings. While diseased rats progressively decreased body weights over 21-day-long postimmunization period, the rats treated with PTX did not change body weight in comparison with the starting values. The heart weights in rats treated with PTX were significantly lower ($p < 0.05$) than that of untreated animals, while no difference was detected in the value of this parameter between PTX-treated groups. Hwt/Bwt ratios were also

significantly lower ($p < 0.01$) in both groups of PTX treated animals compared with the saline injected controls, and did not differ from the values of the healthy control. Saline injected animals, immunized with cardiac myosin, exhibited discolored areas over the cardiac surface (mean macroscopic score 1.9), had numerous inflammatory infiltrates in the heart tissue and showed extensive myocardial necrosis (**Fig.1**). In the early PTX-treated group, only one heart that appeared macroscopically normal, microscopically showed mild inflammation (mean microscopic score 0.2). In the group treated later with PTX, mild to moderate inflammation was detected in two hearts, but the mean microscopic score was 0.4, still markedly lower than that of untreated animals. Taken together, 28% (2/7) animals developed mild myocarditis when they were treated from day 14 to day 20 after immunization.

Immunohistochemical analysis of heart sections from animals treated early with PTX demonstrated no differences in comparison with the normal heart tissue. The number of CD4⁺ cells in the animals treated early with PTX was markedly lower than in saline injected controls (**Fig.1**). In one case, small subepicardial clusters of mononuclear cells not exceeding 10-15 cells/cluster (microscopic score 0.2) were observed (**Table 2**). In late treatment group two hearts had rare, small-sized infiltrates, showed the increased expression of adhesion molecules on the interstitial and vascular endothelial cells. In these rats OX-6⁺, R73⁺ and CD4⁺ cells were slightly more frequent (not statistically significant) than in healthy control animals.

According to the histological and immunohistochemical findings, the early PTX treatment prevented the disease development, while the late PTX treatment effectively suppressed myocarditis.

It has been reported that cytokines relating to inflammation are involved in the induction and resolution of EAM (4). Th1 type cytokines produced mainly by infiltrating lymphocytes, and proinflammatory cytokines produced by the infiltrating macrophages, were detected only in the inflammatory phase (day 19-25) of EAM, while in the recovery phase the expression of a Th2 cytokine, IL-10, and TGF- β was observed (5, 8, 11). We demonstrated histologically and immunohistochemically the inhibitory effect of PTX on myocardial inflammation, early treatment was demonstrated to prevent the disease development, while late treatment significantly reduced the severity of EAM. It is reasonable to believe that the drug specifically targets production of proinflammatory

cytokines, although there may be also some other explanations. For example PTX has been found to inhibit apoptosis in different human cell types (20). Further investigation is necessary to test if PTX prevent the apoptotic cell death of cardiomyocytes, as well as its putative effect on the chronic phase of EAM.

In conclusion, in our study we found that PTX exhibited both preventive and therapeutical effects in EAM.

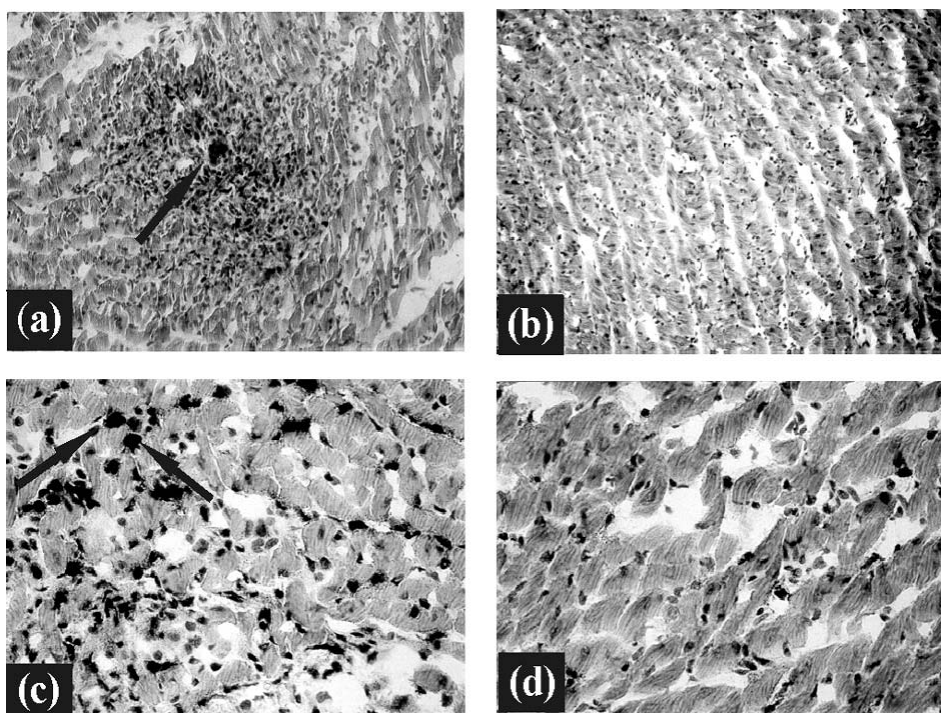


Figure 1

- a. Inflammatory infiltrate in EAM at day 21, untreated animal (HE staining, magnification x 125)
Inflamatorni infiltrat u EAM 21-og dana, netretirane životinje
- b. PTX-treated animal in EAM at day 21, (HE staining, magnification x 125)
PTX-tretirana životinja, EAM, 21 dan
- c. CD4⁺ cells in untreated animal, EAM at day 21, (magnification x 500)
CD4⁺ ćelije u netretirane životinje, EAM, 21 dan
- d. CD4⁺ cells in PTX treated animal (0-6 day), (magnification x 500)
CD4⁺ ćelije u životinje tretirane PTX (0-6 dan)

IMUNOMODULACIJA EKSPERIMENTALNOG AUTOIMUNSKOG MIOKARDITISA PRIMENOM PENTOKSIFILINA

MARINA MILENKOVIĆ¹, PETAR MILOSAVLJEVIĆ²,
ZORICA STOJIĆ-VUKANIĆ¹, MIROSLAVA DIMITRIJEVIĆ¹,
MIODRAG ČOLIĆ²

¹*Institut za mikrobiologiju i imunologiju, Farmaceutski fakultet, Beograd*

²*Institut za medicinska istraživanja, Vojnomedicinska akademija, Beograd*

Kratak sadržaj

U radu je ispitivan uticaj pentoksifilina (PTX) na razvoj i tok eksperimentalnog autoimunog miokarditisa pacova. Pentoksifilin je derivat ksantina sa inhibitornim efektom na produkciju TNF- α , a klinički je potvrđen i njegov pozitivan učinak u terapiji pacijenata sa dilatacionom kardiomiopatijom. U ispitivanju je testiran imunomodulatorni efekat PTX u tretmanu eksperimentalnog autoimunog miokarditisa koji predstavlja eksperimentalni model za proučavanje autoimunskih mehanizama uključenih u razvoj dilatacione kardiomiopatije. Pacovi DA soja imunizovani srčanim miozinom tretirani su pentoksifilinom u dozi od 200 mg/kg t.m., počev od 0.-6. dana (rani tretman), ili od 14.-20. dana (kasni tretman) u odnosu na termin imunizacije miozinom. Razvoj i intenzitet miokarditisa praćeni su analizom makroskopskih karakteristika srca, indeksa masa srca/telesna masa (Hwt/Bwt), histoloških i imunohistohemijskih analiza miokarda. Dobijeni rezultati su pokazali da PTX ispoljava profilaktičan i terapijski učinak u eksperimentalnom autoimunom miokarditisu.

Ključne reči: srčani miozin, autoimunski miokarditis,
pentoksifilin (PTX).

References

1. *Pummerer C, Berger P, Fruhwirth M, Öfner C, Neu N.* Cellular infiltrate, major histocompatibility antigen expression and immunopathogenic mechanisms in cardiac myosin-induced myocarditis. *Laborat. Invest.* 1991; Vol. 65 (5): 538-47.
2. *Suzuki K.* A histological study on experimental autoimmune myocarditis with special reference to initiation of the disease and cardiac dendritic cells. *Virchows Arch* 1995; 426: 493-500.
3. *Pummerer C, Grässl G, Sailer M, Bachmaier KW, Penninger JM, Neu N.* Cardiac myosin-induced myocarditis: target recognition by autoreactive T cells requires prior activation of cardiac interstitial cells. *Laborat. Invest.* 1996; Vol. 74(5): 845-52.
4. *Okura Y, Takeda K, Honda Sh, Hanawa H, Watanabe H, Kodama M, et al.* Recombinant murine interleukin-12 facilitates induction of cardiac myosin-specific type 1 helper T cells in rats. *Circ Res.* 1998; 82:1035-42.
5. *Kurrer MO, Kopf M, Penninger JM, Eriksson U.* Cytokines that regulate autoimmune myocarditis. *Swiss Med Wkly* 2002; 132: 408-13.
6. *Ishiyama Sh, Hiroe M, Nishikawa T, Shimojo T, Abe Sh, Fujisaki H, et al.* The Fas/Fas ligand system is involved in the pathogenesis of autoimmune myocarditis in rats. *J of Immunol.* 1998; 161: 4695-701.
7. *Ishiyama Sh, Hiroe M, Nishikawa T, Shimojo T, Hosokawa T, Ikeda I, et al.* Inhibitory effects of vesnarinone in the progression of myocardial damage in experimental autoimmune myocarditis in rats. *Cardiovas. Res.* 1999; 43: 389-97.
8. *Menghini VV, Savcenko V, Olson LJ, Tazelaar HD, Dec W, Kao A, Cooper LT.* Combined immunosuppression for the treatment of idiopathic giant cell myocarditis. *Mayo Clin Proc.* 1999; 74: 1221-26.
9. *Dimitrijevic M, Milenkovic M, Milosavljevic P, Stojic-Vukanic Z, Colic M, Bartlett R.* Beneficial effects of leflunomide on cardiac myosin-induced experimental autoimmune myocarditis in rats. *Int. J. Immunotherapy* 1998; 14: 9-21.
10. *Dimitrijevic M, Milenkovic M, Milosavljevic P, and Colic M.* Effects of leflunomide on experimental autoimmune myocarditis with special reference to the dendritic cells. *Trans. Proceedings* 1998; 30(8): 4149-50.
11. *Takehana H, Inomata T, Niwano H, Nishii M, Matsuda Ch, Kohno K, et al.* Immunomodulatory effect of pentoxifylline in suppressing experimental autoimmune myocarditis. *Circ J* 2002; 66: 499-504.
12. *Neu N, Rose NR, Beisel KW, Herskowitz A, Gurri-Glass G, Craig SW.* Cardiac myosin induces myocarditis in genetically predisposed mice. *J Immunol* 1987; 139: 3630-36.
13. *Kodama M, Matsumoto Y, Fujiwara M, Masani F, Izumi T, Shibata A.* A novel experimental model of giant cell myocarditis induced in rats by immunization with cardiac myosin fraction. *Clin Immunol Immunopathol* 1990; 57: 250-62.

14. Kodama M, Hanawa H, Saeki M, Hosono H, Inomata T, Suzuki K, et al. Rat dilated cardiomyopathy after autoimmune giant cell myocarditis. *Circ Res* 1994; 75: 278-84.
15. Inomata T, Hanawa H, Miyanishi T, Yajima E, Nakayama S, Maita T, et al. Localization of porcine cardiac myosin epitopes that induce experimental autoimmune myocarditis. *Circ Res* 1995; 76:726-33.
16. Inomata T, Watanabe T, Haga M, Hirahara H, Abo T, Okura Y, et al. Anti-CD2 monoclonal antibodies prevent the induction of experimental autoimmune myocarditis. *Jpn Heart J* 2000; 41: 507-17.
17. Wegmann KW, Zhao W, Griffin AC, Hickey WF. Identification of myocarditogenic peptides derived from cardiac myosin capable of inducing experimental allergic myocarditis in the Lewis rat. *J Immunol* 1994; 153: 892-900.
18. Noel C, Copin MC, Hazzan M, Labalette M, Susen S, Lelievre G, et al. Immunomodulatory effect of pentoxifylline during human allograft rejection. *Transplantation* 2000; 69: 1102-7.
19. Smith SC, Allen PM. Neutralization of endogenous tumor necrosis factor ameliorates the severity of myosin-induced myocarditis. *Circ Res* 1992; 70: 856-63.
20. Jimenez JL, Punzon C, Navaro J. Phosphodiesterase 4 inhibitors prevent cytokine secretion by T lymphocytes by inhibiting nuclear factor κ B and nuclear factor of activated T cells activation. *J Pharmacol Exp Ther* 2001; 299: 753-9.
21. Boldt J, Brosch C, Piper SN, Suttner S. Influence of prophylactic use of pentoxifylline on postoperative organ function in elderly cardiac surgery patients. *Crit Care Med* 2001; 29(5): 952-8.
22. Navarro JF, Mora C, Rivero A. Urinary protein excretion and serum tumor necrosis factor in patients with advanced renal failure: effects of pentoxifylline administration. *Am J Kidney Dis* 1999; 33(3): 458-63.
23. Rieckman P, Weber F, Gunther A, Martin S, Bitsch A, Broocks A, et al. Pentoxifylline, a phosphodiesterase inhibitor, induces immune deviation in patients with multiple sclerosis. *J Neuroimmunol* 1996; 64: 193-200.
24. Bienvenu J, Doche C, Gutowski MC, Lenoble M, Lepape A, Perdrix JP. Production of proinflammatory cytokines and cytokines involved in the TH1/TH2 balance is modulated by pentoxifylline. *J Cardiovasc Pharmacol* 1995; 25: S80-S84.