

PDF hosted at the Radboud Repository of the Radboud University Nijmegen

The following full text is a publisher's version.

For additional information about this publication click this link.

<http://hdl.handle.net/2066/208984>

Please be advised that this information was generated on 2020-09-09 and may be subject to change.

Contrast-Enhanced MRI for Breast Cancer Screening

Ritse M. Mann, MD, PhD,^{1,2*} Christiane K. Kuhl, MD, PhD,³ and Linda Moy, MD⁴

Multiple studies in the first decade of the 21st century have established contrast-enhanced breast MRI as a screening modality for women with a hereditary or familial increased risk for the development of breast cancer. In recent studies, in women with various risk profiles, the sensitivity ranges between 81% and 100%, which is approximately twice as high as the sensitivity of mammography. The specificity increases in follow-up rounds to around 97%, with positive predictive values for biopsy in the same range as for mammography. MRI preferentially detects the more aggressive/invasive types of breast cancer, but has a higher sensitivity than mammography for any type of cancer. This performance implies that in women screened with breast MRI, all other examinations must be regarded as supplemental. Mammography may yield ~5% additional cancers, mostly ductal carcinoma in situ, while slightly decreasing specificity and increasing the costs. Ultrasound has no supplemental value when MRI is used. Evidence is mounting that in other groups of women the performance of MRI is likewise superior to more conventional screening techniques. Particularly in women with a personal history of breast cancer, the gain seems to be high, but also in women with a biopsy history of lobular carcinoma in situ and even women at average risk, similar results are reported. Initial outcome studies show that breast MRI detects cancer earlier, which induces a stage-shift increasing the survival benefit of screening. Cost-effectiveness is still an issue, particularly for women at lower risk. Since costs of the MRI scan itself are a driving factor, efforts to reduce these costs are essential. The use of abbreviated MRI protocols may enable more widespread use of breast MRI for screening.

Level of Evidence: 1

Technical Efficacy: Stage 5

J. MAGN. RESON. IMAGING 2019;50:377–390.

Screening for Breast Cancer

Mammography

SCREENING FOR BREAST CANCER is mostly mammography-based. The basic concept is that detection of cancer before symptoms occur allows for better treatment, and therefore reduced breast cancer-related morbidity and mortality. In essence, the detection and treatment of ductal carcinoma in situ (DCIS), especially of high-grade DCIS, can even be regarded as a form of primary prevention of breast cancer development. Several meta-analyses of randomized controlled trials on mammography screening showed that this concept works, with a reported mortality reduction of ~20% in women invited to screening,¹ and a much higher mortality reduction in women actually undergoing screening.²

Unfortunately, mammography fails to detect a significant amount of cancers before the symptomatic phase that consequently present as interval carcinomas between screening rounds. Particularly in women with a large relative fraction of fibroglandular tissue, ie, with "dense" breasts, up to 50% of cancers is detected between screening rounds.^{3,4}

Women at an increased risk for the development of breast cancer are usually prone to develop breast cancer at a much younger age, and are consequently screened from a younger age.^{5,6} As a result, the fraction of women in this population with extremely dense breasts is high. In addition, imaging characteristics of cancers developing in women at very high risk are less specific and may resemble benign lesions.^{7,8} Consequently, mammographic screening in women at increased risk has substantially lower performance than in the average population.

View this article online at wileyonlinelibrary.com. DOI: 10.1002/jmri.26654

Received Dec 8, 2018, Accepted for publication Jan 4, 2019.

*Address reprint requests to: R.M.M., Department of Radiology and Nuclear Medicine (766), Radboud University Medical Center, P.O. Box 9101, 6500 HB Nijmegen, the Netherlands. E-mail: ritse.mann@radboudumc.nl

From the ¹Department of Radiology and Nuclear Medicine, Radboud University Medical Center, Nijmegen, the Netherlands; ²Department of Radiology, the Netherlands Cancer Institute/Antoni van Leeuwenhoek Hospital, Amsterdam, the Netherlands; ³Department of Diagnostic and Interventional Radiology, University of Aachen, Aachen, Germany; and ⁴Center for Advanced Imaging Innovation and Research / Department of Radiology, Laura and Isaac Perlmutter Cancer Center, New York University School of Medicine, New York, New York, USA

This is an open access article under the terms of the Creative Commons Attribution-NonCommercial License, which permits use, distribution and reproduction in any medium, provided the original work is properly cited and is not used for commercial purposes.

MRI

After the initial realization that contrast-enhanced breast magnetic resonance imaging (MRI) has a very high sensitivity for the detection of breast cancer,^{9,10} it was rapidly tested as a supplementary screening tool. The high sensitivity is based on the fact that no breast cancer can grow beyond 2 mm in size without creating new blood vessels that provide sufficient nutrients for the tumor to grow.¹¹ This neo-vascularization results in creation of vessels that are leaky. Gadolinium-based contrast agents, which are relatively large molecules, can easily extravasate from such vessels, and therefore rapidly accumulate in the breast cancer stroma.¹² Their paramagnetic properties shorten the T₁ time in the surrounding tissue, and therefore increase the local signal on T₁-based sequences. A basic breast MRI protocol consists of one precontrast T₁-weighted acquisition and several T₁-weighted acquisitions after contrast administration in order to document the kinetic behavior of contrast accumulation in a lesion, since the leakiness of the vessels in cancer also leads to rapid washout of the contrast agent. Often a T₂-weighted acquisition is also obtained.^{13,14}

Following a single-center study that showed the potential of MRI as a screening tool,^{15–17} several large-scale multicenter trials were conducted to assess the value of MRI as a supplementary screening tool. Inclusion criteria varied, but always included women with germline mutations in the BRCA1 and BRCA2 genes, in many instances supplemented with women at increased risk based on familial predisposition.^{18–22} Albeit in some of the initial studies the sensitivity of breast MRI was lower than expected—71% in the Dutch Magnetic Resonance Imaging screening study (MRISC),¹⁸ and 77% in the British Magnetic Resonance Imaging in Breast Screening study (MARIBS)¹⁹—MRI almost doubled the sensitivity of mammography in all studies. In meta-analysis, a sensitivity of 77% for MRI was reported (compared with 39% for mammography), with a specificity of 86% (compared with 95% for mammography).²³ The relatively low sensitivity of the initial studies is likely due to a, at that time, still immature technique in combination with the absence of clear interpretation guidelines, especially for nonmass lesions.

In later studies, such as the German EVA trial and the High Breast Cancer Risk Italian 1 Study (HIBCRIT-1), the sensitivity was over 90%.^{24,25} Recent large series presenting a realistic overview of the current performance of breast MRI for screening are listed in Table 1. Sensitivity of MRI alone ranges between 75.2% and 100%, and is generally over 80%; specificity ranges between 83% and 98.4%. In the studies that report on prevalent and incident rounds, the specificity of MRI alone climbs from ~90–97%, which implies that the lower specificity of MRI is mainly a first-round effect. The range of reported positive predictive values for biopsy runs from 11–40%, which is similar to what is reported for mammography. A large fraction of false-positive findings in breast

MRI (40%) is due to the detection of enhancing high-risk lesions, which may still be relevant for determination of the screening regimen.²⁶ In general, true interval cancers are rare in women screened with MRI, occurring mainly in BRCA mutation carriers (eg, 11 of 16 interval cancers in the study by Vreemann et al²⁷).

Supplemental Screening Techniques

Based on the results of the screening studies listed in Table 1, together documenting 56,801 screening examinations performed in 29,172 women, it follows that for any woman screened with breast MRI any other screening modality should be regarded as a supplemental test with only a minor contribution to early cancer detection.

Mammography

The most commonly used supplemental test is without doubt mammography, as the postulate has long been reversed (MRI was regarded as a supplemental test to mammography). It is important to realize that this is no longer true, even when studies are still presenting MRI as a supplemental test.^{34,36} The incremental cancer detection with mammography ranges from 0–19.4%.^{22–32} However, the study by Sung et al reports on MRI and mammography examinations that were not simultaneously obtained and should therefore likely be disregarded in this sense.³¹ Hence, the added sensitivity with mammography is around 5%, ranging from 0–8.6%. This comes at a decrease in specificity ranging between 0.4–2%. While the latter appears modest, it should be realized that even in high-risk screening no more than 2% of the examinations are positive, and therefore a modest reduction in specificity affects many women. Also, other side effects of supplemental mammography, such as the need for compression, the use of ionizing radiation, and incremental costs need to be taken into account.

Sung et al show that the types of tumors detected by MRI and mammography are different, based on a very large cohort of 18,064 screening MRI examinations and 26,866 mammographic examinations; the sensitivity of mammography reduces for more aggressive/invasive types of cancers, whereas the sensitivity of MRI increases,³¹ which is corroborated by several other studies.^{37,38} Consequently, the gain of mammography is mostly in the detection of DCIS, even though the sensitivity of MRI for any grade of DCIS is higher than that of mammography.^{31,37} Phi et al conducted a meta-analysis of the earlier studies to determine the impact of mammography in BRCA mutation carriers.³⁹ In BRCA1 mutation carriers the incremental cancer detection was 3.9%, whereas in BRCA2 mutation carriers the incremental detection was 12.6%. Disturbingly, most incremental detections with mammography only were done in the age group below 40 years (9.3% for BRCA1 and 34.5% for BRCA2). They reported a number

TABLE 1. Results of Recent Screening Breast MRI Studies

Study	Year	Study type	N patients	N screens	Population	Screenings- methods	N cancers	Sens		Spec		N interval cancers (%) ^d
								MRI	Mx	MRI	Mx	
Kuhl (24)	2010	Prospective	687	1679	hereditary and familial risk	MRI + CBE + Mx + US	27	92.6	98.4	100	97.6	0 (0)
Sardanelli (25)	2011	Prospective	501	1592	hereditary and familial risk	MRI + CBE + Mx + US	52	91.3	96.7	93.2	96.3	3 (6)
Cheng (28)	2012	Retrospective	3586	3586	average risk	MRI	47	90	98.1	NA	NA	0 (0)
Chiarelli (29)	2014	Retrospective	2150	2150	hereditary and familial risk	MRI + Mx	35	100	93	100	92.3	NA
Riedl (30)	2015	Prospective	559	1365	hereditary and familial risk	MRI + Mx + US	40	90	88.9	95	88.2	1 (3)
Sung ^a (31)	2016	Retrospective	7519	18064	mixed high risk	MRI + Mx	222	75.2	NA	94.6	NA	12 (5)
Huzarski ^b (32)	2017	Prospective	2995	5322	familial and average risk	MRI + Mx + US	27	86.3	NA	90.9	NA	2 (7)
Lo ^c (33)	2017	Retrospective	1249	1977	mixed high risk	MRI + Mx	45	95.6	93.7	95.6	91.7	0 (0)
Kuhl (34)	2017	Prospective	2120	3861	average risk	MRI (after Mx + US)	60	100	97.1	NA	NA	0 (0)
Lee (35)	2017	Retrospective	5343	8387	mixed high risk	MRI (after Mx)	181	81	83	NA	NA	12 (7)
Vreemann (27)	2018	Retrospective	2463	8818	mixed high risk	MRI + Mx	145	81.4	95.1	90	93.8	16 (11)

^aMRI and mammography were not simultaneously obtained, the interval is not reported;

^bsensitivity and specificity are calculated based upon invasive cancers only;

^csensitivity and specificity were recalculated considering BIRADS3 negative;

^dCancers are considered "interval cancers" when detected by symptoms within the screening interval. N = number, Sens = Sensitivity, Spec = Specificity, MRI = Magnetic resonance imaging, Mx = mammography, US = Ultrasound, NA = Not available, CBE = Clinical breast evaluation.

needed to screen of 717 for BRCA1 and 231 for BRCA2 to detect an additional cancer after the first round. However, the relatively low sensitivity of MRI in the included studies, particularly for DCIS, should be taken into account when interpreting these data. Recent results on the sensitivity of MRI for DCIS are much better, and, thus, the added value of mammography is lower. In agreement with this, Obdeijn et al reported on more recent data only a 2% incremental cancer detection rate (CDR) in BRCA1 mutation carriers, two cases of DCIS in women over 50.⁴⁰ In a subsequent modeling study they noted that mammography under 40 had no, or even a negative effect, in this population.⁴¹ Narayan et al report a 0% increase in cancer detection by adding mammography in women below 40 with various risk factors.⁴² In a similar, but much larger, mixed cohort, Vreemann et al reported 13/125 cancers to be solely detected by mammography, including eight cases of DCIS.⁴³ However, they reported no supplemental detection in BRCA mutation carriers below the age of 50, and overall 77% of additional detections in women over 50, leading to a number of mammography screens needed to detect an additional cancer in women younger than 50 of 1427.

Ultrasound

Since ultrasound is readily available, and has been shown to be a useful supplemental screening tool in women with mammographically dense breasts,^{44,45} the use of ultrasound as a supplemental screening technique, usually on top of the combination of MRI and mammography, has been evaluated. This has been considered particularly for BRCA1 mutation carriers, where, due to the particularly fast growth rates of BRCA1-associated breast cancers, the "lead time" is particularly short, such that in these women, interval cancer rates can still be relatively high (11–25%).⁴⁶ Table 2 lists the studies that performed such triple modality screening.

In none of the studies listed in Table 2, totaling 7696 screens in 3629 women, ultrasound contributed to cancer detection at the screening rounds, while the yield of MRI in an incident round after negative mammography and ultrasound still amounts to cancer detection in 14.7/1000 screens.⁴⁴ Only in the study by Bosse et al were three cancers detected in the 6-month interval.⁴⁷ In the study by van Zelst et al, two cancers were in retrospect visible at the 6-month interval, but missed due to their benign appearance.⁴⁸ The addition of ultrasound to MRI and mammography leads to a reduction of specificity of between 0% and 5.5%.

Outcome Effects

Since none of the initial MRI studies were randomized, direct assessment of the effects of MRI screening on breast cancer-specific survival is precluded. Rather, the studies used the existing evidence that early detection improves outcomes from the mammography screening trials as an argument for the efficacy of MRI screening. Considering the fact that

several studies have shown that MRI preferentially detects the more aggressive subtypes of breast cancer, this assumption seems more than justified.^{31,37,38}

Compared with nonrandomized control groups, several studies showed that the fraction of minimal cancers (invasive <1 cm) is much higher in women screened with MRI than in women screened with mammography.^{46,49–51} Likewise, the fraction of women with positive axillary lymph nodes is much lower. Saadatmand et al reported improved metastasis-free survival with a hazard ratio of 0.4 for patients who participated in the MRISC trial.⁵² Evans et al reported a significantly higher overall survival of 95.3% in women at very high risk participating in an MRI-based screening program compared with 73.7% for equally high-risk women who did not.⁵¹ According to Heijnsdijk et al, who combined the data of several of the initial studies, the added mortality reduction for a combined regimen is between 3% and 20%, and only slightly lower for MRI screening alone.⁴⁶ Still, Moller et al report a 10-year survival of only 69% for BRCA1 mutation carriers participating in an MRI-based screening program, which points to the still much worse outcome in this specific population.⁵³ Podo et al, however, showed that the 5-year overall survival difference between triple-negative breast cancers and less aggressive subtypes was relatively small (86% ± 9% for TNBCs vs. 93% ± 5% for others) in patients who participated in the HIBCRIT-1 trial.⁵⁴

Current Indications for MRI Screening

The largely improved detection of early breast cancer shown in the early studies is the basis for the widely adopted recommendations of the American Cancer Society (ACS).⁵⁵ They advise MRI screening for all women with a lifetime risk for the development of breast cancer of 20–25% or higher based on family history or genetic predisposition. Based on expert opinion, these recommendations also include women with a history of radiation to the chest at a young age, and women with p53 and PTEN mutation, which were underrepresented in the original cohorts, but for whom the relative risk of developing breast cancer is likewise high (roughly 6–8 times the population risk).

These recommendations still form the basis for most national and international guidelines. Unfortunately, due to the fact that for many women the presence of genetic risk factors is unknown, and the fact that many facilities do not have breast MRI available, there is a large fraction of eligible women that is not screened according to these standards. In part, this may also be due to inadequate patient information about the benefits of MRI. Wernli et al reported that by 2009 29% of eligible women were screened with MRI.⁵⁶ Miles et al showed that in 2012 43.9% of women with familial risk visited a clinic with MRI facilities for screening. However, only 6.6% were screened with MRI within 2 years from

a mammogram.⁵⁷ Stout et al reported that only 48.4% of women with known genetic mutations underwent MRI screening.⁵⁸

Developing Indications for Breast MRI Screening

The ACS also defined patient categories where evidence was insufficient to recommend for or against screening. These include women with a lifetime risk of between 15% and 20% (as these women were only included in the MRISC trial), women with biopsy results of an atypical epithelial proliferation (lobular carcinoma in situ [LCIS], atypical lobular hyperplasia [ALH], atypical ductal hyperplasia [ADH]), women with a personal history of breast cancer, and women with heterogeneously or extremely dense breasts on mammography. Based on expert opinion, screening of women at average risk (lifetime risk <15%) with MRI was not advised by the ACS. Currently, however, evidence for the use of MRI screening in these subgroups is mounting.

Hereditary and Familial Risk

Genetic testing has become more extensive in recent years; women suspected of hereditary cancer are subjected to panel tests that include other susceptibility genes such as PALB2, STK11, CDH1, ATM, and CHECK2 that account for relative risks from 2.5–3 for lower-risk alterations such as CHECK2 and ATM to 4–6 for the others.^{59,60} Local guidelines are rapidly changing to also include these mutations as an indication for MRI screening. It should be noted that women with a family history of breast cancer and such a mutation are in general at higher risk than women in whom the mutation was found accidentally.^{61,62} In the absence of a genetic mutation, the risk for women with a family history of breast cancer is somewhat lower. Consequently, the use of MRI in women with only a family history of breast cancer is changing somewhat.

Personal History of Breast Cancer

Women with a personal history of breast cancer (PHBC) are at a substantially increased risk for the development of a second breast cancer. Even though local recurrence rates are nowadays relatively low, cumulative incidence of second breast cancers may amount to 5.4% in 5 years.⁶³ Schacht et al reported a relative risk compared with women with a positive family history of 1.4.⁶⁴ The sensitivity of mammography for early detection of second breast cancers is dismal due to postoperative changes, including scar formation and dystrophic calcifications. This implies that classically, most local recurrences are detected by palpation. However, it was shown that earlier detection of second cancers, both in the ipsilateral and contralateral breast, improves relative overall survival, especially in younger patients.^{65–67} Consequently, there is a clear incentive for earlier detection of second cancers in women

with a personal history of breast cancer. In recent years many studies evaluated the value of breast MRI for this purpose, with remarkably concordant results, which are listed in Table 3.

It should be noted that all but one of the 12 studies listed in Table 3 are retrospective in nature, which implies that even without formal recommendations for postoperative screening with breast MRI, the technique is widely practiced. Still, it also implies a patient selection, which favors young patients, patients with very dense breasts, patients in whom the initial cancer was mammographically occult, and patients who also have a positive family history for breast cancer. Therefore, the results may not be applicable to all women with a personal history of breast cancer. In the evaluated studies, MRI sensitivity ranged from 80–100%, whereas mammography sensitivity ranged from 0–53% (Table 3). Specificities for MRI screening in this population are relatively high (albeit still somewhat lower than for mammography). However, in women with a personal history of breast cancer breast imaging reporting and data system (BI-RADS) 3 evaluations, ie, likely benign findings with less than 2% risk of being malignant, are rather common.^{36,69,72} In the early phase after surgery this may be due to radiotherapy, causing some focal residual enhancement in the breast that requires follow-up imaging.⁷⁷ This enhancement reduces over time. Specificity is substantially higher in follow-up rounds than in first-round examinations. Cho et al also evaluated the combination of mammography and ultrasound for this indication, showing that in their population (Asian, which is relevant due to the higher average breast density and lower cancer frequency in these women compared with European or American women^{78,79}) approximately half of the cancers detected by MRI could also be found by ultrasound.³⁶ Ultrasound did not aid in cancer detection when MRI was used.

Atypical Epithelial Proliferations

Women with atypical epithelial proliferation such as atypical ductal hyperplasia, atypical lobular hyperplasia, and lobular carcinoma in situ have a relative risk for the development of breast cancer of 3–10 times that of the general population.^{80,81} Since the risk is on a par with other MRI screening indications, several small-scale studies have been performed. Sung et al detected cancer in 14 patients initially diagnosed with LCIS after 840 screening rounds (MRI + Mx). Sensitivity was 71% for MRI and 36% for mammography; with no overlap between MRI- and mammography-detected cases.⁸² The overall biopsy rate was 10.2% (7.1% due to MRI, 3.1% due to Mx). In a similar screening study, Friedlander et al reported the detection of five cancers in 307 screening studies, at a likewise relatively high biopsy rate (8.8%).⁸³ Still, cancer detection is strikingly similar between the studies (1.6%), and the positive predictive values of biopsy are in the range of normal findings. In addition, both studies report a

TABLE 2. Results of the Addition of Ultrasound to MRI & Mammography-Based Screening Program

Study	Year	N patients	N screens	Population	Ultrasound policy	N cancers	Sens		Spec	
							MRI&Mx	MRI&Mx + US	MRI&Mx	MRI&Mx + US
Kuhl (24)	2010	687	1679	hereditary and familial risk	Biannual ^d	27	100	100	97.6	97.6
Sardanelli (25)	2011	501	1592	hereditary and familial risk	Annual	52	93.2	93.3	96.3	96
Berg ^a (44)	2012	612	612	mixed high risk	Annual	16	100	100	70.6	65.4
Bosse ^b (47)	2014	221	~663	BRCA1 and 2	Biannual ^d (~1220 US)	27	100	100	NA	NA
Riedl (30)	2015	559	1365	hereditary and familial risk	Annual	40	95	95	88.2	87.5
Zelst ^c (48)	2017	296	702	BRCA1 and 2	Biannual ^d (1109 US)	21	76.3	76.3	93.6	88.1
Kuhl (34)	2017	753	1083	average risk	Annual	12	100	100	NA	NA

^aSubset of patients that underwent MRI,
^bEstimated numbers as only the total number of examinations and the median number of screening rounds are reported
^cUltrasound examinations using an automated whole breast ultrasound. Subset of patients in the incident round who also underwent ultrasound.
^dStudies with a biannual ultrasound policy performed ultrasound every 6 months, with MRI and Mx annually. N = number, Sens = Sensitivity, Spec = Specificity, MRI = Magnetic resonance imaging, Mx = mammography, US = Ultrasound.

TABLE 3. Performance of MRI and Mammography Screening for Second Breast Cancers in Women With a Personal History of Breast Cancer

Study	Year	Study type	N patients	N screens	Population	Screenings-methods	N cancers	Sens Mx	Spec Mx	Sens MRI	Spec MRI
Elmore (68)	2010	Retrospective	114	202	PHBC	MRI + Mx	2	Negative	NA	100	89.9 ^c
Schacht (64)	2014	Retrospective	208	208	PHBC	MRI (others not reported)	6	Negative	NA	100	NA
Gweon (69)	2014	Retrospective	607	607	PHBC	MRI	11	Negative	NA	91.7	82.2 ^c
Giess (70)	2015	Retrospective	691	1194	PHBC	MRI + Mx	12	9.1	NA	100	89.9 ^c
Weinstock (71)	2015	Retrospective	249	571	PHBC	MRI + Mx	13	23.1	96.4	84.6	95.3
Destounis (72)	2016	Retrospective	131	381	PHBC<50	MRI + Mx	22	31.8	96.9	100 ^b	83.6 ^c
Chung (73)	2016	Retrospective	181	308	PHBC	MRI (others not reported)	4	NA	NA	100	96.1
Lehman (74)	2016	Retrospective	915	915	PHBC	MRI (others not reported)	20	NA	NA	80	94
Cho (36)	2017	Prospective	754	2065	PHBC<50	MRI + Mx + US	17	53	96	88	90 ^c
Tadros (75)	2017	Retrospective	186	491	PHBC	MRI + Mx	9	11.1	NA	100	94.1
Vreemann ^a (27)	2018	Retrospective	836	3011	PHBC	MRI + Mx	45	46.7	97.2	82.2	96.5
Choi (76)	2018	Retrospective	725	799	PHBC	MRI + Mx + US	12	Negative	NA	100	89.2 ^c

^aSubset of patients with PHBC. A negative mammogram was an inclusion criterion for the study, therefore sensitivity is by definition 0.

^bOnly patients with negative mammography underwent MRI.

^cBIRADS 3 was regarded as positive, in non-starred studies need for biopsy is regarded as positive. N = number, PHBC = Personal history of breast cancer, PHBC <50 = PHBC with first cancer under the age of 50, Sens = Sensitivity, Spec = Specificity, MRI = Magnetic resonance imaging, Mx = mammography, US = Ultrasound.

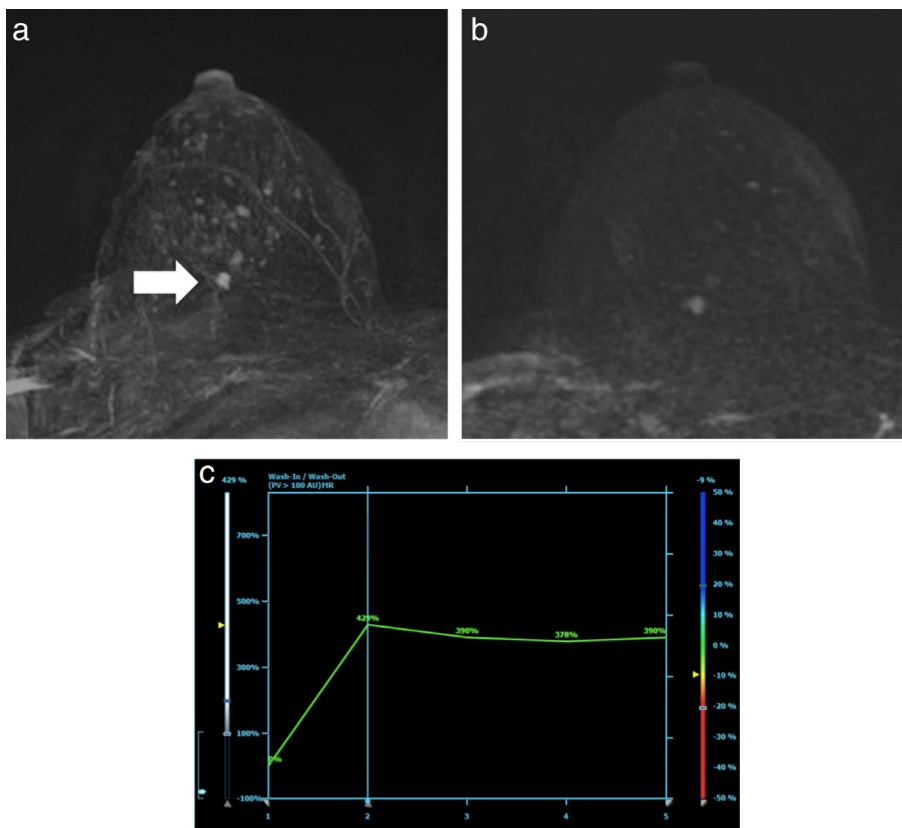


FIGURE 1: Typical finding of an MRI-detected breast cancer (arrow). In this case a 9 mm grade 2 invasive ductal carcinoma in a 46-year-old women screened because of familial risk. As with most cancers, this tumor is clearly evident on the maximum intensity projection (MIP) image shown (A), which was created from subtraction images of regular high-resolution T₁-weighted acquisitions obtained prior to and 90 seconds after contrast injection. Ultrafast examinations may be used to differentiate the cancer from the somewhat nodular parenchymal background enhancement. (B) MIP generated from the ultrafast series (8.6 sec after enhancement of the descending aorta) is provided, showing that the lesion stands out from the other enhancing foci. (C) The corresponding relative enhancement vs. time curve is given (type 2, plateau).

high rate of additional high-risk lesions at biopsy (35 and 25.9%, respectively). However, in a study directly comparing women with LCIS screened with MRI to women screened only with mammography, King et al confirmed the high incidence of cancer (13% in 5 years), but did not report a difference in overall CDR or eventual tumor stage between the cohorts.⁸⁴ Consequently, the benefit of MR screening in women diagnosed with LCIS is not entirely sure, but likely present. Some smaller studies also evaluated MRI screening in other atypical hyperplasias, with CDRs between 0% and 1.5%^{85,86}; however, for these types of lesions the evidence for or against breast MRI screening is scarce.

Extremely Dense Breasts

Women with extremely dense breast tissue according to clinical BI-RADS evaluation have a relative risk for the development of breast cancer that is about 2.3 times higher than that of women with scattered fibroglandular density.⁸⁷ Moreover, their risk of presenting with an interval cancer is about 5.6 times higher,⁸⁸ which is the major reason for the strong call for supplemental screening techniques for these women. Since their personal risk is in the same area as for women with a positive

family history, the use of breast MRI seems logical, albeit ultrasound is currently more commonly used. In two overlapping studies using MRI, Chen et al reported additional cancer detection in respectively 14 of 356 and 16 of 478 women with a negative mammography.^{89,90} However, the exceptionally high CDR in these studies (3.6%) seems to point to the presence of other risk factors as well, even though in the latter study patients with a positive family history were excluded. To determine the actual value of MRI screening in women with extremely dense breasts, the results of the Dutch DENSE trial, that randomizes women between MRI screening and no MRI screening, and the ECOG-ACRIN 1141, that compares cancer detection with an abbreviated MRI protocol to digital breast tomosynthesis, need to be awaited.^{91,92} These results are expected in the first half of 2019.

Women at Average Risk

The success of mammographic screening in the reduction of breast cancer mortality is mostly due to the induction of a stage-shift of the detected breast cancers. After implementation of screening, the fraction of cancers smaller than 2 cm increased from 36–68%.⁹³ Still, most tumors are detected

with mammography when they are between 1 and 2 cm in size, whereas the mean size of MRI-detected cancers is about 0.8 mm^{24,31,93} (Fig. 1). According to Lee et al, 69% of MRI-detected cancers is smaller than 1 cm.³⁵ For such small tumor sizes, Welch et al reported overall survival estimates that exceed the population average.⁹³ Consequently, MRI has the potential to further downstage the average cancer by earlier detection and improve breast cancer-specific survival. Kuhl et al reported detection of 22.6 additional cancers per 1000 screens in women at average risk with negative mammography and ultrasound examinations in a prevalent round. In subsequent incident rounds, the CDR with MRI dropped to 6.9 per 1000, supporting the hypothesis of a stage shift. Importantly, this effect was equally present in all breast density categories,³⁴ which seems to point to earlier detection regardless of breast density. Cheng et al presented similar results in a prevalent round in an Asian population.²⁸

Quality of Screening

BI-RADS Benchmarks

Despite the excellent results of breast MRI screening reported above, it is imperative to realize that all screening comes at a cost, and that the balance between risks to women without breast cancer and benefits for women with breast cancer must be observed.

To this end the BI-RADS lexicon incorporates performance benchmarks for breast MRI screening that are listed in Table 4.⁹⁴ Based on the reported performance in the studies described above, achievable performance measures are also listed. In direct comparison, a large study by Lee et al showed that most of the BI-RADS benchmarks were easily reached.³⁵ Strigel et al only reported a higher incidence of node-positive invasive cancers, albeit this was a much smaller study.⁹⁵ Vreemann et al showed that performance of screening is highly dependent on the actual screening indication.²⁷ For example, the sensitivity of the screening program was only 81% in BRCA1 carriers, whereas it exceeded 90% for all other indications, which is likely an effect of the fast growth of cancers in these women. Recently, Guindalini et al showed that with a biannual breast MRI screening protocol, the frequency of interval cancers in this group was 0.⁹⁶ On the other hand, Vreemann et al²⁷ reported a positive predictive value for biopsy of only 14% in women with a positive family history as the only risk factor, whereas it was around 30% for most other indications, which is due to the lower prevalence of cancer in the familial risk group. This implies that it is of paramount importance to be aware of the screening indication and adjust recall and biopsy thresholds depending on the degree of individual risk.

The suggested CDR of MRI screening for the established indications is between 20 and 30 per 1000. However, this figure depends heavily on the subgroup screened and the screening round. While in first-round examinations between

TABLE 4. BI-RADS Benchmarks and Achievable Performance Levels for MRI-Based Screening

Indicator	BI-RADS	
	benchmark	Achievable
Cancer detection rate (1000 examinations)	20–30	Depends on screening indication and screening round (prevalent vs incident)
PPV2 (%)	15	20
PPV3 (%)	20–50	25–40
Sensitivity (%)	>80	>90 (except in BRCA1)
Specificity (%)	85–90	90 (first round), >95 (follow-up)
Minimal cancer ^a (%)	>50	>70
Node negative cancer	>80	>80

^aMinimal cancer is defined as invasive cancer with size <1 cm or DCIS. PPV2 = positive predictive value for women referred to biopsy. PPV3 = positive predictive value for women who underwent biopsy.

15 and 30 cancers can likely be found in most populations, in follow-up rounds the CDR should return to (or just above) the baseline frequency of cancer detection in that population. In other words, for women at average risk the CDR on follow-up examinations should not exceed 3–4/1000 for annual or about 7/1000 for biennial screening. Consequently, in longitudinal screening programs that include women at risks lower than that of BRCA mutation carriers, the BI-RADS benchmark cannot be met.

False-Negative Examinations

Unfortunately, not all cancers are detected by MRI screening. While some are not visible, a large fraction of undiagnosed cancers is due to reading or management errors, which may be caused by lack of experience in the detection of more subtle abnormalities,⁹⁷ but are likely always present. Pages et al retrospectively reviewed the priors of 60 MRI screen detected breast cancers, reporting that 28 of these lesions would be regarded as BI-RADS 3–5 lesions in the prior, six lesions had been missed, 15 lesions were misdiagnosed, and seven lesions were mismanaged due to incorrect tissue sampling at second-look ultrasound.⁹⁸ In a similar study, Yamaguchi et al reported that 7 out of 15 cancers were retrospectively visible.⁹⁹ In a recent study of 131 cancers with priors, including

16 interval cancers, Vreemann et al reported that overall 34% of cancers were actionable on the prior scan.¹⁰⁰ The presence of a BRCA mutation largely reduced the risk on false-negative examinations, which reflects the lower threshold for work-up in these women. Less than perfect image quality increased the risk. In order to preserve the balance between detection and prevention of harm to women without cancer, such errors are likely unavoidable, albeit their frequency can possibly be reduced by incorporating double-reading or computer-aided diagnosis. Regardless, auditing of MRI screening on a regular basis, as is also common for mammography screening, seems advisable.

Cost-Effectiveness of MRI Screening

The relatively slow adoption of breast MRI as a screening modality of choice is partly due to the limited availability of MRI scanners. However, more important, its use is forestalled by the high costs of the examination. For BRCA mutation carriers, estimates vary widely, but studies in general conclude that breast MRI screening is cost-effective at a willingness to pay \$100,000 per quality adjusted life year gained.^{101–105} However, for women at lower risks most studies show that breast MRI is likely not cost-effective at this level.^{103,106,107} Saadatmand et al showed that the younger you start with MRI screening in women with a familial risk, the less cost-effective it becomes due to the lower frequency of cancers in younger women.¹⁰⁷ Despite the fact that these studies are based on the initial MRI studies, in which MRI performance was lower, many European breast cancer guidelines deviate from the ACS recommendations by excluding women without a very strong familial risk.^{6,108} There are two major drivers for cost-effectiveness: the frequency of undiagnosed breast cancer, and the cost of the MRI scan itself.^{102,103} For women at average risk, the frequency of breast cancer is relatively low, and therefore the number of screens needed to detect a breast cancer is relatively high, which implies that at the current cost of breast MRI, MRI screening in this population is very unlikely to be cost-effective. However, considering the smaller average tumor size, and the propensity of breast MRI to preferentially detect the more aggressive breast cancer subtypes,³¹ adjustment of the screening interval (making it longer) may be considered to improve the cost-effectiveness.

Future Perspectives

To enable wider use of breast MRI and improve cost-effectiveness, the use of shorter and less costly MRI protocols is mandatory. The concept of abbreviated breast MRI was introduced to enable this,^{109,110} reducing the acquisition time to 3 minutes and making reading much faster. Many studies evaluating this concept have been published in recent years, showing that abbreviated protocols provide virtually equal cancer detection performance compared with more extended

multiparametric protocols.¹¹¹ Ultrafast dynamic sequences, with a temporal resolution that is typically below 5 seconds, obtained during contrast inflow can be used to preserve specificity, without penalty in acquisition time.^{112,113} Evaluating only these ultrafast acquisitions was recently shown to yield similar results as reading a full diagnostic protocol, including the late phase of enhancement, T₂, and diffusion-weighted imaging (DWI).¹¹⁴ Unfortunately, breast MRI still relies on the administration of an intravenous contrast agent. This is time-consuming, costly, painful, and has the potential for complications, despite the fact that the currently used macrocyclic contrast agents are very stable and safe.¹¹⁵ MRI techniques that do not rely on contrast administration such as DWI are therefore under evaluation. Studies have so far been unequivocally successful in showing that DWI is at least as sensitive as mammography for the early detection of cancer.^{116–118} Recent advances, such as the use of readout segmented DWI and reduced field of view DWI, have improved image quality,^{119–122} whereas the use of strong background suppression and higher b-values have been shown to improve lesion visibility.^{118,123} However, the limited spatial resolution and the frequent presence of artifacts reduces the value of DWI in the detection of lesions smaller than 12 mm.¹²⁴ Consequently, at this point in time MRI techniques without intravenous contrast administration cannot compete with contrast-enhanced breast MRI for screening purposes. Recently, the *Journal of Magnetic Resonance Imaging* published a large review on abbreviated, ultrafast, and noncontrast-enhanced MRI that summarizes the existing studies.¹¹¹ For a more detailed description of these techniques, which are believed to be important to enable the use of breast MRI in a larger population, the reader is referred to this publication.

Conclusion

The current literature clearly shows that, for early breast cancer detection, contrast-enhanced breast MRI outperforms noncontrast-based alternatives such as mammography and ultrasound in all women at increased risk for breast cancer development, and probably also for women at average risk. The supplemental use of mammography may slightly increase cancer detection over breast MRI alone, but also reduces specificity. Supplemental use of ultrasound only decreases specificity and should be avoided. The earlier detection of cancers with MRI seems to translate into survival benefits in women who participated in the initial MRI screening studies, which is fully in line with the concept of screening for breast cancer and will therefore likely hold true for all indications. A point of concern is that MRI has a higher sensitivity for all types of breast cancer, including low-grade DCIS, and may therefore also increase overdiagnosis. While indications for breast MRI screening are expanding, its wider use is mainly

stalled by the limited availability of MRI scanners and high costs of the examination, along with the need for contrast administration. Abbreviated breast MRI protocols may alleviate these issues, but the use of intravenous contrast agents is still mandatory.

References

- Marmot MG, Altman DG, Cameron DA, Dewar JA, Thompson SG, Wilcox M. The benefits and harms of breast cancer screening: An independent review. *Lancet* 2012;380:1778–1786.
- Tabar L, Dean PB, Chen TH, et al. The incidence of fatal breast cancer measures the increased effectiveness of therapy in women participating in mammography screening. *Cancer* 2018 [Epub ahead of print].
- Weigel S, Heindel W, Heidrich J, Hense HW, Heindinger O. Digital mammography screening: Sensitivity of the programme dependent on breast density. *Eur Radiol* 2017;27:2744–2751.
- Wanders JOP, Holland K, Karssemeijer N, et al. The effect of volumetric breast density on the risk of screen-detected and interval breast cancers: A cohort study. *Breast Cancer Res* 2017;19.
- National Comprehensive Cancer Network. *Breast Cancer Screening and Diagnosis*. 2018. https://www.nccn.org/professionals/physician_gls/pdf/breast-screening.pdf
- Excellence National Institute for Health and Care Excellence. *Familial breast cancer: Classification, care and managing breast cancer and related risks in people with a family history of breast cancer*. 2017. <https://www.nice.org.uk/guidance/cg164>
- Gilbert FJ, Warren RM, Kwan-Lim G, et al. Cancers in BRCA1 and BRCA2 carriers and in women at high risk for breast cancer: MR imaging and mammographic features. *Radiology* 2009;252:358–368.
- Krammer J, Pinker-Domenig K, Robson ME, et al. Breast cancer detection and tumor characteristics in BRCA1 and BRCA2 mutation carriers. *Breast Cancer Res Treat* 2017;163:565–571.
- Heywang SH, Fenzl G, Hahn D, et al. MR imaging of the breast: Comparison with mammography and ultrasound. *J Comput Assist Tomogr* 1986;10:615–620.
- Kaiser WA. MRM promises earlier breast cancer diagnosis. *Diagn Imaging* 1992;14:88–93.
- Carmeliet P, Jain RK. Angiogenesis in cancer and other diseases. *Nature* 2000;407:249–257.
- Knopp MV, Weiss E, Sinn HP, et al. Pathophysiologic basis of contrast enhancement in breast tumors. *J Magn Reson Imaging* 1999;10:260–266.
- Mann RM, Kuhl CK, Kinkel K, Boetes C. Breast MRI: Guidelines from the European Society of Breast Imaging. *Eur Radiol* 2008;18:1307–1318.
- Newell MS, Giess CS, Argus AD, et al. *ACR practice parameter for the performance of contrast enhanced magnetic resonance imaging (MRI) of the breast*. American College of Radiology: Reston, VA; 2018.
- Tilanus-Linthorst MM, Bartels CC, Obdeijn AI, Oudkerk M. Earlier detection of breast cancer by surveillance of women at familial risk. *Eur J Cancer* 2000;36:514–519.
- Kuhl CK, Schmützler RK, Leutner CC, et al. Breast MR imaging screening in 192 women proved or suspected to be carriers of a breast cancer susceptibility gene: Preliminary results. *Radiology* 2000;215:267–279.
- Stoutjesdijk MJ, Boetes C, Jager GJ, et al. Magnetic resonance imaging and mammography in women with a hereditary risk of breast cancer. *J Natl Cancer Inst* 2001;93:1095–1102.
- Kriege M, Brekelmans CT, Boetes C, et al. Efficacy of MRI and mammography for breast-cancer screening in women with a familial or genetic predisposition. *N Engl J Med* 2004;351:427–437.
- Leach MO, Boggis CR, Dixon AK, et al. Screening with magnetic resonance imaging and mammography of a UK population at high familial risk of breast cancer: A prospective multicentre cohort study (MARIBS). *Lancet* 2005;365:1769–1778.
- Warner E, Plewes DB, Hill KA, et al. Surveillance of BRCA1 and BRCA2 mutation carriers with magnetic resonance imaging, ultrasound, mammography, and clinical breast examination. *JAMA* 2004;292:1317–1325.
- Kuhl CK, Schrading S, Leutner CC, et al. Mammography, breast ultrasound, and magnetic resonance imaging for surveillance of women at high familial risk for breast cancer. *J Clin Oncol* 2005;23:8469–8476.
- Hagen AI, Kvistad KA, Maehle L, et al. Sensitivity of MRI versus conventional screening in the diagnosis of BRCA-associated breast cancer in a national prospective series. *Breast* 2007;16:367–374.
- Warner E, Messersmith H, Causer P, Eisen A, Shumak R, Plewes D. Systematic review: Using magnetic resonance imaging to screen women at high risk for breast cancer. *Ann Intern Med* 2008;148:671–679.
- Kuhl C, Weigel S, Schrading S, et al. Prospective multicenter cohort study to refine management recommendations for women at elevated familial risk of breast cancer: The EVA trial. *J Clin Oncol* 2010;28:1450–1457.
- Sardanelli F, Podo F, Santoro F, et al. Multicenter surveillance of women at high genetic breast cancer risk using mammography, ultrasonography, and contrast-enhanced magnetic resonance imaging (the High Breast Cancer Risk Italian 1 Study): Final results. *Invest Radiol* 2011;46:94–105.
- Kuhl CK, Keulers A, Strobel K, Schneider H, Gaisa N, Schrading S. Not all false positive diagnoses are equal: On the prognostic implications of false-positive diagnoses made in breast MRI versus in mammography / digital tomosynthesis screening. *Breast Cancer Res* 2018;20:13.
- Vreemann S, Gubern-Merida A, Schlooz-Vries MS, et al. Influence of risk category and screening round on the performance of an MR imaging and mammography screening program in carriers of the BRCA mutation and other women at increased risk. *Radiology* 2018;286:443–451.
- Cheng YC, Wu NY, Ko JS, et al. Breast cancers detected by breast MRI screening and ultrasound in asymptomatic Asian women: 8 years of experience in Taiwan. *Oncology* 2012;82:98–107.
- Chiarelli AM, Prummel MV, Muradali D, et al. Effectiveness of screening with annual magnetic resonance imaging and mammography: Results of the initial screen from the Ontario high risk breast screening program. *J Clin Oncol* 2014;32:2224–2230.
- Riedl CC, Luft N, Bernhart C, et al. Triple-modality screening trial for familial breast cancer underlines the importance of magnetic resonance imaging and questions the role of mammography and ultrasound regardless of patient mutation status, age, and breast density. *J Clin Oncol* 2015;33:1128–1135.
- Sung JS, Stamler S, Brooks J, et al. Breast cancers detected at screening MR imaging and mammography in patients at high risk: Method of detection reflects tumor histopathologic results. *Radiology* 2016;280:716–722.
- Huzarski T, Gorecka-Szyld B, Huzarska J, et al. Screening with magnetic resonance imaging, mammography and ultrasound in women at average and intermediate risk of breast cancer. *Hered Cancer Clin Pract* 2017;15:4.
- Lo G, Scaranelo AM, Aboras H, et al. Evaluation of the utility of screening mammography for high-risk women undergoing screening breast MR imaging. *Radiology* 2017;285:36–43.
- Kuhl CK, Strobel K, Bieling H, Leutner C, Schild HH, Schrading S. Supplemental breast MR imaging screening of women with average risk of breast cancer. *Radiology* 2017;283:361–370.
- Lee JM, Ichikawa L, Valencia E, et al. Performance benchmarks for screening breast MR imaging in community practice. *Radiology* 2017;285:44–52.
- Cho N, Han W, Han BK, et al. Breast cancer screening with mammography plus ultrasonography or magnetic resonance imaging in women 50 years or younger at diagnosis and treated with breast conservation therapy. *JAMA Oncol* 2017;3:1495–1502.

37. Kuhl CK, Schrading S, Bieling HB, et al. MRI for diagnosis of pure ductal carcinoma in situ: A prospective observational study. *Lancet* 2007;370:485–492.
38. Kriege M, Brekelmans CT, Peterse H, et al. Tumor characteristics and detection method in the MRISC screening program for the early detection of hereditary breast cancer. *Breast Cancer Res Treat* 2007;102:357–363.
39. Phi XA, Saadatmand S, De Bock GH, et al. Contribution of mammography to MRI screening in BRCA mutation carriers by BRCA status and age: Individual patient data meta-analysis. *Br J Cancer* 2016;114:631–637.
40. Obdeijn IM, Winter-Warnars GA, Mann RM, Hooning MJ, Hunink MG, Tilanus-Linthorst MM. Should we screen BRCA1 mutation carriers only with MRI? A multicenter study. *Breast Cancer Res Treat* 2014;144:577–582.
41. Obdeijn IM, Heijnsdijk EA, Hunink MG, Tilanus-Linthorst MM, de Koning HJ. Mammographic screening in BRCA1 mutation carriers postponed until age 40: Evaluation of benefits, costs and radiation risks using models. *Eur J Cancer* 2016;63:135–142.
42. Narayan AK, Visvanathan K, Harvey SC. Comparative effectiveness of breast MRI and mammography in screening young women with elevated risk of developing breast cancer: A retrospective cohort study. *Breast Cancer Res Treat* 2016;158:583–589.
43. Vreemann S, van Zelst JCM, Schlooz-Vries M, et al. The added value of mammography in different age-groups of women with and without BRCA mutation screened with breast MRI. *Breast Cancer Res* 2018;20:84.
44. Berg WA, Zhang Z, Lehrer D, et al. Detection of breast cancer with addition of annual screening ultrasound or a single screening MRI to mammography in women with elevated breast cancer risk. *JAMA* 2012;307:1394–1404.
45. Ohuchi N, Suzuki A, Sobue T, et al. Sensitivity and specificity of mammography and adjunctive ultrasonography to screen for breast cancer in the Japan Strategic Anti-cancer Randomized Trial (J-START): A randomised controlled trial. *Lancet* 2016;387:341–348.
46. Heijnsdijk EA, Warner E, Gilbert FJ, et al. Differences in natural history between breast cancers in BRCA1 and BRCA2 mutation carriers and effects of MRI screening-MRISC, MARIBS, and Canadian studies combined. *Cancer Epidemiol Biomarkers Prev* 2012;21:1458–1468.
47. Bosse K, Graeser M, Gossmann A, Hackenbroch M, Schmutzler RK, Rhiem K. Supplemental screening ultrasound increases cancer detection yield in BRCA1 and BRCA2 mutation carriers. *Arch Gynecol Obstet* 2014;289:663–670.
48. van Zelst JCM, Mus RDM, Woldringh G, et al. Surveillance of women with the BRCA1 or BRCA2 mutation by using biannual automated breast US, MR imaging, and mammography. *Radiology* 2017;285:376–388.
49. Chereau E, Uzan C, Baileysguier C, et al. Characteristics, treatment, and outcome of breast cancers diagnosed in BRCA1 and BRCA2 gene mutation carriers in intensive screening programs including magnetic resonance imaging. *Clin Breast Cancer* 2010;10:113–118.
50. Warner E, Hill K, Causer P, et al. Prospective study of breast cancer incidence in women with a BRCA1 or BRCA2 mutation under surveillance with and without magnetic resonance imaging. *J Clin Oncol* 2011;29:1664–1669.
51. Evans DG, Kesavan N, Lim Y, et al. MRI breast screening in high-risk women: Cancer detection and survival analysis. *Breast Cancer Res Treat* 2014;145:663–672.
52. Saadatmand S, Obdeijn IM, Rutgers EJ, et al. Survival benefit in women with BRCA1 mutation or familial risk in the MRI screening study (MRISC). *Int J Cancer* 2015;137:1729–1738.
53. Moller P, Stormorken A, Jonsrud C, et al. Survival of patients with BRCA1-associated breast cancer diagnosed in an MRI-based surveillance program. *Breast Cancer Res Treat* 2013;139:155–161.
54. Podo F, Santoro F, Di Leo G, et al. Triple-negative versus non-triple-negative breast cancers in high-risk women: Phenotype features and survival from the HIBCRIT-1 MRI-including screening study. *Clin Cancer Res* 2016;22:895–904.
55. Saslow D, Boetes C, Burke W, et al. American Cancer Society guidelines for breast screening with MRI as an adjunct to mammography. *CA Cancer J Clin* 2007;57:75–89.
56. Wernli KJ, DeMartini WB, Ichikawa L, et al. Patterns of breast magnetic resonance imaging use in community practice. *JAMA Intern Med* 2014;174:125–132.
57. Miles R, Wan F, Onega TL, et al. Underutilization of supplemental magnetic resonance imaging screening among patients at high breast cancer risk. *J Womens Health* 2018;27:748–754.
58. Stout NK, Nekhlyudov L, Li L, et al. Rapid increase in breast magnetic resonance imaging use: Trends from 2000 to 2011. *JAMA Intern Med* 2014;174:114–121.
59. Rosenthal ET, Evans B, Kidd J, et al. Increased identification of candidates for high-risk breast cancer screening through expanded genetic testing. *J Am Coll Radiol* 2017;14:561–568.
60. Couch FJ, Shimelis H, Hu C, et al. Associations between cancer predisposition testing panel genes and breast cancer. *JAMA Oncol* 2017;3:1190–1196.
61. Adank MA, Verhoef S, Oldenburg RA, et al. Excess breast cancer risk in first degree relatives of CHEK2 *1100delC positive familial breast cancer cases. *Eur J Cancer* 2013;49:1993–1999.
62. Antoniou AC, Casadei S, Heikkinen T, et al. Breast-cancer risk in families with mutations in PALB2. *N Engl J Med* 2014;371:497–506.
63. Lee JM, Buist DS, Houssami N, et al. Five-year risk of interval-invasive second breast cancer. *J Natl Cancer Inst* 2015;107(7).
64. Schacht DV, Yamaguchi K, Lai J, Kulkarni K, Sennett CA, Abe H. Importance of a personal history of breast cancer as a risk factor for the development of subsequent breast cancer: Results from screening breast MRI. *AJR Am J Roentgenol* 2014;202:289–292.
65. Houssami N, Given-Wilson R, Ciatto S. Early detection of breast cancer: Overview of the evidence on computer-aided detection in mammography screening. *J Med Imaging Radiat Oncol* 2009;53:171–176.
66. Lam DL, Houssami N, Lee JM. Imaging surveillance after primary breast cancer treatment. *AJR Am J Roentgenol* 2017;208:676–686.
67. Robertson C, Arcot Ragupathy SK, Boachie C, et al. The clinical effectiveness and cost-effectiveness of different surveillance mammography regimens after the treatment for primary breast cancer: Systematic reviews registry database analyses and economic evaluation. *Health Technol Assess* 2011;15:v–vi, 1–322.
68. Elmore L, Margenthaler JA. Use of breast MRI surveillance in women at high risk for breast cancer: A single-institutional experience. *Ann Surg Oncol* 2010;17(Suppl 3):263–267.
69. Gweon HM, Cho N, Han W, et al. Breast MR imaging screening in women with a history of breast conservation therapy. *Radiology* 2014;272:366–373.
70. Giess CS, Poole PS, Chikarmane SA, Sippo DA, Birdwell RL. Screening breast MRI in patients previously treated for breast cancer: diagnostic yield for cancer and abnormal interpretation rate. *Acad Radiol* 2015;22:1331–1337.
71. Weinstock C, Campassi C, Goloubeva O, et al. Breast magnetic resonance imaging (MRI) surveillance in breast cancer survivors. *Springerplus* 2015;4:459.
72. Destounis S, Arieno A, Morgan R. Personal history of premenopausal breast cancer as a risk factor for referral to screening breast MRI. *Acad Radiol* 2016;23:353–357.
73. Chung MT, Lourenco AP, Mainiero MB. Screening breast MRI in women with a personal history of breast cancer. *Breast J* 2016;22:252–253.
74. Lehman CD, Lee JM, DeMartini WB, et al. Screening MRI in women with a personal history of breast cancer. *J Natl Cancer Inst* 2016;108(3).
75. Tadros A, Arditi B, Weltz C, Port E, Margolies LR, Schmidt H. Utility of surveillance MRI in women with a personal history of breast cancer. *Clin Imaging* 2017;46:33–36.

76. Choi BH, Choi N, Kim MY, Yang JH, Yoo YB, Jung HK. Usefulness of abbreviated breast MRI screening for women with a history of breast cancer surgery. *Breast Cancer Res Treat* 2018;167:495–502.
77. Morakkabati N, Leutner CC, Schmiedel A, Schild HH, Kuhl CK. Breast MR imaging during or soon after radiation therapy. *Radiology* 2003;229:893–901.
78. Rajaram N, Mariapun S, Eriksson M, et al. Differences in mammographic density between Asian and Caucasian populations: A comparative analysis. *Breast Cancer Res Treat* 2017;161:353–362.
79. Cancer Today. Estimated age-standardized incidence and mortality rates (World) in 2018, all cancers, both sexes, all ages. 2018. Available at: <https://gco.iarc.fr/today/home>
80. Page DL, Dupont WD. Premalignant conditions and markers of elevated risk in the breast and their management. *Surg Clin North Am* 1990;70:831–851.
81. King TA, Pilewskie M, Muhsen S, et al. Lobular carcinoma in situ: A 29-year longitudinal experience evaluating clinicopathologic features and breast cancer risk. *J Clin Oncol* 2015;33:3945–3952.
82. Sung JS, Malak SF, Bajaj P, Alis R, Dershaw DD, Morris EA. Screening breast MR imaging in women with a history of lobular carcinoma in situ. *Radiology* 2011;261:414–420.
83. Friedlander LC, Roth SO, Gavenonis SC. Results of MR imaging screening for breast cancer in high-risk patients with lobular carcinoma in situ. *Radiology* 2011;261:421–427.
84. King TA, Muhsen S, Patil S, et al. Is there a role for routine screening MRI in women with LCIS? *Breast Cancer Res Treat* 2013;142:445–453.
85. Schwartz T, Cyr A, Margenthaler J. Screening breast magnetic resonance imaging in women with atypia or lobular carcinoma in situ. *J Surg Res* 2015;193:519–522.
86. Port ER, Park A, Borgen PI, Morris E, Montgomery LL. Results of MRI screening for breast cancer in high-risk patients with LCIS and atypical hyperplasia. *Ann Surg Oncol* 2007;14:1051–1057.
87. Brandt KR, Scott CG, Ma L, et al. Comparison of clinical and automated breast density measurements: Implications for risk prediction and supplemental screening. *Radiology* 2016;279:710–719.
88. Kerlikowske K, Scott CG, Mahmoudzadeh AP, et al. Automated and clinical breast imaging reporting and data system density measures predict risk for screen-detected and interval cancers: A case-control study. *Ann Intern Med* 2018;168:757–765.
89. Chen SQ, Huang M, Shen YY, Liu CL, Xu CX. Abbreviated MRI protocols for detecting breast cancer in women with dense breasts. *Korean J Radiol* 2017;18:470–475.
90. Chen SQ, Huang M, Shen YY, Liu CL, Xu CX. Application of abbreviated protocol of magnetic resonance imaging for breast cancer screening in dense breast tissue. *Acad Radiol* 2017;24:316–320.
91. Emaus MJ, Bakker MF, Peeters PH, et al. MR imaging as an additional screening modality for the detection of breast cancer in women aged 50–75 years with extremely dense breasts: The DENSE Trial study design. *Radiology* 2015;277:527–537.
92. Kuhl CK. Abbreviated breast MRI for screening women with dense breast: The EA1141 trial. *Br J Radiol* 2018;91:20170441.
93. Welch HG, Prorok PC, O'Malley AJ, Kramer BS. Breast-cancer tumor size, overdiagnosis, and mammography screening effectiveness. *N Engl J Med* 2016;375:1438–1447.
94. American College of Radiology. *BI-RADS atlas*, 5th ed. Reston, VA: ACR; 2013.
95. Strigel RM, Rollenhagen J, Burnside ES, et al. Screening breast MRI outcomes in routine clinical practice: Comparison to BI-RADS benchmarks. *Acad Radiol* 2017;24:411–417.
96. Guindalini RS, Zheng Y, Abe H, et al. Intensive surveillance with bi-annual dynamic contrast-enhanced magnetic resonance imaging downstages breast cancer in BRCA1 mutation carriers. *Clin Cancer Res* 2018 [Epub ahead of print].
97. Warner E, Causer PA, Wong JW, et al. Improvement in DCIS detection rates by MRI over time in a high-risk breast screening study. *Breast J* 2011;17:9–17.
98. Pages EB, Millet I, Hoa D, Doyon FC, Taourel P. Undiagnosed breast cancer at MR imaging: Analysis of causes. *Radiology* 2012;264:40–50.
99. Yamaguchi K, Schacht D, Newstead GM, et al. Breast cancer detected on an incident (second or subsequent) round of screening MRI: MRI features of false-negative cases. *AJR Am J Roentgenol* 2013;201:1155–1163.
100. Vreemann S, Gubern-Merida A, Lardenoije S, et al. The frequency of missed breast cancers in women participating in a high-risk MRI screening program. *Breast Cancer Res Treat* 2018;169:323–331.
101. Plevritis SK, Kurian AW, Sigal BM, et al. Cost-effectiveness of screening BRCA1/2 mutation carriers with breast magnetic resonance imaging. *JAMA* 2006;295:2374–2384.
102. Griebisch I, Brown J, Boggis C, et al. Cost-effectiveness of screening with contrast enhanced magnetic resonance imaging vs X-ray mammography of women at a high familial risk of breast cancer. *Br J Cancer* 2006;95:801–810.
103. Taneja C, Edelsberg J, Weycker D, Guo A, Oster G, Weinreb J. Cost effectiveness of breast cancer screening with contrast-enhanced MRI in high-risk women. *J Am Coll Radiol* 2009;6:171–179.
104. Lee JM, McMahon PM, Kong CY, et al. Cost-effectiveness of breast MR imaging and screen-film mammography for screening BRCA1 gene mutation carriers. *Radiology* 2010;254:793–800.
105. Pataky R, Armstrong L, Chia S, et al. Cost-effectiveness of MRI for breast cancer screening in BRCA1/2 mutation carriers. *BMC Cancer* 2013;13:339.
106. Moore SG, Shenoy PJ, Fanucchi L, Tumei JW, Flowers CR. Cost-effectiveness of MRI compared to mammography for breast cancer screening in a high risk population. *BMC Health Serv Res* 2009;9:9.
107. Saadatmand S, Tilanus-Linthorst MM, Rutgers EJ, et al. Cost-effectiveness of screening women with familial risk for breast cancer with magnetic resonance imaging. *J Natl Cancer Inst* 2013;105:1314–1321.
108. Federatie Medisch Specialisten. Screening (breast cancer). 2018. https://richtlijnendatabase.nl/en/richtlijn/breast_cancer/breast_cancer.html
109. Fischer U, Korthauer A, Baum F, Luftner-Nagel S, Heyden D, Marten-Engelke K. Short first-pass MRI of the breast. *Acta Radiol* 2012;53:267–269.
110. Kuhl CK, Schrading S, Strobel K, Schild HH, Hilgers RD, Bieling HB. Abbreviated breast magnetic resonance imaging (MRI): First postcontrast subtracted images and maximum-intensity projection—a novel approach to breast cancer screening with MRI. *J Clin Oncol* 2014;32:2304–2310.
111. Leithner D, Moy L, Morris EA, Marino MA, Helbich TH, Pinker K. Abbreviated MRI of the breast: Does it provide value? *J Magn Reson Imaging* 2018 [Epub ahead of print].
112. Mann RM, Mus RD, van Zelst J, Geppert C, Karssemeijer N, Platel B. A novel approach to contrast-enhanced breast magnetic resonance imaging for screening high-resolution ultrafast dynamic imaging. *Invest Radiol* 2014;49:579–585.
113. Abe H, Mori N, Tsuchiya K, et al. Kinetic analysis of benign and malignant breast lesions with ultrafast dynamic contrast-enhanced MRI: Comparison with standard kinetic assessment. *AJR Am J Roentgenol* 2016;207:1159–1166.
114. van Zelst JCM, Vreemann S, Witt H-J, et al. Multireader study on the diagnostic accuracy of ultrafast breast magnetic resonance imaging for breast cancer screening. *Invest Radiol* 2018;53:579–586.
115. Runge VM. Dechelation (transmetalation): Consequences and safety concerns with the linear gadolinium-based contrast agents, in view of recent health care rulings by the EMA (Europe), FDA (United States), and PMDA (Japan). *Invest Radiol* 2018;53:571–578.
116. Baltzer PA, Benndorf M, Dietzel M, Gajda M, Camara O, Kaiser WA. Sensitivity and specificity of unenhanced MR mammography (DWI combined with T2-weighted TSE imaging, ueMRM) for the differentiation of mass lesions. *Eur Radiol* 2010;20:1101–1110.

117. Trimboli RM, Verardi N, Cartia F, Carbonaro LA, Sardanelli F. Breast cancer detection using double reading of unenhanced MRI including T1-weighted, T2-weighted STIR, and diffusion-weighted imaging: A proof of concept study. *AJR Am J Roentgenol* 2014;203:674–681.
118. Bickelhaupt S, Laun FB, Tesdorff J, et al. Fast and noninvasive characterization of suspicious lesions detected at breast cancer x-ray screening: Capability of diffusion-weighted MR imaging with MIPs. *Radiology* 2016;278:689–697.
119. Filli L, Ghafoor S, Kenkel D, et al. Simultaneous multi-slice readout-segmented echo planar imaging for accelerated diffusion-weighted imaging of the breast. *Eur J Radiol* 2016;85:274–278.
120. Bogner W, Pinker-Domenig K, Bickel H, et al. Readout-segmented echo-planar imaging improves the diagnostic performance of diffusion-weighted MR breast examinations at 3.0 T. *Radiology* 2012;263:64–76.
121. Barentsz MW, Taviani V, Chang JM, et al. Assessment of tumor morphology on diffusion-weighted (DWI) breast MRI: Diagnostic value of reduced field of view DWI. *J Magn Reson Imaging* 2015;42:1656–1665.
122. Dong H, Li Y, Li H, Wang B, Hu B. Study of the reduced field-of-view diffusion-weighted imaging of the breast. *Clin Breast Cancer* 2014;14:265–271.
123. Stadlbauer A, Bernt R, Gruber S, et al. Diffusion-weighted MR imaging with background body signal suppression (DWIBS) for the diagnosis of malignant and benign breast lesions. *Eur Radiol* 2009;19:2349–2356.
124. Pinker K, Moy L, Sutton EJ, et al. Diffusion-weighted imaging with apparent diffusion coefficient mapping for breast cancer detection as a stand-alone parameter comparison with dynamic contrast-enhanced and multiparametric magnetic resonance imaging. *Invest Radiol* 2018; 53:587–595.