








## Interactive clinical cases

## Extended Abstract

# A patient with permanent atrial fibrillation and very high bleeding risk – when is the optimal time to refer for left atrial appendage occluder device implantation?

 Sandra Prša<sup>1\*</sup>,  
 Ivana Petrović Juren<sup>1</sup>,  
 Ante Anić<sup>2</sup>,  
 Ivana Smoljan<sup>3</sup>,  
 Darija Baković Kramarić<sup>2</sup>,  
 Kristina Milevoj Križić<sup>1</sup>,  
 Andreja Čleković-Kovačić<sup>1</sup>,  
 Vlasta Soukup Podravec<sup>1</sup>,  
 Iva Ladić<sup>1</sup>,  
 Gabriela Bašković<sup>1</sup>

<sup>1</sup>Bjelovar General Hospital, Bjelovar, Croatia

<sup>2</sup>University Hospital Centre Split, Split, Croatia

<sup>3</sup>University Hospital Centre Rijeka, Rijeka, Croatia

**KEYWORDS:** left atrial appendage, thrombus, bleeding risk, Amplatzer Amulet occluder device.

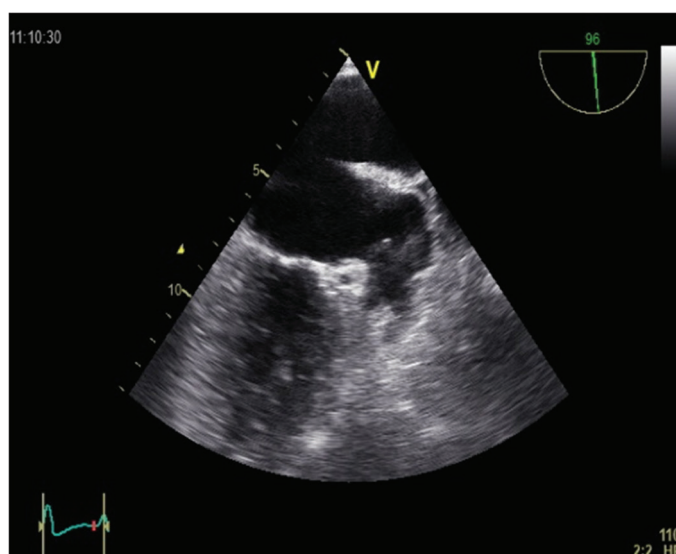
**CITATION:** *Cardiol Croat.* 2019;14(9-10):252-3. | <https://doi.org/10.15836/ccar2019.252>

**\*ADDRESS FOR CORRESPONDENCE:** Sandra Prša, Opća bolnica Bjelovar, A. Mihanovića 8, HR-43000 Bjelovar, Croatia. / Phone: +385-92-284-9891 / E-mail: [sandrajura2001@yahoo.com](mailto:sandrajura2001@yahoo.com)

**ORCID:** Sandra Prša, <https://orcid.org/0000-0001-9639-3918> • Ivana Petrović Juren, <https://orcid.org/0000-0002-2793-3455> Ante Anić, <https://orcid.org/0000-0002-6864-3999> • Ivana Smoljan, <https://orcid.org/0000-0002-9668-291X> Darija Baković Kramarić, <https://orcid.org/0000-0001-6751-5242> • Kristina Milevoj Križić, <https://orcid.org/0000-0003-2115-3076> Andreja Čleković-Kovačić, <https://orcid.org/0000-0002-4532-3597> • Vlasta Soukup Podravec, <https://orcid.org/0000-0002-4605-0068> Iva Ladić, <https://orcid.org/0000-0003-0124-5256> • Gabriela Bašković, <https://orcid.org/0000-0002-5413-873X>

**Introduction:** Most patients with atrial fibrillation (AF) should receive anticoagulant therapy to reduce the risk of systemic embolization. However, there are varying degrees of bleeding risk associated with anticoagulation thus reducing the number of candidates for this therapy. The left atrial appendage (LAA) is the usual source of clot embolisms. Percutaneous approaches, often referred to as LAA exclusion procedures, mechanically prevent embolization of LAA thrombi.<sup>1,2</sup> We consider the placement of percutaneous LAA Occlusion Device (Amplatzer Amulet device) a good choice for patients with high bleeding risk.

**Case report:** We present a male, 67-year-old patient with permanent AF, diabetes mellitus, hypertension, (CHADS VASc Score 3) who was admitted to Department of Neurology with nontraumatic intracerebral hemorrhage twice in the same year. First time during oral anticoagulation therapy with warfarin and second time while receiving dabigatran. Since patient had recurrent bleeding on anticoagulant therapy, and his neurological deficit was fully recovered we considered him as ideal patient for LAA Occlusion Device implantation. A transesophageal echocardiogram (TEE) showed a large thrombus almost protruding from the LAA to the left atrium (**Figure 1**), and treatment with low molecular weight heparin with consecutive monitoring with TEE every six weeks followed mild resolution of thrombus and the patient was sent to interventional cardiologist in University Hospital Centre Split where he was amicably admitted for the life threatening malignant thrombus. After the usual pre-procedural processing including MSCT left atrial angiography, patient was subjected for Amplatzer Amulet Occluding Device 31 mm, with no signs of early complications. Post-procedural patient was receiving



**FIGURE 1.** Large thrombus protruding from the left atrial appendage to the left atrium.

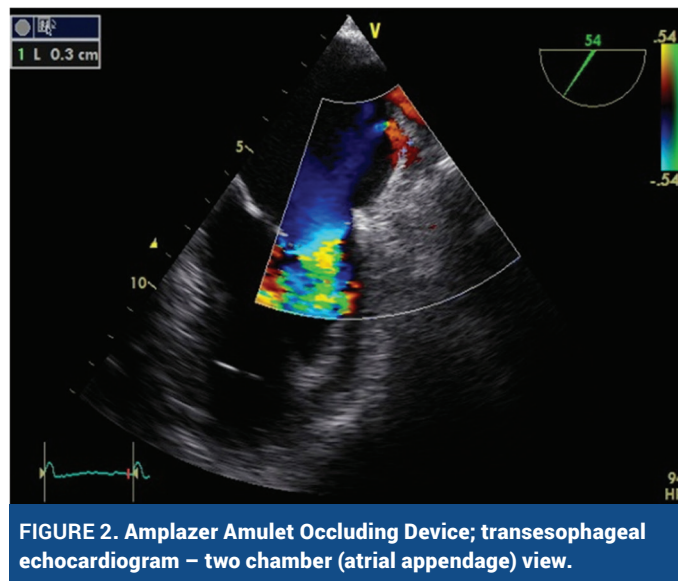
**RECEIVED:**  
August 4, 2019

**ACCEPTED:**  
September 16, 2019



## A patient with permanent atrial fibrillation and very high bleeding risk – when is the optimal time to refer for left atrial appendage occluder device implantation?

dual antiplatelet therapy for six months. Six weeks after implantation TEE exam showed no thrombosis on device, no leak and clots inside the left atrium (**Figure 2**).



**Conclusion:** The importance of the LAA in thromboembolic risk among patients with AF provides the rationale for ligation, amputation, or occlusion of the LAA, especially in patients who are candidates for, but cannot receive oral anticoagulation, or those at high risk for bleeding with oral anticoagulation.

### LITERATURE

1. Tzikas A. Left Atrial Appendage Occlusion with Amplatzer Cardiac Plug and Amplatzer Amulet: a Clinical Trials Update. *J Atr Fibrillation*. 2017 Dec 31;10(4):1651. <https://doi.org/10.4022/jafib.1651>
2. Kirchhof P, Benussi S, Kotecha D, Ahlsson A, Atar D, Casadei B, et al. 2016 ESC Guidelines for the management of atrial fibrillation developed in collaboration with EACTS. *Europace*. 2016 Nov;18(11):1609-1678. <https://doi.org/10.1093/eurpace/euw295>