

# Gluten Challenge Induces Skin and Small Bowel Relapse in Long-Term Gluten-Free Diet–Treated Dermatitis Herpetiformis



JID Open

Eriika Mansikka<sup>1,2</sup>, Kaisa Hervonen<sup>1,2</sup>, Katri Kaukinen<sup>2,3</sup>, Tuire Ilus<sup>4</sup>, Pia Oksanen<sup>4,5</sup>, Katri Lindfors<sup>2</sup>, Kaija Laurila<sup>2</sup>, Minna Hietikko<sup>2</sup>, Juha Taavela<sup>2,6</sup>, Juha Jernman<sup>7</sup>, Päivi Saavalainen<sup>8,9</sup>, Timo Reunala<sup>1,2</sup> and Teea Salmi<sup>1,2</sup>

Dermatitis herpetiformis (DH) is an extraintestinal manifestation of celiac disease causing an itchy, blistering rash. Granular IgA deposits in the skin are pathognomonic for DH, and the treatment of choice is a lifelong gluten-free diet (GFD). Preliminary evidence suggests that there are patients with DH who redevelop gluten tolerance after adherence to a GFD treatment. To evaluate this, we performed a 12-month gluten challenge with skin and small-bowel mucosal biopsy samples in 19 patients with DH who had adhered to a GFD for a mean of 23 years. Prechallenge biopsy was negative for skin IgA and transglutaminase 3 deposits in 16 patients (84%) and indicated normal villous height-to-crypt depth ratios in the small bowel mucosa in all 19 patients. The gluten challenge caused a relapse of the rash in 15 patients (79%) in a mean of 5.6 months; of these 15 patients, 13 had skin IgA and transglutaminase 3 deposits, and 12 had small-bowel villous atrophy. In addition, three patients without rash or immune deposits in the skin developed villous atrophy, whereas one patient persisted without any signs of relapse. In conclusion, 95% of the patients with DH were unable to tolerate gluten even after long-term adherence to a GFD. Therefore, lifelong GFD treatment remains justified in all patients with DH.

*Journal of Investigative Dermatology* (2019) **139**, 2108–2114; doi:10.1016/j.jid.2019.03.1150

## INTRODUCTION

Dermatitis herpetiformis (DH) is an extraintestinal manifestation of celiac disease presenting with an itchy and blistering rash, mainly on the elbows, knees, and buttocks (Bolotin and Petronic-Rosic, 2011; Collin et al., 2017). The diagnosis of DH is confirmed with direct immunofluorescence examination showing granular IgA deposits in the papillary dermis of perilesional skin (Zone et al., 1996). Marked gastrointestinal symptoms are rare in DH, although approximately 75% of patients develop villous atrophy in the small bowel mucosa (Mansikka et al., 2017). Even in patients without obvious

changes in the villous structures, intestinal celiac-type inflammation with increased densities of intraepithelial lymphocytes (IELs)—in particular  $\gamma\delta^+$  IELs (Savilahti et al., 1992)—is evident. Parallel to celiac disease, transglutaminase 2 (TG2)-targeted autoantibodies are frequently observed in the serum and small-bowel mucosa in untreated DH and are known to respond to a gluten-free diet (GFD) (Dieterich et al., 1999; Salmi et al., 2014). However, in DH, the antigen for deposited cutaneous IgA is epidermal transglutaminase (e.g., transglutaminase 3 [TG3]), another member of the transglutaminase family along with TG2, and IgA-class TG3 antibodies (Abs) are often observed in the serum of patients with DH (Hull et al., 2008; Sárdy et al., 2002).

In DH, the treatment of choice is a GFD, which treats both the rash and small-bowel villous atrophy (Fry et al., 1973). However, adherence to the diet must be strict; and it has been observed that the rash typically disappears after a mean duration of 2 years (Garioch et al., 1994; Reunala et al., 1977), but IgA and TG3 deposits in the skin are known to persist much longer (Hietikko et al., 2018). It is generally accepted that in DH and celiac disease, adherence to GFD treatment should be lifelong (Caproni et al., 2009; Ludvigsson et al., 2014). There are, however, a few studies that show that up to 18% of patients with DH seem to acquire a tolerance to gluten during the GFD and do not relapse upon the reintroduction of gluten (Bardella et al., 2003; Garioch et al., 1994; Leonard et al., 1983; Paek et al., 2011). Likewise, there are sporadic reports demonstrating the development of gluten tolerance during a GFD in patients with celiac disease (Hopman et al., 2008; Matysiak-Budnik et al., 2007).

<sup>1</sup>Department of Dermatology, Tampere University Hospital, Tampere, Finland; <sup>2</sup>Celiac Disease Research Center, Tampere University, Faculty of Medicine and Health Technology, Tampere, Finland; <sup>3</sup>Department of Internal Medicine, Tampere University Hospital, Tampere, Finland; <sup>4</sup>Department of Gastroenterology and Alimentary Tract Surgery, Tampere University Hospital, Tampere, Finland; <sup>5</sup>Faculty of Medicine and Health Technology, Tampere University, Tampere, Finland; <sup>6</sup>Department of Internal Medicine, Central Hospital of Central Finland, Jyväskylä, Finland; <sup>7</sup>Department of Pathology, Fimlab Laboratories, Tampere, Finland; <sup>8</sup>Research Programs Unit, Immunobiology, University of Helsinki, Helsinki, Finland; and <sup>9</sup>Department of Medical and Clinical Genetics, University of Helsinki, Helsinki, Finland

Correspondence: Teea Salmi, Department of Dermatology, Tampere University Hospital, PO Box 2000, 33521 Tampere, Finland. E-mail: [teea.salmi@staff.uta.fi](mailto:teea.salmi@staff.uta.fi)

Abbreviations: Ab, antibody; DH, dermatitis herpetiformis; EmA, endomysial antibody; GFD, gluten-free diet; IEL, intraepithelial lymphocyte; SD, standard deviation; TG2, transglutaminase 2; TG3, transglutaminase 3

Received 14 December 2018; revised 11 March 2019; accepted 25 March 2019; accepted manuscript published online 15 April 2019; corrected proof published online 27 June 2019

**Table 1. Gluten Challenge Outcome in 19 Patients with Dermatitis Herpetiformis**

Patient/Sex/Age	Duration of GFD Before Challenge, Y	Challenge Outcome			Challenge Duration, Mo	Skin IgA and TG3 Deposits Pre/Postchallenge	Serum TG3 Abs <sup>7</sup> Pre/Postchallenge
		Rash	Villous Atrophy <sup>2</sup>	Serum TG2-Targeted Abs <sup>4</sup>			
1/M/49	5	+	+	–	1	+/+ <sup>6</sup>	–/–
2/M/61	5	+	–	–	2	+/+ <sup>6</sup>	–/–
3/M/60	24	+	+ <sup>3</sup>	+	3	–/+	–/+
4/M/41	20	+	+	+	3	–/+	–/+
5/M/65	24	+	+ <sup>3</sup>	+	3	–/+	–/+
6/F/56	31	+	+ <sup>3</sup>	+	3	–/–	–/+
7/M/47	14	+	+ <sup>3</sup>	+	3	–/+	–/+
8/M/72	15	+	+ <sup>3</sup>	+	4	–/+	+/+ <sup>6</sup>
9/M/51	8	+	+ <sup>3</sup>	+	4	–/–	–/+
10/F/55	40	+	+	–	6	–/+	–/+
11/F/68	33	+	+ <sup>3</sup>	+	9	–/+	–/+
12/F/59	34	+	– <sup>3</sup>	+	9	–/+	–/–
13/M/58	18	+	+	+	10	–/+	–/+
14/M/66	34	+	+	–	12	–/+	–/–
15/F/71	34 <sup>1</sup>	+	–	–	12	+/+	–/+
16/M/56	22	–	+ <sup>3</sup>	+ <sup>5</sup>	4	–/–	+/+ <sup>6</sup>
17/F/37	9	–	+ <sup>3</sup>	+ <sup>5</sup>	4	–/–	–/–
18/M/68	22 <sup>1</sup>	–	+	–	12	–/–	–/–
19/M/58	36 <sup>1</sup>	–	–	–	12	–/–	–/–
Mean Age at Prechallenge, Y (Range)	Mean Duration of GFD, Y (Range)	Rash, n (%)	Villous Atrophy, n (%)	Serum TG2-Targeted Abs, n (%)	Mean Duration (Range)	Negative to Positive, n (%)	Negative to Positive, n (%)
58 (37–72)	23 (5–40)	15 (79)	15 (79)	12 (63)	6.1 (1–12)	10 (53)	10 (53)

Abbreviations: Ab, antibody; F, female; GFD, gluten-free diet; M, male; Mo, month; TG, transglutaminase; Y, year.

<sup>1</sup>Dietary lapses 1–5 times per month.

<sup>2</sup>Villous height-to-crypt depth ratio < 2.0.

<sup>3</sup>TG2-specific IgA deposits in the small bowel mucosa.

<sup>4</sup>Serum TG2 antibodies  $\geq$  3.0 AU/ml and endomysial antibody titer 1: $\geq$ 5.

<sup>5</sup>Challenge discontinued because of appearance of serum TG2-targeted antibodies.

<sup>6</sup>At postchallenge, deposits more intense or antibody levels more increased.

<sup>7</sup>TG3 antibodies > 30 AU/ml.

The aim of this study was to investigate in detail whether gluten tolerance may exist in patients with DH after long-term adherence to a GFD. The study specifically focused on examining the skin TG3 and IgA immune response during gluten reintroduction in treated subjects with DH. To address these issues, a gluten challenge of up to 12 months was performed in volunteering patients with DH in remission, and the reappearance of the rash, skin IgA and TG3 deposits, serum TG2- and TG3-targeted Abs, and small bowel mucosal deterioration were examined.

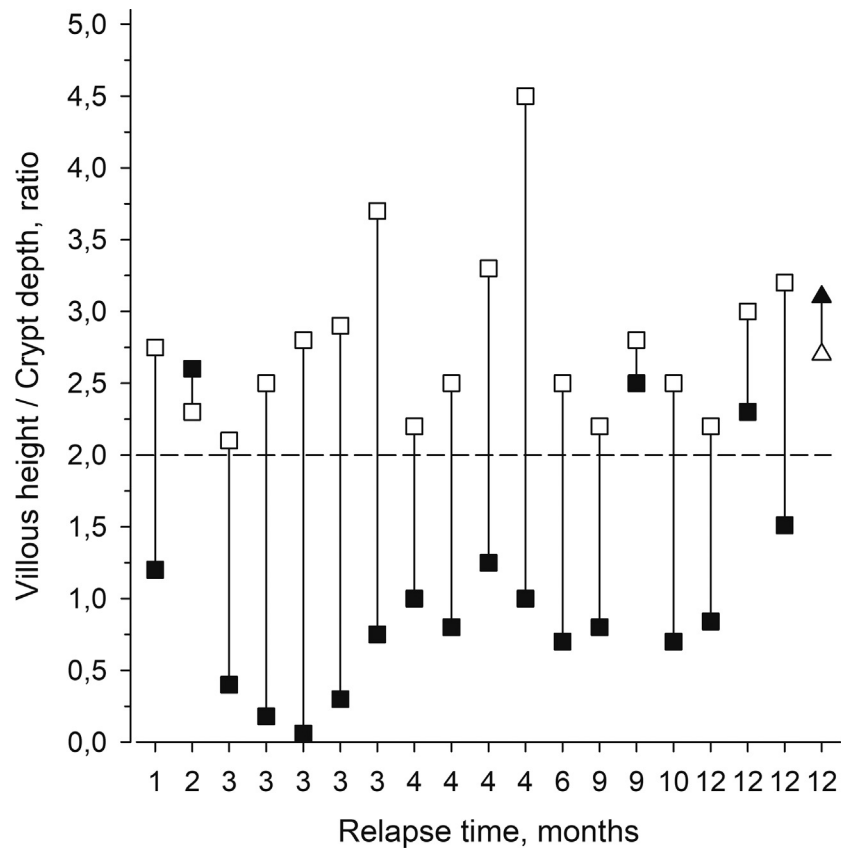
## RESULTS

Of the 19 patients with DH who volunteered for this study, 13 were male and 6 were female, and their mean age was 58 years (see Table 1). At the prechallenge examination, none of the 19 patients with DH exhibited a rash, and 16 patients (84%) did not have IgA or TG3 deposits in the skin. Serum TG2-targeted Abs (TG2 and endomysial Abs [EmAs]) were negative in all patients, and two had slightly elevated TG3 Ab levels (40 and 41 AU/ml). The small-bowel villous height-to-crypt depth ratio was normal in all 19 patients (see Figure 1), and none had TG2-specific IgA deposits in the

small bowel mucosa. Sixteen patients carried HLA-DQ2 (three homozygous) haplotypes, and three carried HLA-DQ8 haplotypes.

The gluten challenge led to the reappearance of the DH rash in 15 patients (79%) in a mean of 5.6 (range, 1–12) months (see Table 1). At postchallenge, 12 of these patients evinced small-bowel mucosal villous atrophy, and 10 patients with a rash had elevated levels of serum TG2-targeted Abs. However, one patient (patient 12, see Table 1) presenting with a rash but a normal villous height-to-crypt depth ratio at relapse showed a marked increase in the densities of CD3<sup>+</sup> (from 31 cells/mm at prechallenge to 91 cells/mm at postchallenge) and  $\gamma\delta^+$  (from 10.5 cells/mm at prechallenge to 38.3 cells/mm at postchallenge) IELs. Two patients who did not develop a rash during the challenge (patients 16 and 17, see Table 1) developed high levels of serum IgA-class TG2-targeted Abs (TG2 Ab levels 100 and 54 AU/ml, EmA titers 1:1000 and 1:500, respectively), because of which the challenge was discontinued at 4 months. The small bowel biopsy showed villous atrophy in both patients. In addition, one patient (patient 18, see Table 1) had no rash or serum TG2-targeted Abs, but the small bowel biopsy performed at

**Figure 1. Villous height-to-crypt depth ratios in 19 gluten-challenged patients with dermatitis herpetiformis at pre- and at postchallenge.** Eighteen patients experienced relapse during the challenge (pre- □ and postchallenge ■). One patient (pre Δ and postchallenge ▲) did not relapse during the challenge. Values above the dashed line are considered normal. The two bars on the right-hand side show mean villous height-to-crypt depth ratios with 95% CIs at pre- and postchallenge depicted with ○ and ●, respectively. CI, confidence interval.



12 months according to the study protocol disclosed villous atrophy. Thus, a relapse was demonstrated in 18 gluten-challenged patients (95%) with DH after a mean of 5.8 months (see Table 1). The remaining patient (patient 19, see Table 1) did not exhibit any skin or gastrointestinal symptoms during the challenge, and at the final examination at 12 months, the small-bowel villous structures were normal, as were the densities of CD3<sup>+</sup> and γδ<sup>+</sup> IELs. According to the dietary diary, the patient's gluten consumption had been at least 8 g of gluten per day. After 2 years on a gluten-containing diet, the patient was still asymptomatic, and the skin IgA and serum TG2- and TG3-targeted Abs were negative.

During the gluten challenge, skin IgA became positive in 10 patients with DH, who also developed a rash (see Table 1). In addition, two of the three patients with the positive skin IgA findings at prechallenge (patients 1 and 2, see Table 1) showed more intense fluorescence after the challenge. In double staining, TG3 was found to colocalize with IgA in all skin biopsy samples. Two patients (patients 6 and 9, see Table 1) with the reappearance of the typical DH rash remained negative for skin IgA and TG3 deposits. In both patients, the rash was mild and had appeared a few days to 2 weeks before the skin biopsy samples were taken. However, both had markedly elevated levels (189 AU/ml) of serum TG3 Abs at this time.

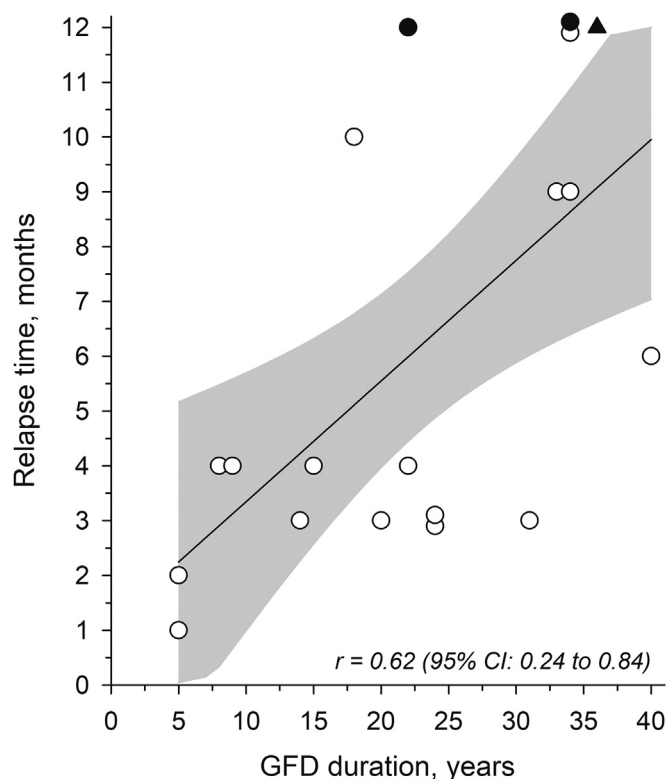
When the prechallenge data were compared to the postchallenge data, significant increase in the median levels of serum Abs was noted: TG3 Abs from 4 (range, 0–41) to 89 (range, 5–189) AU/ml; TG2 Abs from 0 to 12 (range, 0–100)

AU/ml; and EmA titers from 0 to 1:200 (range, 0–1:4000) ( $P < 0.001$ , in all analyses). In the small-bowel biopsy samples, the mean villous height-to-crypt depth ratio (see Figure 1) decreased significantly from 2.8 (standard deviation [SD] 0.59) to 1.2 (SD 0.87) ( $P < 0.001$ ), whereas the mean densities of CD3<sup>+</sup> and γδ<sup>+</sup> IELs increased significantly from 40 (SD 15) to 74 (SD 29) cells/mm ( $P < 0.001$ ) and from 10.8 (SD 8.0) to 16.5 (SD 11.3) cells/mm ( $P = 0.018$ ), respectively. The Dermatology Life Quality Index mean score increased significantly ( $P < 0.001$ ) from 0.11 (SD 0.32) at prechallenge to 1.58 (SD 2.04) at postchallenge. The total Gastrointestinal Symptom Rating Scale score showed no significant change ( $P = 0.22$ ) with mean scores of 1.66 (SD 0.55) and 1.86 (SD 0.73).

The duration of the GFD before the challenge was shown to correlate significantly with the relapse time ( $r = 0.62$ , confidence interval = 0.24–0.84; see Figure 2), but age at the time of the DH diagnosis was found not to correlate with the relapse time ( $r = -0.23$ , confidence interval: -0.62 to 0.25).

## DISCUSSION

In this study featuring 19 GFD-treated patients with DH in remission, a gluten challenge was shown to induce relapse in 95% of the patients. The vast majority (15 of 19 patients, 79%) of the relapsed patients experienced a DH rash, and most also developed small-bowel mucosal villous atrophy. In addition, three relapsed patients with no rash exhibited progression to villous atrophy. The remaining patients, however, did not manifest any signs of DH or celiac disease during 2 years on a normal gluten-containing diet.



**Figure 2. Correlation between the duration of a GFD before the study (years) and relapse time (months) in 19 gluten-challenged patients with dermatitis herpetiformis.** The 95% CI of the correlation curve is shown in gray. Patients following a strict GFD before the challenge are marked with ○, and those with a history of dietary lapses are marked with ●. One patient not relapsing during the challenge and with a history of dietary lapses in GFD before the challenge is marked with ▲. CI, confidence interval; GFD, gluten-free diet.

We are aware of two previously conducted gluten challenge studies in adults with DH. Parallel results to ours were found in a study by Leonard et al. (1983): 11 out of 12 patients (92%) with DH relapsed with a rash, and of these, 7 patients (64%) also developed villous atrophy. Bardella et al. (2003) reported 31 patients with DH in whom the rash relapsed within 6 months on a gluten challenge. However, they also observed seven patients (18% of the study group) who did not manifest any type of relapse in the skin or small bowel during the prolonged gluten challenge. It must be noted that these seven patients had been diagnosed in childhood, and compliance with a GFD in these nonrelapsed patients with DH had been only moderate or poor before the challenge. Therefore, the authors suggested that the ingestion of small doses of gluten from childhood may induce immune tolerance (Bardella et al., 2003). Supporting this, the development of tolerance to gluten has also been reported in patients with celiac disease, especially when they have been diagnosed in childhood and continued to eat a normal gluten-containing diet (Hopman et al., 2008; Matysiak-Budnik et al., 2007). In this study, none of the patients had been diagnosed in childhood, and moreover, our previous study on GFD-treated children with DH did not find any patients achieving tolerance to gluten (Hervonen et al., 2014). Furthermore, three of the patients with DH from this

series reported dietary lapses when adhering to a GFD, and two of these patients relapsed. The only patient not relapsing during the challenge was documented to consume enough gluten to cause villous atrophy (Lähdeaho et al., 2011). However, this patient had been on a GFD for 36 years, which might cause a delayed DH relapse. Hence, a longer follow-up than 2 years on a normal gluten-containing diet is mandatory before a final conclusion of redeveloped gluten tolerance can be drawn.

In this study, 15 of the gluten-challenged patients with DH developed villous atrophy, and of these, three patients had no rash or skin IgA or TG3 deposits. It has been previously shown that the phenotype of celiac disease can change, especially from the classical disease to DH (Salmi et al., 2015), but it is also probable that the patients with DH without the rash at postchallenge would have developed skin symptoms if gluten exposure had been prolonged. Nonetheless, the results of this study suggest that the gut could be the initial site of the gluten-induced autoimmune reaction, that is, celiac disease, and it is only thereafter that the skin become affected, that is, DH develops (Collin et al., 2017; Sárdy et al., 2002). Nevertheless, we also observed that in three patients with DH who relapsed with the rash, villous atrophy had not developed. It is widely recognized that in celiac disease, small-bowel mucosal changes develop gradually, and villous atrophy is only the end stage of the disease process and not evident in all affected individuals (Kurppa et al., 2009). For instance, the presence of small-bowel mucosal TG2-specific IgA deposits can precede villous atrophy in celiac disease (Koskinen et al., 2008), and the deposits have been shown to occur also in patients with DH with normal small bowel mucosa (Salmi et al., 2014). In agreement with this, one gluten-challenged patient with DH with no villous atrophy had intestinal TG2-specific IgA deposits and increased densities of CD3<sup>+</sup> and  $\gamma\delta^+$  IELs. In addition, this patient further showed significant levels of TG2-targeted Abs in the serum, also suggesting an ongoing gluten-induced inflammatory response in the small bowel (Katz et al., 2011; Kumar et al., 2001).

At prechallenge, 16 patients were found not to have IgA and TG3 deposits in the skin. These deposits are considered pathognomonic for untreated DH (Donaldson et al., 2007; Sárdy et al., 2002) and are known to resolve slowly during the GFD treatment (Hietikko et al., 2018). In the previous challenge studies by Leonard et al. (1983) and Bardella et al. (2003), 24% and 42% of the patients, respectively, were found not to have IgA deposits in the skin. In these two studies, the patients had adhered to GFD treatment for a mean of 8 years, whereas in this study, the mean duration was 23 years, that is, almost three times longer. This shows that the likelihood of testing negative for skin IgA deposits increases parallel to the duration of the GFD treatment. It is, however, intriguing why skin IgA and TG3 deposits persist for several years after the rash and small-bowel villous atrophy have resolved in patients on a GFD (Hietikko et al., 2018). The explanation might be that IgA and TG3 are deposited in the papillary dermis as immune aggregates in which the TG3 enzyme is active, resulting in covalent cross-linking of the complex to dermal structures (Taylor et al., 2015). In contrast to the very slow disappearance from the skin of a patient on a GFD, this

study documented a rather rapid reappearance (after 3–12 months) of both IgA and TG3 in ten challenged patients, which is to our knowledge a previously unreported finding.

This study also examined whether skin IgA and TG3 aggregates reappear simultaneously with the rash. Coincidental appearance was shown to occur in ten challenged patients. Unexpectedly, two patients developed the DH rash but remained skin IgA- and TG3-negative, though they had markedly elevated TG3 Ab levels in the serum. Skin biopsy samples were taken from the perilesional skin of both patients (Donaldson et al., 2007; Zone et al., 1996), making it unlikely that the results are false negatives. However, there is a possibility that with a short-term rash, the quantity of IgA and TG3 in these two patients was so minute that they were not detectable by the conventional technology that was used. Skin lesions in DH have been previously produced experimentally by the application of potassium iodide, and these studies have shown the activation of elastase and urokinase plasminogen activator enzymes but no alteration in the intensity of IgA deposits (Airola et al., 1997; Reitamo et al., 1981). Furthermore, Taylor and Zone (2018) showed that potassium iodine directly activates IgA-bound TG3 in DH skin and suggested that lesion development is likely dependent on the aberrant activity of the TG3 enzyme.

The major strengths of this study were a well-defined long-term GFD-treated study group from our prospectively collected large DH series (Salmi et al., 2011) and the thoroughly conducted gluten challenge with regular follow-up visits and clinical, serological, and small-bowel mucosal biopsy end points. A limitation, however, was the relatively small number of patients, as was the comparatively short follow-up time for the nonrelapsed patient with DH.

In conclusion, this 12-month gluten challenge study in adult patients with DH showed that 95% of the patients had not achieved tolerance to gluten even after long-term GFD treatment. The gluten challenge was shown to induce a DH rash in the majority of the patients, but intriguingly in a few challenged patients, only small-bowel mucosal deterioration was documented. Moreover, IgA and TG3 aggregates in the skin were not disclosed in every patient with a DH rash. At present, a lifelong adherence to GFD seems justified in all patients with DH.

## MATERIALS AND METHODS

### Patients and gluten challenge

A total of 19 patients with DH on a GFD from our prospectively collected DH series at Tampere University Hospital participated in the study (see Table 1) (Salmi et al., 2011).

The inclusion criteria were as follows: a diagnosis of DH based on the typical clinical picture, the presence of granular IgA deposits in the papillary dermis with direct immunofluorescence examination, adherence to a GFD for at least 5 years, and absence of skin symptoms for at least 3 years. The exclusion criteria were as follows: age > 80 years, severe cardiovascular disease, previous malignancies, and the use of dapson or immunosuppressive or anticoagulation medication other than acetylsalicylic acid. At the time of the diagnosis of DH, the mean age of the study participants was 35 (range, 19–57) years, and twelve patients (86%) with available data had small-bowel villous atrophy, and two (14%) had normal villous architecture in the small bowel mucosa.

Before the gluten challenge, the patients had been on a GFD for a mean of 23 (range, 5–40) years. Sixteen patients adhered to the diet strictly, and three reported having 1–5 dietary lapses per month.

The study protocol was approved by the Regional Ethics Committee of Tampere University Hospital (R16039), and all study participants gave their written informed consent.

After the prechallenge investigations, the gluten challenge was initiated by giving the patients 200 g of commercially available wheat bread to be consumed daily for 3 days (Anderson et al., 2000). A follow-up visit was conducted at day 6, and subsequently, the patients commenced a normal gluten-containing diet with a minimum of 10 g of wheat (i.e., about 1 g of gluten) per day. A follow-up telephone call was conducted after 3 weeks, and regular follow-up visits were made every 3 months until the final examination at 12 months. The patients were advised to contact the researchers if they noticed skin or gastrointestinal symptoms, or if they experienced any medical problems during the challenge. In such cases, an extra visit was arranged at the outpatient clinic to consider whether the challenge should be discontinued.

### Clinical and dietary evaluation and questionnaires

At each study visit, patients were examined for the presence of skin, gastrointestinal, and other celiac disease–related signs. To ensure the adequate consumption of gluten, a 3-day dietary diary was filled out by the study participants before every follow-up visit and analyzed by a dermatologist experienced in GFD treatment.

Dermatology Life Quality Index and Gastrointestinal Symptom Rating Scale questionnaires assessing the quality of life and the presence of gastrointestinal symptoms were filled out by the patients during the study visits. The Dermatology Life Quality Index is used in dermatological diseases, and it includes six sections: symptoms and feelings, daily activities, leisure, work and school, personal relationships, and treatment unit. Higher scores indicate decreased quality of life (Finlay and Khan, 1994). The Gastrointestinal Symptom Rating Scale has been widely used in previous celiac disease studies (Ludvigsson et al., 2018; Viljamaa et al., 2005), and it includes five categories: diarrhea, indigestion, constipation, abdominal pain, and reflux. Higher scores indicate more severe symptoms (Svedlund et al., 1988).

### Skin and small-bowel biopsy samples

Skin and small-bowel biopsy samples were obtained at prechallenge and the end of the gluten challenge to detect findings compatible with DH and/or celiac disease. The skin biopsy sample was taken from uninvolved elbow skin or perilesional skin when the rash had appeared. The samples were fixed in optimal cutting temperature compound (Tissue-Tek O.C.T. Compound, Sakura Finetek USA, Torrance, CA), snap-frozen in liquid nitrogen, and stored at  $-70^{\circ}\text{C}$  until examined. To investigate IgA deposits, sections cut from the samples were stained with TRITC-conjugated goat anti-human IgA (1:50) (A18786, Life Technologies, Frederick, MD). For the examination of TG3 deposits, sections were stained with FITC-conjugated rabbit polyclonal TG3 antibody (1:100) (A030, ZEDIRA GmbH, Darmstadt, Germany). All sections were further double stained for IgA and TG3 as previously described (Hietikko et al., 2018).

During gastroscopy, 6–8 forceps biopsy samples were obtained from the distal part of the duodenum, and at least two samples were stained with hematoxylin and eosin and investigated with light microscopy. At least three well-oriented villous crypt units were measured, and the mean was given as a result. A ratio over 2.0 was considered normal. The remaining samples were freshly embedded

in OCT, snap-frozen in liquid nitrogen, and stored at  $-70^{\circ}\text{C}$ . Stainings of  $\text{CD3}^{+}$  and  $\gamma\delta^{+}$  IELs was carried out on 5- $\mu\text{m}$ -thick frozen sections, and the normal values were  $<37$  cells/mm for  $\text{CD3}^{+}$  and  $<4.3$  cells/mm for  $\gamma\delta^{+}$  IELs (Järvinen et al., 2003). Small-bowel TG2-targeted IgA deposits were studied from unfixed, frozen, 5- $\mu\text{m}$ -thick small-bowel mucosal sections by direct immunofluorescence as described by Korponay-Szabó et al. (2004).

### Serological investigations

Serological investigations were performed at each study visit. The investigated TG2-targeted Abs were TG2 Abs and EmAs (Korponay-Szabó et al., 2003). TG2 Abs were determined with a commercially available ELISA kit (Celikey, Phadia, GmbH, Freiburg, Germany) as previously described (Dieterich et al., 1999), and values  $\geq 3.0$  AU/ml were considered positive. Serum EmA was measured with an indirect immunofluorescence method with human umbilical cord as a substrate, and a titer of  $1:\geq 5$  was regarded as positive (Ladinszer et al., 1994). In cases where TG2-targeted Abs were found to convert to positive, the challenge was discontinued, and post-challenge investigations were carried out. TG3 Abs were determined with a commercially available ELISA kit (Immundiagnostik, Bensheim, Germany) as previously described (Reunala et al., 2015), and values  $>30$  AU/ml were considered positive. Elevation of serum TG3 Abs alone was not considered a reliable marker of DH or celiac disease relapse and thus was not considered a sufficient reason for challenge discontinuation. HLA DQ2 and DQ8 genotypes were determined using the Olerup SSP DQB1 low-resolution kit (Olerup SSP AB, Saltsjöbaden, Sweden/Qiagen Vertriebs GmbH, Vienna, Austria).

### Statistical analysis

Statistical comparisons within-subjects were performed by permutation test or Wilcoxon matched-pairs signed rank test with exact *P*-values. Correlations were estimated by Spearman correlation coefficient method. The normality of the variables was tested by using the Shapiro-Wilk *W* test. Stata 15.0 (StataCorp LP, College Station, TX) statistical package was used for the analysis.

### Data availability statement

The data that support the findings of this study are available on request from the corresponding author. The data are not publicly available because of Finnish legislation concerning patient-related data.

### ORCID

Eriika Mansikka: <https://orcid.org/0000-0002-3358-3922>  
 Kaisa Hervonen: <https://orcid.org/0000-0002-6759-8399>  
 Katri Kaukinen: <https://orcid.org/0000-0002-5046-8133>  
 Tuire Ilus: <https://orcid.org/0000-0002-7493-4776>  
 Pia Oksanen: <https://orcid.org/0000-0003-3480-4819>  
 Katri Lindfors: <https://orcid.org/0000-0001-7417-5151>  
 Kaija Laurila: <https://orcid.org/0000-0001-6895-7931>  
 Minna Hietikko: <https://orcid.org/0000-0002-9966-5306>  
 Juha Taaavela: <https://orcid.org/0000-0003-3948-9555>  
 Juha Jernman: <https://orcid.org/0000-0002-5927-962X>  
 Päivi Saavalainen: <https://orcid.org/0000-0002-1399-1689>  
 Timo Reunala: <https://orcid.org/0000-0002-6271-5189>  
 Teea Salmi: <https://orcid.org/0000-0001-7459-4938>

### CONFLICT OF INTEREST

The authors state no conflict of interest.

### ACKNOWLEDGMENTS

This work was supported by the Academy of Finland, the Sigrid Juselius Foundation, The Finnish Medical Foundation, and the Competitive State Research Financing of the Expert Responsibility area of Tampere University Hospital (grants 9T018, 9U019, 9U053, and 9V059).

### AUTHOR CONTRIBUTIONS

Conceptualization: KH, KK, TR, TS; Data Curation: EM, KH, TR, TS; Formal Analysis: EM, KH, TR, TS; Funding Acquisition: TS, KK, KLi; Investigation: EM, KH, TI, PO, TS; Methodology: EM, KK, KLi, KLa, MH, JT, JJ, PS, TR, TS; Supervision: KH, TR, TS; Writing - Original Draft Preparation: EM, KH, KK, TI, PO, KLi, KLa, MH, JT, JJ, PS, TR, TS; Writing - Review and Editing: EM, TR, TS

### REFERENCES

- Airola K, Reunala T, Salo S, Saarialho-Kere UK. Urokinase plasminogen activator is expressed by basal keratinocytes before interstitial collagenase, stromelysin-1, and laminin-5 in experimentally induced dermatitis herpetiformis lesions. *J Invest Dermatol* 1997;108:7–11.
- Anderson RP, Degano P, Godkin AJ, Jewell DP, Hill AV. In vivo antigen challenge in celiac disease identifies a single transglutaminase-modified peptide as the dominant A-gliadin T-cell epitope. *Nat Med* 2000;6:337–42.
- Bardella MT, Fredella C, Trovato C, Ermacora E, Cavalli R, Saladino V, et al. Long-term remission in patients with dermatitis herpetiformis on a normal diet. *Br J Dermatol* 2003;149:968–71.
- Bolotin D, Petronic-Rosic V. Dermatitis herpetiformis. Part I. Epidemiology, pathogenesis, and clinical presentation. *J Am Acad Dermatol* 2011;64:1017–24; quiz 1025–6.
- Caproni M, Antiga E, Melani L, Fabbri P, Italian Group for Cutaneous Immunopathology. Guidelines for the diagnosis and treatment of dermatitis herpetiformis. *J Eur Acad Dermatol Venereol* 2009;23:633–8.
- Collin P, Salmi TT, Hervonen K, Kaukinen K, Reunala T. Dermatitis herpetiformis: a cutaneous manifestation of coeliac disease. *Ann Med* 2017;49:23–31.
- Dieterich W, Laag E, Bruckner-Tuderman L, Reunala T, Kárpáti S, Zágonyi T, et al. Antibodies to tissue transglutaminase as serologic markers in patients with dermatitis herpetiformis. *J Invest Dermatol* 1999;113:133–6.
- Donaldson MR, Zone JJ, Schmidt LA, Taylor TB, Neuhausen SL, Hull CM, et al. Epidermal transglutaminase deposits in perilesional and uninvolved skin in patients with dermatitis herpetiformis. *J Invest Dermatol* 2007;127:1268–71.
- Finlay AY, Khan GK. Dermatology Life Quality Index (DLQI)—a simple practical measure for routine clinical use. *Clin Exp Dermatol* 1994;19:210–6.
- Fry L, Riches DJ, Seah PP, Hoffbrand AV. Clearance of skin lesions in dermatitis herpetiformis after gluten withdrawal. *Lancet* 1973;1:288–91.
- Garioch JJ, Lewis HM, Sargent SA, Leonard JN, Fry L. 25 years' experience of a gluten-free diet in the treatment of dermatitis herpetiformis. *Br J Dermatol* 1994;131:541–5.
- Hervonen K, Salmi TT, Kurppa K, Kaukinen K, Collin P, Reunala T. Dermatitis herpetiformis in children: a long-term follow-up study. *Br J Dermatol* 2014;171:1242–3.
- Hietikko M, Hervonen K, Salmi T, Ilus T, Zone JJ, Kaukinen K, et al. Disappearance of epidermal transglutaminase and IgA deposits from the papillary dermis of patients with dermatitis herpetiformis after a long-term gluten-free diet. *Br J Dermatol* 2018;178:e198–201.
- Hopman EG, von Blomberg ME, Batstra MR, Morreau H, Dekker FW, Koning F, et al. Gluten tolerance in adult patients with celiac disease 20 years after diagnosis? *Eur J Gastroenterol Hepatol* 2008;20:423–9.
- Hull CM, Liddle M, Hansen N, Meyer LJ, Schmidt L, Taylor T, et al. Elevation of IgA anti-epidermal transglutaminase antibodies in dermatitis herpetiformis. *Br J Dermatol* 2008;159:120–4.
- Järvinen TT, Kaukinen K, Laurila K, Kyrönpalo S, Rasmussen M, Mäki M, et al. Intraepithelial lymphocytes in celiac disease. *Am J Gastroenterol* 2003;98:1332–7.
- Katz KD, Rashtak S, Lahr BD, Melton LJ 3rd, Krause PK, Maggi K, et al. Screening for celiac disease in a North American population: sequential serology and gastrointestinal symptoms. *Am J Gastroenterol* 2011;106:1333–9.
- Korponay-Szabó IR, Halttunen T, Szalai Z, Laurila K, Király R, Kovács JB, et al. In vivo targeting of intestinal and extraintestinal transglutaminase 2 by coeliac autoantibodies. *Gut* 2004;53:641–8.
- Korponay-Szabó IR, Laurila K, Szondy Z, Halttunen T, Szalai Z, Dahlbom I, et al. Missing endomysial and reticulin binding of coeliac antibodies in transglutaminase 2 knockout tissues. *Gut* 2003;52:199–204.

- Koskinen O, Collin P, Korponay-Szabo I, Salmi T, Iltaanen S, Haimila K, et al. Gluten-dependent small bowel mucosal transglutaminase 2-specific IgA deposits in overt and mild enteropathy coeliac disease. *J Pediatr Gastroenterol Nutr* 2008;47:436–42.
- Kumar V, Jarzabek-Chorzelska M, Sulej J, Rajadhyaksha M, Jablonska S. Tissue transglutaminase and endomysial antibodies-diagnostic markers of gluten-sensitive enteropathy in dermatitis herpetiformis. *Clin Immunol* 2001;98:378–82.
- Kurppa K, Collin P, Viljamaa M, Haimila K, Saavalainen P, Partanen J, et al. Diagnosing mild enteropathy coeliac disease: a randomized, controlled clinical study. *Gastroenterology* 2009;136:816–23.
- Ladinsker B, Rossipal E, Pittschieler K. Endomysium antibodies in coeliac disease: an improved method. *Gut* 1994;35:776–8.
- Lähdeaho ML, Mäki M, Laurila K, Huhtala H, Kaukinen K. Small-bowel mucosal changes and antibody responses after low- and moderate-dose gluten challenge in coeliac disease. *BMC Gastroenterol* 2011;11:129.
- Leonard J, Haffenden G, Tucker W, Unsworth J, Swain F, McMinn R, et al. Gluten challenge in dermatitis herpetiformis. *N Engl J Med* 1983;308:816–9.
- Ludvigsson JF, Bai JC, Biagi F, Card TR, Ciacci C, Ciclitira PJ, et al. Diagnosis and management of adult coeliac disease: guidelines from the British Society of Gastroenterology. *Gut* 2014;63:1210–28.
- Ludvigsson JF, Ciacci C, Green PH, Kaukinen K, Korponay-Szabo IR, Kurppa K, et al. Outcome measures in coeliac disease trials: the Tampere recommendations. *Gut* 2018;67:1410–24.
- Mansikka E, Hervonen K, Salmi TT, Kautiainen H, Kaukinen K, Collin P, et al. The decreasing prevalence of severe villous atrophy in dermatitis herpetiformis: a 45-year experience in 393 patients. *J Clin Gastroenterol* 2017;51:235–9.
- Matysiak-Budnik T, Malamut G, de Serre NP, Grosdidier E, Segulier S, Brousse N, et al. Long-term follow-up of 61 coeliac patients diagnosed in childhood: evolution toward latency is possible on a normal diet. *Gut* 2007;56:1379–86.
- Paek SY, Steinberg SM, Katz SI. Remission in dermatitis herpetiformis: a cohort study. *Arch Dermatol* 2011;147:301–5.
- Reitamo S, Reunala T, Kontinen YT, Saksela O, Salo OP. Inflammatory cells, IgA, C3, fibrin and fibronectin in skin lesions in dermatitis herpetiformis. *Br J Dermatol* 1981;105:167–77.
- Reunala T, Blomqvist K, Tarpila S, Halme H, Kangas K. Gluten-free diet in dermatitis herpetiformis. I. Clinical response of skin lesions in 81 patients. *Br J Dermatol* 1977;97:473–80.
- Reunala T, Salmi TT, Hervonen K, Laurila K, Kautiainen H, Collin P, et al. IgA anti-epidermal transglutaminase antibodies in dermatitis herpetiformis: a significant but not complete response to a gluten-free diet treatment. *Br J Dermatol* 2015;172:1139–41.
- Salmi TT, Hervonen K, Kautiainen H, Collin P, Reunala T. Prevalence and incidence of dermatitis herpetiformis: a 40-year prospective study from Finland. *Br J Dermatol* 2011;165:354–9.
- Salmi TT, Hervonen K, Kurppa K, Collin P, Kaukinen K, Reunala T. Celiac disease evolving into dermatitis herpetiformis in patients adhering to normal or gluten-free diet. *Scand J Gastroenterol* 2015;50:387–92.
- Salmi TT, Hervonen K, Laurila K, Collin P, Mäki M, Koskinen O, et al. Small bowel transglutaminase 2-specific IgA deposits in dermatitis herpetiformis. *Acta Derm Venereol* 2014;94:393–7.
- Sárdy M, Kárpáti S, Merkl B, Paulsson M, Smyth N. Epidermal transglutaminase (TGase 3) is the autoantigen of dermatitis herpetiformis. *J Exp Med* 2002;195:747–57.
- Savilahti E, Reunala T, Mäki M. Increase of lymphocytes bearing the gamma/delta T cell receptor in the jejunum of patients with dermatitis herpetiformis. *Gut* 1992;33:206–11.
- Svedlund J, Sjödin I, Dotevall G. GSRS—A clinical rating scale for gastrointestinal symptoms in patients with irritable bowel syndrome and peptic ulcer disease. *Dig Dis Sci* 1988;33:129–34.
- Taylor TB, Schmidt LA, Meyer LJ, Zone JJ. Transglutaminase 3 present in the IgA aggregates in dermatitis herpetiformis skin is enzymatically active and binds soluble fibrinogen. *J Invest Dermatol* 2015;135:623–5.
- Taylor TB, Zone JJ. Sensitivity of transglutaminase 3 in the IgA aggregates in dermatitis herpetiformis skin to potassium iodide. *J Invest Dermatol* 2018;138:2066–8.
- Viljamaa M, Collin P, Huhtala H, Sievänen H, Mäki M, Kaukinen K. Is coeliac disease screening in risk groups justified? A fourteen-year follow-up with special focus on compliance and quality of life. *Aliment Pharmacol Ther* 2005;22:317–24.
- Zone JJ, Meyer LJ, Petersen MJ. Deposition of granular IgA relative to clinical lesions in dermatitis herpetiformis. *Arch Dermatol* 1996;132:912–8.



**This work is licensed under a Creative Commons Attribution-NonCommercial-NoDerivatives 4.0 International License. To view a copy of this license, visit <http://creativecommons.org/licenses/by-nc-nd/4.0/>**