

DOI: 10.1111/imr.12573

INVITED REVIEW

WILEY 

Abscopal, immunological effects of radiotherapy: Narrowing the gap between clinical and preclinical experiences

Nikko Brix^{1,*} | Anna Tiefenthaler^{1,*} | Heike Anders^{1,*} | Claus Belka^{1,2,3} | Kirsten Lauber^{1,2} 

¹Department of Radiation Oncology, University Hospital, Ludwig-Maximilians-University of Munich, Munich, Germany

²Clinical Cooperation Group 'Personalized Radiotherapy in Head and Neck Cancer' Helmholtz Center Munich, German Research Center for Environmental Health GmbH, Neuherberg, Germany

³German Cancer Consortium Partner Site München, Munich, Germany

Correspondence

Kirsten Lauber, Department of Radiation Oncology, University Hospital, Ludwig-Maximilians-University of Munich, Munich, Germany.
Email: kirsten.lauber@med.uni-muenchen.de

Funding information

Bundesministerium für Bildung und Forschung, Grant/Award Number: The German Consortium for Translational Cancer Res and ZissTrans O2NUK047C; Elitenetwerk Bayern, Grant/Award Number: Graduate program iTarget

Summary

Radiotherapy—despite being a local therapy that meanwhile is characterized by an impressively high degree of spatial accuracy—can stimulate systemic phenomena which occasionally lead to regression and rejection of non-irradiated, distant tumor lesions. These abscopal effects of local irradiation have been observed in sporadic clinical case reports since the beginning of the 20th century, and extensive preclinical work has contributed to identify systemic anti-tumor immune responses as the underlying driving forces. Although abscopal tumor regression still remains a rare event in the radiotherapeutic routine, increasing numbers of cases are being reported, particularly since the clinical implementation of immune checkpoint inhibiting agents. Accordingly, interests to systematically exploit the therapeutic potential of radiotherapy-stimulated systemic responses are constantly growing. The present review briefly delineates the history of radiotherapy-induced abscopal effects and the activation of systemic anti-tumor immune responses by local irradiation. We discuss preclinical and clinical reports with specific focus on the corresponding controversies, and we propose issues that should be addressed in the future in order to narrow the gap between preclinical knowledge and clinical experiences.

KEYWORDS

abscopal effect, anti-tumor immunity, immunogenic cell death, radiotherapy

1 | INTRODUCTION

Together with surgery and chemotherapy, radiotherapy (RT) plays a central role in oncological treatment regimens. More than 60% of all cancer patients receive RT at one point during their medical attendance.¹ Traditionally, the efficacy of RT has been exclusively credited to its ability to induce cancer cell death and the notion that tumors are more prone to damage induced by ionizing radiation (IR) than non-malignant, normal tissues. According to the concept of the four R's of radiotherapy, repair (of IR-induced damage), reoxygenation, redistribution (to other cell cycle phases), and regeneration are the major determinants of a

tissue's response toward IR.² Importantly, tumors and non-malignant tissues are considered to differ in these characteristics, thus forming the rationale for the use of fractionated irradiation regimens with daily fractions over a period of 3–6 weeks in the clinical routine.

It needs to be stressed that in the majority of all cases RT is applied in local settings with a high degree of spatial precision and the cardinal aim to achieve locoregional tumor control. However, there is accumulating evidence that—although applied locally—RT can induce systemic anti-tumor responses leading to regression and rejection of non-irradiated, distant tumor lesions. Collectively, these observations have been summarized under the term 'abscopal effects of RT', and meanwhile it is well accepted that immune mechanisms are the underlying driving forces. For distinct chemotherapeutics, the induction of such systemic, immune-mediated effects has been extensively analyzed by the groups of G. Kroemer and L. Zitvogel.^{3–5} The present

*These authors share equal first authorship.

This article is part of a series of reviews covering Death, Danger & Immunity appearing in Volume 280 of *Immunological Reviews*.

This is an open access article under the terms of the Creative Commons Attribution-NonCommercial License, which permits use, distribution and reproduction in any medium, provided the original work is properly cited and is not used for commercial purposes.

© 2017 The Authors. *Immunological Reviews* Published by John Wiley & Sons Ltd.

review focuses on systemic, abscopal effects stimulated by local RT. We will briefly outline the history of RT-induced abscopal effects as well as the RT-mediated activation of the immune system, and we will present and discuss preclinical and clinical reports with particular emphasis on their discrepancies and issues that should be considered in the future.

2 | THE HISTORY OF RADIOTHERAPY-INDUCED ABS COPAL EFFECTS

It was W.C. Roentgen who announced the discovery of X-rays in November 1895,⁶ published shortly afterward in 1896⁷ (Figure 1). Only a few months after Roentgen's discovery, E.H. Grubbe applied X-rays therapeutically to the first patient who was treated for breast cancer in January 1896.⁸ Since then, RT has undergone continuous improvements, and nowadays different irradiation regimens, including conventionally fractionated RT, hypofractionated settings, and ablative RT, are clinically available. Most patients receive fractionated RT with daily doses of 1.8-2.0 Gy 5 times per week up to a total dose of 45-70 Gy. As mentioned before, the rationale for dose fractionation derives from radiobiological considerations: Repair of IR-mediated damage and regeneration mechanisms support recovery of the normal tissue between the fractions, while reoxygenation and cell cycle redistribution contribute to enhanced responsiveness of the tumor.² In order to reduce treatment time and the number of irradiation sessions, hypofractionated settings with fewer fractions of higher doses have been developed for cancer entities which exhibit less pronounced differences in repair, regeneration, redistribution,

and reoxygenation mechanisms compared to the surrounding normal tissues. Here, patients receive fractions of more than 2.0 up to 6.0 Gy.^{9,10} For breast cancer, this is already standard of care in the UK and parts of Canada.^{11,12} Finally, ablative RT regimens with high single doses of 15 Gy and more are clinically implemented in stereotactic protocols and in intra-operative settings (IORT) where the dose is administered directly into the former tumor bed during surgery prior to wound closure. IORT is commonly used for the treatment of sarcoma, breast, pancreas, and colon cancer.¹³⁻¹⁶

Except for whole body irradiation as conditioning step for bone marrow and stem cell transplantation in case of leukemia treatment, the vast majority of tumor lesions are irradiated locally. Nevertheless, distant and systemic effects have been observed. One of the first clinical reports in this regard dates back to 1908, when H.D. McCulloch irradiated 'lymphatic glands' remote from the tumor lesion and subsequently observed distant tumor regression¹⁷ (Figure 1). However, it should be mentioned that this report lacks an exact description of the irradiation procedure, the irradiation dose, and the localization of the irradiated 'lymphatic glands'. Accordingly, side effects, including scatter radiation, cannot be decisively ruled out. In 1938, G. Segal and C.-P. Leblond reported that IR can provoke effects in organs outside the irradiated field.¹⁸ Upon irradiation of the abdomen of rats with 20-40 Gy, they observed 'une réaction non spécifique' in the shielded, non-irradiated parts of the animals as characterized by atrophy of the lymphoid organs and hypertrophy of the adrenal glands. Interestingly, this effect was abolished upon removal of the adrenal glands, thus excluding the possibility of ineffective shielding. In 1953, R.H. Mole introduced the term 'abscopal effects' (lat.: *ab* = away, *scopus* = target) to describe radiation effects 'at a distance from the

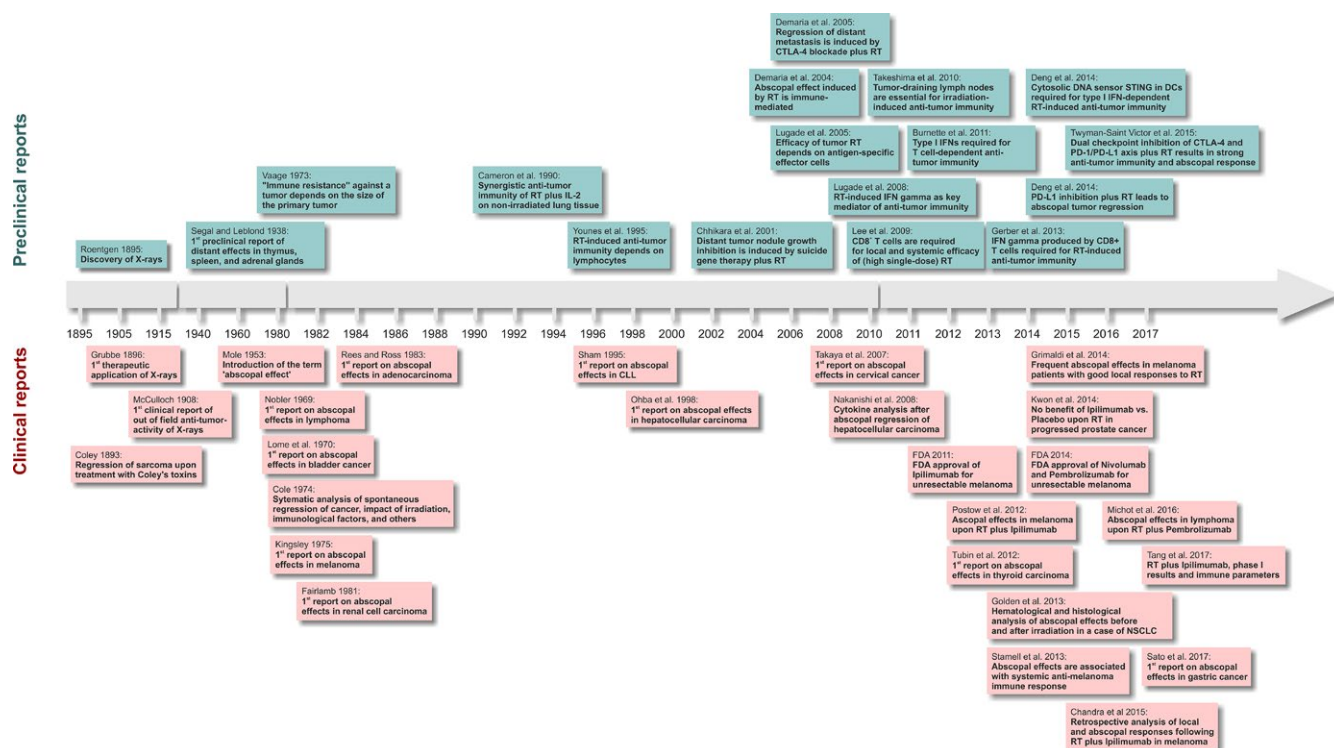


FIGURE 1 Selected milestone publications in the history of radiotherapy-induced abscopal effects [Colour figure can be viewed at wileyonlinelibrary.com]

irradiated volume but within the same organism'.¹⁹ Although originally not coined in a tumor context, nowadays the phrase is commonly used in terms of anti-tumor activity seen outside the irradiation field. The clinical relevance of RT-mediated abscopal effects has long been questioned, since it remained limited to sporadic clinical case reports. However, with the development of novel immunotherapeutic agents, including checkpoint blockers such as Ipilimumab, abscopal effects are being increasingly observed, and efforts to make them clinically exploitable are on the rise.

3 | SYSTEMIC ACTIVATION OF THE IMMUNE SYSTEM BY LOCAL RADIOTHERAPY

Albeit an involvement of the immune system in tumor control was postulated already a long time ago by P. Ehrlich,²⁰ it took more than 50 years after Mole's report until S. Demaria and S.C. Formenti expressed in 2004 that abscopal effects induced by IR are immune-mediated²¹ (Figure 1). They confirmed earlier reports which had already suggested a contribution of the immune system,^{22–31} and they were the first to explicitly draw this conclusion. Today, we know that the immune system represents the missing link between local RT and systemic abscopal effects, since RT is able to stimulate distinct forms of cell death that are recognized by the immune system as dangerous.^{32–34} The awareness that apart from its anti-proliferative capacity, the induction of effective anti-tumor immunity contributes to the therapeutic outcome of RT may shift the focus of interest of clinicians and basic scientists in future.

Historically, RT was considered to have immunosuppressive effects and to enforce immunological tolerance. One reason for this might be that lymphocytes are among the most radiosensitive cells within the body.³⁵ IR reportedly can lead to lymphocytopenia,³⁶ although direct cytotoxic effects of RT are unlikely to account for this phenomenon, since systemic lymphocytopenia was observed upon local RT, and it persisted for several months.³⁷ RT can also induce the downregulation of the costimulatory surface markers CD80 and CD86 on immature dendritic cells (DCs) thus hampering T-cell activation.³⁸ Nonetheless, there is accumulating evidence that RT is able to stimulate activating immune responses, and—in contrast—might help to reverse the tolerogenic phenotype of many tumors. In response to RT, cells undergo different forms of cell death and/or cell stress. Depending on the irradiation dose, the cellular origin, the genetic repertoire, and the functionality of cell cycle checkpoints, diverse phenotypes of apoptosis, necrosis, mitotic catastrophe, and/or senescence can be observed as has been reviewed elsewhere.^{33,39} Notably, the different cell death modalities clearly vary in their immunogenic potential. In order to trigger productive anti-tumor immune responses, it is generally accepted that tumor cells need to undergo forms of cell death which are sensed by the immune system as dangerous and which are accompanied by the exposure and release of danger signals and damage-associated molecular patterns (DAMPs) that attract and activate cells of the innate as well as the adaptive immune system.^{5,40} Briefly, DAMP release triggers extravasation of monocytes and promotes DC maturation and activation. Activated DCs present and cross-present tumor antigens to naïve T cells, thus priming the establishment

of adaptive, anti-tumor responses, which per se are able to counteract the irradiated tumor as well as distant, out-of-field metastases (Figure 2). Mechanistically, an intratumoral cascade of type I and type II interferons (IFNs) is of essential importance in this scenario. Upon phagocytosis of dying irradiated tumor cells, tumor-derived DNA fragments enter the cytosol of DCs and activate the cytosolic DNA sensor cGAS finally leading to STING-mediated transcription of type I IFNs (IFN α and/or IFN β).^{41,42} Since cGAS in principle can sense any DNA that enters the cytosol,⁴³ RT-induced accumulation of cytosolic DNA fragments might also induce intrinsic type I IFN production in irradiated tumor cells. Irrespective of their cellular origin, type I IFNs stimulate antigen cross-presentation by DCs, enhanced T-cell priming in the lymph nodes, and thus the formation of irradiation-induced tumor-specific T-cell responses.^{41,44,45} Activated T cells and natural killer cells (NK cells), in turn, secrete type II interferons (IFN γ) which enhance major histocompatibility complex (MHC) class I expression on tumor cells ultimately resulting in increased immune recognition.⁴⁶ Moreover, IFN γ was shown to modulate the tumor vasculature for improved T-cell trafficking,⁴⁶ and type I IFNs enhance T-cell recruitment by stimulating chemokine secretion.⁴⁷ Most importantly, the treatment efficacy of RT in tumor-bearing immunocompetent mice was abrogated in the absence of type I IFN signaling.⁴¹

According to the classical concept of tumor immunoeediting, established tumors have evolved mechanisms to avoid immune destruction.⁴⁸ This commonly results in a strongly immunosuppressive microenvironment and a tolerogenic phenotype of tumors. IR is able to shift this immunosuppressive microenvironment toward being more immunosupportive.⁴⁹ Via the described IFN cascade, IR enforces the presentation of an extended MHCI ligandome on tumor cells and supports the recruitment, activation, and function of DCs and T cells.^{41,44,50,51} This resembles a defense response upon viral infection, and it is feasible to assume that cytosolic DNA fragments generated upon IR can act as viral mimetics in this regard. Along these lines, IR meanwhile is considered as a means of in situ cancer vaccination by turning the tumor into an 'immunogenic hub'⁵² (Figure 2). In principle, irradiated tumor cells provide all compounds needed for a classic vaccination approach: tumor-specific antigens and adjuvants represented by DAMPs exposed and released upon IR. However, whether IR alone is able to stimulate long-lasting immunological memory as it is a prerequisite for successful vaccination remains questionable. Still, the stimulation of systemic abscopal effects by local RT and their persistence for several months endorses the idea of—at least short-term—established anti-tumor immunity.⁵³

4 | STUDIES OF IRRADIATION-INDUCED ANTI-TUMOR IMMUNITY AND ABSCOPAL EFFECTS IN PRECLINICAL ANIMAL MODELS

Our knowledge about RT-induced anti-tumor immune mechanisms and resulting abscopal effects is largely based on preclinical model systems. In order to analyze the extent and the molecular determinants of immune-mediated, abscopal growth inhibition and tumor rejection, researchers have established and utilized a set of tumor model systems which are discussed in this section (Table 1, Figure 3). Importantly,

none of these models per se can be considered as undisputedly superior to any of the others; they rather differ with regard to their depth in information and exhibit unique advantages and limitations. In principle, preclinical research in oncoimmunology employs not only transplantation models but also autochthonous models which include

genetically engineered and carcinogen-induced tumors.^{54,55} Although representing tumors whose development is more realistic than that of transplantable tumors, the latter two are clearly underrepresented in experimental reports studying RT-induced anti-tumor effects, whereas heterotopic transplantation models such as subcutaneous flank,

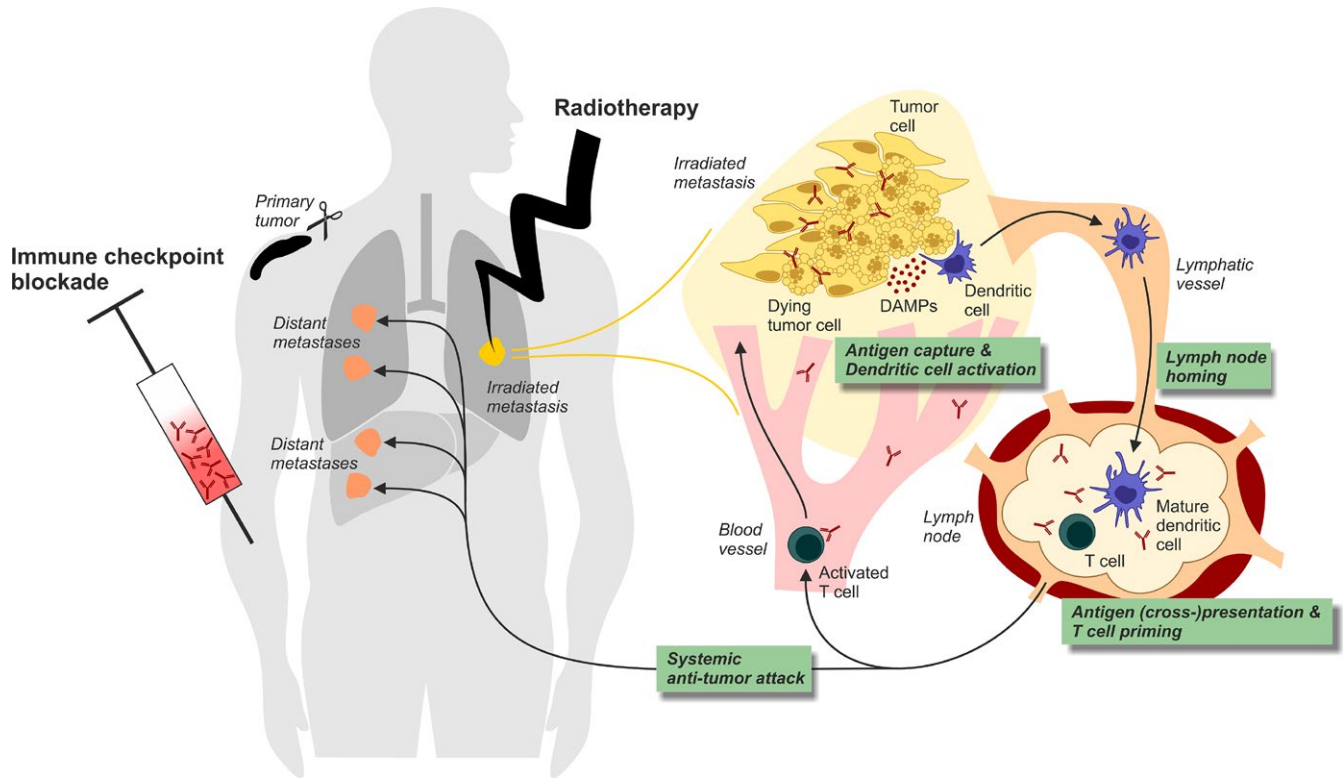


FIGURE 2 Schematic of radiotherapy-induced abscopal effects and out-of-field lesion regression. In this example, the primary tumor was removed by surgery, and abscopal anti-tumor immunity was induced by RT of a pulmonary metastasis combined with systemic immune checkpoint blockade. The generation of an in situ vaccine by RT and immune checkpoint blockade is depicted in the right part of the scheme: Tumor antigens together with adjuvant DAMPs are released by dying tumor cells and are taken up and processed by DCs which in turn (cross-) present these tumor antigens to naïve T cells in a tumor-draining lymph node. Systemic anti-tumor immunity is achieved by activated T cells which leave the lymph node and subsequently attack metastatic tumor nodules at distant, non-irradiated sites [Colour figure can be viewed at wileyonlinelibrary.com]

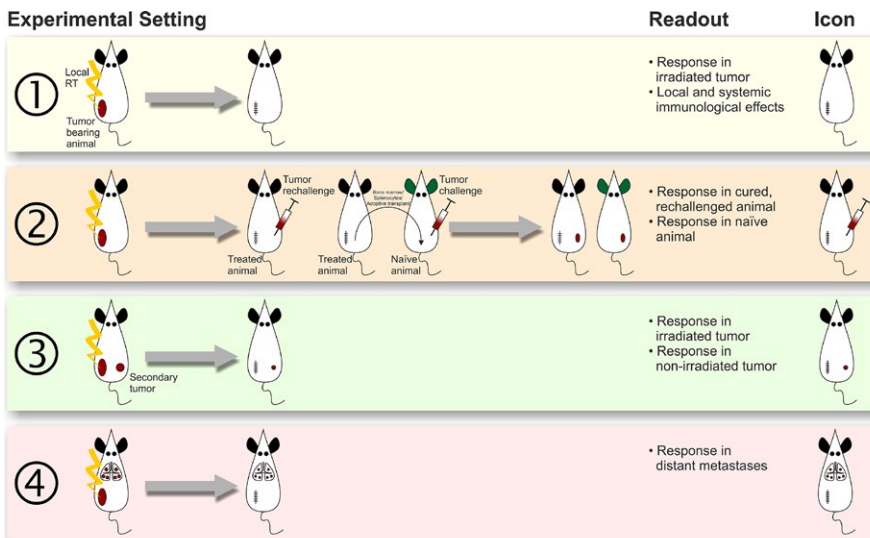


FIGURE 3 Different experimental model systems that are commonly employed to study RT-mediated abscopal effects. Icons correspond to Table 1. For detailed information, please see text [Colour figure can be viewed at wileyonlinelibrary.com]

TABLE 1 Selected studies reporting abscopal, immunological effects of RT in different readout model systems. Studies are sorted according to the readout model systems (for explanation see Figure 3) employed. Negative abscopal effects are not listed in the table but discussed in the text. If not stated otherwise, tumors were injected subcutaneously and tumors were grown syngeneically in BALB/c or C57BL/6 mice, respectively. All relevant cell lines employed *in vivo* and all immunomodulatory substances used are indicated for groups 1 and 2 of the table. For groups 3, 4, and 5, only the cell line(s) and immunomodulatory substances which were employed for the respective abscopal results are listed

Author	Cell line(s) and model system (tumor origin)	Irradiation regimen	Additional therapeutics	Key mediator of anti-tumor effect and comments
<i>(1) Immune-mediated systemic effects of tumor RT</i>				
Lugade et al. ⁴⁴	B16-F0/OVA (melanoma)	1×15, 5×3 Gy	-	Tumor-specific CD8 ⁺ T cells
Lugade et al. ⁴⁶	B16-F0/OVA (melanoma)	1×15 Gy	-	Type II IFN produced by hematopoietic cells, CD8 ⁺ T cells
Burnette et al. ⁴¹	Various B16 clones (melanomas)	3×15, 1×20, 1×25 Gy	-	Type I IFN produced by CD45 ⁺ cells; tumor-infiltrating DCs, CD8 ⁺ T cells
Schaue et al. ¹¹⁹	B16/OVA (melanoma)	1×5, 1×7.5, 1×10, 1×15, 5×3, 3×5, 2×7.5 Gy	-	Tumor-specific T cells
Gerber et al. ⁶⁰	MC38 (colorectal carcinoma)	1×15 Gy	-	CD8 ⁺ T cells which are main producers of type II IFN
Klug et al. ¹²⁵	Spontaneous insulinomas of RT5 mice, RT5 allografts in NOD/SCID mice, MeWo (human melanoma in NSG mice)	1×0.5, 1×1, 1×2, 1×6 Gy	-	Inducible NO synthase+ macrophages, CD8 ⁺ T cells
Lim et al. ⁴⁷	B16-F0 (melanoma)	1×15 Gy	-	Type I and type II IFN, T cells
Deng et al. ⁴²	MC38, MC38/SIY (colorectal carcinomas)	1×20, 2×15 Gy	-	STING signaling in DCs leading to type I IFN production
<i>(2) Tumor rechallenge experiments in mice treated by RT (+ additional therapeutics)</i>				
Vaage ⁶¹	Methylcholanthrene-induced fibrosarcoma in C3Hf/He mice	1×60 Gy	Presensitization with various tumor implants	Anti-tumor immunity
Dranoff et al. ¹⁰⁸	B16-F10 (melanoma), CT26 (colorectal carcinoma), CMS-5 (fibrosarcoma), WP-4 (fibrosarcoma) RENCA (renal cell carcinoma), expressing various cytokines	1×35 Gy <i>in vitro</i>	Tumor cell-derived cytokines (mIL-2, -4, -5, -6, mGM-CSF, mIFN- γ , mIL-1RA, mICAM, mCD2, hTNF- α)	T cells
Nishisaka et al. ¹⁰⁹	RENCA (renal cell carcinoma) stably transfected with mIL-2, mIFN- γ , or mGM-CSF	3×1, 3×2, 1×3, 1×5 Gy (1×50 Gy <i>in vitro</i>)	Vaccination with wtRENCA or mixture of mIL-2-, mIFN- γ - and mGM-CSF-producing RENCA (both preirradiated with 50 Gy)	Lymphocytes
Nikitina et al. ⁶⁷	MethA (sarcoma), C3 (sarcoma; mouse embryonic cells transfected with HPV16 genome and EJ-ras gene)	1×10, 3×10, 4×10, 5×10 Gy	DC administration	Tumor-specific CD8 ⁺ T cells
Chakravarty et al. ⁸⁴	LLC (clone D122, lung carcinoma)	1×60 Gy	rhFlt3-ligand	Suggested: Tumor-specific T cells

(Continues)

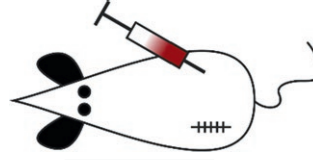
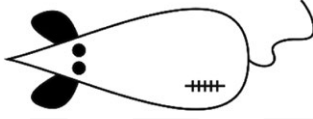


TABLE 1 (Continued)

Author	Cell line(s) and model system (tumor origin)	Irradiation regimen	Additional therapeutics	Key mediator of anti-tumor effect and comments
Tatsuta et al. ¹⁰⁷	C1300 (murine neuroblastoma grown in A mice), B16-F10 (melanoma)	3×3, 3×4, 3×34 Gy	Virally transduced IFN-β-expressing DCs	DC-mediated anti-tumor immunity, suggested: Tumor-specific CD8 ⁺ T cells
Zeng et al. ⁵⁹	GL261/Luc (orthotopic glioblastoma)	1×10 Gy	α-PD-1	CD8 ⁺ T cells
Filatenkov et al. ⁴⁹	CT26, MC38 (colorectal carcinomas)	1×30 Gy	-	CD8 ⁺ type II IFN-producing T cells, CD4 ⁺ T cells, CD8 ⁺ DCs
<i>(3) Abscopal anti-tumor effects of RT on secondary tumors</i>				
Cameron et al. ²³	MC38 (colorectal carcinoma)	1×7.5 Gy	Administration of tumor-infiltrating lymphocytes and rhIL-2	Tumor-infiltrating lymphocytes
Younes et al. ²²	RENCA (renal cell carcinoma)	1×1, 1×3, 1×5, 1×8 Gy	rhIL-2	T cells and NK cells
Everse et al. and Jürgeniemi-Schulz et al. ^{25,27}	SL2 (lymphoma in DBA/2 mice)	1×20 Gy	rhIL-2	Immune cells
Chihikara et al. ²⁹	RM-1 (prostate cancer)	1×5 Gy	Replication-defective adenovirus carrying HSV-tk gene + ganciclovir	Suggested: CD4 ⁺ T cells
Vlachaki et al. ³¹	TM40D (mammary carcinoma)	1×5 Gy	Replication-defective adenovirus carrying HSV-tk gene + ganciclovir	Suggested: immune system
Demaria et al. ²¹	67NR (mammary carcinoma)	1×2, 1×6 Gy	rhFlt3-ligand	T cells
Blanquicett et al. ¹²⁸	BxPC-3 (human pancreatic tumor in athymic nude mice)	10×2 Gy	Capecitabine and celecoxib	Not stated
Akutsu et al. ¹⁹¹	SCC VII (head and neck squamous cell carcinoma in C3H/He mice)	3×10 Gy	DC administration	Suggested: CD8 ⁺ T cells
Shiraishi et al. ⁸⁶	Colon26 (colorectal carcinoma), LLC (lung carcinoma)	1×6 Gy	EC1301 (synthetic variant of macrophage inflammatory protein-1α)	T cells and NK cells; abscopal effect is not tumor type-specific
Dewan et al. ⁹⁵	TSA (mammary carcinoma), MC38 (colorectal carcinoma)	3×8, 5×6, 1×20 Gy	α-CTLA-4	T cells
Yasuda et al. ⁶⁹	Colon26 (colorectal carcinoma)	10×2 Gy	rhIL-2	Suggested: T cells, especially CD4 ⁺ T cells
Hodge et al. ⁷⁰	MC38 (colorectal carcinoma) and LLC (lung carcinoma) (both CEA ⁺ in CEA ⁺ mice)	1×8 Gy, brachytherapy (0.04 Gy/h)	Various viral vaccines containing mB7-1, mICAM-1 and mLFA-3, mGM-CSF and retroviral GP70 genes	CD8 ⁺ T cells

(Continues)

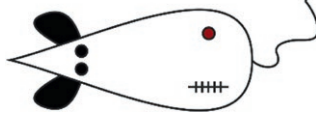


TABLE 1 (Continued)

Author	Cell line(s) and model system (tumor origin)	Irradiation regimen	Additional therapeutics	Key mediator of anti-tumor effect and comments
Kanegasaki et al. ⁸⁵	Colon26 (colorectal carcinoma), FM3A (mammary carcinoma in C3H/HeN or C3H/HeJ mice)	1×6 Gy	EC1301 (synthetic variant of macrophage inflammatory protein-1 α), rmHSP70, bovine HMGB1	HMGB1, TLR4; suggested: T cells
Strigari et al. ¹¹⁸	HCT116 (human colorectal carcinoma; p53 wt or mutant in athymic nude mice)	1×10 Gy, 1×20 Gy	-	p53 in tumor cells
Wu et al. ⁹⁶	AB12 (mesothelioma)	3×5 Gy	α -CTLA-4	T cells
Twyman-Saint Victor et al. ¹⁹²	B16-F10 and relapsed subclones (melanomas)	1×20 Gy	α -CTLA-4, α -PD-L1, α -PD-1	CD8 ⁺ T cells
de Araujo Farias et al. ¹²⁹	G361 (human melanoma in NOD/SCID mice)	1×2 Gy	Human mesenchymal stem cells	Mesenchymal stem cell-derived factors
Park et al. ⁹⁴	B16/OVA (melanoma), RENCA (renal cell carcinoma)	1×15 Gy	α -PD-1, α -CTLA-4	CD8 ⁺ T cells
Habets et al. ⁸³	67NR (mammary carcinoma)	3×8 Gy	rhFlt3-ligand	Exclusion of humoral immune response as mediator of abscopal effects
Hao et al. ¹⁹³	LLC (lung carcinoma)	1×6 Gy	α -CD40	Suggested: APC activation
Schrand et al. ⁶⁵	4T1 (mammary carcinoma)	1×12 Gy	4-1BB aptamer, VEGF aptamer or aptamer conjugate, α -CTLA-4, α -PD-1	T cells
<i>(4) Abscopal anti-tumor effects of RT on distant metastases</i>				
Lu et al. ⁸⁰	LLC (lung carcinoma)	2×8 Gy	rhM-CSF	Suggested: immune system
Teicher et al. ²⁶	LLC (lung carcinoma)	5×2, 5×3, 5×4 Gy	rmIL-12, rhM-CSF	Suggested: T cells
Chakravarty et al. ²⁴	LLC (clone D122, lung carcinoma)	1×60 Gy	rhFlt3-ligand	Suggested: T cells
Denaria et al. ⁷⁷	4T1 (mammary carcinoma)	1×12 Gy	α -CTLA-4	CD8 ⁺ T cells
Lee et al. ¹¹⁰	4T1 (mammary carcinoma), B16-CCR7 (melanoma)	3×15, 2×12 Gy	No additional treatment or adenoviral LIGHT (inductor of various chemokines and T cell costimulator)	CD8 ⁺ T cells; chemotherapy with paclitaxel inhibits abscopal response
Zhang et al. ⁷⁸	LLC (lung carcinoma)	1×20 Gy	TLR9 agonist	Suggested: NKDCs
Ma et al. ⁷⁵	TUBO (neu+), TUBO-P2J (neu-) (mammary carcinomas)	1×20 Gy	α -Her2/neu	T cells

(Continues)

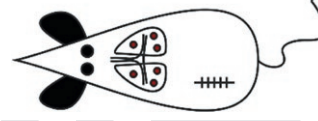














TABLE 1 (Continued)

Author	Cell line(s) and model system (tumor origin)	Irradiation regimen	Additional therapeutics	Key mediator of anti-tumor effect and comments
<i>(5) Abscopal anti-tumor effects and systemic immunity of RT tested with > 1 readout model</i>				
Teicher et al. ³⁰	LLC (lung carcinoma)	5×2, 5×3, 5×4, 10×2, 10×3, 10×4 Gy	rmIL-12, rmGM-CSF	Suggested: NK cells, T cells 
Teitz-Tennenbaum et al. ²⁸	B16 (D5 subclone, melanoma)	5×8.5 Gy	DC administration	Type II IFN-producing T cells 
Fujita et al. ⁶⁸	178-2 BMA (prostate cancer metastasis in 129/Sv mice)	1×5 Gy	Adenovirally transduced mIL-12	NK cells 
Pilonis et al. ¹⁹⁴	4T1 (mammary carcinoma)	2×12 Gy	α-CTLA-4	T cells (invariant NKT cells as negative regulators of anti-tumor immunity) 
Takeshima et al. ⁴⁵	EG7 (=OVA-expressing EL4; lymphoma)	1×2 Gy	OVA-specific Th1 cells	CD8 ⁺ type II IFN-producing T cells 
Dewan et al. ¹⁰⁶	TSA (mammary carcinoma)	3×8 Gy	TLR7 agonist, low-dose cyclophosphamide	CD8 ⁺ type II IFN-producing T cells 
Deng et al. ⁸⁸	TUBO (mammary carcinoma)	1×12 Gy	α-PD-L1	Tumor-specific, type II IFN-producing CD8 ⁺ T cells 

(Continues)

TABLE 1 (Continued)

Author	Cell line(s) and model system (tumor origin)	Irradiation regimen	Additional therapeutics	Key mediator of anti-tumor effect and comments
Yoshimoto et al. ¹²⁰	EL4 (lymphoma)	1×30 Gy	-	CD8 ⁺ T cells, type II IFN, suggested: tumor-specific antibodies 
Young et al. ⁵⁸	CT26 (colorectal carcinoma)	1×20 Gy	TGF-β inhibitor	CD8 ⁺ T cells 
Vanpouille-Box et al. ¹⁹⁵	4T1, TSA (mammary carcinomas)	5×6 Gy	α-PD-1, α-TGF-β	Tumor-specific, type II IFN-producing T cells 
Rodriguez-Ruiz et al. ⁷⁶	B16/OVA (melanoma), 4T1 (mammary carcinoma), MC38 (colorectal carcinoma)	3×8 Gy	α-4-1BB, α-PD1	DCs, type I and type II IFNs, CD8 ⁺ T cells 
Dovedi et al. ¹⁰⁵	CT26 (colorectal carcinoma)	5×2, 1×10 Gy	α-PD-1, α-PD-L1	T cells (separate analysis of T cells in irradiated and abscopal tumor) 

APC, antigen-presenting cell; CD, cluster of differentiation; CEA, carcinoembryonic antigen; CTLA-4, cytotoxic T lymphocyte-associated protein 4; DC, dendritic cell; Flt3-L, Fms-like tyrosine kinase receptor 3 ligand; GM-CSF, granulocyte macrophage colony-stimulating factor; HMGB-1, high mobility group box 1 protein; HPV, human papilloma virus; HSP, heat shock protein; HSV-tk, herpes simplex virus thymidine kinase; ICAM-1, intercellular adhesion molecule-1; IFN, interferon; IL, interleukin; m, murine; M-CSF, macrophage colony-stimulating factor; NK cell, natural killer cell; NKDC, natural killer dendritic cell; NOD/SCID, non-obese diabetic/severe combined immunodeficiency; OVA, ovalbumin; PD-1, programmed cell death protein 1; PD-L1, programmed death-ligand 1; rh, recombinant human; rm, recombinant murine; RT, radiotherapy; STING, stimulator of interferon genes; TGF, transforming growth factor; TLR, toll-like receptor; TNF, tumor necrosis factor; VEGF, vascular endothelial growth factor receptor; wt, wildtype.

footpad, or thigh tumors, are used in the majority of cases. The main reason for the frequent use of transplantable, subcutaneous tumors is that these are easily generated and their monitoring is readily achievable in comparison to most orthotopic tumors which grow within the body and thus require modern imaging techniques and equipment. Moreover, external beam RT can be easily delivered to subcutaneous tumors with concurrent minimal damage to non-cancerous surrounding tissue. This was particularly important in earlier studies where proper dose distribution and protective shielding were often realized by simply using lead plates or boxes in order to expose the small tumor-bearing regions of the animals' bodies.^{18,56} Within the last years, the development of highly sophisticated small animal irradiation platforms has overcome this difficulty: Image-guided RT planning now closely mimics the clinical situation and therefore allows irradiation of orthotopically transplanted tumors at virtually any location in the body without excessive irradiation of non-malignant tissue and organs at risk.⁵⁷⁻⁵⁹ In principle, these small animal RT devices could also be used for the treatment of autochthonous malignancies such as spontaneously occurring and carcinogen-induced tumors. However, standardized RT of these tumors requires extensive monitoring, since the exact location and onset of tumor growth cannot be precisely predicted. Besides, tumor growth at multiple sites is frequent, thus rendering treatment planning even more complex.

5 | PRECLINICAL MODEL SYSTEMS EMPLOYED TO EXPLORE SYSTEMIC, ABCOPAL EFFECTS OF RADIOTHERAPY

5.1 | Focus on initial immune priming and subsequent immune effector functions: Analysis of immune mechanisms in the irradiated tumor itself

Many key mediators of irradiation-induced anti-tumor immunity such as the importance of type I interferon production mediated by STING,^{41,42,47} the essential role of tumor-specific IFN γ -producing T cells,^{44,46,60} and the contribution of DCs cross-presenting tumor antigens,⁴¹ were identified in transplantable tumor models using a single tumor that is irradiated. To this end, a suspension of tumor cells cultured *in vitro* or obtained from a tumor-bearing donor animal is injected subcutaneously. After tumor engraftment (usually 1-3 weeks), tumor RT is performed. Any immunomodulatory substance or combinations thereof can be applied in basically every arbitrary sequence: before, during, or after irradiation. Readout endpoints comprise tumor growth, survival, intratumoral, and/or systemic immune parameters (Figure 3, 1st panel).

5.2 | Focus on long-lasting systemic effects: Tumor rechallenge in treated animals or in naïve animals after bone marrow transplantation or adoptive T-cell transfer

Tumor rechallenge experiments are used to test long-lasting, systemic, immune-mediated protection against a formerly rejected tumor. Animals whose tumors have been treated are rechallenged

by a second injection of tumor cells which is also rejected if sufficient anti-tumor immunity has been achieved. In order to demonstrate tumor specificity of this immune response, failure to reject another, antigenetically unrelated tumor can be demonstrated simultaneously. Instead of rechallenging a treated animal, it is also possible to investigate whether the suggested systemic immunity of a treated animal can be transferred to another, naïve animal by transplanting splenocytes and/or bone marrow cells or by adoptively transferring mature T cells from the donor prior to tumor inoculation in the recipient.^{28,49} To thoroughly exclude that donor-independent immunity is induced in the recipient, these animals' immune cells can be depleted *a priori* by a sublethal dose of whole body IR before bone marrow/stem cell transplantation, or adoptive transfer, respectively⁴⁹ (Figure 3, 2nd panel).

In case of full protective immunity, all rechallenged mice display long-term survival. In several cases, tumor regression in only a fraction of the tested animals is observed, and this is dependent on the amount of tumor cells injected.^{49,61} Moreover, immunity against tumor rechallenge after successful RT might suggest but not guarantee that truly abscopal tumor regression can be demonstrated in the same model system. For instance, Filatenkov et al.⁴⁹ excluded the possibility of IR-induced abscopal effects in a murine colon carcinoma model, because systemic immunity was not achieved immediately but rather weeks after RT. Besides, it is very important to stress that the test for immunological memory only reflects the host's capacity to reject a tumor at a certain time point of rechallenge. Pioneer works at the beginning of the 20th century already demonstrated that immune-mediated tumor rejection may gradually decline within weeks.⁶² Another study found that the probability of tumor rejection is not only dependent on the time span between generation of anti-tumor immunity and rechallenge but may also be heavily diminished if a preexisting large tumor mass is still present in the organism⁶¹—a situation which is frequently observed when treating cancer patients with late-stage disease. Additionally, it should be noted that the capacity to reject a subcutaneous tumor rechallenge does not necessarily predict that the entire body displays a similarly high degree of immunologic memory irrespective of the site of rechallenge. This phenomenon is known from pathogen vaccination studies⁶³ and is further supported by the fact that tissue-specific peculiarities of the immune system are well-known.⁶⁴ Hence, successful rejection of a tumor rechallenge at a certain time point and in a certain tissue is a very important indicator of anti-tumor immunity in preclinical model systems, but it does not always predict temporally unlimited and truly systemic anti-tumor immunity.

5.3 | Focus on abscopal effects on out-of field lesions: Model systems with secondary tumors and/or systemic tumor cell injection

The prototypical model system to study abscopal effects of RT is an animal with two subcutaneous tumors that are inoculated into both the left and the right flank or hindleg, and only one of the two tumors is irradiated (while scattered IR to the second tumor must strictly be

excluded). In case of an abscopal response, growth delay of the non-irradiated tumor or even total regression is observed (Figure 3, 3rd panel).

In a variation of this experimental setup, the secondary tumor injection is applied intravenously or into the spleen resulting in multiple disseminated tumor nodules in a specific organ such as the lungs or the liver.^{29,31,65–69} The most common readout endpoint in this setting is the quantification of tumor growth in the non-irradiated organ—either by enumeration or by simply determining the weight of the tumor-infiltrated organ.^{28,29,31,57,65,68–70} In case of an abscopal response, the extent of tumor growth in the non-irradiated organ is markedly decreased. Occasionally, this model system is also employed to determine abscopal effects on artificial ‘metastases’ generated via disseminated distribution of intravenously injected tumor cells. However, it should be noted that the tumor cells in this setting do not originate from a primary tumor but rather were artificially introduced by systemic injection. Hence, these ‘metastases’ might exhibit larger genetic and thus antigenic similarity to the primary tumor than genuine metastases do.^{71–73} Therefore, it remains questionable whether an inhibition of bona fide metastasis in a (pre-)clinical situation can be deduced from results obtained in this model.

Another variant of this model uses only a single intravenous injection of tumor cells which subsequently form nodules in a certain organ of interest such as lung or liver.^{22,23} Upon application of IR to one half of the infiltrated organ, the number of tumor nodules in the non-irradiated part of the same organ can be assessed as described above. However, the risk of unintentionally irradiating the abscopal field in this setting is higher than in those situations where the two tumor lesions are separated more clearly or with a delay in time.

5.4 | Focus on abscopal effects on distant metastases: Model systems with autochthonous metastases

Some tumor cell lines such as the murine mammary carcinoma 4T1 and Lewis lung carcinoma cells, spontaneously metastasize to distant organs even after subcutaneous implantation.^{24,26,30,74–80} This property can be exploited to measure abscopal effects on metastatic growth after IR of the primary tumor (Figure 3, 4th panel). The severity of the metastatic process is eventually quantified as described above. In contrast to model systems using ‘experimental metastases’ introduced by intravenous or intrasplenic injection of tumor cells, this setup allows to study the abscopal inhibition of bona fide metastases after RT and thus also accounts for the fact that metastatic lesions might already have acquired different antigenic properties, thus distinguishing them from their tumor of origin.^{71–73}

Importantly, to ascertain the detection of abscopal effects on distant metastases (instead of the primary tumor's incapacity to give rise to metastatic cells), therapy of the primary tumor needs to be started at a time point when micrometastases have already formed in the respective organ. However, since this experimental detail is not considered by all authors whose work is discussed here, it cannot be excluded that some of them merely detected anti-tumor effects on the

primary tumor prior to dissemination instead of truly abscopal effects on existing metastases.

6 | ENHANCEMENT OF RADIOTHERAPY-INDUCED ANTI-TUMOR IMMUNITY: IMMUNOMODULATORS, CHEMOTHERAPY, AND EXOGENOUS TUMOR CELL VACCINES

Even before 2004, when Demaria et al.²¹ identified the immune system as the key mediator of abscopal anti-tumor effects, researchers in this field had already focused on combining RT with immunomodulation in order to strengthen the immune response against out-of-field and/or metastatic tumor lesions of various origins.^{22–31,80} Since then, a plethora of—in the broadest sense—immunomodulatory substances has been tested for their capacity to strengthen systemic anti-tumor immune responses or to unleash abscopal effects in the first place. Despite their heterogeneity, the majority of these substances can be summarized into groups which share common properties.

Earlier *in vivo* studies on RT-induced anti-tumor immunity and abscopal effects frequently tested the co-administration of cytokines. By the 1980s, the T-cell proliferation stimulating activity of interleukin (IL)-2 had already been demonstrated in preclinical and clinical cancer immunotherapy,^{81,82} and this cytokine was consequently used in preclinical studies to explore its synergy with RT in murine models of melanoma, lymphoma, colorectal, mammary, and renal cell carcinoma.^{22,23,25,27,28,69} In order to reduce the severe side effects of systemic IL-2 application, peri- or intratumoral administration was successfully employed.^{25,27,28,69} Apart from IL-2, other mostly proinflammatory cytokines were combined with RT, including the DC-stimulating Fms-like tyrosine kinase receptor 3 ligand (Flt3-L),^{21,24,83,84} IL-12 alone or in combination with Granulocyte macrophage colony-stimulating factor (GM-CSF) or M-CSF, respectively.^{26,30,68} Furthermore, M-CSF alone and the Macrophage inflammatory protein 1 α variant ECI301 were successfully tested for their combination with RT.^{80,85,86} Hence, the capacity of certain cytokines to induce either T-cell proliferation and/or activation of antigen-presenting cells (APCs) necessary for T-cell priming apparently can be exploited to enhance RT-induced anti-tumor immunity and thus abscopal effects in animal models.

The transfer of immune cells is another treatment option to enforce RT-induced anti-tumor immunity which can additionally be combined with cytokine administration. For instance, *in vitro* differentiated DCs were successfully used to improve anti-tumor immunity in sarcoma and for abscopal regression of non-irradiated lung tumors induced by systemic injection of melanoma cells.^{28,87} Analogously, injections of T cells potentiated anti-tumor immunity when combined with RT, thus inducing abscopal effects in lymphoma and in experimental liver metastases induced by intrasplenic injection of colorectal cancer cells.^{23,45}

Whereas the rationale for cytokine administration and/or injection of immune cells derives from the fact that subsequent immune activation can induce tumor regression, a complementary approach of attenuating immunosuppression and reinvigorating T-cell responses against growing tumors has been underestimated for decades and

gained enormous attention within the last years. Without knowing the importance of T cells in anti-tumor immunity at that time, early works by J. Vaage⁶¹ already demonstrated that the host's capacity to establish anti-tumor immunity gradually declines if the size of a tumor exceeds a certain threshold. Indeed, as demonstrated in later works, evolving tumors gradually establish an immunosuppressive microenvironment which is infiltrated by regulatory T cells (Tregs), alternatively activated macrophages and myeloid-derived suppressor cells (MDSCs).^{88,89} To overcome this immune inhibition, monoclonal antibodies have shown remarkable anti-tumor efficacy in both preclinical and clinical situations. The most well-known example of these immune checkpoint inhibitors is the antagonistic antibody against cytotoxic T-lymphocyte-associated protein 4 (CTLA-4). Its target is expressed on T cells and binds to the ligand B7-1 on APCs, thus preventing T-cell activation.^{90,91} The capacity of CTLA-4-blocking antibodies to reactivate T cells and therefore inhibit tumor growth was demonstrated more than 20 years ago,⁹² and Ipilimumab—one of the human anti-CTLA-4 antibodies—was the first immune checkpoint blocking antibody in cancer therapy which was approved by the FDA and the European Commission for the treatment of unresectable melanoma in 2011 (Figure 1). Considering its clinical efficacy in melanoma,⁹³ it is not surprising that anti-CTLA-4 is also the most often used substance to demonstrate T cell-dependent abscopal effects in preclinical settings. Various authors observed metastasis inhibition, abscopal regression of secondary tumors, and establishment of immunological memory in tumor rechallenge experiments upon combination of RT with anti-CTLA-4 treatment.^{65,77,79,94–97} These findings are not restricted to a certain mouse model but rather underline the versatile efficacy of CTLA-4 blockade in various cancer entities: Abscopal effects were observed in mammary and colorectal tumors, melanoma, and mesothelioma. Nevertheless, disadvantages of this therapeutic regimen also became apparent. Severe multiorgan autoimmune pathologies were observed in the treated animals which closely resemble the immune-related adverse effects of Ipilimumab treatment in the clinic.^{65,98,99}

Another study concentrated on the issue that RT in combination with CTLA-4 blockade, albeit being effective in some patients, is unable to induce enduring anti-tumor immunity in the majority of cases both in preclinical and clinical settings. The authors attributed this to therapy-induced expression of programmed death ligand 1 (PD-L1) on tumor cells.⁹⁷ Indeed, the axis of PD-L1 and its cognate receptor programmed death 1 (PD-1) on the surface of T cells is known as another T-cell inhibiting signaling pathway. Similarly to anti-CTLA-4 treatment, inhibition of the PD-1/PD-L1 immune checkpoint enhances the activation of T cells, thus facilitating T cell-dependent anti-tumor immunity.^{100,101} However, whereas CTLA-4 blockade results in a broad systemic activation of T cells explaining strong immune cell infiltration and immunopathology in non-malignant tissue,^{65,102} T-cell activation by blockade of PD-1 or PD-L1 appears to be more subtle. Since PD-1 expression is induced on exhausted T cells frequently found within the immunosuppressive milieu of tumors, antibodies targeting the PD-1/PD-L1-axis not surprisingly proved to be effective immunomodulating anti-cancer agents both in preclinical models and in the clinic.^{100,101,103,104} The combination of anti-PD-L1 or

anti-PD-1 antibodies with RT evoked abscopal tumor regression in murine melanoma and in mammary, renal, and colon carcinoma models.^{65,74,76,88,94,97,105} Interestingly, studies using a triple therapy with RT and simultaneous blockade of the PD-1/PD-L1-axis as well as CTLA-4 showed conflicting results with regard to the additional effect of combined immune checkpoint blockade on abscopal tumor responses.^{94,97} Apart from interfering with CTLA-4 and PD1/PD-L1 function, a few preclinical studies employed other monoclonal antibodies combined with RT in order to increase anti-tumor immunity. For instance, RT in combination with T cell-activating antibodies against 4-1BB (CD137) plus PD-1 blockade induced abscopal effects in melanoma, breast, and colon tumors.⁷⁶ Moreover, abscopal regression in three different murine breast cancer models upon RT together with blockade of transforming growth factor- β (TGF- β) or Her2/neu was demonstrated.^{74,75} Unlike anti-CTLA-4, anti-PD-1, and anti-PD-L1, these antibodies are not considered as classical immune checkpoint inhibitors. Nevertheless, their use in combination with RT showed encouraging results and renders them interesting tools for further investigation.

Importantly, various other immunomodulatory substances have been reported to induce systemic anti-tumor immunity when combined with RT. Abscopal responses were observed with aptamers targeting 4-1BB (CD137) and/or vascular endothelial growth factor (VEGF), as well as with agonists for Toll-like receptor (TLR)-7 or TLR-9, respectively.^{65,78,106} Combination of RT with gene therapeutic approaches using IFN β -producing DCs, T cell-activating viral vaccines or cytokine-expressing tumor cells improved systemic immunity and induced abscopal effects in various tumor models.^{70,107–111} Two other studies combined RT with herpes simplex virus thymidine kinase (HSV-tk)-based suicide gene therapy and systemic ganciclovir administration leading to abscopal effects.^{29,31}

The aim of combining local RT with any type of immunomodulatory substance as discussed above is to enhance and improve the in situ cancer vaccination effects of RT (Figure 2). Along these lines, several preclinical studies also tested exogenous tumor vaccination procedures in order to stimulate systemic anti-tumor immunity.^{49,61,84,96,108,109,112} Interestingly, the vaccination effect of ex vivo-irradiated tumor cells (mixed with varying adjuvants) was rather weak, and in some reports it was even counterproductive with regard to different endpoints, including rejection of a tumor challenge and regression of an abscopal tumor upon RT,^{49,96,109,112} whereas evidence for much more potent anti-tumor immunity was observed if the irradiated tumor cell vaccine was genetically modified to produce either GM-CSF alone or GM-CSF, IL-2, and IFN γ .¹⁰⁸

Last but not least, some authors also tested different chemotherapeutics in combination with RT and analyzed their impact on abscopal tumor regression.^{86,110,128} It is well-known that the induction of cancer cell death by distinct chemotherapeutics such as anthracyclines, cyclophosphamide, and oxaliplatin can activate strong anti-tumor immune responses, whereas other substances like mitomycin C fail to do so.^{3,113–117} Notably, we were unable to find a study which utilized any chemotherapeutic agent in order to enhance the abscopal effects of RT in fully immunocompetent animals. Instead, one group reported that abscopal effects on lung metastases were nearly completely

abolished upon combination of RT with paclitaxel in murine mammary carcinoma.¹¹⁰ Since combinations of RT and various chemotherapeutics are extensively used in the clinical routine, their potential to activate anti-tumor immunity and abscopal effects should be further investigated in preclinical model systems which mimic the clinical situation as closely as possible.

7 | CRITICAL PARAMETERS OF SYSTEMIC ANTI-TUMOR REACTIONS AND ABS COPAL EFFECTS INDUCED BY RADIOTHERAPY

7.1 | Timing and dosing of radiotherapy and additional therapeutics

So far, we have not paid attention to the dose of IR which was applied to the tumor in order to induce anti-tumor immunity. However, although desirable, it is not possible to extrapolate an 'optimal' RT scheme for the induction of abscopal effects. Only few researchers compared different irradiation regimens in their studies on out-of-field tumor regression and tested various RT schemes such as classically fractionated (2 Gy daily), hypofractionated (between 2 and 10 Gy per dose), and high single dose (i.e. ablative, ≥ 15 Gy) irradiation strategies.^{21,22,30,61,95,105,118} Fractionated and hypofractionated IR elicited potent anti-tumor immune responses in mouse models of melanoma, lymphoma, breast, colon, and lung carcinoma,^{25,27,30,69,105,119} and even brachytherapy (a technique where a radiation source is implanted into the tumor for continuous IR delivery with low dose rates) was successfully used in one study.⁷⁰ In contrast, other groups reported that anti-tumor immunity induced by ablative doses of ≥ 15 Gy was more potent than after fractionated treatments in murine melanoma and colon carcinoma,^{44,49} whereas Dewan et al.⁹⁵ found that hypofractionation (3 \times 8 Gy) was superior both to a single dose of 20 Gy and a regimen using more and smaller fractions (5 \times 6 Gy). In part, these results are conflicting, but it needs to be mentioned that the terms 'high-dose', 'low-dose', 'fractionated', and 'hypofractionated' RT are used inconsistently in preclinical reports, thus leading to misinterpretations when comparing studies from different researchers. Nevertheless, it is remarkable that the majority of all studies discussed here employed (high) single-dose IR or hypofractionated regimens with relatively large doses (≥ 6 Gy) to induce abscopal effects.

Apart from the efficacy of RT itself, the capacity of combined treatment approaches to synergize with IR may also have substantial impact on the therapeutic outcome: As discussed above, most studies demonstrated an enhanced therapeutic effect of RT when combined with additional therapeutics, whereas RT alone was either ineffective or inferior to the combined modality approaches tested. However, this is further complicated by the fact that not only timing and concentration of additional therapeutics but also their site of application may largely influence the establishment of anti-tumor immunity. For instance, abscopal tumor regression upon RT plus IL-2 administration was reported for systemic, peritumoral, or intratumoral IL-2 application, respectively, making it even more complex to identify the best-suited therapy.^{22,25,27,69} However, even large-scale experiments

with dozens of treatment groups evaluating the injection of an immunomodulatory substance at various time points and concentrations only have limited informative value.³⁰ Hence, efficacious combinatorial treatment approaches in preclinical models need to be carefully elaborated in order to prevent that unsuitable timing and dosing will disqualify a potentially useful therapeutic combination.

7.2 | Mediators of systemic, abscopal anti-tumor effects

Considering the work of various authors, there is clear evidence that RT-induced systemic immune responses and abscopal effects largely depend on T cells. This was demonstrated in numerous studies using T-cell depletion experiments.^{22,42,45,49,58-60,74,76,77,79,86,88,94,97,106,110,120} However, conflicting data were published on the contribution of CD4⁺ T cells, which were either important, dispensable, or even inhibitory in this context, respectively.^{22,49,59,74,76,77,79,86,88,94,106} Besides, several authors analyzed the antigen specificity of the relevant T-cell responses by employing animal tumors which express model antigens such as ovalbumin (OVA) or SIYRYGL—a peptide epitope derived thereof.^{44,45,76,110,119} On the one hand, these studies clearly demonstrated that RT (combined with other treatments) is able to induce tumor antigen-specific T cells which react to an antigen only expressed on cancer cells. On the other hand, the presence of foreign antigens in a tumor will increase its immunogenicity and thus artificially simplify tumor rejection unless the same antigen is also introduced into the host. This holds also true for the transduction of reporter genes, including luciferase and green fluorescence protein (GFP) which facilitate in vivo detection of tumor cells but also represent immunogenic antigens for the host's immune system.^{121,122}

Two recent studies have overcome this drawback of model antigen-expressing tumors by in-depth analyses of clonal T-cell expansion: Using immunosequencing of the T-cell receptor repertoire, both reports revealed that RT is able to increase the intratumoral T-cell receptor diversity in melanoma and colon cancer models.^{97,105} Interestingly, the two studies employed completely different RT regimens (1 \times 20 Gy vs 5 \times 2 Gy), thus proving that T-cell expansion after RT is not restricted to a specific irradiation regimen. Furthermore, Dovedi et al. not only analyzed T-cell clonality in irradiated but also in abscopal lesions. In their study, fractionated RT, albeit inducing a polyclonal T-cell response in the irradiated tumor, was unable to diversify the T-cell receptor repertoire at the abscopal site. Importantly, the limited systemic effects of fractionated RT on T-cell expansion were overcome by additional PD-1 blockade leading to strong diversification of the expanded T-cell clones at both tumor sites. This was paralleled by higher complete regression rates of non-irradiated tumors as compared to abscopal tumors in animals receiving RT alone.¹⁰⁵ The results further suggested that hypofractionated or ablative RT in combination with PD-1 blockade might even be more potent in this regard—an issue that needs to be addressed in greater detail. Nevertheless, the two studies clearly underline the importance of clonal intratumoral T-cell expansion, and it is evident that further studies with focus on the T-cell receptor repertoire will improve our understanding of T cell-mediated

abscopal tumor regression. Yet, it needs to be mentioned that the induction of T-cell responses alone is not always predictive of potent anti-tumor immunity. For instance, recruitment of immune cells, including T cells, into tumors may be abrogated by a process termed endothelial cell anergy. This inactivation of the tumor endothelium is characterized by downregulation of Intercellular Adhesion Molecule-1 (ICAM-1)^{123,124} and can be overcome by local low-dose (2 Gy) IR leading to activation of inducible NO synthase (iNOS) expressing macrophages.¹²⁵ However, in other settings, endothelial cell anergy may inhibit potent anti-tumor immune responses even in the presence of tumor-specific T cells.

A few studies also suggested that not exclusively T cells and their effective priming by DCs but also other factors contribute to abscopal anti-tumor responses. For example, an involvement of NK cells and a negative regulation by intratumoral MDSCs have been proposed,^{30,49,68,86,126} whereas B cells appear to be dispensable.^{78,83} Furthermore, two groups reported on the tumor suppressor protein p53 as a mediator of RT-stimulated abscopal effects. Murine lung tumors and fibrosarcomas regressed upon excessive irradiation of distant healthy tissue in wildtype but not in p53 mutant mice.¹²⁷ The mechanisms underlying this effect were not further dissected, but an involvement of massive inflammatory cytokine production was proposed. Another study employed human colorectal xenografts with wildtype or p53 mutant tumors in nude mice, thus excluding any influence of T cells.¹¹⁸ Apart from this report, abscopal effects on human pancreatic xenograft tumors were also observed in T cell-deficient mice.¹²⁸ Although none of the two studies using nude mice clearly identified the major anti-tumoral effector(s), it may be speculated that NK cells exert inflammation-induced systemic anti-tumoral activity upon tumor RT—even or particularly if functional T cells are absent. Though, abscopal effects on human melanoma were also described upon combination of RT with injections of mesenchymal stem cells into NOD/SCID mice which are deficient in both B-, T-, and NK cells.¹²⁹ Taken together, it can be concluded that the effects of RT on distant tumors are clearly but not exclusively T cell-dependent. The great majority of studies in this field either directly demonstrated the requirement of CD8⁺ and/or CD4⁺ T cells, suggested their key player functions, or at least did not exclude a crucial role of T cells in mediating anti-tumor immunity and abscopal effects, respectively.

Finally, it is important to stress that, within the last two decades, most authors who detected abscopal tumor responses concentrated on their strength to inhibit distant tumor cell growth. Commonly, the efficacy to induce abscopal effects of RT alone was lower than in a combinatorial therapeutic setting. However, a few studies discussed here clearly showed or at least speculated on negative abscopal responses in tumor-bearing hosts, i.e. enhanced abscopal tumor growth compared to non-irradiated animals.^{69,118,128,130–132} Strikingly, the question whether local tumor irradiation might enhance or prevent abscopal metastasis growth (or the metastatic capacity of a tumor) was controversially discussed in recent times as reviewed by von Essen.¹³³ An early study by Kaplan and Murphy found an increase in pulmonary metastasis of subcutaneously implanted mammary carcinoma upon IR,¹³² and similar effects were described more than half a century later

in a study by Camphausen et al.¹³¹ using lung and fibrosarcoma tumors. At first sight, these reports appear to be in stark contrast to those of various other authors who showed a therapeutic benefit of primary tumor RT on distant metastasis. However, it is important to stress that both Kaplan and Murphy and Camphausen et al. started tumor RT treatment at a comparably late stage of tumor development when tumor diameters were in the range of 1 cm, whereas the vast majority of researchers who found anti-tumor abscopal effects applied RT as soon as tumors were palpable—i.e. at much earlier time points. Although it is impossible to reconstruct whether this fully explains metastasis-promoting abscopal effects described in historic experiments, we hypothesize that the pioneers of preclinical tumor RT tended to initiate tumor RT at much later time points. Hence, negative abscopal effects of primary tumor RT in immunocompetent models may simply be considered as a confirmation of the aforementioned study by J. Vaage⁶¹ who stated that ‘immune resistance’ against murine tumors reaching 7–8 mm diameter gradually declines with further tumor growth. Later on, Vaage et al.¹³⁰ described that IR of the whole abdomen (most likely including the spleen) enhanced the growth of lung nodules after intravenous tumor cell injection. Similarly, another group demonstrated that RT of healthy tissue rather increased lung tumor growth of intravenously injected tumor cells.⁶⁹ Finally, both of the studies that used nude mice showed moderate abscopal protumor effects of RT alone, although these effects were not tested for their statistical significance.^{118,134} Taken together, these results demonstrate that not only the magnitude of abscopal anti-tumor effects but also the possibility of distant tumor growth promotion needs to be considered. Accordingly, the absence of any effect in a given setting may actually be the sum of two or more opposing abscopal phenomena which—when assessing a certain readout endpoint such as tumor volume—unperceivably add up to zero. Besides, the studies in which normal tissue of immunocompetent animals was irradiated might suggest that applying IR to non-malignant tissue should not only be avoided in order to minimize healthy tissue damage but also to prevent potential growth-promoting abscopal effects on distant tumor cells.^{69,130,135}

8 | CLINICAL EXPERIENCES WITH ABS COPAL EFFECTS OF RADIOTHERAPY

From a clinician's perspective, abscopal effects appear unreal and promising at the same time. Phenomena like spontaneous tumor regression and reduction of untreated tumor lesions following RT are indeed very rare, however, several case reports have been discussed in the literature and serve as a basis for new avenues in research as well as for the development of new treatment approaches.

Abscopal effects could be regarded as special variants of spontaneous tumor regression resulting from radiobiological influences. While in some early descriptions, the true existence of a malignant lesion that was treated remains questionable, later reports are more precise and are mostly confirmed by histological examinations.¹³⁶ A systematic analysis of such cases published in the first half of the 20th

century shows—apart from a steady increase in the number of reports—that some cancer entities seem to lead to spontaneous regression more frequently than others.¹³⁶ Additionally, a trend concerning relevant trigger factors was determined and included immunological factors, irradiation, infection, and others.¹³⁶ A potential relationship between infection, cancer, and immune responses was already observed by W.B. Coley in 1893, when a patient having undergone several operations of his sarcoma showed a regressive response after an incidental erysipelas infection of his surgical wound.¹³⁷ W.B. Coley could further confirm these observations and employed them to develop an early immunotherapeutic approach by artificial injection of streptococci with imposing results: Several of his patients experienced improvements, and some were even cured of disease¹³⁷ (Figure 1).

Immense scientific advances meanwhile offer diverse options for the treatment of cancer today. Nevertheless, cancer therapy is still a challenge, and spontaneous regression remains an exceptional phenomenon. While abscopal effects of RT have repeatedly been reported since the beginning of the 20th century, the number of case reports clearly increased with the introduction of immunomodulatory agents such as immune checkpoint inhibitors targeting CTLA-4 and the PD-1/PD-L1 axis.⁵³ This suggests a close association between radiobiological and immunological mechanisms interacting in complex ways and renders them highly promising with regard to therapy optimization.

9 | CASE REPORTS

Over the last decades, several case reports of RT-induced abscopal effects have been published. A systematic search of the respective literature reveals that sometimes the definition of abscopal effects is not restricted to out-of-field responses toward RT only but also to other types of therapy,¹³⁸ whereas in other cases abscopal effects stimulated by RT are described as ‘spontaneous tumor regression’, thus rendering comprehensive analyses challenging.^{139–141} At first sight, the majority of patients with RT-induced abscopal effects are of advanced age, suffer from progressed and metastasized cancer, and are treated in palliative settings (Table 2). Although various cancer entities can be found, some occur more frequently than others, particularly malignant melanoma, lymphoma, renal cell carcinoma (RCC), and hepatocellular carcinoma (HCC). Regarding prior therapies and preexisting conditions, the group of patients is highly heterogeneous.^{139,142–145} Some patients have undergone multiple different treatment approaches,^{146,147} and in other cases new additional therapies were started directly after the abscopal effects had been noticed.^{144,145} Follow-up times are commonly short, and causes of death are often not documented in detail.^{148,149} Most of the available case reports seem to reliably present RT-induced abscopal effects. Nevertheless, especially with such unusual and rare phenomena, a careful, well-structured and complete presentation is of primary importance. Moreover, systematic analysis of the available reports is complicated by very heterogeneous depth in information, incoherent assessment criteria, missing time specifications and statistics, as well

as hardly any patient and treatment details.¹⁴⁵ Importantly, the question about consistent documentation arises, as publications mostly are restricted to university hospitals, thus implying a bias for statistical analyses. This bias could even be aggravated by inhomogeneous availability of highly specialized imaging techniques as well as by their continuous technical improvement over time—in other words, lesions and their dynamics which might be imaged easily today would not have been detected a few decades ago.

Despite the above mentioned difficulties and limitations of published case reports, attempts to systematically analyze RT-related abscopal effects have been undertaken and allow insights into the frequencies and the groups of patients who displayed abscopal effects, even if they may not entirely present all cases published. Reynders et al. accurately analyzed 23 case reports and one retrospective study conforming with well-defined research criteria and calculated a median age of 64.5 years and a median total irradiation dose of 32 Gy (12–60.75 Gy) at single doses between 1.2–26 Gy.⁵³ The primary tumor was irradiated in eight patients, whereas metastases or lymph nodes constituted the irradiated volume in 15 cases. Abscopal responses occurred after less than 1–24 months persisting for a median time of 5 months, and relapse-free follow-up lasted for a median time of 13 months, but could not be determined in all cases.⁵³ This study shows that—although reports are heterogeneous—some common features, including age, tumor stage, and predominating cancer entities can be extracted and should be investigated in greater detail with view to, but independent of preclinical results, in order to develop improved treatment strategies and to evaluate the transferability of preclinical results into clinical application.

10 | MECHANISTIC CONSIDERATIONS

The therapeutic accessibility of tumor cells is one major challenge in cancer treatment, especially when trying to protect the normal healthy tissue. As described above, tumors evade immune control and hamper access and function of immune cells by various strategies. The mechanistic basis for RT-induced abscopal effects is a penetration and/or reversal of this immunosuppressive milieu, not only in the irradiated but also in distant lesions and maybe even systemically. Under certain conditions, RT is able to trigger these processes. However, the key factors such as irradiation dose, fractionation regimen, as well as size and localization of the irradiated lesion remain to be characterized in greater detail. Apparently, the clinical implementation of immune checkpoint blockers has rendered case reports with RT-induced abscopal effects more frequent suggesting a high degree of synergism between RT and immune checkpoint inhibition.⁵³

10.1 | Immune checkpoint blockade in clinical use: Some limitations when applied as monotherapy

Immune checkpoint blocking antibodies targeting CTLA-4 or the PD-1/PD-L1-axis can unleash endogenous anti-tumor immune responses with impressive results. Accordingly, clinical approval was

TABLE 2 Selected clinical case reports of RT-induced abscopal effects

Author	Sex	Age	Tumor entity	Treatment history	Immunotherapy	RT	Area of abscopal regression	Time to abscopal response
<i>Melanoma</i>								
Kingsley ¹⁹⁶	m	28	Melanoma	Surgery, RT	None	Inguinal region (14.4 Gy, 12 fr, 35 days)	Para-aortic lesion	9 months
Postow et al. ¹⁵⁹	f	33	Melanoma	Surgery, LN dissection, chemotherapy, surgery, Ipilimumab, RT	Ipilimumab	Paraspinal lesion (28.5 Gy, 3 fr, 7 days)	Hilar LN, spleen	4 months
Hiniker et al. ¹⁶⁰	m	57	Melanoma	Surgery, LN dissection, surgery, RT (1), IFN, surgery, Ipilimumab, RT (2)	IFN, Ipilimumab	RT (1): arm (50.4 Gy, 20 fr); RT (2): liver lesions (54 Gy, 3 fr)	Arm	≈6 months after RT ²
Stamell et al. ¹⁶¹	m	67	Melanoma	Chemotherapy, RT (1), RT (2), Ipilimumab, surgery	Ipilimumab	RT (1): lesions on head and neck (24 Gy, 3 fr); RT (2): brain metastasis (SRS)	LN metastases	n.a.
Teulings et al. ¹⁷³	m	67	Melanoma	Surgery, LN dissection, RT (1), neurosurgery, RT (2), chemotherapy	None	RT (1): axilla and suprascapular region (50 Gy, 30 fr); RT (2): WBRT (20 Gy, 5 fr)	Lung, mediastinum, vitiligo-like depigmentation in non-irradiated areas	2 weeks after RT ²
Okwan-Duodu et al. ¹⁶²	f	50	Melanoma	Surgery, LN dissection, IFN therapy, RT (1), IL-2, RT (2), Ipilimumab, surgery, Vemurafenib	IFN, IL-2, Ipilimumab, Vemurafenib	(1) SRS; (2) WBRT	Pulmonary/retroperitoneal/mesenteric LN	After RT ²
Thallinger et al. ¹⁶³	m	44	Melanoma	Ipilimumab, RT, chemotherapy	Ipilimumab	WBRT (10×3 Gy)	Renal/lung/liver metastases, ascites	Some w after RT
Barker and Postow ¹⁶⁴	m	66	Melanoma	Ipilimumab, RT	Ipilimumab	Internal mammary LN (3×9 Gy)	Left axillary LN	3 months
<i>Lymphoma</i>								
Braun and Maziarz ¹⁹⁷	m	50	T cell rich B cell lymphoma	Chemotherapy, RT, G-CSF, leukapheresis for planned bone marrow transplantation	G-CSF	Vertebral and pelvic region (40.8 Gy, 24 fr)	Reduced colony formation of stem cells after RT	≈3 weeks
Robin et al. ¹⁹⁸	f	59	Histiocytic lymphoma	Chemotherapy, RT	None	Kidney (20 Gy, 2 weeks)	Contralateral kidney	Directly after RT
Rees ¹⁴⁵	n.a.	n.a.	Hodgkin's disease	RT	None	Mantle-field (35 Gy, 28 days)	Pelvis	Shortly after RT
Rees ¹⁴⁵	n.a.	n.a.	Hodgkin's disease	RT	None	Mantle-field (35 Gy, 24 days)	Pelvic LN, para-aortic LN	Shortly after RT
Rees ¹⁴⁵	n.a.	n.a.	Hodgkin's disease	RT	None	Para-aortic and pelvic LN (38 Gy, 39 days)	Axillary LN	Shortly after RT
Rees ¹⁴⁵	n.a.	n.a.	Hodgkin's disease	RT	None	Mantle-field (40 Gy, 29 days)	Para-aortic lesion	Shortly after RT
Rees ¹⁴⁵	n.a.	n.a.	Follicular lymphoma	RT	None	Abdomen (21 Gy, 30 days)	Regress of pleural effusion	Shortly after RT
Rees ¹⁴⁵	n.a.	n.a.	Follicular lymphoma	RT	None	Posterior chest wall, right axilla (21 Gy, 15 V)	Axillary LN, spleen	Shortly after RT
Rees ¹⁴⁵	n.a.	n.a.	Lymphosarcoma	RT, abscopal effect, RT*	None	Groin (18 Gy, 13 days)	Nuchal LN	2 months

(Continues)

TABLE 2 (Continued)

Author	Sex	Age	Tumor entity	Treatment history	Immunotherapy	RT	Area of abscopal regression	Time to abscopal response
Rees ¹⁴⁵	n.a.	n.a.	Non-Hodgkin's lymphoma	RT, chemotherapy	None	Breast (35 Gy, 34 days); pelvis (20 Gy, 34 days)	Mediastinum	n.a.
Rees ¹⁴⁵	n.a.	n.a.	Reticulum-cell sarcoma	RT, abscopal effect, RT*	None	Paraaortic and pelvic LN (39 Gy, 43 days)	Axillary LN	Shortly after RT
Rees ¹⁴⁵	n.a.	n.a.	Follicular lymphoma	RT	None	Nuchal LN, supraclavicular LN (30 Gy, 22 days)	Bilateral axillary LN	Shortly after RT
Antoniades et al. ¹⁴⁹	m	44	Lymphocytic lymphoma	RT	None	Supradiaphragmatic LN, Waldeyer's ring, pulmonary lesion (30 Gy, 20 fr, 34 days)	Abdominal LN	Shortly after RT
Antoniades et al. ¹⁴⁹	m	40	Lymphocytic lymphoma	RT	None	Supradiaphragmatic LN, Waldeyer's ring (30 Gy, 20 fr, 26 days)	Abdominal LN	Shortly after RT
Isobe et al. ¹⁴⁷	m	65	Natural killer cell lymphoma	Chemotherapy, RT	None	Skin (40 Gy)	Submandibular LN	<2 months after regression
Michot et al. ¹⁹⁹	m	33	Hodgkin's lymphoma	Chemotherapy, autostemcell transplantation, chemotherapy, Pembrolizumab, RT	Pembrolizumab	Mediastinal LN (30 Gy, 10 fr, 12 days)	Coeliac LN, supra-/infradiaphragmatic LN	2 months
Nobler ¹⁷¹	m	52	Malignant lymphoma	RT	None	Retroperitoneal and paraaortic LN (35 Gy, 26 days)	Liver, spleen, inguinal/femoral LN, pulmonary lesions	Directly after RT
Sham ²⁰⁰	m	77	Chronic lymphatic leukemia	Chemotherapy, RT	None	Nuchal and supraclavicular region (32.4 Gy)	White blood cell count, spleen	3 weeks
Lakshmanagowda et al. ²⁰¹	f	65	Chronic lymphatic leukemia	Chemotherapy, RT	None	Axillary LN (24 Gy, 12 fr, 3 weeks)	Nuchal LN	1 week
<i>Diverse solid tumors</i>								
Tubin et al. ¹⁴⁸	m	72	Medullary thyroid carcinoma	Surgery, LN dissection, tyrosine kinase inhibitor (XL184)—discontinuation, RT, abscopal effect, RT*	Tyrosine kinase inhibitor (XL184)	Mediastinal LN level 4R (30 Gy, 3 fr)	Mediastinal LN station 6	1 month
Orton et al. ²⁰²	m	84	Pleomorphic soft tissue sarcoma	Surgery, RT	None	Postauricular lesion (40 Gy, 8 fr)	Lung metastases	2 months
Takaya et al. ²⁰³	f	69	Cervical cancer	RT (1), RT (2)	None	RT (1): pelvis (1.6×1.8 Gy, 4 weeks); interruption of RT; continuation with (1.1×2 Gy, 3 weeks); RT (2): intracavitary irradiation (4×6 Gy, 4 weeks)	Paraortic LN	Shortly after RT ²

(Continues)

TABLE 2 (Continued)

Author	Sex	Age	Tumor entity	Treatment history	Immunotherapy	RT	Area of abscopal regression	Time to abscopal response
Sato et al. ²⁰⁴	m	54	Gastric cancer	Surgery, chemotherapy, adoptive T cell immunotherapy and DC therapy, RT	Adoptive T cell immunotherapy, DC therapy	Stomach (48 Gy, 24 fr)	Peritoneal lesions	2 months
Lome et al. ¹⁷²	m	66	Transitional cell carcinoma of the bladder	RT, surgery	None	Pelvis (40 Gy, 4 weeks)	Pulmonary lesions	5 months
Fairlamb et al. ¹⁴⁰	f	73	Renal cell carcinoma	Surgery, RT, surgery	None	Groin lesion (40 Gy, 15 fr, 20 days)	Pulmonary lesion	2 months
MacManus et al. ¹⁴¹	m	58	Renal cell carcinoma	RT, abscopal effect, RT*	None	Kidney (10×2 Gy, 2 weeks)	Paratracheal LN, pulmonary/intrathoracic lesions	6 months
Wersäll et al. ¹⁴⁴	f	83	Renal cell carcinoma	RT	None	Kidney (4×8 Gy, 2 weeks)	Lung lesions, renal LN	2 years
Wersäll et al. ¹⁴⁴	f	64	Renal cell carcinoma	Surgery, RT, IFN (terminated), IL-2 (terminated), abscopal effect, thalidomide, RT*	IFN, IL-2	Lung nodules (details n.a.)	Untreated lung lesions	5 months
Wersäll et al. ¹⁴⁴	m	69	Renal cell carcinoma	Surgery, RT, abscopal effect, RT*	None	Lung metastases (2×15 Gy)	Untreated lung metastases	3 months
Wersäll et al. ¹⁴⁴	f	55	Renal cell carcinoma	Surgery (terminated), RT	None	Kidney (4×8 Gy, 2 v)	Lung metastasis	5 months
Desar et al. ¹⁴⁶	m	19	Diffuse-type giant cell tumor	Surgery, Imatinib, RT	Imatinib	Hilar lesion (30 Gy, 10 fr)	Pulmonary lesions	2 weeks
Ohba et al. ¹⁴²	m	76	Hepatocellular carcinoma	Surgery, transcatheter arterial embolization, hepatic arterial infusion with chemotherapy, ethanol injection, RT	None	Vertebral bone metastasis (36 Gy)	Hepatic nodules	10 months
Nam et al. ¹³⁹	m	65	Hepatocellular carcinoma	Mushroom ingestion, RT	None	Skull mass (≈30 Gy)	Hepatic/rib/sternal metastases	10 months
Nakanishi et al. ¹⁷⁶	m	79	Hepatocellular carcinoma	Transcatheter arterial embolization of 1 big hepatic lesion, RT of inferior vena cava lesion	None	Inferior vena cava lesion (≈48 Gy)	Hepatic lesions	5 months
Okuma et al. ²⁰⁵	m	63	Hepatocellular carcinoma	Surgery, RT, abscopal effect, RT*	None	Mediastinal LN (60.75 Gy à 2.25 Gy)	Lung metastasis	Directly after RT
Lock et al. ¹⁴³	m	71	Hepatocellular carcinoma	Sorafenib, RT, hepatic artery embolization	Sorafenib	Liver (70 Gy, 15 fr)	Pulmonary lesions	4 months
Golden et al. ¹⁷⁴	m	64	Adenocarcinoma, lung	Chemotherapy, RT (1), chemotherapy, Ipilimumab, RT (2)	Ipilimumab	RT (1): lung/supraclavicular/hilar lesions, mediastinal LN (59.4 Gy, 33 fr); RT (2): liver lesion (30 Gy, 5 fr, 10 days)	Liver/osseous lesions, lung metastases, hilar LN	Shortly after RT ²

(Continues)

TABLE 2 (Continued)

Author	Sex	Age	Tumor entity	Treatment history	Immunotherapy	RT	Area of abscopal regression	Time to abscopal response
Rees and Ross ²⁰⁶	m	49	Adenocarcinoma, lower esophagus	RT	None	Lung lesions (40 Gy, 20 fr, 28 days)	Non-irradiated lung lesions	shortly after RT
Rees and Ross ²⁰⁶	m	56	Adenocarcinoma, lung	Surgery, RT	None	Mediastinum, left lung (35 Gy, 10 fr, 12 days)	Forehead mass, deltoid mass	During RT
Siva et al. ²⁰⁷	f	78	Non-small-cell lung carcinoma	RT (1) and chemotherapy, RT (2), abscopal effect, RT*	None	RT (1): left pulmonary lesion (60 Gy, 30 fr), RT (2): right pulmonary lesion (1x26 Gy)	Humeral bone lesion, adrenal gland	12 mo after RT ²
Ehlers and Fridman ²⁰⁸	f	35	Papillary adenocarcinoma	RT	None	Nuchal, supraclavicular LN (40 Gy, 4 weeks)	Mediastinal lesion	After RT

DC, dendritic cell; f, female; fr, fraction; IFN, interferon; IL, interleukin; LN, lymph node; m, male; n.a., not available; RT, radiotherapy; SRS, stereotactic radiosurgery; WBRT, whole-brain radiotherapy; *, performed after abscopal effect and therefore not specified.

granted for several cancer entities, including metastatic melanoma, RCC, non-small cell lung cancer (NSCLC), and others (Figure 1).

Although overall response rates of Ipilimumab monotherapy in metastatic melanoma are relatively low with approximately 11%, responding patients show clearly improved survival rates, and a subgroup of long-term survivors has been described.⁹³ Nevertheless, Ipilimumab treatment is often limited by severe toxic effects, including rash, colitis, diarrhea, pruritus, dermatitis, uveitis, nephritis, and hepatitis—synoptically (auto-)immune-related symptoms which can be life-threatening in the worst case.^{150,151} In order to counteract these adverse effects, immunosuppressive agents such as steroids, Infliximab and Mycophenolate mofetil are applied.¹⁵² Undoubtedly, immunosuppressive therapy is crucial in order to control adverse events of immune checkpoint blockade, but these measures will most likely also interfere with beneficial anti-tumor immune responses. A further limitation of Ipilimumab is its known limited (tumor) tissue penetration.¹⁵¹ Consequently, strategies to improve tumor-specific enrichment and effectiveness of Ipilimumab would be advantageous. In this regard, RT and immune checkpoint blocking agents may collaborate and synergize with each other. The in situ vaccinating potential of RT might help to increase local availability and efficacy of checkpoint blockade and at the same time reduce systemic complications.^{153–155}

10.2 | Combinatorial strategies: Synergism and timing

Considering their closely related modes of action, the question of combining different immune checkpoint blockers arises immediately. As their individual targets differ but exert similar functions, their combination might provide improved therapeutic outcome at lower doses. In fact, trials of combined modality approaches with Ipilimumab and Nivolumab reported prolonged survival in the combined treatment arms. However, this was linked to increased occurrence of adverse events, particularly high-grade toxicity.¹⁵⁶ Therefore, the search for appropriate synergistic combination partners with acceptable total toxicity continues. Once more, RT represents an interesting candidate in this regard. Intriguingly, in some case reports where palliative patients often progressed under immune checkpoint blocking therapy alone, local and abscopal responses were observed when radiotherapy was added.^{157–159}

A fundamental difference between most of the radiotherapeutic regimens implemented in the clinical routine and the presented case reports of RT-induced abscopal effects is the volume of tumor and/or metastasis mass that is irradiated. As case reports often concern palliative settings, the entire lesion is irradiated. Thus, upon RT an enormous amount of tumor antigen most likely is released compared to postoperative, adjuvant RT which is standard for the majority of cases in the clinical routine. In one case report, a biopsy sample of the irradiated kidney tumor was subjected to histological examination after manifestation of the abscopal effect.¹⁴¹ Excessive necrosis was described in this sample which might well have contributed to the activation of anti-tumor immune responses in the sense of potent in situ vaccination (Figure 2).

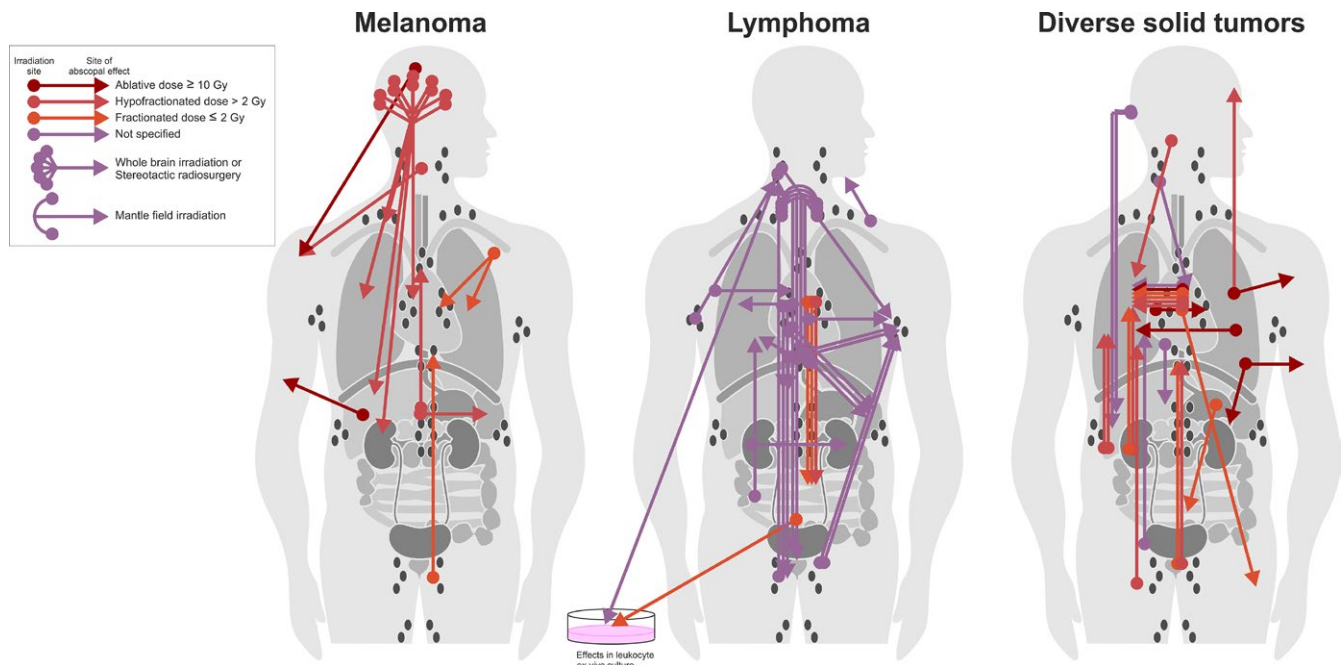


FIGURE 4 Topology of abscopal effects. Available information from clinical case reports and retrospective analyses discussed in this review is implemented in this figure. Abscopal effects in patients with melanoma (left), lymphoma (middle), and with diverse solid tumors except melanoma (right) were considered. Sites of RT (bullet) and of abscopal effects (arrowhead) are indicated. Colors illustrate different irradiation regimens [Colour figure can be viewed at wileyonlinelibrary.com]

11 | OBSERVATIONS IN DIFFERENT CANCER ENTITIES

As already mentioned, systematic analyses of the available case reports imply difficulties and limitations when aiming at extracting a common denominator which should be considered for future treatment approaches in order to fully exploit the therapeutic potential of RT-induced abscopal effects. Case reports from various cancer entities with known differences in immunogenicity have been published, letting it appear reasonable to discuss them separately (Table 2). We have also tried to visualize the reported abscopal effects with regard to cancer entity, irradiated site, irradiation regimen, and site of the described abscopal effects in a schematic drawing (Figure 4).

11.1 | Melanoma

Ipilimumab and other immune checkpoint blockers have reached clinical approval for the treatment of metastatic melanoma due to very convincing trial results.^{93,99,156} Subsequently, they have been described in several case reports of RT-induced abscopal effects,^{159–164} and the combination of RT plus checkpoint inhibition is subject of current clinical trials^{157,165,166} (Table 3). Obviously, checkpoint inhibition powerfully enforces the occurrence of RT-induced abscopal effects. However, this seems to be strongly dependent on the cancer entity, as in case of advanced prostate cancer no comparable observations have been described.¹⁶⁷ Melanoma is a cancer with high mutation frequency, and this might well be responsible for the fact

that stronger immune responses can be triggered in melanoma than in other cancer entities.^{168,169} A clinical observation which underlines this increased anti-melanoma activity is the development of vitiligo upon, e.g. Pembrolizumab treatment.¹⁷⁰ Vitiligo is an acquired autoimmune disease against active melanocytes resulting in depigmented areas of skin at different sites of the body and was shown to go along with better treatment outcome.¹⁷⁰ Like abscopal responses after RT, in these cases vitiligo is a systemic immune effect caused by immunotherapy. In a case report on abscopal effects in metastatic melanoma, seroreactivity to melanocyte antigens was analyzed and melanoma-associated antigen A3 showed seropositivity after radiotherapy which increased even further with administration of Ipilimumab.¹⁶¹ Some trials have been set up in order to investigate the frequencies of RT-induced abscopal effects in melanoma and show impressive results. Between 25 and 52% of patients with advanced melanoma undergoing RT plus checkpoint inhibition displayed abscopal effects, and compared to patients without abscopal effects, they had significantly prolonged overall survival times.^{157,165,166} Although these studies have their limitations, the reported frequencies of abscopal effects are quite remarkable. Yet, these observations could be linked to the particular immunogenicity of malignant melanoma and may not be entirely transferable to other cancer entities.

11.2 | Lymphoma

Another particular field of RT-induced abscopal effects is lymphoma. In 1969, M.P. Nobler was the first to describe an abscopal effect in malignant lymphoma (giant follicle type) and to provide careful

TABLE 3 Selected clinical trials assessing RT-induced abscopal effects

NCT number	Study start date	Phase of Trial	Tumor entity	Irradiation regimen	Additional therapeutics	Outcome measure and comments
NCT03113851	04/2017	Phase II	Non-small-cell lung carcinoma	10×3.5 Gy	rhGM-CSF	Abscopal effect rate assessment for up to 50 months, proportion of patients with abscopal effects after treatment
NCT02334709	02/2014	Phase I/II	Renal cell carcinoma	3×8 Gy, 3×10 Gy, 3×12 Gy	Tyrosine kinase inhibitor	Immunomonitoring for up to 4 years
NCT02474186	04/2003	Phase II	Breast cancer and other solid tumors	10×3.5 Gy	Concurrent systemic therapy (single agent) and GM-CSF	Abscopal effect assessment 7-8 weeks after initiation of treatment; published in 2015 ¹⁷⁹
NCT02787447	05/2016	Phase II	Non-small-cell lung carcinoma	40-45 Gy, 5-15 fr	Thymalfasin, Gefitinib, Erlotinib, Icotinib	Proportion of patients with an abscopal response 1-6 months after RT
NCT02623595	05/2016	Phase II	Non-small-cell lung carcinoma	5×10 Gy	rhGM-CSF	Abscopal effect rate 4 weeks after completion of rhGM-CSF therapy
NCT01401062	07/2011	Phase II	Breast cancer	3×7.5 Gy in week 1 and week 7 given to two different lesions	Fresolimumab	Abscopal effect rate assessment for up to 20 weeks
NCT02406183	03/2015	Phase I	Melanoma	3×8 Gy, 3×10 Gy, 3×12 Gy	Ipilimumab	Immunomonitoring for up to 2 years
NCT02830594	10/2016	Phase II	Gastric, esophageal, and/or gastroesophageal junction cancer	Multifractionated RT	Pembrolizumab	Assessment of progression-free survival for up to 36 months
NCT02562625	02/2016	Phase II	Melanoma	3×8 Gy	Pembrolizumab	Abscopal effect assessment for up to 60 months after randomization
NCT02976740	11/2016	Phase II	Non-small-cell lung carcinoma	50 Gy in 4-10 fr	rhGM-CSF and thymalfasin	Abscopal effect rate 4 weeks after completion of combined treatment
NCT02538471	08/2015	Phase II	Breast cancer	3×7.5 Gy	TGF-β receptor I kinase inhibitor LY2157299	Abscopal effect assessment for up to 16 weeks
NCT02992912	11/2016	Phase II	Solid tumors	3×15 Gy	Atezolizumab	Assessment of progression-free survival for up to 1 year
NCT01689974	01/2013	Phase II	Metastatic Melanoma	5×6 Gy	Ipilimumab	Abscopal effect assessment
NCT02115139	04/2014	Phase II	Melanoma with brain metastasis	10×3 Gy (WBRT)	Ipilimumab	Immune-related response criteria
NCT01734564	11/2012	Phase II	Solid tumors	n.a.	Hiltonol, DC transfer	Abscopal effect assessment
NCT00188929	08/2005	Phase II	Non-Hodgkin's lymphoma	≥30 Gy, ≥20 fr, ≥3 weeks	None	Abscopal effect assessment
NCT03085719	04/2017	Phase II	Head and neck cancer	3× high-dose RT or 3× high-dose and 3× low-dose RT	Pembrolizumab	Abscopal effect assessment for up to 1 year
NCT02888743	05/2017	Phase II	Colorectal carcinoma or Non-small-cell lung carcinoma	High-dose or low-dose RT	Durvalumab, Tremelimumab	Abscopal tumor response rate up to 2 years
NCT02501473	06/2015	Phase I/II	Follicular Non-Hodgkin's lymphoma	Standard low-dose RT	G100 (Phase I), Pembrolizumab (Phase II)	Abscopal tumor response
NCT03150836	07/2017	Phase II	Bladder cancer	5×6 Gy or 5×6.6 Gy	Durvalumab, Tremelimumab	Abscopal effect assessment for up to 50 months

DC, dendritic cell; fr, fraction; rh, recombinant human; GM-CSF, granulocyte macrophage colony-stimulating factor; n.a., not available; RT, radiotherapy; rh, recombinant human; TGF, transforming growth factor; WBRT, whole-brain radiotherapy.

explanations about its origin: A patient suffering from multifocal lymphadenopathy and bilateral hydronephrosis showed a complete abscopal response after paraaortic and retroperitoneal irradiation¹⁷¹ (Figure 1). With the knowledge of that time, the author explained this by a partial loss of lymphoma cells after irradiation followed by recirculation of new lymphoma cells into the irradiation field leading to a general decrease in lymphoma cell counts. A similar explanation of abscopal effects observed in lymphocytic lymphoma was given a few years later, thus supporting this theory of gradual lymphoma cell depletion.¹⁴⁹ The first idea that the immune system could be involved in RT-mediated abscopal effects was presented together with several other theories in the context of mantle field irradiation of lymphoma in 1981 proposing a possible release of 'antigens capable of stimulating cytotoxicity through immune mechanisms'.¹⁴⁵ Unfortunately, this concept was abandoned. More than 20 years later, a case report on natural killer cell lymphoma described complete regression of the primary lesion with appearance of a submandibular lymphadenopathy after chemo- and radiotherapy. This second lesion responded after 2 months without further treatment, and histological analyses showed an increased infiltration of CD8⁺ T cells in the secondary lesion, which was not detectable in the primary lesion.¹⁴⁷ Steady fluctuation and systemic trafficking of tumor cells in many hematologic malignancies might explain their susceptibility to abscopal effects.¹⁴⁵ Therefore, generalization to other cancer entities might be rather limited.

11.3 | Diverse solid tumors

RT-mediated abscopal effects have been reported also for diverse solid tumors. Nevertheless, two entities appear to dominate: RCC and HCC. An interesting detail in two of the collected case reports is that progressive disease was observed at one site, while abscopal regression was simultaneously described at different other sites of the body.^{146,172} This implies that the susceptibility of some metastases to abscopal responses seems to be different than that of others, and it needs to be clarified which factors are responsible in this scenario.

11.4 | Brain lesions

Due to its particular anatomy and the blood-brain barrier, the brain's accessibility for drugs and cells of the immune system underlies specific restrictions. Accordingly, the question arises if RT-mediated abscopal effects with involvement of brain lesions (metastases as well as primary brain tumors) display certain peculiarities. Among the published case reports on RT-stimulated abscopal tumor regression, there is a number of melanoma cases with brain metastases.^{161-163,173} Intriguingly, to our knowledge, so far no case report has shown abscopal brain metastasis regression when peripheral lesions were irradiated. On the contrary, two reports showed peripheral abscopal responses upon brain irradiation (whole brain RT as well as stereotactic radiosurgery with and without additional immune checkpoint blockade).^{162,163} Two other reports presented similar cases, where abscopal effects appeared after brain radiotherapy.^{161,173} However, it

needs to be considered that these patients had already received previous RT treatments in other body regions, and it cannot be specified if the abscopal effects were primarily due to brain irradiation or the preceding RT. Although these reports have their limitations, it appears that abscopal effects can be stimulated by irradiation of brain lesions, whereas irradiation of peripheral nodules vice versa fails to stimulate abscopal lesion regression in the brain.

12 | CELLULAR AND MOLECULAR PARAMETERS IN PATIENTS WITH RADIOTHERAPY-INDUCED ABS COPAL EFFECTS

Although patients with RT-induced abscopal effects represent a rather heterogeneous group, they exhibit common features—not only clinically, but also on a cellular and molecular level. However, since abscopal responses are generally not expected a priori, all analyses were performed retrospectively, and systematic prospective evaluations are not available.

In the well-known case report by Postow et al.,¹⁵⁹ abscopal lesion regression in a patient with metastatic melanoma upon RT in combination with Ipilimumab treatment was accompanied by increased serum antibody titers against the tumor antigen NY-ESO-1. Additional flow cytometric analyses revealed elevated expression of MHCII on circulating monocytes and a decline in circulating MDSCs. Moreover, levels of activated circulating CD4⁺ICOS^{hi} T cells showed an intense increase. Golden et al. investigated the dynamics of blood cell counts in an abscopally responding patient with NSCLC and found peaks in leukocytes, lymphocytes, and eosinophils directly after the start of concomitant radioimmunotherapy with Ipilimumab. Simultaneously, levels of the tumor marker CEA increased, went through a maximum (indicating tumor cell disintegration), and afterward decreased to background levels. In order to compare nodal metastases, extirpation of abscopal, tumor-bearing lymph nodes was performed before and after therapy. In contrast to the lymph node that was excised before RT, the one extirpated postirradiation showed lymphocytes invading tumor regions, increased infiltration of CD8⁺ T cells, an enhanced CD8⁺/FoxP3⁺ T-cell ratio, and more cytotoxic granules.¹⁷⁴ A correlation between clinical benefit and peripheral blood cell counts was demonstrated by Tang et al.: Patients showing abscopal responses upon radioimmunotherapy with Ipilimumab and RT of lung or liver metastases were analyzed for peripheral blood cell populations. Whereas high numbers of CD8⁺ T cells as well as high CD8⁺/CD4⁺ T-cell ratios correlated with increased clinical benefit, high CD4⁺ counts failed to do so.¹⁷⁵ Nakanishi et al. investigated cytokine serum levels of an abscopally responding HCC patient before and after RT and reported increases in IL-1 β , IL-4, and IL-6.¹⁷⁶ Finally, Teulings et al. performed immunological analyses of lymph node and brain metastases of a melanoma patient with abscopal tumor regression upon whole brain RT and described the presence of CD8⁺ T cells and antibody reactivity against melanocyte differentiation antigens expressed in the primary tumor, lymph node, and brain metastasis indicating T cell-mediated anti-melanoma activity.¹⁷³ In

summary, these reports provide clinical evidence for the concept of RT-mediated *in situ* vaccination and the specific importance of CD8⁺ T-cell responses as has already been discussed for the preclinical model systems. However, critical prospective evaluation is necessary in order to identify and characterize reliable molecular markers of RT-mediated abscopal immune effects which are of predictive value and can serve for monitoring purposes in the future.

13 | CLINICAL TRIALS AND RETROSPECTIVE ANALYSES WITH FOCUS ON ABSCOPAL RESPONSES

Although RT-mediated abscopal effects are rather rare phenomena, a number of case reports as well as common characteristics among them suggest that distinct factors contribute to their appearance. While early case reports were rather anecdotal stories of individual patients, recent studies present retrospective analyses of dozens of patients—a fact that could derive from an increased occurrence of abscopal effects due to enhanced implementation of combined modality RT (including checkpoint inhibition), sharpened interest in RT-induced abscopal effects, and/or more frequent detection as a result of improved imaging techniques. Nonetheless, systematic analyses of out-of-field responses are lacking, and existing studies mostly have limitations in cohort sizes and treatment groups, among others. The exploitation of abscopal effects as endogenous weapons in cancer treatment seems highly attractive, but the underlying mechanisms as well as the details of treatment regimens, including timing, dosing, and combination strategies, clearly need further investigation.

A retrospective analysis underlining the increased efficacy of RT plus checkpoint inhibition in melanoma patients with brain metastases showed that in comparison to patients without Ipilimumab after RT, patients treated with Ipilimumab displayed improved overall survival (5.3 vs 18.3 months).¹⁷⁷ However, some control group patients received RT plus Bortezomib which limits interpretation. Interestingly, patients undergoing stereotactic radiosurgery revealed better responses compared to patients with whole brain RT implying a certain advantage of RT regimens with higher doses. However, another retrospective analysis which directly compared stereotactic radiosurgery with and without additional Ipilimumab treatment in patients with melanoma brain metastases could not confirm this. The authors did also not observe differences depending on the time point of Ipilimumab administration.¹⁷⁸

A prospective clinical trial with patients with different metastatic cancers (stable or progressing on single-agent chemotherapy or hormonal therapy) undergoing RT plus GM-CSF treatment described an abscopal effect rate of 25% (11 of 41 patients)¹⁷⁹ (NCT02474186). Importantly, the authors reported significantly prolonged overall survival for patients with out-of-field responses compared to those with no abscopal response (median overall survival 8.33 months vs 20.98 months, hazard ratio 2.06). This trial did not include classic immunomonitoring but identified a low baseline neutrophil/lymphocyte ratio as predictor of RT-induced abscopal responses.

Yet, the mechanisms behind this remain elusive, and more in-depth analyses are needed in this regard. GM-CSF was chosen as an agent which can stimulate DC activation and cross-presentation. However, the authors argue that T-cell exhaustion might limit long-term anti-tumor immunity, and therefore suggest systematic trial approaches to evaluate immune checkpoint inhibition in combination with RT.¹⁷⁹ This is the focus of several ongoing clinical trials (Table 3). As an example, the KEYNOTE-001 trial investigated the efficacy and toxicity of Pembrolizumab treatment for patients with advanced NSCLC¹⁸⁰ (NCT01295827). A secondary analysis of this trial focused on the role of previous RT in the treatment history.¹⁸¹ Intriguingly, patients who had previously received RT showed longer progression-free survival upon Pembrolizumab treatment than patients who had not (4.4 months vs 2.2 months, hazard ratio 0.56), and previous RT was identified as an independent predictor in this regard. Similar results were obtained for the analysis of overall survival. Despite these encouraging observations, patients with prior RT also experienced more treatment-related toxicities. Nevertheless, the numbers of high-grade toxicities were similar between both groups. So, immune checkpoint blockade and RT apparently are powerful partners, but careful supervision of potential toxicities needs to be ensured. Accordingly, the results of other ongoing trials are eagerly awaited—not only with regard to treatment outcome and toxicity, but also in view of recommendations for treatment details, including timing and dosing, and the identification of suitable predicting and monitoring markers.

14 | THE PERSISTING GAP BETWEEN CLINICAL AND PRECLINICAL OBSERVATIONS

For decades, abscopal tumor regression has been an extremely rare and nearly mysterious phenomenon which was observed in very few patients, and only some but by far not all determinants of this effect have been elucidated by now. With the advent of immunotherapies, the view on RT-induced abscopal effects has gradually changed, but many clinicians still do not consider distant tumor regression in response to local RT as a reasonable therapeutic aim but rather as an incidental side benefit in a very limited set of patients. In contrast, our knowledge about the mediators in this context is largely based on preclinical animal models, where IR-dependent out-of-field tumor regression can be generated reproducibly with a given treatment. As discussed before, these preclinical models fundamentally contributed to our understanding of RT-stimulated abscopal responses. However, several aspects in this field are still not sufficiently addressed and other findings lack translational relevance. Most importantly, we are about to reach a point where it is no longer sufficient to simply demonstrate once more that abscopal effects can be generated in a given mouse model. Instead, the time is overdue to test novel therapeutics and treatment approaches for their efficacy in combination with RT to stimulate abscopal effects using clinically relevant treatment regimens in animal models which closely mimic the clinical situation in the patient.

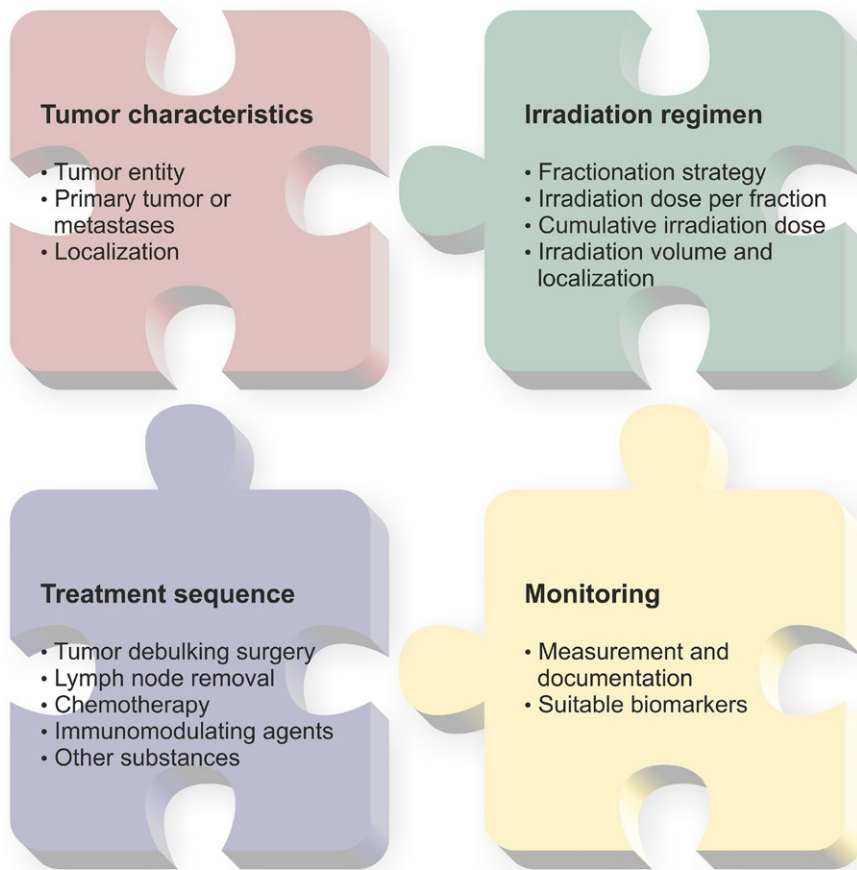


FIGURE 5 Major determinants influencing the occurrence and observation of radiotherapy-mediated abscopal effects [Colour figure can be viewed at wileyonlinelibrary.com]

Considering the RT regimen, there is an obvious discrepancy between preclinical findings and the clinical routine (Figure 5): Whereas about half of the preclinical reports employed high (ablative) single IR doses of up to 60 Gy for the activation of anti-tumor immunity, clinicians commonly use smaller single doses, hypofractionated treatments, or classically fractionated protocols, respectively, because higher doses bear the risk of increased side effects. Interestingly, most case reports of RT-induced abscopal responses are associated with palliative irradiation schemes where higher single doses were employed, and retrospective analyses also support the idea that increased single doses might be beneficial with regard to their immunostimulating potential.^{159,177} Hence, basic and clinical research may consider the question whether RT-induced abscopal effects are rarely seen in the clinical routine because of a preponderance of immunologically less effective irradiation regimens. In this regard, it should again be emphasized that local RT per se is by far not always immune activating, since various immune cell populations—including lymphocytes—are known to decline temporarily after standard RT treatments.^{36,37} Another issue regarding the RT regimen that needs to be discussed is the localization of the lesion that should be irradiated in order to stimulate abscopal responses when a patient presents with multiple nodules. At first sight, analysis of the available literature does not allow absolute conclusions. However, we could not find a single report in which abscopal regression of brain lesions was observed upon irradiation of tumors and/or metastases in peripheral organs (Figure 4, Table 2). Clearly, this needs further in-depth examination.

Second, the gap between preclinical findings and clinical experiences might be narrowed by fully exploiting the available animal models used for studies of RT-mediated stimulation of anti-tumor immunity. We found only two publications employing orthotopic syngeneic mouse models in this regard: Zeng and coworkers demonstrated a T cell-dependent impact on survival of RT in combination with PD-1 blockade in mice bearing intracranial murine glioblastomas,⁵⁹ and Young et al. reported a significant reduction in pancreatic tumor growth and an increase in T-cell infiltration upon RT in combination with TGF- β inhibition.⁵⁸ Astonishingly, truly every preclinical finding on RT-induced distant tumor growth inhibition in immunocompetent mice derives from heterotopic subcutaneous or intramuscular tumors and—at least to our knowledge—not a single orthotopic or autochthonous model has ever been employed to study immune-mediated abscopal effects of irradiation. This brings up the provocative question whether immune-mediated distant tumor regression can only be reproducibly instigated by RT in preclinical model systems with subcutaneous tumors but not with orthotopic tumor transplants, or autochthonous tumors, respectively. Although this is hopefully not the case, there is an obvious need to address this unresolved issue, since massive differences between growth characteristics and therapeutic responses of autochthonous, orthotopically, and heterotopically growing tumors are well-known.^{55,182}

Finally, the treatment sequence is another obvious difference between preclinical models reproducibly showing abscopal anti-tumor effects and the clinic where RT-induced distant tumor regression is

still quite rare (Figure 5): Reportedly, RT can generate *in situ* cancer vaccines, including antigen material and immunostimulating adjuvants, via the induction of immunogenic forms of cell death in the tumor. However, the effective priming of anti-tumor immune responses is also dependent on the influences of other therapeutic measures. As such, preceding surgery defines the amount of tumor mass that is irradiated as well as the presence or absence of lymph nodes which are needed for proper interactions between DCs and T cells. Whereas many patients undergo surgery of both their tumor and its draining lymph nodes before adjuvant RT, in preclinical settings RT is usually administered to the subcutaneous bulk tumor without any preceding surgery. Consequently, the antigenic load liberated from billions of dying and/or damaged tumor cells in the irradiated experimental tumors is magnitudes higher than in a clinical situation where only very few tumor cells remain after successful surgery. Hence, it would be interesting to elucidate whether the strength of inducible anti-tumor immunity and abscopal effects in preclinical model systems is dependent on the irradiated tumor's volume as has already been suggested by J. Vaage years ago.⁶¹ If this is the case, it would also explain why abscopal effects in the clinic are commonly observed in metastasized situations where surgery is no longer indicated. For clinical translation, this would imply that neoadjuvant concepts with several RT fractions prior to surgery might be considered where applicable. Furthermore, the impact of lymph nodes in this setting also needs to be evaluated in order to elucidate whether their surgical removal prior to RT decreases systemic anti-tumor immunity in patients owing to inefficient T-cell (cross-)priming. In this regard, it has already been reported that tumor-draining lymph nodes are indispensable for T-cell priming and tumor growth inhibition in response to RT.⁴⁵ Thus, we carefully propose to elucidate whether the time point of lymph node and bulk tumor removal relative to RT could be optimized in order to make abscopal tumor regression more likely. Besides, many cancer patients are co-treated by chemotherapy. Extensive work from the Kroemer group has elegantly demonstrated the hitherto unknown immunogenic effects of several chemotherapeutic agents,^{3,113,115,117,183} thus rendering them highly attractive for combination with RT in order to strengthen abscopal anti-tumor immunity. However, concurrent chemotherapy can also interfere with immune cell viability and function due to its well-known immunosuppressive side effects. Accordingly, clinically established treatment protocols should be (re-)evaluated since various chemotherapeutic regimens showed conflicting results with regard to posttherapy T-cell functionality in the clinic.^{184–187} This also raises the question whether clinical failure of chemotherapy and/or RT regimens can partly be attributed to the fact that immunogenic forms of cell death are either absent or insufficient to positively influence the clinical outcome in distinct patients, since immune cell recovery may be strongly impeded after local RT and especially after systemic chemotherapy. Hence, both RT and chemotherapy regimens may require immunological fine-tuning in order to fully exploit their immune activating potential. Finally, immunotherapy can help to unleash anti-tumor immune responses, but again correct timing appears crucial. So, complex interactions, mutual reinforcement and/or interference, as well as parallel effects raise the question of how to ideally combine

these therapeutic measures. Unfortunately, only limited data are available in this regard, and more studies focusing on optimizing the therapeutic sequence are needed.

Considering that the great advances in modern cancer therapy were only possible due to gradually improving the interplay between surgery, RT, chemotherapy, molecularly targeted therapy, and immunotherapy, it is already evident that this will by no means question the crucial importance of any of the involved disciplines but rather shed light on the issue of their optimal therapeutic interplay with the aim of achieving the best therapeutic outcome for every individual patient. We are convinced that our understanding of RT-induced abscopal effects will increase rendering their therapeutic potential exploitable on a regular basis if, on the one hand, preclinical researchers address the aforementioned clinically relevant problems in suitable animal models with clinically relevant treatment regimens and if, on the other hand, clinicians carefully reflect these findings in order to fine-tune and to reconsider the clinically established treatment protocols. Besides, bioinformatic approaches have been proposed as a means to improve our understanding of abscopal tumor regression by integrating preclinical and clinical data into mathematical models.^{189,190} However, due to the obvious limitations in biological and clinical information available at present, it is questionable whether these models will offer any reliable conclusions for the clinic at this early stage.

In spite of the aforementioned challenges, a systematic clinical evaluation of RT-induced abscopal effects has already begun, and clinical trials have been set up for metastatic neoplasms of different origins such as breast cancer (NCT01401062, NCT02538471), RCC (NCT02334709), melanoma (NCT02406183, NCT02562625), lymphoma (NCT02501473), and NSCLC (NCT02623595) (Table 3). These trials are important examples of efforts to narrow the gap between preclinical and clinical findings as hypofractionated RT regimens with three to five single doses of 6 to 12 Gy in combination with immunomodulatory drugs such as PD-1 or CTLA-4 blockade, TGF- β inhibition, tyrosine kinase inhibitors, and GM-CSF are employed. One remaining issue that will also be addressed in these trials is the identification of predictive and follow-up markers which will help to select suitable subgroups of patients and can serve for proper monitoring (Figure 5).

15 | CONCLUSIONS

Abscopal effects of RT have a long-standing history and have made their way through anecdotal case reports and preclinical evaluation. Despite still being rare observations in the radiotherapeutic routine, interests in their therapeutic application are constantly increasing—particularly since the clinical implementation of immunotherapeutic approaches, as meanwhile it is well acknowledged that systemic anti-tumor immune mechanisms are the underlying driving forces of RT-induced out-of-field lesion regression. We are convinced that narrowing the gap between clinical and preclinical experiences is achievable, and we want to encourage preclinical researchers to critically scrutinize their model systems and treatment regimens with respect to clinical relevance, as well as clinicians, in turn, to carefully

reconsider established treatment protocols in view of timing and dosing. The number of clinical trials which are currently being initiated clearly indicates that abscopal effects are no longer considered as experimental artifacts but instead as clinically exploitable phenomena which might broaden the scope of cancer therapy in the near future.

ACKNOWLEDGEMENTS

The authors thank Guido Drexler for helpful proofreading of the manuscript. Work in the Lauber lab is supported by funding of the BMBF (The German Consortium for Translational Cancer Research (DKTK) and ZissTrans 02NUK047C) and the EliteNetzwerk Bayern (Graduate program iTarget).

CONFLICT OF INTEREST

None.

REFERENCES

- Orth M, Lauber K, Niyazi M, et al. Current concepts in clinical radiation oncology. *Radiat Environ Biophys.* 2014;53:1-29.
- Withers HR. The four R's of radiotherapy. In: John TL, Howard A, eds. *Advances in radiation biology.* Elsevier; 1975:241-271. <http://www.sciencedirect.com/science/article/pii/B9780120354054500128?via%3Dihub>.
- Ghiringhelli F, Apetoh L, Tesniere A, et al. Activation of the NLRP3 inflammasome in dendritic cells induces IL-1beta-dependent adaptive immunity against tumors. *Nat Med.* 2009;15:1170-1178.
- Kroemer G, Galluzzi L, Kepp O, Zitvogel L. Immunogenic cell death in cancer therapy. *Annu Rev Immunol.* 2013;31:51-72.
- Galluzzi L, Buque A, Kepp O, Zitvogel L, Kroemer G. Immunogenic cell death in cancer and infectious disease. *Nat Rev Immunol.* 2017;17:97-111.
- Evans TC. X-ray treatment-its origin, birth and early history. Emil H. Grubbe. *Q Rev Biol.* 1951;26:223.
- Rontgen WC. On a new kind of rays. *Science.* 1896;3:227-231.
- del Regato JA. Albert Soiland and the early development of therapeutic radiology in the United States. *Int J Radiat Oncol Biol Phys.* 1983;9:243-253.
- Yeoh EE, Botten RJ, Butters J, Di Matteo AC, Holloway RH, Fowler J. Hypofractionated versus conventionally fractionated radiotherapy for prostate carcinoma: Final results of phase III randomized trial. *Int J Radiat Oncol Biol Phys.* 2011;81:1271-1278.
- Holloway CL, Panet-Raymond V, Olivetto I. Hypofractionation should be the new 'standard' for radiation therapy after breast conserving surgery. *Breast.* 2010;19:163-167.
- Haviland JS, Owen JR, Dewar JA, et al. The UK Standardisation of Breast Radiotherapy (START) trials of radiotherapy hypofractionation for treatment of early breast cancer: 10-year follow-up results of two randomised controlled trials. *Lancet Oncol.* 2013;14:1086-1094.
- Koulis TA, Phan T, Olivetto IA. Hypofractionated whole breast radiotherapy: Current perspectives. *Breast Cancer.* 2015;7:363-370.
- Vaidya JS, Wenz F, Bulsara M, et al. Risk-adapted targeted intraoperative radiotherapy versus whole-breast radiotherapy for breast cancer: 5-year results for local control and overall survival from the TARGIT-A randomised trial. *The Lancet.* 2014;383:603-613.
- Tran CL, Udani S, Holt A, Arnell T, Kumar R, Stamos MJ. Evaluation of safety of increased time interval between chemoradiation and resection for rectal cancer. *Am J Surg.* 2006;192:873-877.
- Krempien R, Roeder F. Intraoperative radiation therapy (IORT) in pancreatic cancer. *Radiat Oncol.* 2017;12:8.
- Roeder F, Krempien R. Intraoperative radiation therapy (IORT) in soft-tissue sarcoma. *Radiat Oncol.* 2017;12:20.
- McCulloch HD. On the analogy between spontaneous recoveries from cancer and the specific immunity induced by X ray irradiations of the lymphatic glands involved. *BMJ.* 1908;2:1146-1148.
- Segal G, Leblond C-P. Réaction d'alarme produite par l'action des rayons x sur l'abdomen chez le rat. *CR Soc Biol.* 1938;128:995.
- Mole RH. Whole body irradiation; radiobiology or medicine? *Br J Radiol.* 1953;26:234-241.
- Ehrlich P. Über den jetzigen Stand der Karzinomforschung. *Ned Tijdschr Geneesk.* 1909;53:273-290.
- Demaria S, Ng B, Devitt ML, et al. Ionizing radiation inhibition of distant untreated tumors (abscopal effect) is immune mediated. *Int J Radiat Oncol Biol Phys.* 2004;58:862-870.
- Younes E, Haas GP, Dezso B, et al. Local tumor irradiation augments the response to IL-2 therapy in a murine renal adenocarcinoma. *Cell Immunol.* 1995;165:243-251.
- Cameron RB, Spiess PJ, Rosenberg SA. Synergistic antitumor activity of tumor-infiltrating lymphocytes, interleukin 2, and local tumor irradiation. Studies on the mechanism of action. *J Exp Med.* 1990;171:249-263.
- Chakravarty PK, Alfieri A, Thomas EK, et al. Flt3-ligand administration after radiation therapy prolongs survival in a murine model of metastatic lung cancer. *Cancer Res.* 1999;59:6028-6032.
- Everse LA, Renes IB, Jurgenliemk-Schulz IM, et al. Local low-dose interleukin-2 induces systemic immunity when combined with radiotherapy of cancer. A pre-clinical study. *Int J Cancer.* 1997;72:1003-1007.
- Teicher BA, Ara G, Menon K, Schaub RG. In vivo studies with interleukin-12 alone and in combination with monocyte colony-stimulating factor and/or fractionated radiation treatment. *Int J Cancer.* 1996;65:80-84.
- Jurgenliemk-Schulz IM, Renes IB, Rutgers DH, et al. Anti-tumor effects of local irradiation in combination with peritumoral administration of low doses of recombinant interleukin-2 (rIL-2). *Radiat Oncol Invest.* 1997;5:54-61.
- Teitz-Tennenbaum S, Li Q, Rynkiewicz S, et al. Radiotherapy potentiates the therapeutic efficacy of intratumoral dendritic cell administration. *Cancer Res.* 2003;63:8466-8475.
- Chhikara M, Huang H, Vlachaki MT, et al. Enhanced therapeutic effect of HSV-tk+GCV gene therapy and ionizing radiation for prostate cancer. *Mol Ther.* 2001;3:536-542.
- Teicher BA, Ara G, Buxton D, Leonard J, Schaub RG. Optimal scheduling of interleukin-12 and fractionated radiation therapy in the murine Lewis lung carcinoma. *Radiat Oncol Invest.* 1998;6:71-80.
- Vlachaki MT, Chhikara M, Aguilar L, et al. Enhanced therapeutic effect of multiple injections of HSV-TK + GCV gene therapy in combination with ionizing radiation in a mouse mammary tumor model. *Int J Radiat Oncol Biol Phys.* 2001;51:1008-1017.
- Demaria S, Formenti SC. Role of T lymphocytes in tumor response to radiotherapy. *Front Oncol.* 2012;2:95.
- Lauber K, Ernst A, Orth M, Herrmann M, Belka C. Dying cell clearance and its impact on the outcome of tumor radiotherapy. *Front Oncol.* 2012;2:116.
- Matzinger P. The danger model: A renewed sense of self. *Science.* 2002;296:301-305.
- Trowell OA. The sensitivity of lymphocytes to ionising radiation. *J Pathol Bacteriol.* 1952;64:687-704.
- Hoppe RT, Fuks ZY, Strober S, Kaplan HS. The long term effects of radiation of T and B lymphocytes in the peripheral blood after regional irradiation. *Cancer.* 1977;40:2071-2078.
- Belka C, Ottinger H, Kreuzfelder E, et al. Impact of localized radiotherapy on blood immune cells counts and function in humans. *Radiother Oncol.* 1999;50:199-204.

38. Cao M-D, Chen Z-D, Xing Y. Gamma irradiation of human dendritic cells influences proliferation and cytokine profile of T cells in autologous mixed lymphocyte reaction. *Cell Biol Int*. 2004;28:223-228.
39. Lauber K, Brix N, Ernst A, et al. Targeting the heat shock response in combination with radiotherapy: Sensitizing cancer cells to irradiation-induced cell death and heating up their immunogenicity. *Cancer Lett*. 2015;368:209-229.
40. Peter C, Wesselborg S, Herrmann M, Lauber K. Dangerous attraction: Phagocyte recruitment and danger signals of apoptotic and necrotic cells. *Apoptosis*. 2010;15:1007-1028.
41. Burnette BC, Liang H, Lee Y, et al. The efficacy of radiotherapy relies upon induction of type I interferon-dependent innate and adaptive immunity. *Cancer Res*. 2011;71:2488-2496.
42. Deng L, Liang H, Xu M, et al. STING-dependent cytosolic DNA sensing promotes radiation-induced type I interferon-dependent antitumor immunity in immunogenic tumors. *Immunity*. 2014;41:843-852.
43. Cai X, Chiu YH, Chen ZJ. The cGAS-cGAMP-STING pathway of cytosolic DNA sensing and signaling. *Mol Cell*. 2014;54:289-296.
44. Lugade AA, Moran JP, Gerber SA, Rose RC, Frelinger JG, Lord EM. Local radiation therapy of B16 melanoma tumors increases the generation of tumor antigen-specific effector cells that traffic to the tumor. *J Immunol*. 2005;174:7516-7523.
45. Takeshima T, Chamoto K, Wakita D, et al. Local radiation therapy inhibits tumor growth through the generation of tumor-specific CTL: Its potentiation by combination with Th1 cell therapy. *Cancer Res*. 2010;70:2697-2706.
46. Lugade AA, Sorensen EW, Gerber SA, Moran JP, Frelinger JG, Lord EM. Radiation-induced IFN- production within the tumor microenvironment influences antitumor immunity. *J Immunol*. 2008;180:3132-3139.
47. Lim JY, Gerber SA, Murphy SP, Lord EM. Type I interferons induced by radiation therapy mediate recruitment and effector function of CD8(+) T cells. *Cancer Immunol Immunother*. 2014;63:259-271.
48. Schreiber RD, Old LJ, Smyth MJ. Cancer immunoediting: Integrating immunity's roles in cancer suppression and promotion. *Science*. 2011;331:1565-1570.
49. Filatenkov A, Baker J, Mueller AM, et al. Ablative tumor radiation can change the tumor immune cell microenvironment to induce durable complete remissions. *Clin Cancer Res*. 2015;21:3727-3739.
50. Reits EA, Hodge JW, Herberts CA, et al. Radiation modulates the peptide repertoire, enhances MHC class I expression, and induces successful antitumor immunotherapy. *J Exp Med*. 2006;203:1259-1271.
51. Chakraborty M, Abrams SI, Camphausen K, et al. Irradiation of tumor cells up-regulates Fas and enhances CTL lytic activity and CTL adoptive immunotherapy. *J Immunol*. 2003;170:6338-6347.
52. Formenti SC, Demaria S. Radiation therapy to convert the tumor into an in situ vaccine. *Int J Radiat Oncol Biol Phys*. 2012;84:879-880.
53. Reynders K, Illidge T, Siva S, Chang JY, De Ruyscher D. The abscopal effect of local radiotherapy: Using immunotherapy to make a rare event clinically relevant. *Cancer Treat Rev*. 2015;41:503-510.
54. Zitvogel L, Pitt JM, Dailhere R, Smyth MJ, Kroemer G. Mouse models in oncoimmunology. *Nat Rev Cancer*. 2016;16:759-773.
55. Talmadge JE, Singh RK, Fidler IJ, Raz A. Murine models to evaluate novel and conventional therapeutic strategies for cancer. *Am J Pathol*. 2007;170:793-804.
56. Raventos A. An abscopal effect of x-ray upon mouse spleen weight. *Radiat Res*. 1954;1:381-387.
57. Verhaegen F, Granton P, Tryggestad E. Small animal radiotherapy research platforms. *Phys Med Biol*. 2011;56:R55-R83.
58. Young KH, Newell P, Cottam B, et al. TGFbeta inhibition prior to hypofractionated radiation enhances efficacy in preclinical models. *Cancer Immunol Res*. 2014;2:1011-1022.
59. Zeng J, See AP, Phallen J, et al. Anti-PD-1 blockade and stereotactic radiation produce long-term survival in mice with intracranial gliomas. *Int J Radiat Oncol Biol Phys*. 2013;86:343-349.
60. Gerber SA, Sedlacek AL, Cron KR, Murphy SP, Frelinger JG, Lord EM. IFN-gamma mediates the antitumor effects of radiation therapy in a murine colon tumor. *Am J Pathol*. 2013;182:2345-2354.
61. Vaage J. Influence of tumor antigen on maintenance versus depression of tumor-specific immunity. *Cancer Res*. 1973;33:493-503.
62. Wogtom WH. The duration and extent of induced resistance toward tumor transplantation in mice. *J Exp Med*. 1912;16:629-643.
63. Stary G, Olive A, Radovic-Moreno AF, et al. VACCINES. A mucosal vaccine against *Chlamydia trachomatis* generates two waves of protective memory T cells. *Science*. 2015;348:aaa8205.
64. Matzinger P, Kamala T. Tissue-based class control: The other side of tolerance. *Nat Rev Immunol*. 2011;11:221-230.
65. Schrand B, Verma B, Levay A, et al. Radiation-induced enhancement of antitumor T-cell immunity by VEGF-targeted 4-1BB costimulation. *Cancer Res*. 2017;77:1310-1321.
66. Hodge JW, Guha C, Neefjes J, Gulley JL. Synergizing radiation therapy and immunotherapy for curing incurable cancers. Opportunities and challenges. *Oncology*. 2008;22:1064-1070; discussion 1075, 1080-1061, 1084.
67. Frey B, Rubner Y, Wunderlich R, et al. Induction of abscopal antitumor immunity and immunogenic tumor cell death by ionizing irradiation - Implications for cancer therapies. *Curr Med Chem*. 2012;19:1751-1764.
68. Fujita T, Timme TL, Tabata K, et al. Cooperative effects of adenoviral vector-mediated interleukin 12 gene therapy with radiotherapy in a preclinical model of metastatic prostate cancer. *Gene Ther*. 2007;14:227-236.
69. Yasuda K, Nirei T, Tsuno NH, Nagawa H, Kitayama J. Intratumoral injection of interleukin-2 augments the local and abscopal effects of radiotherapy in murine rectal cancer. *Cancer Sci*. 2011;102:1257-1263.
70. Hodge JW, Sharp HJ, Gameiro SR. Abscopal regression of antigen disparate tumors by antigen cascade after systemic tumor vaccination in combination with local tumor radiation. *Cancer Biother Radiopharm*. 2012;27:12-22.
71. Singh RK, Talmadge JE. The evolution of diversity within tumors and metastases. In: Kaiser HE, Nasir A, eds. *Selected Aspects of Cancer Progression: Metastasis, Apoptosis and Immune Response*. Dordrecht: Springer; 2008:59-90.
72. Schirmmacher V, Fogel M, Russmann E, Bosslet K, Altevogt P, Beck L. Antigenic variation in cancer metastasis: Immune escape versus immune control. *Cancer Metastasis Rev*. 1982;1:241-274.
73. Klein CA. Parallel progression of primary tumours and metastases. *Nat Rev Cancer*. 2009;9:302-312.
74. Vanpouille-Box C, Diamond JM, Pilonis KA, et al. TGFbeta is a master regulator of radiation therapy-induced antitumor immunity. *Cancer Res*. 2015;75:2232-2242.
75. Ma SY, Song H, Park JH, et al. Addition of anti-neu antibody to local irradiation can improve tumor-bearing BALB/c mouse survival through immune-mediated mechanisms. *Radiat Res*. 2015;183:271-278.
76. Rodriguez-Ruiz ME, Rodriguez I, Garasa S, et al. Abscopal effects of radiotherapy are enhanced by combined immunostimulatory mabs and are dependent on CD8 T cells and crosspriming. *Cancer Res*. 2016;76:5994-6005.
77. Demaria S, Kawashima N, Yang AM, et al. Immune-mediated inhibition of metastases after treatment with local radiation and CTLA-4 blockade in a mouse model of breast cancer. *Clin Cancer Res*. 2005;11:728-734.
78. Zhang H, Liu L, Yu D, et al. An in situ autologous tumor vaccination with combined radiation therapy and TLR9 agonist therapy. *PLoS ONE*. 2012;7:e38111.
79. Pilonis KA, Kawashima N, Yang AM, Babb JS, Formenti SC, Demaria S. Invariant natural killer T cells regulate breast cancer response to radiation and CTLA-4 blockade. *Clin Cancer Res*. 2009;15:597-606.
80. Lu L, Shen RN, Lin ZH, Aukerman SL, Ralph P, Broxmeyer HE. Anti-tumor effects of recombinant human macrophage

- colony-stimulating factor, alone or in combination with local irradiation, in mice inoculated with Lewis lung carcinoma cells. *Int J Cancer*. 1991;47:143-147.
81. Mule JJ, Shu S, Schwarz SL, Rosenberg SA. Adoptive immunotherapy of established pulmonary metastases with LAK cells and recombinant interleukin-2. *Science*. 1984;225:1487-1489.
 82. Rosenberg SA, Lotze MT, Muul LM, et al. A progress report on the treatment of 157 patients with advanced cancer using lymphokine-activated killer cells and interleukin-2 or high-dose interleukin-2 alone. *N Engl J Med*. 1987;316:889-897.
 83. Habets TH, Oth T, Houben AW, et al. Fractionated radiotherapy with 3 x 8 Gy induces systemic anti-tumour responses and abscopal tumour inhibition without modulating the humoral anti-tumour response. *PLoS ONE*. 2016;11:e0159515.
 84. Chakravarty PK, Guha C, Alfieri A, et al. Flt3L therapy following localized tumor irradiation generates long-term protective immune response in metastatic lung cancer: Its implication in designing a vaccination strategy. *Oncology*. 2006;70:245-254.
 85. Kanegasaki S, Matsushima K, Shiraishi K, Nakagawa K, Tsuchiya T. Macrophage inflammatory protein derivative ECI301 enhances the alarmin-associated abscopal benefits of tumor radiotherapy. *Cancer Res*. 2014;74:5070-5078.
 86. Shiraishi K, Ishiwata Y, Nakagawa K, et al. Enhancement of antitumor radiation efficacy and consistent induction of the abscopal effect in mice by ECI301, an active variant of macrophage inflammatory protein-1alpha. *Clin Cancer Res*. 2008;14:1159-1166.
 87. Nikitina EY, Gabrilovich DI. Combination of gamma-irradiation and dendritic cell administration induces a potent antitumor response in tumor-bearing mice: Approach to treatment of advanced stage cancer. *Int J Cancer*. 2001;94:825-833.
 88. Deng L, Liang H, Burnette B, et al. Irradiation and anti-PD-L1 treatment synergistically promote antitumor immunity in mice. *J Clin Invest*. 2014;124:687-695.
 89. Motz GT, Coukos G. Deciphering and reversing tumor immune suppression. *Immunity*. 2013;39:61-73.
 90. Pardoll DM. The blockade of immune checkpoints in cancer immunotherapy. *Nat Rev Cancer*. 2012;12:252-264.
 91. Scott AM, Wolchok JD, Old LJ. Antibody therapy of cancer. *Nat Rev Cancer*. 2012;12:278-287.
 92. Leach DR, Krummel MF, Allison JP. Enhancement of antitumor immunity by CTLA-4 blockade. *Science*. 1996;271:1734-1736.
 93. Hodi FS, O'Day SJ, McDermott DF, et al. Improved survival with ipilimumab in patients with metastatic melanoma. *N Engl J Med*. 2010;363:711-723.
 94. Park SS, Dong H, Liu X, et al. PD-1 restrains radiotherapy-induced abscopal effect. *Cancer Immunol Res*. 2015;3:610-619.
 95. Dewan MZ, Galloway AE, Kawashima N, et al. Fractionated but not single-dose radiotherapy induces an immune-mediated abscopal effect when combined with anti-CTLA-4 antibody. *Clin Cancer Res*. 2009;15:5379-5388.
 96. Wu L, Wu MO, De la Maza L, et al. Targeting the inhibitory receptor CTLA-4 on T cells increased abscopal effects in murine mesothelioma model. *Oncotarget*. 2015;6:12468-12480.
 97. Twyman-Saint Victor C, Rech AJ, Maitly A, et al. Radiation and dual checkpoint blockade activate non-redundant immune mechanisms in cancer. *Nature*. 2015;520:373-377.
 98. Bertrand A, Kostine M, Barnette T, Truchetet ME, Schaefferbeke T. Immune related adverse events associated with anti-CTLA-4 antibodies: Systematic review and meta-analysis. *BMC Med*. 2015;13:211.
 99. Larkin J, Chiarion-Sileni V, Gonzalez R, et al. Combined nivolumab and ipilimumab or monotherapy in untreated melanoma. *N Engl J Med*. 2015;373:23-34.
 100. Zitvogel L, Kroemer G. Targeting PD-1/PD-L1 interactions for cancer immunotherapy. *Oncoimmunology*. 2012;1:1223-1225.
 101. Mahoney KM, Freeman GJ, McDermott DF. The next immune-checkpoint inhibitors: PD-1/PD-L1 blockade in melanoma. *Clin Ther*. 2015;37:764-782.
 102. Chen H, Liakou CI, Kamat A, et al. Anti-CTLA-4 therapy results in higher CD4+ICOShi T cell frequency and IFN-gamma levels in both nonmalignant and malignant prostate tissues. *Proc Natl Acad Sci USA*. 2009;106:2729-2734.
 103. Brahmer JR, Tykodi SS, Chow LQ, et al. Safety and activity of anti-PD-L1 antibody in patients with advanced cancer. *N Engl J Med*. 2012;366:2455-2465.
 104. Hamid O, Robert C, Daud A, et al. Safety and tumor responses with lambrolizumab (anti-PD-1) in melanoma. *N Engl J Med*. 2013;369:134-144.
 105. Dovedi SJ, Cheadle EJ, Popple A, et al. Fractionated radiation therapy stimulates anti-tumor immunity mediated by both resident and infiltrating polyclonal T-cell populations when combined with PD1 blockade. *Clin Cancer Res*. 2017;in press.
 106. Dewan MZ, Vanpouille-Box C, Kawashima N, et al. Synergy of topical toll-like receptor 7 agonist with radiation and low-dose cyclophosphamide in a mouse model of cutaneous breast cancer. *Clin Cancer Res*. 2012;18:6668-6678.
 107. Tatsuta K, Tanaka S, Tajiri T, et al. Complete elimination of established neuroblastoma by synergistic action of gamma-irradiation and DCs treated with rSeV expressing interferon-beta gene. *Gene Ther*. 2009;16:240-251.
 108. Dranoff G, Jaffee E, Lazenby A, et al. Vaccination with irradiated tumor cells engineered to secrete murine granulocyte-macrophage colony-stimulating factor stimulates potent, specific, and long-lasting anti-tumor immunity. *Proc Natl Acad Sci USA*. 1993;90:3539-3543.
 109. Nishisaka N, Maini A, Kinoshita Y, et al. Immunotherapy for lung metastases of murine renal cell carcinoma: Synergy between radiation and cytokine-producing tumor vaccines. *J Immunother*. 1999;22:308-314.
 110. Lee Y, Auh SL, Wang Y, et al. Therapeutic effects of ablative radiation on local tumor require CD8+ T cells: Changing strategies for cancer treatment. *Blood*. 2009;114:589-595.
 111. Chakraborty M, Abrams SI, Coleman CN, Camphausen K, Schlom J, Hodge JW. External beam radiation of tumors alters phenotype of tumor cells to render them susceptible to vaccine-mediated T-cell killing. *Cancer Res*. 2004;64:4328-4337.
 112. Revesz L. Effect of tumour cells killed by x-rays upon the growth of admixed viable cells. *Nature*. 1956;178:1391-1392.
 113. Casares N, Pequignot MO, Tesniere A, et al. Caspase-dependent immunogenicity of doxorubicin-induced tumor cell death. *J Exp Med*. 2005;202:1691-1701.
 114. Ma Y, Adjemian S, Mattarollo SR, et al. Anticancer chemotherapy-induced intratumoral recruitment and differentiation of antigen-presenting cells. *Immunity*. 2013;38:729-741.
 115. Obeid M, Tesniere A, Ghiringhelli F, et al. Calreticulin exposure dictates the immunogenicity of cancer cell death. *Nat Med*. 2007;13:54-61.
 116. Schiavoni G, Sistigu A, Valentini M, et al. Cyclophosphamide synergizes with type I interferons through systemic dendritic cell reactivation and induction of immunogenic tumor apoptosis. *Cancer Res*. 2011;71:768-778.
 117. Apetoh L, Ghiringhelli F, Tesniere A, et al. Toll-like receptor 4-dependent contribution of the immune system to anticancer chemotherapy and radiotherapy. *Nat Med*. 2007;13:1050-1059.
 118. Strigari L, Mancuso M, Ubertaini V, et al. Abscopal effect of radiation therapy: Interplay between radiation dose and p53 status. *Int J Radiat Biol*. 2014;90:248-255.
 119. Schaefer D, Ratikan JA, Iwamoto KS, McBride WH. Maximizing tumor immunity with fractionated radiation. *Int J Radiat Oncol Biol Phys*. 2012;83:1306-1310.

120. Yoshimoto Y, Suzuki Y, Mimura K, et al. Radiotherapy-induced anti-tumor immunity contributes to the therapeutic efficacy of irradiation and can be augmented by CTLA-4 blockade in a mouse model. *PLoS ONE*. 2014;9:e92572.
121. Gambotto A, Dworacki G, Cicinnati V, et al. Immunogenicity of enhanced green fluorescent protein (EGFP) in BALB/c mice: Identification of an H2-Kd-restricted CTL epitope. *Gene Ther*. 2000;7:2036-2040.
122. Ansari AM, Ahmed AK, Matsangos AE, et al. Cellular GFP toxicity and immunogenicity: Potential confounders in in vivo cell tracking experiments. *Stem Cell Rev*. 2016;12:553-559.
123. Griffioen AW, Damen CA, Blijham GH, Groenewegen G. Tumor angiogenesis is accompanied by a decreased inflammatory response of tumor-associated endothelium. *Blood*. 1996;88:667-673.
124. Hellebrekers DM, Castermans K, Vire E, et al. Epigenetic regulation of tumor endothelial cell energy: Silencing of intercellular adhesion molecule-1 by histone modifications. *Cancer Res*. 2006;66:10770-10777.
125. Klug F, Prakash H, Huber PE, et al. Low-dose irradiation programs macrophage differentiation to an iNOS(+)/M1 phenotype that orchestrates effective T cell immunotherapy. *Cancer Cell*. 2013;24:589-602.
126. Gaipal US, Multhoff G, Scheithauer H, et al. Kill and spread the word: Stimulation of antitumor immune responses in the context of radiotherapy. *Immunotherapy*. 2014;6:597-610.
127. Camphausen K, Moses MA, Menard C, et al. Radiation abscopal antitumor effect is mediated through p53. *Cancer Res*. 2003;63:1990-1993.
128. Blanquicett C, Saif MW, Buchsbaum DJ, et al. Antitumor efficacy of capecitabine and celecoxib in irradiated and lead-shielded, contralateral human BxPC-3 pancreatic cancer xenografts: Clinical implications of abscopal effects. *Clin Cancer Res*. 2005;11:8773-8781.
129. de Araujo FV, O'Valle F, Lerma BA, et al. Human mesenchymal stem cells enhance the systemic effects of radiotherapy. *Oncotarget*. 2015;6:31164-31180.
130. Vaage J, Doroshow JH, DuBois TT. Radiation-induced changes in established tumor immunity. *Cancer Res*. 1974;34:129-137.
131. Camphausen K, Moses MA, Beecken WD, Khan MK, Folkman J, O'Reilly MS. Radiation therapy to a primary tumor accelerates metastatic growth in mice. *Cancer Res*. 2001;61:2207-2211.
132. Kaplan HS, Murphy ED. The effect of local roentgen irradiation on the biological behavior of a transplantable mouse carcinoma; increased frequency of pulmonary metastasis. *J Natl Cancer Inst*. 1949;9:407-413.
133. von Essen CF. Radiation enhancement of metastasis: A review. *Clin Exp Metas*. 1991;9:77-104.
134. Blanquicett C, Gillespie GY, Nabors LB, et al. Induction of thymidine phosphorylase in both irradiated and shielded, contralateral human U87MG glioma xenografts: Implications for a dual modality treatment using capecitabine and irradiation. *Mol Cancer Ther*. 2002;1:1139-1145.
135. Price JG, Idoyaga J, Salmon H, et al. CDKN1A regulates Langerhans cell survival and promotes Treg cell generation upon exposure to ionizing irradiation. *Nat Immunol*. 2015;16:1060-1068.
136. Cole WH. Spontaneous regression of cancer: The metabolic triumph of the host? *Ann NY Acad Sci*. 1974;230:111-141.
137. Coley WB. The treatment of malignant tumors by repeated inoculations of erysipelas. With a report of ten original cases. 1893. *Clin Orthop Relat Res*. 1991;3-11.
138. Perego D, Faravelli A. Unexpected consequence of splenectomy in composite lymphoma. The abscopal effect. *Haematologica*. 2000;85:211.
139. Nam SW, Han JY, Kim JI, et al. Spontaneous regression of a large hepatocellular carcinoma with skull metastasis. *J Gastroenterol Hepatol*. 2005;20:488-492.
140. Fairlamb DJ. Spontaneous regression of metastases of renal cancer: A report of two cases including the first recorded regression following irradiation of a dominant metastasis and review of the world literature. *Cancer*. 1981;47:2102-2106.
141. MacManus MP, Harte RJ, Stranex S. Spontaneous regression of metastatic renal cell carcinoma following palliative irradiation of the primary tumour. *Ir J Med Sci*. 1994;163:461-463.
142. Ohba K, Omagari K, Nakamura T, et al. Abscopal regression of hepatocellular carcinoma after radiotherapy for bone metastasis. *Gut*. 1998;43:575-577.
143. Lock M, Muinuddin A, Kocha WI, Dinniwel R, Rodrigues G, D'Souza D. Abscopal effects: Case report and emerging opportunities. *Cureus*. 2015;7:e344.
144. Wersall PJ, Blomgren H, Pisa P, Lax I, Kalkner KM, Svedman C. Regression of non-irradiated metastases after extracranial stereotactic radiotherapy in metastatic renal cell carcinoma. *Acta Oncol*. 2006;45:493-497.
145. Rees GJ. Abscopal regression in lymphoma: A mechanism in common with total body irradiation? *Clin Radiol*. 1981;32:475-480.
146. Desai IM, Braam PM, Kaal SE, Gerritsen WR, Oyen WJ, van der Graaf WT. Abscopal effect of radiotherapy in a patient with metastatic diffuse-type giant cell tumor. *Acta Oncol*. 2016;55:1510-1512.
147. Isobe Y, Aritaka N, Sasaki M, Oshimi K, Sugimoto K. Spontaneous regression of natural killer cell lymphoma. *J Clin Pathol*. 2009;62:647-650.
148. Tubin S. A case report on metastatic thyroid carcinoma: Radiation-induced bystander or abscopal effect? *J Cancer Sci Ther*. 2012;4.
149. Antoniadis J, Brady LW, Lightfoot DA. Lymphangiographic demonstration of the abscopal effect in patients with malignant lymphomas. *Int J Radiat Oncol Biol Phys*. 1977;2:141-147.
150. Beck KE, Blansfield JA, Tran KQ, et al. Enterocolitis in patients with cancer after antibody blockade of cytotoxic T-lymphocyte-associated antigen 4. *J Clin Oncol*. 2006;24:2283-2289.
151. Patel SP, Woodman SE. Profile of ipilimumab and its role in the treatment of metastatic melanoma. *Drug Des Devel Ther*. 2011;5:489-495.
152. Heinzerling L, Goldinger SM. A review of serious adverse effects under treatment with checkpoint inhibitors. *Curr Opin Oncol*. 2017;29:136-144.
153. Formenti SC, Demaria S. Combining radiotherapy and cancer immunotherapy: A paradigm shift. *J Natl Cancer Inst*. 2013;105:256-265.
154. Demaria S, Coleman CN, Formenti SC. Radiotherapy: Changing the game in immunotherapy. *Trends Cancer*. 2016;2:286-294.
155. Weichselbaum RR, Liang H, Deng L, Fu YX. Radiotherapy and immunotherapy: A beneficial liaison? *Nat Rev Clin Oncol*. 2017;14:365-379.
156. Hodi FS, Chesney J, Pavlick AC, et al. Combined nivolumab and ipilimumab versus ipilimumab alone in patients with advanced melanoma: 2-year overall survival outcomes in a multicentre, randomised, controlled, phase 2 trial. *Lancet Oncol*. 2016;17:1558-1568.
157. Grimaldi AM, Simeone E, Giannarelli D, et al. Abscopal effects of radiotherapy on advanced melanoma patients who progressed after ipilimumab immunotherapy. *Oncoimmunology*. 2014;3:e28780.
158. Hiniker SM, Chen DS, Knox SJ. Abscopal effect in a patient with melanoma. *N Engl J Med*. 2012;366:2035; author reply 2035-2036.
159. Postow MA, Callahan MK, Barker CA, et al. Immunologic correlates of the abscopal effect in a patient with melanoma. *N Engl J Med*. 2012;366:925-931.
160. Hiniker SM, Chen DS, Reddy S, et al. A systemic complete response of metastatic melanoma to local radiation and immunotherapy. *Transl Oncol*. 2012;5:404-407.
161. Stamell EF, Wolchok JD, Gnjatich S, Lee NY, Brownell I. The abscopal effect associated with a systemic anti-melanoma immune response. *Int J Radiat Oncol Biol Phys*. 2013;85:293-295.
162. Okwan-Duodu D, Pollack BP, Lawson D, Khan MK. Role of radiation therapy as immune activator in the era of modern immunotherapy for metastatic malignant melanoma. *Am J Clin Oncol*. 2015;38:119-125.

163. Thallinger C, Prager G, Ringl H, Zielinski C. [Abscopal effect in the treatment of malignant melanoma]. *Hautarzt*. 2015;66:545-548.
164. Barker CA, Postow MA. Combinations of radiation therapy and immunotherapy for melanoma: A review of clinical outcomes. *Int J Radiat Oncol Biol Phys*. 2014;88:986-997.
165. Chandra RA, Wilhite TJ, Balboni TA, et al. A systematic evaluation of abscopal responses following radiotherapy in patients with metastatic melanoma treated with ipilimumab. *Oncoimmunology*. 2015;4:e1046028.
166. Hiniker SM, Reddy SA, Maecker HT, et al. A prospective clinical trial combining radiation therapy with systemic immunotherapy in metastatic melanoma. *Int J Radiat Oncol Biol Phys*. 2016;96:578-588.
167. Kwon ED, Drake CG, Scher HI, et al. Ipilimumab versus placebo after radiotherapy in patients with metastatic castration-resistant prostate cancer that had progressed after docetaxel chemotherapy (CA184-043): A multicentre, randomised, double-blind, phase 3 trial. *Lancet Oncol*. 2014;15:700-712.
168. Lawrence MS, Stojanov P, Polak P, et al. Mutational heterogeneity in cancer and the search for new cancer-associated genes. *Nature*. 2013;499:214-218.
169. Melis C, Rogiers A, Bechter O, van den Oord JJ. Molecular genetic and immunotherapeutic targets in metastatic melanoma. *Virchows Arch*. 2017; in press.
170. Hua C, Boussemer L, Mateus C, et al. Association of vitiligo with tumor response in patients with metastatic melanoma treated with pembrolizumab. *JAMA Dermatol*. 2016;152:45-51.
171. Nobler MP. The abscopal effect in malignant lymphoma and its relationship to lymphocyte circulation. *Radiology*. 1969;93:410-412.
172. Lome LG, Navani S, Aral IM. Spontaneous regression of pulmonary metastases from transitional cell carcinoma of the bladder. *Cancer*. 1970;26:415-418.
173. Teulings HE, Tjin EP, Willemsen KJ, et al. Radiation-induced melanoma-associated leucoderma, systemic antimelanoma immunity and disease-free survival in a patient with advanced-stage melanoma: A case report and immunological analysis. *Br J Dermatol*. 2013;168:733-738.
174. Golden EB, Demaria S, Schiff PB, Chachoua A, Formenti SC. An abscopal response to radiation and ipilimumab in a patient with metastatic non-small cell lung cancer. *Cancer Immunol Res*. 2013;1:365-372.
175. Tang C, Welsh JW, de Groot P, et al. Ipilimumab with stereotactic ablative radiation therapy: Phase I results and immunologic correlates from peripheral T cells. *Clin Cancer Res*. 2017;23:1388-1396.
176. Nakanishi M, Chuma M, Hige S, Asaka M. Abscopal effect on hepatocellular carcinoma. *Am J Gastroenterol*. 2008;103:1320-1321.
177. Silk AW, Bassetti MF, West BT, Tsien CI, Lao CD. Ipilimumab and radiation therapy for melanoma brain metastases. *Cancer Med*. 2013;2:899-906.
178. Mathew M, Tam M, Ott PA, et al. Ipilimumab in melanoma with limited brain metastases treated with stereotactic radiosurgery. *Melanoma Res*. 2013;23:191-195.
179. Golden EB, Chhabra A, Chachoua A, et al. Local radiotherapy and granulocyte-macrophage colony-stimulating factor to generate abscopal responses in patients with metastatic solid tumours: A proof-of-principle trial. *Lancet Oncol*. 2015;16:795-803.
180. Garon EB, Rizvi NA, Hui R, et al. Pembrolizumab for the treatment of non-small-cell lung cancer. *N Engl J Med*. 2015;372:2018-2028.
181. Shaverdian N, Lisberg AE, Bornazyan K, et al. Previous radiotherapy and the clinical activity and toxicity of pembrolizumab in the treatment of non-small-cell lung cancer: A secondary analysis of the KEYNOTE-001 phase 1 trial. *Lancet Oncol*. 2017;18:895-903.
182. Killian JJ, Radinsky R, Fidler IJ. Orthotopic models are necessary to predict therapy of transplantable tumors in mice. *Cancer Metastasis Rev*. 1998;17:279-284.
183. Ma Y, Kepp O, Ghiringhelli F, et al. Chemotherapy and radiotherapy: Cryptic anticancer vaccines. *Semin Immunol*. 2010;22:113-124.
184. Onyema OO, Decoster L, Njemini R, et al. Chemotherapy-induced changes and immunosenescence of CD8+ T-cells in patients with breast cancer. *Anticancer Res*. 2015;35:1481-1489.
185. Fagnoni FF, Lozza L, Zibera C, et al. T-cell dynamics after high-dose chemotherapy in adults: Elucidation of the elusive CD8+ subset reveals multiple homeostatic T-cell compartments with distinct implications for immune competence. *Immunology*. 2002;106:27-37.
186. McCoy MJ, Lake RA, van der Most RG, Dick IM, Nowak AK. Post-chemotherapy T-cell recovery is a marker of improved survival in patients with advanced thoracic malignancies. *Br J Cancer*. 2012;107:1107-1115.
187. Maeda K, Hazama S, Tokuno K, et al. Impact of chemotherapy for colorectal cancer on regulatory T-cells and tumor immunity. *Anticancer Res*. 2011;31:4569-4574.
188. Kiess AP, Wolchok JD, Barker CA, et al. Stereotactic radiosurgery for melanoma brain metastases in patients receiving ipilimumab: Safety profile and efficacy of combined treatment. *Int J Radiat Oncol Biol Phys*. 2015;92:368-375.
189. Serre R, Benzekry S, Padovani L, et al. Mathematical modeling of cancer immunotherapy and its synergy with radiotherapy. *Cancer Res*. 2016;76:4931-4940.
190. Poleszczuk JT, Luddy KA, Prokopiou S, et al. Abscopal benefits of localized radiotherapy depend on activated T-cell trafficking and distribution between metastatic lesions. *Cancer Res*. 2016;76:1009-1018.
191. Akutsu Y, Matsubara H, Urashima T, et al. Combination of direct intratumoral administration of dendritic cells and irradiation induces strong systemic antitumor effect mediated by GRP94/gp96 against squamous cell carcinoma in mice. *Int J Oncol*. 2007;31:509-515.
192. Yagi M, Arentsen L, Shanley RM, et al. A dual-radioisotope hybrid whole-body micro-positron emission tomography/computed tomography system reveals functional heterogeneity and early local and systemic changes following targeted radiation to the murine caudal skeleton. *Calcif Tissue Int*. 2014;94:544-552.
193. Hao Y, Yasmin-Karim S, Moreau M, Sinha N, Sajjo E, Ngwa W. Enhancing radiotherapy for lung cancer using immunoadjuvants delivered in situ from new design radiotherapy biomaterials: A preclinical study. *Phys Med Biol*. 2016;61:N697-N707.
194. Pilonis KA, Demaria S. Research highlights: Immunotherapy. *Immunotherapy*. 2009;1:733-736.
195. Vanpouille-Box C, Pilonis KA, Wennerberg E, Formenti SC, Demaria S. In situ vaccination by radiotherapy to improve responses to anti-CTLA-4 treatment. *Vaccine*. 2015;33:7415-7422.
196. Kingsley DP. An interesting case of possible abscopal effect in malignant melanoma. *Br J Radiol*. 1975;48:863-866.
197. Braun MP, Maziarz RT. Abscopal depression of G-CSF mobilized peripheral stem cells. *Bone Marrow Transplant*. 1994;14:1005-1007.
198. Robin HI, AuBuchon J, Varanasi VR, Weinstein AB. The abscopal effect: Demonstration in lymphomatous involvement of kidneys. *Med Pediatr Oncol*. 1981;9:473-476.
199. Michot JM, Mazeran R, Derclé L, et al. Abscopal effect in a Hodgkin lymphoma patient treated by an anti-programmed death 1 antibody. *Eur J Cancer*. 2016;66:91-94.
200. Sham RL. The abscopal effect and chronic lymphocytic leukemia. *Am J Med*. 1995;98:307-308.
201. Lakshmanagowda PB, Viswanath L, Thimmaiah N, Dasappa L, Supe SS, Kallur P. Abscopal effect in a patient with chronic lymphocytic leukemia during radiation therapy: A case report. *Cases J*. 2009;2:204.
202. Orton A, Wright J, Buchmann L, Randall L, Hitchcock YJ. A case of complete abscopal response in high-grade pleiomorphic sarcoma treated with radiotherapy alone. *Cureus*. 2016;8:e821.
203. Takaya M, Niibe Y, Tsunoda S, et al. Abscopal effect of radiation on toruliform para-aortic lymph node metastases of advanced uterine cervical carcinoma—a case report. *Anticancer Res*. 2007;27:499-503.

204. Sato H, Suzuki Y, Yoshimoto Y, et al. An abscopal effect in a case of concomitant treatment of locally and peritoneally recurrent gastric cancer using adoptive T-cell immunotherapy and radiotherapy. *Clin Case Rep.* 2017;5:380-384.
205. Okuma K, Yamashita H, Niibe Y, Hayakawa K, Nakagawa K. Abscopal effect of radiation on lung metastases of hepatocellular carcinoma: A case report. *J Med Case Rep.* 2011;5:111.
206. Rees GJ, Ross CM. Abscopal regression following radiotherapy for adenocarcinoma. *Br J Radiol.* 1983;56:63-66.
207. Siva S, Callahan J, MacManus MP, Martin O, Hicks RJ, Ball DL. Abscopal [corrected] effects after conventional and stereotactic lung irradiation of non-small-cell lung cancer. *J Thorac Oncol.* 2013;8:e71-e72.
208. Ehlers G, Fridman M. Abscopal effect of radiation in papillary adenocarcinoma. *Br J Radiol.* 1973;46:220-222.

How to cite this article: Brix N, Tiefenthaller A, Anders H, Belka C, Lauber K. Abscopal, immunological effects of radiotherapy: Narrowing the gap between clinical and preclinical experiences. *Immunol Rev.* 2017;280:249–279. <https://doi.org/10.1111/imr.12573>