

Washington University School of Medicine

**Digital Commons@Becker**

---

Open Access Publications

---

2018

**Previous failed hip arthroscopy negatively impacts early patient-reported outcomes of the periacetabular osteotomy: An ANCHOR matched cohort study**

Eduardo N. Novais

Benjamin R. Coobs

Jeff J. Nepple

John C. Clohisy

Paul E. Beaulé

*See next page for additional authors*

Follow this and additional works at: [https://digitalcommons.wustl.edu/open\\_access\\_pubs](https://digitalcommons.wustl.edu/open_access_pubs)

---

---

**Authors**

*Eduardo N. Novais, Benjamin R. Coobs, Jeff J. Nepple, John C. Clohisy, Paul E. Beaulé, Yong-Jo Kim, Michael B. Millis, David A. Podeszwa, Perry L. Schoenecker, Rafael J. Sierra, Ernest L. Sink, Daniel J. Sucato, Robert T. Trousdale, and Ira Zaltz*

---

# Previous failed hip arthroscopy negatively impacts early patient-reported outcomes of the periacetabular osteotomy: an ANCHOR Matched Cohort Study

Eduardo N. Novais<sup>1</sup>, Benjamin R. Coobs<sup>2</sup>, Jeff J. Nepple<sup>3</sup>,  
ANCHOR Study Group<sup>3</sup> and John C. Clohisy<sup>3\*</sup>

<sup>1</sup>Department of Orthopedic Surgery, Boston Children's Hospital, 300 Longwood Ave., Boston, MA 02115, USA,

<sup>2</sup>Department of Orthopedic Surgery, Virginia Tech Carilion School of Medicine, 2331 Franklin Rd. SW Roanoke, VA 24014, USA and

<sup>3</sup>Department of Orthopedic Surgery, Washington University in St. Louis, 660 South Euclid Ave, Campus Box 8233, St Louis, MO 63110, USA

\*Correspondence to: J. C. Clohisy. E-mail: clohisyj@wudosis.wustl.edu

Investigation performed at Department of Orthopaedic Surgery, Washington University St. Louis.

Submitted 5 January 2018; Revised 31 May 2018; revised version accepted 1 August 2018

## ABSTRACT

Surgical treatment of hip dysplasia by arthroscopic procedures remains controversial. The aim of this study was to compare outcomes of periacetabular osteotomy (PAO) after failed hip arthroscopy to a matched-control group without previous arthroscopy. Fifty-two patients who underwent PAO after failed hip arthroscopy were matched to two subjects without arthroscopy based on age, sex, BMI and radiographic severity. Pre- and post-operative patient self-reported outcomes and radiographic parameters were compared at minimum 1-year follow-up. Prior to PAO the failed hip arthroscopy group exhibited lower modified Harris hip scores (mHHS; 57 versus 62;  $P = 0.04$ ), WOMAC (59.9 versus 66.3;  $P = 0.08$ ), UCLA activity (5 versus 7;  $P = 0.001$ ) and SF12 physical scores (34 versus 40;  $P = 0.001$ ) compared with the non-arthroscopy group. At minimum 1-year follow-up, the failed hip arthroscopy group had lower mHHS (78 versus 87;  $P = 0.003$ ); worse WOMAC (84.1 versus 90.8;  $P = 0.02$ ) and SF-12 physical component (46 versus 50;  $P = 0.02$ ) with similar UCLA (7 versus 8;  $P = 0.21$ ) compared with the non-arthroscopy group. No differences were detected regarding radiographic parameters or in patient-reported outcomes from preoperative to follow up. PAO achieved the desired radiographic correction and significant improvement in pain and function after a failed previous hip arthroscopy, however, the patient-reported outcomes were inferior to those of PAO without previous failed arthroscopy.

## INTRODUCTION

Acetabular dysplasia is characterized by inadequate femoral head coverage by the acetabulum, which results in abnormal mechanics and potential labral and cartilage damage [1, 2]. Isolated hip arthroscopy has been suggested for the treatment of labral pathology, FAI and capsular laxity in the setting of mild hip dysplasia [3–12]. However, because previous studies reported conflicting results, the role of an isolated hip arthroscopy for the treatment of hip dysplasia remains controversial [3–11, 13–21]. While few studies [3–5, 7, 9, 12] report short-term improvement in pain and function after hip arthroscopy for patients with borderline dysplasia, others report inferior results and high failure

rates (around 30%) in patients with mild-to-moderate dysplasia [6, 7, 10, 20] with an additional risk of potential iatrogenic instability and rapid progression of osteoarthritis [18, 20, 22–24].

A recent prospective study investigating hip arthroscopy failures suggested that amongst patients who did not improve with hip arthroscopy, 24% were diagnosed with acetabular dysplasia and underwent a periacetabular osteotomy (PAO) for definitive treatment [21]. PAO is a well-recognized treatment for symptomatic acetabular dysplasia with supportive literature regarding its safety [25] and good clinical outcomes relative to improved symptoms, function and preservation of the native hip at the

intermediate [26] and over 20 [27] and 30 years [28] after surgery. However, there is limited literature [15, 16] reporting outcomes of patients undergoing PAO after a previous failed hip arthroscopy.

The purpose of this study was to compare patient-reported outcomes and radiographic correction in a cohort of patients with symptomatic acetabular dysplasia who underwent PAO after failed hip arthroscopy to a matched control cohort of patients who underwent PAO as an index procedure without previous hip arthroscopy.

## MATERIALS AND METHODS

After approval by the institutional review board at the participating institutions, a query of the Academic Network for Conservational Hip Outcomes Research (ANCHOR) database identified 971 patients who underwent a PAO over a 4-year period. ANCHOR is a multicenter research group that has collected prospective longitudinal data for hip preservation surgeries including PAO. Inclusion criteria for the study group were patients who underwent PAO for the treatment of residual or persistent pain after an ipsilateral hip arthroscopy and the diagnosis of acetabular dysplasia associated with developmental dysplasia of the hip (DDH) based on lateral center-edge angle (LCEA) of Wiberg [29] lower than 25° or acetabular roof inclination of Tönnis [30] greater than 10°. Exclusion criteria were diagnosis different than DDH and previous open surgeries. Eight hundred and eighty-five patients underwent PAO for acetabular dysplasia associated with DDH and 147 patients underwent previous surgery. Our final study cohort consisted of 52 patients who underwent PAO for the treatment of symptomatic acetabular dysplasia after previous failed hip arthroscopy (Fig. 1).

The ANCHOR database was searched for control subjects who underwent PAO as an index procedure with the following inclusion criteria: (i) diagnosis of acetabular dysplasia due to DDH; (ii) no previous hip surgery; (iii) no concurrent femoral osteotomy procedure. Each patient with PAO after failed hip arthroscopy was matched with two control subjects (no previous arthroscopy) using a modified nearest neighbor approach based on sex, age, BMI and LCEA. Subjects in the previous arthroscopy group were stratified in blocks based on sex. Controls were assigned to an appropriate block and control subjects closest in age ( $\pm 2$  years) and body mass index (BMI; kg/m<sup>2</sup>;  $\pm 5$  units) were matched together with each patient in the previous arthroscopy group. Finally, two control subjects with the closest LCEA to the study patient were selected if more than two potential subjects were identified. Minimum follow-up was 12 months and was achieved for all subjects enrolled in the study. For patients in the failed

hip arthroscopy group, PAO was performed after a mean of 29.6 months ( $\pm 21.4$  months) following the initial hip arthroscopy procedure.

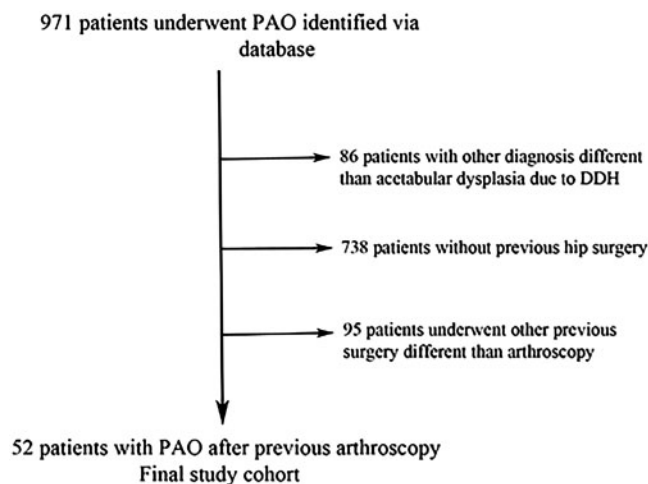
Surgery was performed according to a previous described technique [31, 32]. At the time of PAO 25 (48%) patients in the previous arthroscopy group underwent an arthrotomy and 15 (33%) underwent a concomitant arthroscopy. Femoral head neck osteochondroplasty was performed in 29 (56%) patients, the labrum was repaired in 7 (14%) patients and debrided in 9 (17%) patients. In the non-previous arthroscopy group, 55 (53%) patients underwent an open arthrotomy at the time of PAO, while 25 (24%) patients underwent a concomitant hip arthroscopy. Femoral head neck osteochondroplasty was performed in 59 (57%) patients; labral repair in 9 (9%) and labral debridement in 10 (10%) patients.

Clinical outcome scores were prospectively collected before surgery and at minimum 1-year follow-up using the modified Harris hip score (mHHS) [33], the WOMAC [34], the 12-Item Short-form healthy survey (SF-12 including physical and mental components) [35] and the UCLA activity scores [36]. At latest follow-up, patients were considered to have an excellent mHHS outcome if the scores were higher than 90 points [37].

Anteroposterior (AP) pelvic and false profile [38] radiographs were assessed preoperative and at most recent follow-up visit by measurements of the LCEA of Wiberg [29], acetabular index of Tönnis [30] and anterior center-edge angle (ACEA) [38]. Osteoarthritis was classified on AP pelvic radiographs using the Tönnis classification [30]. Radiographs were assessed by the same orthopedic surgeon not involved in the clinical care of the patients. The intra-class correlation coefficients (ICCs) for intra-observer variability in a radiographic performed study of this same patient group was reported as being between 0.82 and 1.0, and the inter-observer reliability for LCEA between 0.42 and 0.92, Tönnis angle between 0.45 and 0.85, and ACEA from 0.55 to 0.88 [39].

## Statistical analysis

Patient characteristics were summarized using mean and standard deviation for continuous characteristics and by frequency and percent for categorical characteristics. Patient-reported outcomes and radiographic measurements were summarized and compared across treatment groups at baseline and at most-recent follow-up. Continuous measurements were compared at baseline and follow-up using Student's *t*-tests while binary characteristics were compared using a  $\chi^2$  test and ordinal characteristics using the Cochran–Armitage test for trends. Change in patient-reported outcomes and radiographic measurements was



**Fig. 1.** Schematic demonstration of the study group sample.

analyzed across treatment groups using linear mixed model analysis. Modeling controlled for the matched design of the study and for repeated measures on the same subject. All tests were two-sided and  $P$ -values less than 0.05 were considered significant.

## RESULTS

There were a total of 52 patients in the previous failed arthroscopy group who were matched to 104 patients treated with PAO without previous arthroscopy. Mean patient age at time of PAO in each group was 25 years ( $P = 0.93$ ) on average at PAO, with average BMI of 24 ( $\pm 4$ ) ( $P = 0.74$ ). Each cohort was 6% male ( $P = 1.00$ ) (Table I). The arthroscopy cohort was followed for a median of 1.8 years (range 1–5 years) and the non-arthroscopy cohort for a median of 2.1 years (range 1–7 years) ( $P = 0.01$ ).

At baseline before PAO the patients who underwent PAO after failed hip arthroscopy exhibited worse pain, function, and quality of life and lower level of physical activity as measured by lower mHHS (57 versus 62;  $P = 0.04$ ), lower WOMAC pain scores (53.5 versus 60.5;  $P = 0.04$ ), lower SF12 physical component scores (34 versus 40;  $P = 0.001$ ) and lower UCLA activity scores (5 versus 7;  $P = 0.001$ ) compared with the non-previous arthroscopy cohort (Table I). At the most recent follow-up, patients in the previous failed arthroscopy group had persistent lower mHHS (78 versus 87;  $P = 0.003$ ) including a lower proportion of patients with an excellent (mHHS > 90) mHHS outcome (31% versus 54%;  $P = 0.01$ ). The WOMAC pain scores ( $P = 0.01$ ) and the SF12 physical component scores were also lower ( $P = 0.02$ ) in the previous failed arthroscopy group although no difference was observed for the UCLA activities

scores ( $P = 0.21$ ) (Table II). No difference was detected across the two groups with respect to the magnitude of change in the patient-reported outcomes from preoperative to most-recent follow-up (Table III).

Radiographic measurements obtained before PAO showed that patients in each cohort had comparable severity of acetabular dysplasia as assessed by the LCEA ( $P = 0.68$ ), AI ( $P = 0.17$ ) and ACEA ( $P = 0.11$ ) as well as severity of hip osteoarthritis grade ( $P = 0.35$ ) (Table I). At most-recent follow-up, LCEA ( $P = 0.86$ ) and AI ( $P = 0.95$ ) were comparable across treatment groups; however, average ACEA was slightly higher in the previous failed arthroscopy group (36 versus 32;  $P = 0.03$ ) compared with the non-previous arthroscopy group (Table II). No difference in the degree of correction of acetabular dysplasia, assessed by change in the radiographic measurements were observed between the two groups. (Table III).

## DISCUSSION

This study shows that PAO achieved pain, function and radiographic improvement in patients with failed hip arthroscopy with no differences across groups with respect to change in radiographic measures or in patient-reported outcomes from preoperative to follow-up. Although the improvement observed after failed hip arthroscopy supports PAO as a salvage operation, patients in the failed arthroscopy group had worse hip scores assessed by the mHHS, WOMAC, UCLA and SF-12 PCS at the most recent follow-up.

The of hip arthroscopy in the setting of acetabular dysplasia remains controversial with conflicting results regarding patient-reported outcomes improvement and proportion of surgical failure [3–11, 13–21]. A recent systematic review

**Table I. Baseline characteristics by cohort**

Characteristic	Arthroscopy (n = 52)	No arthroscopy (n = 104)	P
	Mean ± SD	Mean ± SD	
<b>Demographics</b>			
Age	24.6 ± 7.29	24.8 ± 7.80	0.93
Gender	3 (6%)	6 (6%)	1.00
BMI	23.9 ± 4.44	23.6 ± 3.82	0.75
<b>Preoperative measurements</b>			
<i>Radiographic measurements</i>			
Tönnis classification			
0	0 (0%)	1 (1%)	0.11
1	35 (67%)	56 (54%)	
2	17 (33%)	41 (40%)	
3	0 (0%)	4 (4%)	
4	0 (0%)	1 (1%)	
LCEA (°)	15.6 ± 8.77	15.0 ± 6.66	0.68
LCEA/DDH category			
Mild (>15)	47 (90%)	93 (90%)	1.00
Moderate (5–15)	0 (0%)	0 (0%)	
Severe (<5)	5 (10%)	10 (10%)	
ACEA (°)	16.3 ± 9.51	13.5 ± 9.29	0.11
Acetabular index	15.8 ± 5.74	17.2 ± 6.42	0.17
<i>Patient-reported outcomes</i>			
Modified Harris hip score	57.0 ± 15.64	62.3 ± 13.81	0.04
UCLA activity score	5.1 ± 2.57	6.7 ± 2.68	0.001
WOMAC pain	53.5 ± 20.21	60.5 ± 19.78	0.04
WOMAC stiffness	57.0 ± 26.13	58.5 ± 23.84	0.72
WOMAC physical	61.1 ± 23.47	68.6 ± 18.92	0.06
WOMAC total	59.9 ± 21.67	66.3 ± 18.35	0.08
SF12 PCS	34.2 ± 9.99	40.1 ± 10.52	0.001
SF12 MCS	52.2 ± 10.62	52.0 ± 9.73	0.92

suggested an overall high rate of re-operation and conversion to THA [11]. Arthroscopic treatment in the setting of acetabular dysplasia achieved inferior results and had higher failure when compared with hip arthroscopy for FAI without

dysplasia. [7] Fukui *et al.* [6] described 5/28 patients (18%) underwent conversion to THA, 2 (7%) underwent a PAO and 2 (7%) required a revision hip arthroscopy for an overall proportion of 32% failure of arthroscopic treatment of mild-

**Table II. Post-operative outcome measurements**

Outcome	Arthroscopy (n = 52)	No arthroscopy (n = 104)	P
	Mean ± SD	Mean ± SD	
<i>Radiographic measurements</i>			
Tönnis classification			
0	0 (0%)	0 (0%)	0.45
1	24 (53%)	51 (61%)	
2	18 (40%)	27 (33%)	
3	3 (7%)	5 (6%)	
4	0 (0%)	0 (0%)	
LCEA (°)	30.8±7.62	30.6±6.34	0.86
ACEA (°)	35.9±9.84	31.6±10.57	0.03
Acetabular index	4.3±4.24	4.3±4.67	0.95
<i>Patient-reported outcomes</i>			
Modified Harris hip score	77.9±17.88	86.7±13.82	0.003
>80	24 (46%)	77 (74%)	0.001
>90	16 (31%)	56 (54%)	0.01
UCLA activity score	7.1±2.40	7.6±2.13	0.21
WOMAC pain	80.1±20.67	89.6±14.62	0.01
WOMAC stiffness	76.8±20.79	83.8±16.60	0.046
WOMAC physical	85.5±17.43	91.9±13.02	0.03
WOMAC total	84.1±17.14	90.8±13.06	0.02
SF12 PCS	46.0±10.55	50.1±8.85	0.02
SF12 MCS	55.0±9.26	54.7±7.22	0.83

to-moderate dysplasia (LCEA 15°–19°). Another study reported similar proportion of failure (9/28 patients; 32%) in patients with hip dysplasia after arthroscopic labral repair, femoral osteoplasty and capsular closure [10]. An even higher rate of failure (24 of 34 patients, 70%) was reported after hip arthroscopy when the hip capsule is not adequately closed and labrum debridement is performed instead of repair in the setting of dysplasia [20]. Further concerns have been raised after previous reports demonstrating hip instability and progressive osteoarthritis after hip arthroscopic surgery in the setting of hip dysplasia [18, 23, 24].

Poor femoral head coverage assessed by LCEA is associated with up to three to five times higher risk of progression to osteoarthritis in population-based studies [40–42].

This is concerning because hip arthroscopy does not allow for correction of the abnormal hip mechanics in the setting of structural instability associated with inadequate femoral head coverage by a dysplastic acetabulum. At best, hip arthroscopy may allow for short-term improvement in symptoms without any evidence of long-term benefit regarding patient-reported outcomes or hip survivorship. In contrast, PAO allows biomechanical improvement by medializing and reducing cartilage stress in patients with hip dysplasia [43] and is an effective treatment of symptomatic hip dysplasia with reported survival of the native hip joint in 96% at 5-year [44], 60% at 20-year [27] follow-up and 30% at 30-year follow-up [28]. Despite lack of long-term studies supporting hip arthroscopy in the treatment of hip

**Table III. Change in radiographic and patient-reported outcome measurements**

Outcome	Arthroscopy (n = 52)		No arthroscopy (n = 104)		P
	Mean	95% CI	Mean	95% CI	
<i>Radiographic measurements</i>					
LCEA (°)	28.8	(26.4 to 31.2)	28.2	(26.8 to 29.6)	0.55
ACEA (°)	-11.4	(-13.6 to 27.6)	-13.0	(-14.5 to 28.0)	0.32
Acetabular index	19.0	(14.5 to 27.5)	19.1	(16.0 to 29.5)	0.85
<i>Patient-reported outcomes</i>					
Modified Harris hip score	20.8	(14.9 to 26.7)	24.3	(21.1 to 27.6)	0.30
Change >10 (freq. (%))	35	(67%)	80	(77%)	0.27
Change >20 (freq. (%))	28	(54%)	60	(58%)	0.78
UCLA activity score	1.9	(1.1 to 2.7)	0.9	(0.4 to 1.5)	0.06
WOMAC pain	28.1	(19.9 to 36.4)	29.8	(25.6 to 34.1)	0.54
WOMAC stiffness	20.8	(12.1 to 29.6)	25.1	(20.3 to 30.0)	0.28
WOMAC physical	27.6	(19 to 36.1)	27.9	(22.9 to 32.9)	0.73
WOMAC total	30.1	(21.4 to 38.9)	28.8	(24.0 to 38.9)	0.95
SF12 PCS	11.9	(8.5 to 15.2)	10.2	(7.9 to 12.6)	0.42
SF12 MCS	3.0	(0.0 to 6.0)	2.7	(0.7 to 4.8)	0.95

dysplasia, a recent prospective study reported that 24% of the patients that failed hip arthroscopy were diagnosed with acetabular dysplasia and underwent a PAO for definitive treatment [21].

To the best of our knowledge only two studies have investigated the impact of a previously failed arthroscopy on the outcomes of PAO. Jackson *et al.* [15] reported improvement in clinical outcomes at 2-year follow-up of a 31-year-old female who underwent concomitant arthroscopic labral repair and PAO after a failed hip arthroscopy in the setting of acetabular dysplasia. Kain *et al.* [16] compared 17 female patients who underwent PAO after previous failed arthroscopy to 34 patients that underwent PAO as index procedures. They reported no difference in change in the pre- and post-operative WOMAC scores between the two groups as well as no difference in the outcomes assessed before and after surgery. Although the authors suggested that failed arthroscopic treatment prior to PAO may not have an impact on the short-term outcomes after PAO, their findings should be interpreted with caution. Only 12 patients completed pre- and post-operative WOMAC scores and 3 of 17 (17%) of the patients in the failed arthroscopy group had progressed to a THA

compared with only 1 (3%) patient in the non-arthroscopy group. Our data also showed improvement in patient-reported outcomes after PAO in patients who had failed previous arthroscopy and the magnitude of change in outcome scores was not different than the change in patients that underwent PAO as an index procedure. However, we found that patients who had a failed arthroscopy had worse hip function, pain and quality of life assessed by the mHHS, WOMAC and SF-12 before the PAO and at the most recent follow-up. Most importantly, the percentage of patients with an excellent clinical result (mHHS  $\geq 90$ ) was markedly reduced in those with a failed arthroscopy when compared with those without previous arthroscopy.

This study has limitations. First and most important there is a potential for selection bias. The reason why arthroscopy was selected as the treatment of choice in the failed arthroscopy group is not clear because most patients underwent surgery outside the centers of the ANCHOR study group. Furthermore, the lack of patient-reported outcomes and intra-operative information does not allow us to establish a baseline comparison to the group that did not undergo a hip arthroscopy. The patients undergoing PAO with a previous failed arthroscopy could potentially



not have the same clinical indication or severity of dysplasia as those who underwent PAO only. We attempt to compensate this potential bias by matching patients by severity of dysplasia based on the LCEA. Second, we do not have information about all patients who may have been treated successfully with arthroscopy and to this date have not required PAO. However, our goal was not to identify proportion of success/failure of arthroscopy in the setting of dysplasia. Rather we focused on improve the understanding on a challenging clinical scenario we have seen in clinical practice: the patient with symptomatic hip dysplasia that undergoes hip arthroscopy and do not obtain the pain relief they were expecting after surgery. Third, the short-term results reported herein do not allow any comparison regarding long-term hip survivorship between the two groups. We currently follow these patients and expect to address this issue in further studies. Fourth, there may have been slight variation of PAO technique as multiple surgeons were included in the study. However, all surgeons have extensive experience with the procedure with lower reported rates of complication [25] and by including multiple surgeons our findings may be better generalized.

The long-term outcomes and hip survival of arthroscopic treatment of intra-articular pathology in the setting of acetabular dysplasia are unknown, and the proportion of early failure and reoperation appear to be higher than those after PAO even in mild dysplasia [45]. Some surgeons may offer hip arthroscopy for the treatment of labral tear in the setting of hip dysplasia based on the premise that it is a less invasive procedure and if it fails PAO could be performed later. In this study, we compared patient-reported outcomes and radiographic measurements in a cohort of patients who had undergone a previous failed hip arthroscopy to a matched cohort of patients who underwent PAO as the index procedure without prior arthroscopy. We found lower preoperative scores suggesting that patients with underlying acetabular dysplasia who do not experience improvement after hip arthroscopy have worse pain and function and lower physical activity level than patients with acetabular dysplasia undergoing PAO as the index procedure. We observed a similar magnitude of change in patient-reported outcomes between the groups suggesting that it is reasonable to consider PAO for the definitive management of patients with acetabular dysplasia that have recurrent or persistent symptoms after prior failed hip arthroscopy. However, at most recent follow-up after PAO, the clinical outcomes for the failed arthroscopy group were worse and the percentage of patients with excellent results was lower when compared with the non-arthroscopy group. Although we favor PAO for correction of the structural deformity, further studies are necessary to determine

the best surgical strategy for symptomatic patients with hip instability associated with mild acetabular dysplasia (LCEA between 20° and 25°).

#### ACKNOWLEDGEMENTS

ANCHOR Study Group Members who contributed to this article: Paul E. Beaulé, MD, FRCSC, Young-Jo Kim, MD, PhD, Michael B. Millis, MD, David A. Podeszwa, MD, Perry L. Schoenecker, MD, Rafael J. Sierra, MD, Ernest L. Sink, MD, Daniel J. Sucato, MD, Robert T. Trousdale, MD, and Ira Zaltz, MD.

#### FUNDING

This work was supported in part by Award UL1RR024992 from the National Center for Research Resources (J.C.C.). It was also supported in part by the Curing Hip Disease Fund (J.C.C.), the ANCHOR Research Fund, Smith & Nephew (J.C.C.), and the NFL Charities (J.C.C.).

#### REFERENCES

1. Henak CR, Abraham CL, Anderson AE *et al.* Patient-specific analysis of cartilage and labrum mechanics in human hips with acetabular dysplasia. *Osteoarthritis Cartilage* 2014; **22**: 210–7.
2. Domb BG, Lareau JM, Baydoun H *et al.* Is intraarticular pathology common in patients with hip dysplasia undergoing periacetabular osteotomy? *Clin Orthop Relat Res* 2014; **472**: 674–80.
3. Byrd JW, Jones KS. Hip arthroscopy in the presence of dysplasia. *Arthroscopy* 2003; **19**: 1055–60.
4. Domb BG, Stake CE, Lindner D *et al.* Arthroscopic capsular plication and labral preservation in borderline hip dysplasia: two-year clinical outcomes of a surgical approach to a challenging problem. *Am J Sports Med* 2013; **41**: 2591–8.
5. Fukui K, Briggs KK, Trindade CA, Philippon MJ. Outcomes after labral repair in patients with femoroacetabular impingement and borderline dysplasia. *Arthroscopy* 2015; **31**: 2371–9.
6. Fukui K, Trindade CA, Briggs KK, Philippon MJ. Arthroscopy of the hip for patients with mild to moderate developmental dysplasia of the hip and femoroacetabular impingement: outcomes following hip arthroscopy for treatment of chondrolabral damage. *Bone Joint J* 2015; **97-B**: 1316–21.
7. Larson CM, Ross JR, Stone RM *et al.* Arthroscopic management of dysplastic hip deformities: predictors of success and failures with comparison to an arthroscopic FAI cohort. *Am J Sports Med* 2016; **44**: 447–53.
8. Kalisvaart MM, Safran MR. Microinstability of the hip-it does exist: etiology, diagnosis and treatment. *J Hip Preserv Surg* 2015; **2**: 123–35.
9. Nawabi DH, Degen RM, Fields KG *et al.* Outcomes after arthroscopic treatment of femoroacetabular impingement for patients with borderline hip dysplasia. *Am J Sports Med* 2016; **44**: 1017–23.
10. Uchida S, Utsunomiya H, Mori T *et al.* Clinical and radiographic predictors for worsened clinical outcomes after hip arthroscopic

- labral preservation and capsular closure in developmental dysplasia of the hip. *Am J Sports Med* 2016; **44**: 28–38.
11. Yeung M, Kowalczyk M, Simunovic N, Ayeni OR. Hip arthroscopy in the setting of hip dysplasia: a systematic review. *Bone Joint Res* 2016; **5**: 225–31.
  12. Jayasekera N, Aprato A, Villar RN. Hip arthroscopy in the presence of acetabular dysplasia. *Open Orthop J* 2015; **9**: 185–7.
  13. Domb BG, LaReau J, Redmond JM. Combined hip arthroscopy and periacetabular osteotomy: indications, advantages, technique, and complications. *Arthrosc Tech* 2014; **3**: e95–e100.
  14. Duplantier NL, McCulloch PC, Nho SJ *et al*. Hip dislocation or subluxation after hip arthroscopy: a systematic review. *Arthroscopy* 2016; **32**: 1428–34.
  15. Jackson TJ, Watson J, LaReau JM, Domb BG. Periacetabular osteotomy and arthroscopic labral repair after failed hip arthroscopy due to iatrogenic aggravation of hip dysplasia. *Knee Surg Sports Traumatol Arthrosc* 2014; **22**: 911–4.
  16. Kain MS, Novais EN, Vallim C *et al*. Periacetabular osteotomy after failed hip arthroscopy for labral tears in patients with acetabular dysplasia. *J Bone Joint Surg Am* 2011; **93**(Suppl 2): 57–61.
  17. Kim KI, Cho YJ, Ramteke AA, Yoo MC. Peri-acetabular rotational osteotomy with concomitant hip arthroscopy for treatment of hip dysplasia. *J Bone Joint Surg Br* 2011; **93**: 732–7.
  18. Matsuda DK, Khatod M. Rapidly progressive osteoarthritis after arthroscopic labral repair in patients with hip dysplasia. *Arthroscopy* 2012; **28**: 1738–43.
  19. McCarthy JC, Mason JB, Wardell SR. Hip arthroscopy for acetabular dysplasia: a pipe dream? *Orthopedics* 1998; **21**: 977–9.
  20. Parvizi J, Bican O, Bender B *et al*. Arthroscopy for labral tears in patients with developmental dysplasia of the hip: a cautionary note. *J Arthroplasty* 2009; **24**: 110–3.
  21. Ross JR, Clohisy JC, Baca G *et al*. Patient and disease characteristics associated with hip arthroscopy failure in acetabular dysplasia. *J Arthroplasty* 2014; **29**: 160–3.
  22. Bogunovic L, Gottlieb M, Pashos G *et al*. Why do hip arthroscopy procedures fail? *Clin Orthop Relat Res* 2013; **471**: 2523–9.
  23. Mei-Dan O, McConkey MO, Brick M. Catastrophic failure of hip arthroscopy due to iatrogenic instability: can partial division of the ligamentum teres and iliofemoral ligament cause subluxation? *Arthroscopy* 2012; **28**: 440–5.
  24. Yeung M, Memon M, Simunovic N *et al*. Gross instability after hip arthroscopy: an analysis of case reports evaluating surgical and patient factors. *Arthroscopy* 2016; **32**: 1196–204.e1.
  25. Zaltz I, Baca G, Kim YJ *et al*. Complications associated with the periacetabular osteotomy: a prospective multicenter study. *J Bone Joint Surg Am* 2014; **96**: 1967–74.
  26. Matheney T, Kim YJ, Zurakowski D *et al*. Intermediate to long-term results following the bernese periacetabular osteotomy and predictors of clinical outcome: surgical technique. *J Bone Joint Surg Am* 2010; **92**(Suppl 1 Pt 2):115–29.
  27. Steppacher SD, Tannast M, Ganz R, Siebenrock KA. Mean 20-year followup of Bernese periacetabular osteotomy. *Clin Orthop Relat Res* 2008; **466**: 1633–44.
  28. Lerch TD, Steppacher SD, Liechti EF *et al*. One-third of hips after periacetabular osteotomy survive 30 years with good clinical results, no progression of arthritis, or conversion to THA. *Clin Orthop Relat Res* 2016; **475**: 1154–68.
  29. Wiberg G. The anatomy and roentgenographic appearance of a normal hip joint. *Acta Chir Scand* 1939; **83**: 7–38.
  30. Tönnis D. Normal values of the hip joint for the evaluation of X-rays in children and adults. *Clin Orthop Relat Res* 1976; **119**: 39–47.
  31. Clohisy JC, Barrett SE, Gordon JE *et al*. Periacetabular osteotomy in the treatment of severe acetabular dysplasia. Surgical technique. *J Bone Joint Surg Am* 2006; **88**(Suppl 1 Pt 1):65–83.
  32. Ganz R, Klaue K, Vinh TS, Mast JW. A new periacetabular osteotomy for the treatment of hip dysplasias. Technique and preliminary results. *Clin Orthop Relat Res* 1988; **(232)**:26–36.
  33. Harris WH. Traumatic arthritis of the hip after dislocation and acetabular fractures: treatment by mold arthroplasty. An end-result study using a new method of result evaluation. *J Bone Joint Surg Am* 1969; **51**: 737–55.
  34. Bellamy N, Buchanan WW, Goldsmith CH *et al*. Validation study of WOMAC: a health status instrument for measuring clinically important patient relevant outcomes to antirheumatic drug therapy in patients with osteoarthritis of the hip or knee. *J Rheumatol* 1988; **15**: 1833–40.
  35. Ware J Jr., Kosinski M, Keller SD. A 12-Item Short-Form Health Survey: construction of scales and preliminary tests of reliability and validity. *Med Care* 1996; **34**: 220–33.
  36. Amstutz HC, Thomas BJ, Jinnah R *et al*. Treatment of primary osteoarthritis of the hip. A comparison of total joint and surface replacement arthroplasty. *J Bone Joint Surg Am* 1984; **66**: 228–41.
  37. Byrd JW, Jones KS. Arthroscopic management of femoroacetabular impingement: minimum 2-year follow-up. *Arthroscopy* 2011; **27**: 1379–88.
  38. Lequesne M. de S. [False profile of the pelvis. A new radiographic incidence for the study of the hip. Its use in dysplasias and different coxopathies.]. *Rev Rhum Mal Osteoartic* 1961; **28**: 643–52.
  39. Lehmann CL, Nepple JJ, Baca G *et al*. Do fluoroscopy and post-operative radiographs correlate for periacetabular osteotomy corrections? *Clin Orthop Relat Res* 2012; **470**: 3508–14.
  40. Lane NE, Lin P, Christiansen L *et al*. Association of mild acetabular dysplasia with an increased risk of incident hip osteoarthritis in elderly white women: the study of osteoporotic fractures. *Arthritis Rheum* 2000; **43**: 400.
  41. Reijman M, Hazes JM, Pols HA *et al*. Acetabular dysplasia predicts incident osteoarthritis of the hip: the Rotterdam study. *Arthritis Rheum* 2005; **52**: 787–93.
  42. Agricola R, Heijboer MP, Roze RH *et al*. Pincer deformity does not lead to osteoarthritis of the hip whereas acetabular dysplasia does: acetabular coverage and development of osteoarthritis in a nationwide prospective cohort study (CHECK). *Osteoarthritis Cartilage* 2013; **21**: 1514–21.
  43. Abraham CL, Knight SJ, Peters CL *et al*. Patient-specific chondrolabral contact mechanics in patients with acetabular dysplasia following treatment with peri-acetabular osteotomy. *Osteoarthritis Cartilage* 2017; **25**: 676–84.
  44. Matheney T, Kim YJ, Zurakowski D *et al*. Intermediate to long-term results following the Bernese periacetabular osteotomy and predictors of clinical outcome. *J Bone Joint Surg Am* 2009; **91**: 2113–23.
  45. Ricciardi BF, Fields KG, Wentzel C *et al*. Complications and short-term patient outcomes of periacetabular osteotomy for symptomatic mild hip dysplasia. *Hip Int* 2016; **27**: 42–8.