

Washington University School of Medicine

Digital Commons@Becker

Open Access Publications

9-1-2019

Videofluoroscopic swallow study features of lower esophageal sphincter achalasia-like syndrome in dogs

Megan E Grobman

James Schachtel

C Prakash Gyawali



Teresa E Lever

Carol R Reiner

Follow this and additional works at: https://digitalcommons.wustl.edu/open_access_pubs

STANDARD ARTICLE

Videofluoroscopic swallow study features of lower esophageal sphincter achalasia-like syndrome in dogs

Megan E. Grobman¹  | James Schachtel² | C. Prakash Gyawali³ | Teresa E. Lever⁴ | Carol R. Reiner¹ 

¹Department of Veterinary Medicine and Surgery, College of Veterinary Medicine, University of Missouri, Columbia, Missouri

²Brames Animal Health, Littleton, Colorado

³Division of Gastroenterology, Washington University School of Medicine, St. Louis, Missouri

⁴Department of Otolaryngology-Head and Neck Surgery, School of Medicine, University of Missouri, Columbia, Missouri

Correspondence

Carol R. Reiner, Department of Veterinary Medicine and Surgery, College of Veterinary Medicine, University of Missouri, 900 E Campus Drive, Columbia MO 65211.
 Email: reinerc@missouri.edu

Funding information

Mizzou Advantage Fund; Upright Canine Brigade

Abstract

Background: Megaesophagus (ME) carries a poor long-term prognosis in dogs. In people, lower esophageal sphincter (LES) disorders causing functional obstruction are rare causes of ME that may respond to targeted treatment. Functional LES disorders are reported rarely in dogs because of challenges in diagnostic methodologies.

Hypothesis/Objectives: To identify dogs with videofluoroscopic swallow study (VFSS) features of LES achalasia-like syndrome (LES-AS). We hypothesized that dogs with LES-AS could be distinguished from normal dogs using standardized VFSS criteria.

Animals: Dogs with LES-AS by VFSS (n = 19), healthy normal dogs (n = 20).

Methods: Retrospective study. One-hundred thirty dogs presented to the University of Missouri Veterinary Health Center (MU-VHC) between April 2015 and December 2017 for a free-feeding VFSS; 20 healthy dogs were included as controls. Swallow studies were evaluated for failure of the LES to relax during pharyngeal swallow (LES-AS). Affected dogs subsequently were evaluated using standardized criteria to identify metrics important for identifying and characterizing dogs with LES-AS.

Results: Nineteen dogs with LES-AS were identified out of 130 VFSS. Megaesophagus was present in 14 of 19 (73.7%) dogs with LES-AS. A baseline esophageal fluid-line and “bird beak” were present in 68.4% (95% confidence interval [CI], 47.5%-89.3%) and 63.2% (95% CI, 41.5%-84.8%) of affected dogs, respectively. The esophagus was graded as acontractile (8/19), hypomotile (8/19), or hypermotile (3/19).

Conclusions and Clinical Importance: Dogs with LES-AS may successfully be identified by VFSS using a free-feeding protocol. These data are of critical clinical importance because a subpopulation of dogs with functional LES obstruction may be candidates for targeted intervention.

KEYWORDS

dysphagia, fluoroscopy, free-feeding, functional obstruction, megaesophagus

Abbreviations: CI, confidence interval; DeD, distal esophageal diameter; HRM, high-resolution manometry; IQR, interquartile range; LES, lower esophageal sphincter; LES-AS, LES achalasia-like syndrome; ME, megaesophagus; MU-VHC, University of Missouri Veterinary Health Center; VFSS, videofluoroscopic swallow study.

This is an open access article under the terms of the Creative Commons Attribution-NonCommercial License, which permits use, distribution and reproduction in any medium, provided the original work is properly cited and is not used for commercial purposes.

© 2019 The Authors. *Journal of Veterinary Internal Medicine* published by Wiley Periodicals, Inc. on behalf of the American College of Veterinary Internal Medicine.

1 | INTRODUCTION

Megaesophagus (ME) in dogs is a motility disorder of the esophagus carrying a poor long-term prognosis with death frequently reported secondary to aspiration pneumonia, malnutrition, and euthanasia because of poor quality of life.¹⁻³ Classically, ME is described as congenital or acquired and as idiopathic or secondary to a number of underlying etiologies including hypoadrenocorticism and myasthenia gravis (MG).⁴⁻⁶ However, identification of an underlying disease fails to determine if a functional outflow obstruction of the esophagus is causing ME. This distinction is critically important in people where lower esophageal sphincter (LES) disorders causing functional obstruction (LES achalasia) are rare causes of ME that respond to targeted treatment designed to address esophagogastric outflow obstruction.⁷⁻⁹ This condition is considered distinct from conditions that cause esophageal hypomotility without functional LES obstruction. Achalasia, a primary esophageal motility disorder in people, results from a selective loss of inhibitory myenteric neurons leading to failure of the LES to relax in response to a pharyngeal swallow and impaired esophageal peristalsis.¹⁰ Although sporadic cases of functional LES obstruction have been suspected in dogs, comparable etiologic information is lacking. Functional LES disorders in dogs rarely are diagnosed because of limitations in currently available testing used in dysphagia evaluation.¹¹⁻¹⁴ However, functional LES disorders may represent an important, yet undetected, subpopulation of dogs with ME, perhaps responsive to targeted intervention and with a different long-term prognosis.

In people, high-resolution manometry (HRM) is considered the gold standard for the diagnosis of functional LES disorders such as LES achalasia. Understanding the limitations of HRM in dogs, which include cost, availability, and animal compliance, our goal was to use a free-feeding VFSS protocol¹⁵ to characterize VFSS features of functional LES obstruction. We defined a functional LES obstruction as failure of the LES to relax in response to a pharyngeal swallow. Although a direct comparison between dogs and people cannot be made without manometry, we elected to refer to functional LES obstruction in our canine patients as LES achalasia-like syndrome (LES-AS) after the key pathophysiologic feature of achalasia in humans.^{7,16} Our objective was to identify VFSS parameters that could be used to identify LES-AS in dogs. We hypothesized that dogs with LES-AS could be distinguished from normal dogs using standardized VFSS criteria.

2 | MATERIALS AND METHODS

2.1 | Case selection and criteria

Medical records for dogs presented to the University of Missouri Veterinary Health Center (MU-VHC) between April 2015 and December 2017 for VFSS were retrospectively reviewed. Dogs were included if they had a standing, free-feeding VFSS available for review, a complete medical record, and evidence of failure of the LES to relax in response to a pharyngeal swallow (LES-AS). Dogs determined to have LES-AS, were further evaluated for discriminating criteria between LES-AS, dogs

with non-LES-AS ME, and healthy dogs. Common features among dogs with LES-AS were assessed to evaluate for discrete clinical syndromes.^{7,17} Standardized assessment and diagnostic criteria were developed and validated by calculating agreement between a panel of investigators at the University of Missouri College of Veterinary Medicine and a blinded expert reviewer with expertise in the area of swallowing disorders (C.P.G.) based on diagnostic criteria and characteristic features of disease identified in people. These criteria included failure of the LES to relax in response to a pharyngeal swallow, esophageal motility, retained ingesta, or oral secretions within the esophagus, "bird beak," reflux, and the absence of mechanical obstruction.^{7,9,18,19} Objective metrics for determining ME involve comparisons to the cervical vertebrae or thoracic inlet. Unfortunately, these regions may be out of view during parts of the VFSS. As such, subjective assessment of dogs with all dogs with ME on VFSS was objectively evaluated by comparing the ratios of distal esophageal diameter (DeD) to the height of the 12th thoracic vertebral body compared to healthy dogs. For those with focal ME, the most distal portion of the esophagus oral to the obstruction was used to calculate the DeD.

Dogs receiving prokinetic medications or opioids and those with focal ME or VFSS evidence of mechanical obstruction (including hiatal hernia and esophageal strictures) were excluded. Additional testing for hypothyroidism, MG, and hypoadrenocorticism was performed in most dogs at the discretion of the attending clinician based on supporting clinical evidence. Dogs with a positive diagnosis of hypothyroidism, MG, or hypoadrenocorticism were not excluded from further evaluation. Swallow studies were compared against archived normal data from a previous publication ($n = 20$).¹⁵ Control dogs were considered healthy based on physical examination and the absence of either respiratory or gastrointestinal signs, including oral, pharyngeal, and esophageal dysphagia, for the 6 months before the VFSS.

2.2 | Demographic data

Demographic data, clinical features, duration of clinical signs, incidences of aspiration pneumonia, and body condition scores were acquired from the medical record.

2.3 | Videofluoroscopic swallow study protocol

The VFSS was performed in accordance with a previously validated free-feeding VFSS protocol.¹⁵ Briefly, after a 12-hour fast, dogs were placed in 1 of 4 polycarbonate kennels designed to accommodate small or toy (≤ 16 kg), medium (> 16 kg to ≤ 30 kg), large (> 30 kg to ≤ 39 kg), and giant breed (≥ 39 kg) dogs. These kennels were designed to permit upright free-feeding behavior, direct animal visualization, and contrast videofluoroscopy. The dogs were fed 3 standardized food consistencies containing a contrast agent: puree (25% iohexol [350 mg/mL]), liquid (25% iohexol [350 mg/mL]), and kibble (barium 40% wt/vol). Studies were performed at 30 frames per second using a GE Advantx or GE OEC 9900 Elite Mobile C-Arm system at the MU-VHC. Studies were considered complete if they included VFSS views as described in Table 1. The VFSS for functional LES-AS was

TABLE 1 Recommended minimum VFSS clips (video sequences) for a diagnosis of lower esophageal achalasia-like syndrome in dogs

Lateral views
Obtain prefeeding video sequence(s) of the thorax (pharynx to LES) <ul style="list-style-type: none"> High-resolution images of the larynx are recommended
Slurry (canned pureed food) <ul style="list-style-type: none"> Obtain single video sequence consisting of 3 swallows focused on the UES; follow 3rd-4th swallow to the LES Focus on the LES while actively swallowing Focus on the LES while the dog is not eating but is sitting or standing
Liquid <ul style="list-style-type: none"> Obtain a single video sequence from the UES (3–6 rapid swallows) panning to LES
Kibble <ul style="list-style-type: none"> Obtain a single video sequence that follows one kibble swallow from the UES to the LES; stay focused on the LES while the animal is actively swallowing Focus on the LES while the animal is not eating (sitting or standing) Repeat if necessary
Application of abdominal pressure (induction of hernia or reflux): minimum of 1 video sequence focused on the LES
Delayed phase <ul style="list-style-type: none"> Evaluate residual esophageal column height before and after 5 minutes of being held upright
Dorsoventral views
Slurry <ul style="list-style-type: none"> Focus on the LES while swallowing slurry Focus on the LES while the animal is not eating
Kibble <ul style="list-style-type: none"> Focus on the LES while swallowing kibble Focus on the LES while the animal is not eating

Abbreviations: LES, lower esophageal sphincter; VFSS, videofluoroscopic swallow study; UES, upper esophageal sphincter.

considered diagnostic only if the LES could be evaluated in response to pharyngeal swallowing using multiple food or liquid consistencies containing contrast. The LES was actively challenged (ie, contrast abutting the LES) during active swallowing with the dog in a sitting or standing position or both to mitigate the effect of esophageal weakness on the passage of contrast through the LES. Evaluation also was performed when the dog was not actively swallowing to assess for bolus passage secondary to hydrostatic pressure. Some dogs were required to sit during active swallows to add an additional challenge to the LES.

2.4 | Statistical analysis

Statistical analysis was performed using the MedCalc data analysis software (version 18.5). Descriptive statistics were determined where appropriate. Nonparametric analysis was performed on objective swallow metrics because of the small sample size. Data are presented as median and interquartile range (IQR). A 95% confidence interval (CI) was calculated for common VFSS features of LES-AS. A receiver operator characteristic curve analysis was performed to determine

the sensitivity and specificity for detection of ME using a ratio between the maximal DeD and the height of the T12 vertebral body. Kappa or weighted kappa coefficients were calculated to assess for agreement between the MU panel and the independent reviewer (C.P.G.) for criteria discriminating between dogs with LES-AS and normal dogs and the assigned LES-AS subtype for each dog. Weighted kappa coefficients were weighed linearly. A P -value $\leq .05$ was considered significant.

3 | RESULTS

3.1 | Animals

One hundred thirty dogs underwent VFSS at the MU-VHC between April 2015 and December 2017. Twenty-nine dogs were found to have ME based on VFSS. Megaesophagus was described as either generalized ($n = 23$) or focal ($n = 6$). Those with generalized ME without LES-AS ($n = 9$) were characterized by diffuse esophageal body hypomotility without LES obstruction. In these cases, a food bolus passed unimpeded into the stomach once presented to the LES. Timing of LES relaxation was coordinated with a pharyngeal swallow. Videofluoroscopic swallow study diagnoses for the 130 cases reviewed are available in Figure 5.

Of 130 VFSS, 19 dogs, including 61% of those with generalized ME, met entry criteria for further evaluation by having a failure of the LES to relax in response to pharyngeal swallow. For those with LES-AS, ages ranged from 5 weeks to 12 years, with a median (IQR) age of 2.5 years (0.9–6.7 years). Seven dogs were spayed females, 2 were intact females, 8 were castrated males, and 2 were intact males. Breeds represented included mixed breeds ($n = 4$), Australian Shepherd ($n = 3$), Chihuahua ($n = 2$), Golden Retriever ($n = 2$), Miniature Schnauzer ($n = 1$), Miniature Dachshund ($n = 1$), Doberman Pinscher ($n = 1$), German Shepherd Dog ($n = 1$), Irish Wolfhound ($n = 1$), Boston Terrier ($n = 1$), German Shorthair Pointer ($n = 1$), and English Cocker Spaniel ($n = 1$). The median (IQR) body condition score on a 9-point scale was 3 (2–5), with 4–5 of 9 being considered ideal.

Of 19 dogs with LES-AS, presenting complaints included regurgitation ($n = 14$), regurgitation and cough ($n = 4$), and cough alone ($n = 1$). The duration of clinical signs before presentation ranged from 5 weeks to 4 years, with a median (IQR) of 7 months (4–16 months). Hypothyroidism was ruled out in 17 of 19 dogs by total serum T4 and TSH concentrations. Hypoadrenocortisolism was ruled out in 17 of 19 dogs by either baseline serum cortisol ($>2 \mu\text{g/dL}$ or $>55 \text{ nmol/L}$) concentrations or ACTH stimulation test. Acetylcholine receptor antibody testing was performed in 14 of 19 dogs. Testing was confirmatory for MG in 1 dog. In the remaining dogs, clinicians elected to forgo testing based on lack of supporting clinical signs. A history of aspiration pneumonia was reported in 5 of 19 dogs. No dog underwent anesthesia within 30 days before presentation to the VHC.

Archived VFSS from 20 research and companion dogs were included in our study as healthy controls ($n = 20$). Dogs were determined to be healthy based on history (no evidence of dysphagia, or gastrointestinal or respiratory signs within 6 months of the VFSS) and

TABLE 2 Standardized VFSS scoring rubric for LES achalasia-like syndrome in the dog

VFSS metric	Feature
Baseline fluid line	Present
	Absent
Subjective ME	Present
	Absent
Primary peristalsis (contraction)	Acontractile
	Hypomotile
	Hypermotile
	Normal
Primary peristalsis (propulsion)	Effective, complete
	Effective, partial
	Ineffective
	Absent
Primary peristaltic defect (location)	Focal
	Diffuse
Secondary peristalsis (contraction)	Acontractile
	Hypomotile
	Hypermotile
	Normal
Secondary peristalsis (propulsion)	Effective, complete
	Effective, partial
	Ineffective
	Absent
LES "bird beak"	Present
	Absent
Narrowed/hypermotile distal esophagus	Present
	Absent
Entry of ingesta into the stomach	With pharyngeal swallow
	With hydrostatic pressure
	Complete obstruction
	Normal
Reflux	Present
	Absent
Hiatal hernia	Present
	Absent
Functional LES obstruction	Present
	Absent
Consistency of food where achalasia was observed	Puree
	Liquid
	Kibble
Inappropriate LES function	>50% of swallows
	<50% of swallows
Collective impression to support LES-AS	Present
	Absent

(Continues)

TABLE 2 (Continued)

VFSS metric	Feature
Subtype	Type 1
	Type 2
	Type 3
	Pseudoachalasia

Abbreviations: LES, lower esophageal sphincter; LES-AS, LES achalasia-like syndrome; VFSS, videofluoroscopic swallow study.

physical examination. Ages ranged from 4 weeks to 14 years, with a median (IQR) age of 4.9 years (2.0-9.0 years). Eleven dogs were spayed females and 9 dogs were castrated males. Breeds represented included Pembroke Welsh Corgis (n = 6), long haired Dachshunds (n = 5), Chinese Crested and Beagle mix (n = 5), large mixed breeds (n = 2), Jack Russell Terrier (n = 1), and German Shepherd Dog (n = 1).

3.2 | Videofluoroscopic swallow studies

3.2.1 | MU results

The VFSS metrics for evaluation are described in Table 2. Functional obstruction of the LES was diagnosed if failure of the LES to relax in response to a pharyngeal swallow was observed during active challenge of the LES. The VFSS videos initially were evaluated by a panel of trained reviewers, including 2 board-certified internal medicine specialists (M.G., C.R.), a PhD and board-certified speech-language pathologist specializing in translational deglutology (T.L.), and a senior radiology resident (J.S.). Panel results were achieved by consensus. An MD gastroenterologist considered an expert in esophageal motility disorders (C.P.G.) independently reviewed each study using the standardized criteria in Table 2. The independent reviewer (C.P.G.) was blinded to the findings of the MU panel. The results of the MU panel and the independent reviewer were evaluated for agreement in order to validate our VFSS criteria for diagnosis and classification. Multiple criteria for evaluation were used based on esophageal motility studies performed in people using standardized criteria (see below)^{18,20,21}.

1. *Megaesophagus*: Dogs were assessed for the presence or absence of generalized esophageal dilatation. Subjective evaluation subsequently was compared to objective parameters (esophageal diameter at its widest point compared with the height of the T12 vertebral body). The T12 vertebra was selected for ease of visualization relative to the LES (Figure 1).
2. *Timing of ingesta entry into the stomach*: Movement of the contrast bolus from the distal esophagus into the stomach was assessed to determine if bolus passage was in response to active pharyngeal swallowing, secondary to hydrostatic pressure (ie, gravity-dependent and not during swallowing) or in response to a secondary peristaltic wave.
3. *Baseline fluid line*: Before administering contrast-laden food or liquid, the esophagus was assessed for the presence or absence of

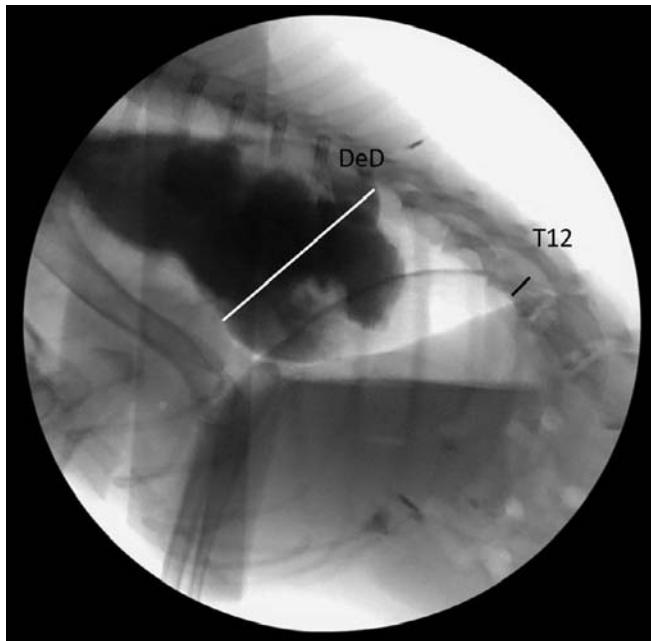


FIGURE 1 Maximal distal esophageal diameter (DeD) and the height of the T12 vertebral body are used to generate a DeD:T12 ratio. A comparison between this ratio (with >4.7 times being 94% sensitive and 100% specific for ME) and subjective assessment of ME showed perfect correlation with a kappa coefficient of 1

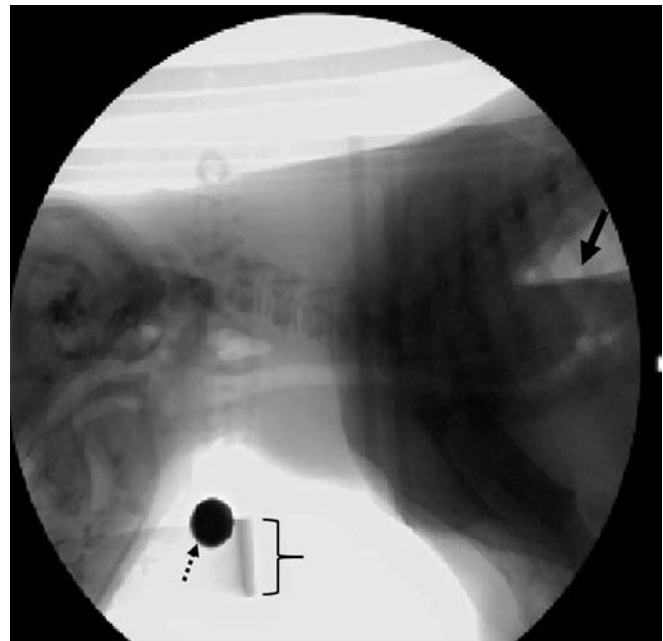


FIGURE 2 Cranial (left), caudal (right). Lateral projection of a still image from a videofluoroscopic swallow study. A baseline fluid line (arrow) is visible in the esophagus after a ≥ 12 -hour fast before administration of oral contrast material. The top lip of the food bowl is marked by brackets. The dashed arrow points to a 1 cm calibration marker worn around the animal's neck

fluid retention within the esophagus after a prolonged fast (≥ 12 hours). This is distinguished from reflux by evaluating for persistence or lack of clearance. Ventrally dependent fluid within a diverticulum was not considered positive for a fluid line (Figure 2).

4. **LES "bird beak":** The distal esophagus and LES were assessed for the presence or absence of a dilated distal esophagus terminating in an elongated taper ("bird beak") through the LES during active pharyngeal swallowing (Figure 3).
5. **Esophageal peristalsis (contraction and propulsion):** The esophagus was assessed for the presence or absence of the following clinical features:
 - a. **Primary peristalsis** was defined as a wave of bolus movement beginning in the proximal esophagus, initiated by a pharyngeal swallow;
 - b. **Secondary peristalsis** was defined as a wave initiated by esophageal distention, evaluated while the dog was not actively eating or drinking to avoid confounding by concurrent primary peristalsis and clearance initiated by a subsequent food bolus;
 - c. **Esophageal contraction** referred to the inward movement of the dorsal and ventral esophageal walls; and
 - d. **Propulsion** referred to the ability of either primary or secondary peristaltic activity to conduct a food bolus aborally towards the LES.
6. **Narrowed (spastic) distal esophagus:** The distal esophagus was assessed for the presence or absence of a transient segmental decrease in diameter of the distal esophagus, proximal to the LES, resulting in a narrowed contrast column. A lack of robust contractions against a

closed LES distinguishes this finding from a hypermotile esophagus (Figure 4).

7. **Hypermotile distal esophagus:** The distal esophagus was assessed for the presence or absence of robust contraction against a closed LES, during or between pharyngeal swallows.
8. **Reflux:** The presence or absence of orad movement of contrast from the stomach into the esophagus was evaluated passively and during forced abdominal compression. During abdominal compression, a licensed veterinarian wearing appropriate personal protective equipment applied abdominal pressure to a standing dog to induce reflux, a sliding hiatal hernia, or both.
9. **Hiatal hernia:** The presence or absence of herniation of the stomach into the thoracic cavity (through the esophageal hiatus of the diaphragm) was assessed either passively or in response to abdominal pressure by a licensed veterinarian.

Megaesophagus was present in 14 of 19 dogs with LES-AS. The ratio of the maximum DeD to height of the T12 vertebral body was significantly higher in all dogs with subjective ME ($n = 29$; median, 6.4; IQR, 6.0-7.3) compared to healthy dogs (median, 3.8; IQR, 3.3-4.0; $P < .001$). No significant differences were identified between LES-AS and non-LES-AS dogs with ME for the DeD:height of T12. A DeD:T12 ratio >4.8 was 94% sensitive and 100% specific for ME compared to normal controls. In dogs with LES-AS, a baseline esophageal fluid line was present in 68.4% (95% CI, 47.5%-89.3%). An LES "bird beak" was present in 63.2% (95% CI, 41.5%-84.8%) of dogs with LES-AS. These

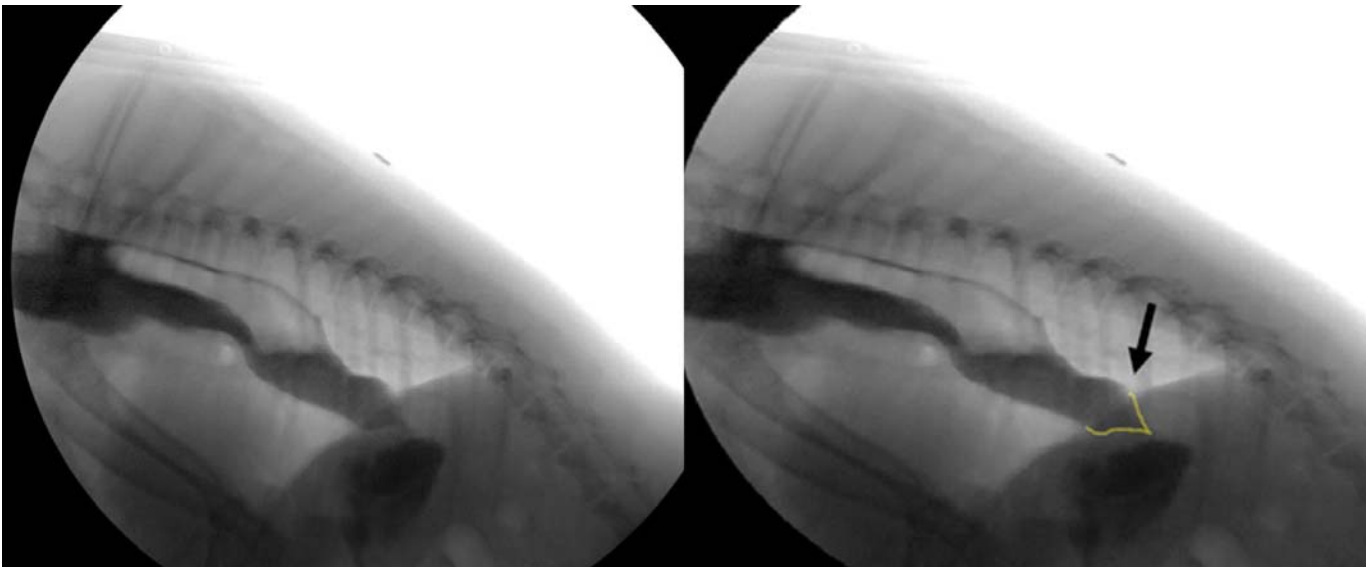
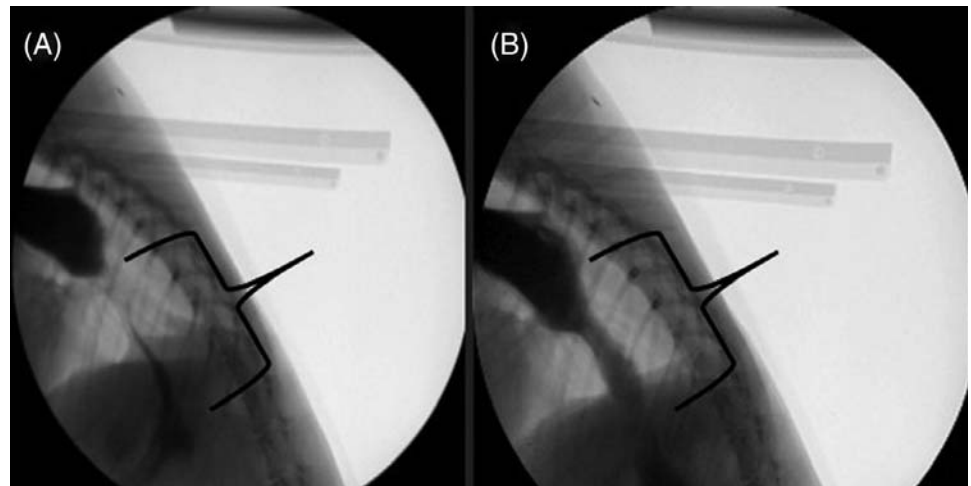


FIGURE 3 Cranial (left), caudal (right). Fluoroscopic static image of the distal esophagus in a dog actively swallowing a pureed food consistency. This image demonstrates a narrowed contrast column resulting in an elongated taper through the lower esophageal sphincter (arrow). This appearance bears resemblance to a “bird beak,” which is where this clinical feature received its name

FIGURE 4 Cranial (left), Caudal (right). (A) A narrowed distal esophagus is present (region displayed by brackets) that (B) partially increases in diameter with increased hydrostatic pressure/gravity as the dog is sitting down. This demonstrates that failure of the lower esophageal sphincter to relax is secondary to a functional obstruction and can be overcome with enough hydrostatic pressure



features were not present in any dog with ME that did not also have LES-AS. Additional discriminatory VFSS criteria for LES-AS compared to controls are presented in Table 3.

For primary peristalsis, the esophagus was subjectively graded by the MU panel as acontractile ($n = 8$), hypomotile ($n = 8$), or hypermotile ($n = 3$) compared to normal controls. Normal primary peristaltic propulsion was not identified in any LES-AS dog. Apart from 1 dog, in dogs with acontractile or hypomotile primary peristalsis, decreased secondary peristalsis also was observed. Normal secondary contractions ($n = 4$) diffuse throughout the length of the esophagus were observed in dogs with hypermotile primary peristalsis and in the distal esophagus of 1 dog with hypomotile primary peristalsis. Reflux was identified in 1 of 19 dogs with LES-AS compared to 8 of 20 healthy controls. In healthy dogs, physiologic reflux occurred commonly during feeding but tended to be restricted to the distal esophagus and was rapidly cleared

by a subsequent food bolus. In our experience, in clinical patients in which reflux is thought to be pathologic, reflux tends to occur spontaneously (not during feeding), may span the length of the esophagus, or may be retained in the esophagus for a longer period. The 1 dog with LES-AS with reflux appeared to have physiologic reflux, excepting that reflux events occurred spontaneously (ie, not during feeding). This dog later was diagnosed with distal mechanical obstruction of the esophagus (pseudoachalasia). Postprocedural aspiration pneumonia was not reported for any dog undergoing VFSS.

In evaluating VFSS in dogs with LES-AS, classification criteria for 3 discrete syndromes were developed, and a case of pseudoachalasia was identified. Although each syndrome was characterized by failure of the LES to relax in response to pharyngeal swallowing, differences were observed in the extent and type of peristaltic dysfunction, as well as in the extent of gastric filling and esophageal dilatation.

Type 1 LES-AS (n = 8 dogs) was characterized by ME with acontractile primary peristalsis and absent secondary contraction. Abnormal LES relaxation (failure to relax in response to pharyngeal swallowing) was observed in response to all food and liquid types, resulting in minimal gastric filling.

Type 2 LES-AS (n = 7 dogs) was characterized by hypomotile primary peristalsis with or without ME. Of note, increased hydrostatic pressure (achieved by sitting, upright feeding, or substantial accumulation of food within the esophagus) facilitated gastric filling.

Type 3 LES-AS (n = 3 dogs) was characterized by a spastic distal third of the esophagus or a hypermotile distal esophagus against a closed LES, with or without ME.

TABLE 3 Frequency of VFSS abnormalities in LES-AS patients compared with normal controls

VFSS parameter	LES-AS	Control
Failure of LES to open during pharyngeal swallowing	19/19	0/20
Abnormal LES relaxation >50% of swallows	18/19	0/20
Abnormal LES relaxation ≥20% to <50% of swallows	1/19	0/20
Passage of ingesta from esophagus to stomach exclusively due to hydrostatic pressure	13/19	0/20
LES "Bird Beak"	12/19	0/20
Baseline fluid line	13/19	0/20
Gastric reflux	1/19	8/20

Abbreviations: LES, lower esophageal sphincter; LES-AS, LES achalasia-like syndrome; VFSS, videofluoroscopic swallow study.

TABLE 4 VFSS parameters with kappa/weighted kappa (linear weighting) coefficients, standard error, 95% CI, and degree of agreement between the MU panel and an independent reviewer (C.P.G.)

VFSS parameter	Kappa	Standard error	95% CI	Degree of agreement
Presence of functional LES obstruction	1.0	0.0	1-1	Perfect
Timing of ingesta into the stomach (with pharyngeal swallow)	0.7	0.2	0.5-1	Substantial
Timing of ingesta into the stomach (from hydrostatic pressure)	1.0	0.0	1-1	Perfect
Baseline fluid line	1.0	0.0	1-1	Perfect
Megaesophagus (presence or absence of ME)	1.0	0.0	1-1	Perfect
LES "Bird beak"	0.7	0.2	0.4-1	Substantial
Primary peristalsis (contraction)	0.8	0.3	0-0.9	Near Perfect
Primary peristalsis (propulsion)	0.5	0.6	0.2-0.8	Moderate
Hypermotile distal esophagus	0.7	0.2	0.3-1	Substantial
Consistency where LES-AS was noted	0.9	0.1	0.7-1	Near perfect
Secondary peristalsis	0.8	0.1	0.6-1	Near perfect
Type of LES-AS	0.8	0.1	0.5-1	Near perfect
Reflux (abdominal pressure)	1.0	0.0	1-1	Perfect
Reflux (spontaneous)	0.9	0.1	0.8-1	Near perfect
Reflux (location)	0.9	0.1	0.8-1	Near perfect
Frequency of observed LES abnormalities	0.3	0.3	0-0.9	Fair

Abbreviations: LES, lower esophageal sphincter; LES-AS, LES achalasia-like syndrome; ME, megaesophagus; VFSS, videofluoroscopic swallow study.

Pseudoachalasia (n = 1) was characterized by mechanical esophageal-gastric junction outflow obstruction. In the dog in this report, it was caused by a circumferential adenocarcinoma.

Objective (DeD:T12) and subjective interpretations of ME were found to have perfect agreement. After agreement was achieved among the MU panel, discriminatory and subclassification criteria were compared to the review performed by the MD gastroenterologist to calculate agreement. Specific kappa values, standard error, and 95% CI are presented in Table 4.

4 | DISCUSSION

Our study indicated that a subpopulation of dogs with ME has a functional obstruction of the LES (LES-AS), which may allow additional therapeutic opportunities. A lack of understanding of disease pathogenesis and limitations in available diagnostic tests play a role in the poor prognosis associated with ME. We have used VFSS to characterize functional LES obstruction, termed LES-AS in dogs. The identification of a previously overlooked subpopulation of dogs with esophageal dysphagia provides hope for these patients, as humans with analogous diseases may respond to interventions targeting functional obstruction of the LES including injection of the LES with botulinum toxin A, pneumatic LES dilatation, or surgical LES myotomy. Although further research is needed, the identification of similar clinical syndromes between dogs and people may suggest utility for dogs with LES-AS as a translational model for humans with LES achalasia. Successful treatment protocols used for humans also may benefit dogs and merit evaluation in clinical trials.

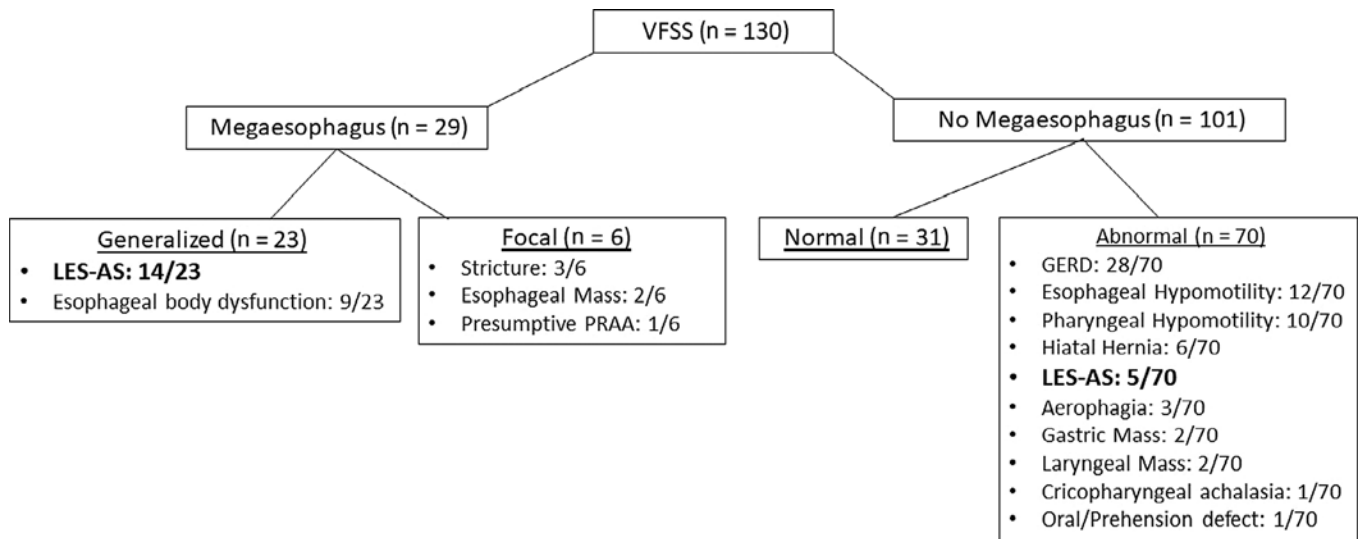


FIGURE 5 Final videofluoroscopic swallow study (VFSS) diagnosis for all patients evaluated by VFSS at the University MU-VHC between April 2015 and December 2017

The criterion standard for evaluation of LES achalasia in people is HRM, which evaluates esophageal motor function by detecting esophageal and LES pressure profiles.^{7-9,22} In humans, this technique allows detection and subcategorization of obstructive LES disorders based on their pathophysiologic profiles.⁸ This technique rarely is utilized in companion animals because of limited availability, high cost, and variable animal tolerance.²³⁻²⁵ Conventionally, evaluation of dysphagia in dogs has relied upon historical information, physical examination findings, and radiography including VFSS, all of which are considered the gold standard in veterinary medicine.¹⁵ In people, swallow studies were used before the development of HRM to detect LES achalasia and more recently have been proposed as the method of choice for detecting recurrence of functional LES obstruction after treatment.^{9,18,21} The barium esophagram is an established protocol for detecting LES achalasia and is considered an alternative initial approach in humans where LES achalasia is suspected.^{7,9,21} Standardized dynamic contrast studies, such as the “timed barium swallow,” allow clinicians to detect the extent of esophageal bolus retention.¹⁸ Despite only moderate sensitivity, these tests are considered specific for a diagnosis of LES achalasia.²¹

Before our VFSS-based study, there had been no such standardized protocols developed for evaluating functional LES obstruction in dogs. In part, this may be a consequence of the paucity of VFSS in dogs with ME and other forms of dysphagia, for which the historical protocol of restrained recumbency and force feeding of contrast has unacceptable risks of aspiration.^{26,27} However, allowing upright free-feeding in unrestrained dogs dramatically decreases the risk of aspiration to no more than what would be encountered during feeding at home and allows the study of any type of dysphagia (ie, oral, pharyngeal, or esophageal).¹⁵ This technique also allows the investigator to assess the timing of LES relaxation in response to a pharyngeal swallow, allowing investigators to distinguish between LES-AS and other forms of ME. These are broadly characterized by esophageal hypomotility or weakness without functional obstruction of the LES. This distinction is critically

important because the functional obstruction at the level of the LES is what determines candidacy for targeted therapeutic intervention. In our clinic, no dog having undergone a free-feeding VFSS that developed postprocedural aspiration pneumonia. Our VFSS findings can be contrasted to those of a prior study where VFSS performed with dogs in lateral recumbency failed to identify any dog with functional LES obstruction compared to 61% of our patients with ME (Figure 5).²⁷ Our findings suggest that this procedure can be performed safely in dogs with ME and esophageal dysphagia to identify dogs with functional LES disorders.

Abnormal relaxation of the LES in response to pharyngeal swallowing is recognized as the key pathophysiologic feature in LES achalasia.^{7-9,22} This highlights the need for evaluation of the LES during active swallowing in order to assess for inappropriate failure of the LES to relax. Several swallows should be evaluated for each food and liquid consistency, because LES achalasia may not occur with every swallow. Common features of LES achalasia in people undergoing dynamic imaging include ME, LES “bird beak,” lack of primary peristalsis, and a persistent contrast column above the LES.⁹ As a result of this functional obstruction, the esophageal body can lose tone and dilate, retaining both ingesta and oral or respiratory secretions. In our study, these clinical features also were identified in dogs with LES-AS. Interestingly, though ME commonly was identified, 5 of 19 dogs with LES-AS had objectively and subjectively normal esophageal diameter compared to controls. As such, the absence of ME does not rule out LES-AS in dogs and should be considered as a differential diagnosis in dogs with signs of esophageal dysphagia despite the absence of ME. Serial evaluation of these dogs would be warranted to determine if they progress to development of ME. In our study, subjective and objective assessment of ME in dogs compared to healthy dogs had perfect agreement, suggesting that objective calculations are not always necessary to confirm a diagnosis of ME and objective measurement may be reserved for cases in which ME may be considered borderline. However, the lack of

a gold standard measurement for ME is a limitation in calculating specificity for dogs in our study. A baseline fluid line and “bird beak” frequently were identified in patients with LES-AS and were absent in normal dogs and in this population of dogs with other forms of ME. This observation may suggest that fluid line and “bird beak” could discriminate LES-AS from forms ME, but further study is needed. Two cases of confirmed MG were identified in our population: 1 with LES-AS and the other with diffuse esophageal hypomotility without LES obstruction. A previously published case report performed manometry to confirm functional LES obstruction in a Pug with seronegative MG.²⁴ This suggests that functional obstruction of the LES may be a feature of ME in some, but not all patients with MG. However, too little data exists to speculate on the pathophysiology of ME in these patients.

In humans, LES achalasia represents a family of syndromes grouped by variations in esophageal contractility rather than a single disorder characterized by a sole discrete phenotype.⁷⁻⁹ The subtype of LES-AS in people does not determine candidacy for targeted intervention. It may, however, be used to help determine which means of LES disruption is selected (eg, pneumatic dilatation versus botulinum toxin A injections or surgery) because different subtypes may have different response rates.^{8,16,17,22} Three phenotypes were characterized in our canine animal population, which share similarities to the syndromes described in people.⁷⁻⁹ As in people, type 1 was considered end-stage with the absence of esophageal motility and the presence of esophageal dilatation and minimal gastric filling. Type 2 was characterized by esophageal hypomotility. Retention of some esophageal tone and biophysical processes allowed for improved esophageal emptying and gastric filling compared to type 1, especially gravity-dependent increases in hydrostatic pressure. Type 3 LES-AS demonstrated impaired distal esophageal and LES relaxation in response to a food bolus resulting in esophageal bolus retention despite vigorous esophageal contraction upstream to the LES.⁸ Like HRM, VFSS may result in a false-positive diagnosis for patients with a distal mechanical LES obstruction (ie, pseudoachalasia). In our study, 1 dog initially classified as having type 3 achalasia was later identified to have a circumferential LES adenocarcinoma, resulting in a mechanical LES obstruction. Interestingly, this dog also was the only dog with detectable reflux compared to 8 of 20 asymptomatic healthy controls. Although speculative, pseudoachalasia may have resulted in an LES with a fixed diameter that simultaneously impeded gastric filling and permitted small volumes of spontaneous reflux. This form of pseudoachalasia previously has been identified in humans²⁸ and emphasizes the need for adjunctive diagnostic tests such as esophagoscopy to evaluate for occult mechanical obstructions that may mimic LES-AS before targeted intervention.²²

Given the clinical importance of ME and esophageal dysphagia in dogs, it is critical that patients that may be responsive to targeted treatment be accurately identified. For this reason, VFSS images were interpreted by a blinded, independent MD reviewer who participated in the international working group for disorders of gastrointestinal motility and function to develop the consensus statement on achalasia syndromes in humans. Our goal was to adapt these diagnostic criteria and gauge the ease by which they could be applied to clinically

affected dogs.¹⁶ Agreement between the MU group and the MD reviewer was perfect for 6 of 17 VFSS parameters, nearly perfect for 5 of 17 parameters, substantial for 4 of 17 parameters, moderate for 1 of 17 parameters, and fair for 1 of 17 parameters²⁹ (Table 4). These findings suggest that, with training, these criteria could be applied by others to detect the subpopulation of dogs affected by LES-AS, thus enhancing the ability of veterinarians to detect patients that may respond to targeted intervention. Only fair agreement, however, was reached for the frequency of abnormal swallow events (ie, failure of the LES to relax in response to pharyngeal swallow). This finding supports our earlier recommendation that multiple swallow events should be evaluated because, depending on the LES-AS subtype and observer, aberrant swallowing events may appear variably frequent. However, this did not impact the agreement between the MU panel and the independent reviewer (C.P.G.) for the final diagnosis of LES-AS for any dog.

5 | CONCLUSIONS

Because of its inherent limitations, HRM for diagnosis of LES-AS does not currently have substantial clinical utility outside a few veterinary research centers or tertiary care facilities. The morbidity and mortality of ME in dogs necessitated developing a more accessible diagnostic test for identifying dogs that may respond to targeted intervention. Compared to HRM, VFSS is relatively accessible, inexpensive, and, with training, easy to perform. In keeping with our stated objective, we demonstrated that functional LES obstructions (LES-AS) can be identified by VFSS. We also have demonstrated the VFSS could identify discrete achalasia syndromes as appreciated in humans. Interpretation will require high-quality diagnostic studies and practice, with the guidelines developed herein highlighting important features of LES-AS. Identifying this previously unrecognized animal population allows future exploration of treatments focusing on relieving functional obstruction of the LES to decrease morbidity and mortality associated with ME and esophageal dysphagia in dogs.

ACKNOWLEDGMENTS

Dr. Grobman's salary is supported by the Boehringer Ingelheim Resident-Postdoctoral Scholar Program.

CONFLICT OF INTEREST DECLARATION

The United States Patent No. 9107385 for the free-feeding kennels is held by the Curators of the University of Missouri, listing as inventors: Teresa Lever, Joan Coates, Mitchell Allen, and Laila Al-Khashti.

OFF-LABEL ANTIMICROBIAL DECLARATION

Authors declare no off-label use of antimicrobials.

INSTITUTIONAL ANIMAL CARE AND USE COMMITTEE (IACUC) OR OTHER APPROVAL DECLARATION

Authors declare no IACUC or other approval was needed.

HUMAN ETHICS APPROVAL DECLARATION

Authors declare human ethics approval was not needed for this study.

ORCID

Megan E. Grobman  <https://orcid.org/0000-0002-7695-5562>

Carol R. Reinero  <https://orcid.org/0000-0002-6382-5582>

REFERENCES

- McBrearty AR, Ramsey IK, Courcier EA, et al. Clinical factors associated with death before discharge and overall survival time in dogs with generalized megaesophagus. *J Am Vet Med Assoc.* 2011;238:1622-1628.
- Mace S, Shelton G, Eddlestone S. Megaesophagus. *Compend Contin Educ Vet.* 2012;34:E1.
- Harvey C, O'Brien J, Durie V, Miller DJ, Veenema R. Megaesophagus in the dog: a clinical survey of 79 cases. *J Am Vet Med Assoc.* 1974;165:443-446.
- Mears EA, Jenkins CC. Canine and feline megaesophagus. *Compend Contin Educ Vet.* 1997;19:313-326.
- Shelton GD. Myasthenia gravis and congenital myasthenic syndromes in dogs and cats: a history and mini-review. *Neuromuscul Disord.* 2016;26:331-334.
- Gaynor A, Shofer F, Washabau R. Risk factors for acquired megaesophagus in dogs. *J Am Vet Med Assoc.* 1997;211:1406-1412.
- Gyawali C. Achalasia: new perspectives on an old disease. *J Neurogastroenterol Motil.* 2016;28:4-11.
- Kahrilas PJ, Boeckxstaens G. The spectrum of achalasia: lessons from studies of pathophysiology and high-resolution manometry. *Gastroenterology.* 2013;145:954-965.
- Pohl D, Tutuian R. Achalasia: an overview of diagnosis and treatment. *J Gastrointest Liver Dis.* 2007;16:297.
- Furuzawa-Carballeda J, Torres-Landa S, Valdovinos M, et al. New insights into the pathophysiology of achalasia and implications for future treatment. *World J Gastroenterol.* 2016;22:7892-7907.
- Kempf J, Beckmann K, Kook P. Achalasia-like disease with esophageal pressurization in a myasthenic dog. *J Vet Intern Med.* 2014;28:661-665.
- Osborne C, Clifford D, Jessen C. Hereditary esophageal achalasia in dogs. *J Am Vet Med Assoc.* 1967;151:572-581.
- Palmer C. Achalasia or cardiospasm in great Dane puppies. *Vet Med Small Anim Clin.* 1968;63:574-576.
- Quintavalla F, Menozzi A, Pozzoli C, et al. Sildenafil improves clinical signs and radiographic features in dogs with congenital idiopathic megaesophagus: a randomised controlled trial. *Vet Rec.* 2017;180:404-404.
- Harris R, Grobman M, Allen M, et al. Standardization of a videofluoroscopic swallow study protocol to investigate dysphagia in dogs. *J Vet Intern Med.* 2017;31:383-393.
- Kahrilas PJ, Bredenoord AJ, Fox M, et al. Advances in the management of oesophageal motility disorders in the era of high-resolution manometry: a focus on achalasia syndromes. *Nat Rev Gastroenterol Hepatol.* 2018;15:323.
- Boeckxstaens G, Zaninotto G. Achalasia and esophago-gastric junction outflow obstruction: focus on the subtypes. *J Neurogastroenterol Motil.* 2012;24:27-31.
- Neyaz Z, Gupta M, Ghoshal UC. How to perform and interpret timed barium esophagogram. *J Neurogastroenterol Motil.* 2013;19:251-256.
- Jung DH, Park H. Is gastroesophageal reflux disease and achalasia coincident or not? *J Neurogastroenterol Motil.* 2017;23:5-8.
- Gyawali C, Bredenoord A, Conklin J, et al. Evaluation of esophageal motor function in clinical practice. *J Neurogastroenterol Motil.* 2013;25:99-133.
- El-Takli I, O'Brien P, Paterson W. Clinical diagnosis of achalasia: how reliable is the barium x-ray? *Canadian J Gastroenterol Hepatol.* 2006;20:335-337.
- Kahrilas PJ, Pandolfino JE. Treatments for achalasia in 2017: how to choose among them. *Curr Opin Gastroenterol.* 2017;33:270-276.
- Ullal TV, Kass PH, Conklin JL, Belafsky PC, Marks SL. High-resolution manometric evaluation of the effects of cisapride on the esophagus during administration of solid and liquid boluses in awake healthy dogs. *Am J Vet Res.* 2016;77:818-827.
- Kempf J, Lewis F, Reusch CE, Kook PH. High-resolution manometric evaluation of the effects of cisapride and metoclopramide hydrochloride administered orally on lower esophageal sphincter pressure in awake dogs. *Am J Vet Res.* 2014;75:361-366.
- Kempf J, Heinrich H, Reusch CE, Kook PH. Evaluation of esophageal high-resolution manometry in awake and sedated dogs. *Am J Vet Res.* 2013;74:895-900.
- Pollard RE. Imaging evaluation of dogs and cats with dysphagia. *ISRN Vet Sci.* 2012;2012:1-15.
- Pollard RE, Marks SL, Cheney DM, Bonadio CM. Diagnostic outcome of contrast videofluoroscopic swallowing studies in 216 dysphagic dogs. *Vet Radiol Ultrasound.* 2017;58:373-380.
- Martinez C, Targarona EM, Sainz S, et al. Pseudoachalasia: a diagnosis to consider in the assessment of dysphagia. *Gastroenterol Hepatol.* 2000;23:14-15.
- Viera AJ, Garrett JM. Understanding interobserver agreement: the kappa statistic. *Fam Med.* 2005;37:360-363.

How to cite this article: Grobman ME, Schachtel J, Gyawali CP, Lever TE, Reinero CR. Videofluoroscopic swallow study features of lower esophageal sphincter achalasia-like syndrome in dogs. *J Vet Intern Med.* 2019;33:1954-1963. <https://doi.org/10.1111/jvim.15578>