

Review Article

Ear, nose and throat (ENT) involvement in zoonotic diseases: a systematic review

Bruno Galletti¹, Valentina K. Mannella¹, Roberto Santoro¹, Alfonso J. Rodriguez-Morales^{2,3} Francesco Freni¹, Claudio Galletti⁴, Francesco Galletti¹, Antonio Cascio^{3,5}

¹ Otorhinolaryngology Unit Department of Surgical Specialities, University Hospital G. Martino, Messina, Italy

² Faculty of Health Sciences, Universidad Tecnológica de Pereira, Pereira, Risaralda, Colombia. Comité de Zoonosis y Fiebres Hemorrágicas, Asociación Colombiana de Infectología (ACIN)

³ Working Group on Zoonoses, International Society for Chemotherapy

⁴ Department of Neurosciences, Psychiatric and Anesthesiological Sciences, University of Messina, Italy

⁵ Tropical and Parasitological Diseases Unit, Department of Human Pathology, Policlinico G. Martino, Messina, Italy

Abstract

Introduction: Zoonoses are infections transmitted from animal to man, either directly (through direct contact or contact with animal products) or indirectly (through an intermediate vector, such as an arthropod). The causative agents include bacteria, parasites, viruses, and fungi. The purpose of this review is to make an accurate examination of all zoonotic diseases that can be responsible of ear, nose, and throat (ENT) involvement.

Methodology: A PubMed search was performed combining the terms (otorhinolaryngology OR rhinology OR laryngology OR otology OR mastoiditis OR otitis OR sinusitis OR laryngitis OR rhinitis OR pharyngitis OR epiglottitis OR dysphonia OR ear OR larynx OR nose OR pharynx) with each one of the etiological agents of zoonoses for the period between January 1997 and August 2012 without language restrictions.

Results: A total of 164 articles were selected and examined. Larynx was the most commonly involved ENT organ, followed by oral cavity, pharynx, and neck. Bacteria were the most representative microorganisms involved. Nose and major salivary glands were affected most frequently by protozoa; paranasal sinus, oral cavity, ear, neck, nerves and upper airway by bacteria; and larynx by fungi.

Conclusions: ENT symptoms and signs may be present in many zoonotic diseases, some of which are also present in industrialized countries. Most zoonotic diseases are not commonly encountered by ENT specialists. Appreciation of the possible occurrence of these diseases is important for a correct microbiological approach, which often requires special culture media and diagnostic techniques.

Key words: ENT; zoonoses; otorhinolaryngology

J Infect Dev Ctries 2014; 8(1):017-023. doi:10.3855/jidc.4206

(Received 03 September 2013 – Accepted 02 December 2013)

Copyright © 2014 Galletti *et al.* This is an open-access article distributed under the Creative Commons Attribution License, which permits unrestricted use, distribution, and reproduction in any medium, provided the original work is properly cited.

Introduction

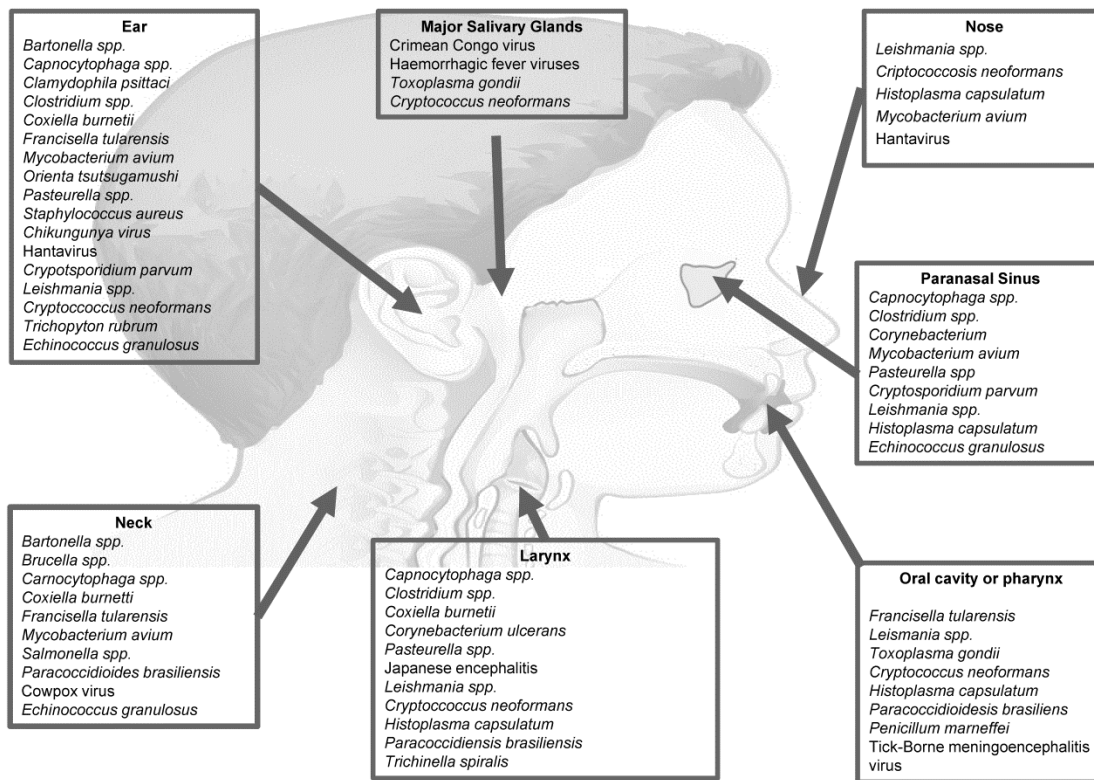
Although zoonotic infections are a major burden worldwide – both in terms of immediate and long-term morbidity and mortality [1,2] and in terms of socio-economical, ecological, and political impact [3] – scientific and public health interest and funding for these diseases remain relatively minor and inadequate [4]. Zoonotic infections are defined, in general, as infections transmitted from animal to man (and, less frequently, vice versa), either directly (through direct contact or contact with animal products) or indirectly (through an intermediate vector, such as an arthropod) [5]. Zoonotic disease may affect ENT districts. Unfortunately, literature is often limited to single case reports from different countries and does not allow

adequate appreciation of the problem. Otorhinolaryngologists often lack in-depth knowledge of zoonotic diseases, which complicates etiological identification and treatment and control strategies. In the present review, we summarized scientific publications on zoonotic diseases that directly or indirectly involved the ENT area.

Bibliographical research

A PubMed Medline search for human cases of zoonotic diseases involving head and neck areas was performed combining the terms (otorhinolaryngology OR rhinology OR laryngology OR otology OR mastoiditis OR otitis OR sinusitis OR laryngitis OR rhinitis OR pharyngitis OR epiglottitis OR dysphonia

Figure 1. Anatomical localization of zoonotic agents at ENT region.



OR ear OR larynx OR nose OR pharynx) with each one of the etiological agents of zoonoses indicated in Tables 1-4 for the period between January 1997 and August 2012 without language restrictions. A study was considered eligible for inclusion in the systematic review if it reported data on patients with zoonotic diseases who presented ENT signs and/or symptoms. Duplicate publications or papers not reporting clinical cases were excluded. The inclusion criteria were applied and the data were extracted by one reviewer and then checked by a second reviewer.

Results

After a scrupulous analysis, 164 papers were considered and examined. Most of the papers are listed on the basis of the etiological agent in Tables 1-4, and a brief note was reported for each paper if it was considered relevant.

Nasal involvement was found in 24 papers. Most of the studies reported cases of leishmaniasis and fungal infections (Tables 3 and 4); bacterial diseases were reported in two articles, and one case each of Hantavirus and echinococcosis was also reported (Tables 2 and 4). Common symptoms were nose bleeding and other symptoms resulting from inflammatory pseudotumor (Figure 1).

Paranasal sinus involvement, commonly with sinusitis symptoms, was described in 13 articles. The etiological agents in seven articles were bacteria; protozoa, fungi, and helminths were each the etiological agents in two articles (Figure 1).

Involvement of the oral cavity or pharynx was found in 41 papers. Bacteria (in most of the cases, *Francisella tularensis* reported from Turkey) were detected as agents of these conditions in 25 articles (Table 1), followed by protozoa (eight articles), fungi (seven articles), and viruses. Pharyngitis, tonsillitis, pharyngotonsillitis, and dysphagia were found frequently, often associated with lymphadenopathy and fever (Figure 1).

Involvement of the larynx was described in 39 articles. Bacteria were the etiologic agents in eight articles, the Japanese encephalitis virus was the etiologic agent in one article, *Leishmania* spp in 11 articles (Table 4), fungi in 18 articles (Table 3), and helminths in one article (Table 4). Symptoms of larynx involvement were epiglottitis, dysphonia, or dyspnea (Figure 1).

Thirty-five articles documented ear involvement. Bacteria were identified in 21 articles (Table 1), viruses in four (Table 2), protozoa in one (Table 4), fungi in four (Table 3), and helminths in one article

(Table 4). Otitis media, otomastoiditis, sensorineural loss of hearing, and vestibular dysfunction were the most frequently reported conditions (Figure 1).

Involvement of the neck was found in 33 articles. Bacteria were identified in 29 articles, fungi in two articles, viruses (Cowpox virus) in one article, and helminths (*Echinococcus granulosus*) in one article. The most frequent manifestation was lymphadenopathy. Rarely, retropharyngeal or neck abscess and necrotizing fasciitis were found (Figure 1).

Nerve disease was described in eight articles. The most frequently involved agents were bacteria: *Bartonella henselae*, *Borrelia burgdorferi*, and *Campylobacter* spp. in one case (Table 1), West Nile Virus in one case (Table 2), and *Leishmania* spp. were

detected in one case (Table 4). The most frequent manifestation was facial or laryngeal nerve paralysis.

An involvement of the total upper airway was found in three papers, each one reporting cases of infection with *Clostridium botulinum*, *Mycobacterium avium*, and *Corynebacterium ulcerans* (Table 1). Only one article documented an involvement of facial tissue in the course of helminthiasis (dirofilariasis) (Table 4).

Involvement of major salivary glands was found in four articles. Etiological agents were in one case Crimean–Congo haemorrhagic fever virus, in two cases *Toxoplasma gondii*, and in one case *Cryptococcus neoformans*. Symptoms were parotitis or parotid mass (Figure 1).

Table 1. Bacterial agents of zoonoses and ENT manifestations

Bacteria	[References] ENT manifestations and notes
<i>Bartonella</i> spp.	[6] Atypical presentations of cat scratch disease in the head and neck; cat scratch disease presenting as acute mastoiditis; neck abscess secondary to cat-scratch disease; traveler's fever, cervical adenomegaly, Brazilian patient returning from South Africa; cat scratch disease presenting with peripheral facial nerve paralysis.
<i>Brucella</i> spp.	[7] Severe pharyngitis, 2 cases; [8] isolated cervical lymphadenopathy; [9,10] infection of a branchial cyst; [11] paravertebral abscess, torticollis; [12] Brucellar spinal epidural abscess compressing the retropharyngeal space.
<i>Campylobacter</i> spp.	[13] Multiple cranial neuropathy; [14] oropharyngeal palsy with nasal voice.
<i>Capnocytophaga</i> spp.	[15] Sudden sensorineural hearing loss; [16] <i>C. sputigena</i> primary iliopsoas abscess secondary to haematogenous spread from a palatal fistula and chronic sinusitis due to previous treatment for nasopharyngeal carcinoma; [17] epiglottitis and necrotizing fasciitis (complication of infectious mononucleosis); [18] retropharyngeal abscess, 2 cases.
<i>Chlamydomyxa psittaci</i>	[19] Sudden sensorineural hearing loss.
<i>Clostridium</i> spp.	[20] Botulism and dysphagia; [21] diplopia with tonsillitis; [22] infant botulism, retrospective study, 60 cases, infant, Brazil; [23] otogenic tetanus; [24] otogenic tetanus in children; [25] <i>C. perfringens</i> , sphenoid sinusitis; [26] <i>C. perfringens</i> , fatal acute necrotizing tonsillitis; [27] brain abscess secondary to acute otomastoiditis; [18] <i>C. glycolicum</i> , otogenic brain abscesses.
<i>Coxiella burnetii</i>	[28] Otological manifestations; fever, bilateral tonsillitis, spiking fever, lymphadenopathy, and laryngitis.
<i>Corynebacterium ulcerans</i>	[29] Diphtheria, France, Japan, the Netherlands, Indiana, USA; fatal case of necrotizing sinusitis, Germany; [30] laryngopharyngitis, Switzerland.
<i>Francisella tularensis</i>	[31] Oropharyngeal, Serbia; [32] parapharyngeal abscess, Turkey; outbreak of oropharyngeal tularemia Turkey; neck mass, 33 patients; oropharyngeal tularemia, Germany; [33] otitis media, suppurative lymphadenopathy, retropharyngeal abscess, Germany; otitis media, Finland; water-borne outbreak of oropharyngeal and glandular tularemia, Georgia; 12-case outbreak, consumption of camel meat, Jordan.
<i>Mycobacterium avium</i> , <i>M. marinum</i> , <i>M. malmoense</i>	[34] <i>M. avium-intracellulare</i> , sinusitis, 8 patients; [35] <i>M. avium-intracellulare</i> sinusitis; <i>M. avium intracellulare</i> otomastoiditis; <i>M. avium</i> complex, cervical lymphadenitis, 8 cases; <i>M. avium intracellulare</i> , pseudotumor of the anterior nasal cavity; disseminated <i>M. avium</i> infection, immunocompetent aged patient; nasal fish tank granuloma, epistaxis; <i>M. malmoense</i> , laryngitis.
<i>Orientia tsutsugamushi</i>	[36] Otagia and eschar in the external auditory canal in scrub typhus complicated by acute respiratory distress syndrome and multiple organ failure.
<i>Pasteurella</i> spp.	[37] <i>P. multocida</i> , fatal case, epiglottitis; <i>P. haemolytica</i> , croup; contamination of post-endoscopic sinus surgery sinus cavities with <i>P. multocida</i> , Canada; invasive <i>P. multocida</i> sinusitis, renal transplant patient; <i>P. multocida</i> , chronic purulent otorrhoea, meningitis transmitted by a dog that frequently licked his ear; <i>P. multocida</i> , acute bacterial meningitis, otitis media.
<i>Salmonella</i> spp. (excluding <i>S. typhi</i>)	[38] <i>S. lomita</i> retropharyngeal abscess; neck abscess, diabetes mellitus, 2 patients; <i>S. senftenberg</i> , otitis media.
<i>Staphylococcus aureus</i> (clearly associated to animal reservoir)	[39] Destructive otomastoiditis by MRSA from porcine origin, Belgium.

Table 2. Viral agents of zoonoses and ENT manifestations

Viruses	[References] ENT manifestations and notes
Chikungunya virus	[40] Sudden sensorineural hearing loss, India.
Cowpox virus	[41] A case of facial cellulitis and necrotizing lymphadenitis (inoculation in the respiratory epithelium of the nose), Sweden.
Crimean–Congo haemorrhagic fever virus	[42] Transient evoked otoacoustic emission test; parotitis.
Hantaviruses	[43] Delayed sensorineural hearing loss; nose bleeding, acute renal failure.
Japanese encephalitis	Cricopharyngeal dysphagia in a Japanese encephalitis survivor, Republic of China.
Tick-borne meningoencephalitis virus.	Symptomatic palatal myoclonus with ear click after tick-borne meningoencephalitis, Poland.
West Nile Virus	[44] West Nile Virus induced vocal fold paralysis.

Table 3. Parasite agents of zoonoses and ENT manifestations

Parasite groups	[References] ENT manifestations and notes
Protozoa	
<i>Cryptosporidium parvum</i>	[45] Sinusitis and otitis, five cases, AIDS, USA.
<i>Leishmania</i> spp.	Mucosal leishmaniasis, 140 patients, Brazil. [46] Recidivant laryngeal leishmaniasis, immunocompetent, corticosteroids. <i>Leishmania (Viannia) braziliensis</i> complex, Argentina. [47] A chronic mutilating rhinopathy, India; laryngeal involvement, post kala-azar dermal leishmaniasis 3 cases, India; isolated laryngeal leishmaniasis in an immunocompetent patient in India; ulcerative post-kala azar mucosal leishmaniasis masquerading as a carcinoma, Nepal; rhinophymous leishmaniasis. Pakistan; auricular leishmaniasis mimicking squamous cell carcinoma. Iran; leishmaniasis of the auricle mimicking carcinoma, Lebanon; endonasal, <i>L. infantum</i> MON-80, Tunisia; [48] immunocompromised patient, ulcerated nasolabial skin lesion, Greece; [49] <i>L. infantum</i> MON-111 endonasal leishmaniasis, 2 cases, Italy; [50] laryngeal leishmaniasis, immunocompetent, Malta; nasal cavity, UK; [51] laryngeal leishmaniasis, three cases, Spain; acute tonsillitis, immunocompetent, Greece; laryngitis, long term steroid inhaler use, UK; systemic leishmaniasis involving the nose, Belgium; epiglottis involvement in a visceral leishmaniasis, France; [52] nasal, AIDS, Spain; tongue (history of treated laryngeal leishmaniasis), AIDS, Spain; [53] oral, HIV-infected, Italy; old-world leishmaniasis of the auricle, Greece; [54] lip, kidney transplant patient, Italy; [55] laryngitis, vocal cord palsy, Switzerland; mucosal <i>L. infantum</i> leishmaniasis, France; [56] mucosal <i>L. infantum</i> , Germany; laryngitis, Denmark.
<i>Toxoplasma gondii</i>	[57] Lymphadenitis presenting as a parotid mass, 2 cases; unilateral facial swelling, extranodular involvement.
Helminths	
<i>Trichinella spiralis</i>	<i>Trichinella spiralis</i> , laryngeal carcinoma.
<i>Echinococcus granulosus</i>	Maxillary sinus; neck; otogenic brain absces.
<i>Dirofilaria</i> spp.	Paranasal sinuses; facial mass.

Table 4. Fungal agents of zoonoses and ENT manifestations

Fungi	[References] ENT manifestations and notes
<i>Cryptococcus neoformans</i>	[58] Tongue, Malaysia; retropharyngeal abscess; laryngitis, AIDS; vocal cord cyst; laryngitis simulating laryngeal carcinoma; colonization of a voice prosthesis; auricular cryptococcosis as the initial presentation of AIDS, USA; nasal cutaneous cryptococcosis AIDS; parotid gland; <i>C. laurentii</i> , oropharynx, erythroleukaemia, Belgium; otitis and cholesteatoma; meningitis, vestibular dysfunction; isolation of <i>C. magnus</i> and <i>C. chernovii</i> from nasal cavities of pediatric patients with acute lymphoblastic leukemia, Kuwait.
<i>Histoplasma capsulatum</i>	[59] Sinusitis, AIDS; sinusitis, chronic lymphocytic leukemia; oropharyngeal, Brazil, 11 cases (5 AIDS); oral, HIV-negative patient, Brazil; oral histoplasmosis, 31 cases (21 AIDS), Argentina; nasal septum, AIDS; nasal, immunocompetent, India; laryngitis, AIDS, Argentina; epiglottic histoplasmosis.
<i>Paracoccidioides brasiliensis</i>	[60] Imported glottic paracoccidioidomycosis, France; laryngeal paracoccidioidomycosis masquerading as chronic obstructive lung disease, Venezuela; cutaneous-mucosal paracoccidioidomycosis, French Guiana; laryngitis mimicking carcinoma.
<i>Penicillium marneffeii</i>	Pharyngeal tumor, AIDS, China.
<i>Trichophyton</i> spp.	<i>Trichophyton rubrum</i> , external auditory meatus.

Cases occurring in HIV-infected patients were reported in leishmaniasis, cryptococcosis, histoplasmosis, and penicilliosis. Other immunosuppressive factors (malignancy, leukemia, solid organ transplant, steroids) were found in patients with cryptococcosis, leishmaniasis, pasteurellosis, histoplasmosis, penicilliosis, and trichinellosis.

Five papers described cases occurring in travelers: two cases of leishmaniasis (Table 4), and a case each of paracoccidioidomycosis, histoplasmosis (Table 3), and bartonellosis (Table 1). Some cases were complicated by severe symptoms and death. Some papers reported cases in which the zoonotic lesions could have been misdiagnosed as cancer. These included three cases of leishmaniasis (Table 4), a case of laryngeal cryptococcosis (Table 3), two cases of laryngeal paracoccidioidomycosis (Table 3), and one case of toxoplasmosis lymphadenitis presenting as a parotid mass (Table 4).

Discussion

On the basis of the present review, the larynx seem to be the most common ENT organ involved in zoonotic diseases, followed by the oral cavity, pharynx, and neck. Bacteria were the most frequently involved agents [6-39]. The nose and major salivary glands seemed to be affected most frequently by protozoa [47-49]; paranasal sinus, oral cavity, ear, neck, nerves, and upper airway were most affected by bacteria, and the larynx was most affected by fungi [58-60].

Of all the microorganisms considered, some have a worldwide distribution, while others are restricted to certain geographic areas. Mucosal leishmaniasis is uncommon outside of Central and South America. Mucosal leishmaniasis contracted in southern Europe mostly affected adult males, of which half were immunodeficient. Clinical polymorphism makes diagnosis difficult.

It is important to note that the ENT manifestations in some zoonoses can be an integral part of the disease – for example, American mucocutaneous leishmaniasis (ACL) [46-56] and botulism – while in others, such as paracoccidioidomycosis or tularemia, ENT involvement is only occasionally found. In addition, many diseases that usually do not produce ENT involvement (such as histoplasmosis, leishmaniasis of the Mediterranean region, and cryptococcosis) can produce it in immunosuppressed patients. Histoplasmosis, an AIDS-defining disease, may present as a disseminated form in which oral lesions are found in 30% to 50% of patients.

The present work shows that ENT symptoms and signs may be present in many zoonotic diseases, some of which are also present in industrialized countries. Most of these diseases are not commonly encountered by ENT specialists who may confuse them occasionally for neoplastic conditions. Appreciation of the possible occurrence of these diseases is important for a correct microbiological approach, which often requires special culture media and diagnostic techniques.

Zoonotic diseases may be difficult to diagnose and can be capable of confusing even the most experienced physicians, especially if they occur in countries where the disease is not endemic. Because there are no common signs and symptoms of zoonotic diseases involving ENT districts, the practicing otorhinolaryngologist, while attending to patients with ENT symptoms not responding to common therapy, should pay particular attention to anamnesis (immunosuppressive therapy; history of at-risk professional and recreational occupations such as hunter, ranger, farmer, and veterinarian; recent travel to endemic regions; particular environment of life of the patients and their partners; and eating habits) and consider the possibility of a zoonotic disease [3,4].

From the dawn of modern medicine, the understanding of infectious disease and how to treat it has been an integral part of the physician's craft in all fields. Undoubtedly, the impact of zoonotic diseases may vary in relationship to the socioeconomic context and to the public health system in different geographic areas. A greater threat exists in developing countries [3], which today is of utmost importance in the context of globalization. The practice of travel medicine with the possibility of imported cases from endemic regions is also of growing concern. Often, because of economic globalization and increased travel and migration (even forced, as occurs with refugees), agents are found in countries different from their source [61]. Because this may cause serious diagnostic difficulties, it is important that physicians from both endemic and non-endemic zones increase their awareness of diseases that have been previously considered to be uncommon in their home countries.

References

1. Christou L (2011) The global burden of bacterial and viral zoonotic infections. *Clin Microbiol Infect* 17: 326-330.
2. Akritidis N (2011) Parasitic, fungal and prion zoonoses: an expanding universe of candidates for human disease. *Clin Microbiol Infect* 17: 331-335.
3. Cascio A, Bosilkovski M, Rodriguez-Morales AJ, Pappas G (2011) The socio-ecology of zoonotic infections. *Clin Microbiol Infect* 17: 336-342.
4. Pappas G, Cascio A, Rodriguez-Morales AJ (2012) The immunology of zoonotic infections. *Clin Dev Immunol* 2012: 208508.
5. Pappas G (2011) Of mice and men: defining, categorizing and understanding the significance of zoonotic infections. *Clin Microbiol Infect* 17: 321-325.
6. Chiu AG, Hecht DA, Prendiville SA, Mesick C, Mikula S, Deeb ZE (2001) Atypical presentations of cat scratch disease in the head and neck. *Otolaryngol Head Neck Surg* 125: 414-416.
7. Zachou K, Papamichalis PA, Dalekos GN (2008) Severe pharyngitis in stockbreeders: an unusual presentation of brucellosis. *Occup Med (Lond)* 58: 305-307.
8. Yilmaz M, Bayazit N, Gurbuzler L, Ercan N, Ceylan A, Bayazit Y (2009) Isolated cervical lymphadenopathy: unusual presentation of localised brucellosis. *Int J Clin Pract* 63: 674-675.
9. Rameh C, Hamdan AL, Uwaydah M, Sabra O, Araj G, Fuleihan N (2007) *Brucella melitensis* infection of a branchial cyst. *Otolaryngol Head Neck Surg* 136: 1023-1024.
10. Apostolova E, Papadopoulos V, Leptidou-Kerestetzki T (2002) Branchial cyst empyema due to *Brucella melitensis* infection as a form of focal Brucellosis. *J Infect* 44: 271.
11. Simsek S, Yigitkanli K, Kazanci A, Belen D, Bavbek M (2007) Medically treated paravertebral Brucella abscess presenting with acute torticollis: case report. *Surg Neurol* 67: 207-210.
12. Pina MA, Ara JR, Modrego PJ, Juyol MC, Capablo JL (1999) Brucellar spinal epidural abscess. *Eur J Neurol* 6: 87-89.
13. Kobori S, Yoshii F, Takahashi H, Takagi S, Funakoshi K (2007) A case of multiple cranial neuropathy after *Campylobacter jejuni* infection. *Rinsho Shinkeigaku* 47: 53-55.
14. Wada Y, Yanagihara C, Nishimura Y, Susuki K (2006) A case of acute oropharyngeal palsy with nasal voice as main symptom. *No To Shinkei* 58: 235-238.
15. Tamura A, Matsunobu T, Kurita A, Shiotani A (2012) Hemophagocytic Syndrome in the Course of Sudden Sensorineural Hearing Loss. *ORL J Otorhinolaryngol Relat Spec* 74: 211-214.
16. Chan JF, Wong SS, Leung SS, Li IW, To KK, Cheng VC, Yuen KY (2010) *Capnocytophaga sputigena* primary iliopsoas abscess. *J Med Microbiol* 59: 1368-1370.
17. Caballero M, Sabater F, Traserra J, Alos L, Bernal-Sprekelsen M (2005) Epiglottitis and necrotizing fasciitis: a life-threatening complication of infectious mononucleosis. *Acta Otolaryngol* 125: 1130-1133.
18. Miyazaki T, Ito Y, Kato M, Akita S, Mizuta K, Miyata H, Kato N, Watanabe K (1998) Retropharyngeal abscess in an adult and an elderly woman. *Kansenshogaku Zasshi* 72: 157-161.
19. Brewis C, McFerran DJ (1997) 'Farmer's ear': sudden sensorineural hearing loss due to Chlamydia psittaci infection. *J Laryngol Otol* 111: 855-857.
20. Mangilli LD, Andrade CR (2007) Botulism and dysphagia. *Pro Fono* 19: 215-222.
21. Viestenz A, Schoerner C, Mayer U (2003) Diplopia with tonsillitis. *Ophthalmologie* 100: 744-746.
22. Anderson TD, Shah UK, Schreiner MS, Jacobs IN (2002) Airway complications of infant botulism: ten-year experience with 60 cases. *Otolaryngol Head Neck Surg* 126: 234-239.
23. Sharma A, Kapoor S (2006) Relapse in a child with otogenic tetanus. *Trop Doct* 36: 56-57.
24. Bogomol'skii MR, Iakushenkova AP, Ozhan S, Setkhi S (2002) Otogenic tetanus in children. *Vestn Otorinolaringol*: 53-54.
25. Rosenblum BN, Gutwein M, Bartell MF (2001) Sphenoid sinusitis caused by *Clostridium perfringens*. *Otolaryngol Head Neck Surg* 125: 101-102.
26. Gerber JE (2001) Acute necrotizing bacterial tonsillitis with *Clostridium perfringens*. *Am J Forensic Med Pathol* 22: 177-179.
27. Jimenez-Mejias ME, Del Nozal M, Becceril B, Pichardo C, Polaina M, Arroyo A (2000) Brain abscess caused by *Clostridium* sp. secondary to acute otomastoiditis. *J Infect* 40: 294-295.
28. Upile T, Jerjes W, Mahil J (2008) Q fever-related otological manifestations following chronic exposure to products of conception? *Br J Dermatol* 158: 1389.
29. Aaron L, Heurtebise F, Bachelier MN, Guimard Y (2006) Pseudomembranous diphtheria caused by *Corynebacterium ulcerans*. *Rev Med Interne* 27: 333-335.
30. Kaufmann D, Ott P, Ruegg C (2002) Laryngopharyngitis by *Corynebacterium ulcerans*. *Infection* 30: 168-170.
31. Djordjevic-Spasic M, Potkonjak A, Kostic V, Lako B, Spasic Z (2011) Oropharyngeal tularemia in father and son after consumption of under-cooked rabbit meat. *Scand J Infect Dis* 43: 977-981.
32. Koc S, Gurbuzler L, Yaman H, Eyibilen A, Salman N, Ekici A (2012) Tularaemia presenting as parapharyngeal abscess: case presentation. *J Laryngol Otol* 126: 535-537.
33. Gurkov R, Kissner U, Spletstosser W, Hogardt M, Krause E (2009) Tularaemia of middle ear with suppurative lymphadenopathy and retropharyngeal abscess. *J Laryngol Otol* 123: 1252-1257.
34. Suh JD, Ramakrishnan VR, Tajudeen B, Reger C, Kennedy DW, Chiu AG (2011) Identification and treatment of nontuberculous Mycobacterium sinusitis. *Am J Rhinol Allergy* 25: 421-424.
35. Nabi S, Marglani OA, Javer AR (2010) *Mycobacterium avium*-intracellulare Sinusitis. *J Otolaryngol Head Neck Surg* 39: E51-55.
36. Lee BJ, Chen CY, Hu SY, Tsan YT, Lin TC, Wang LM (2011) Otagia and eschar in the external auditory canal in scrub typhus complicated by acute respiratory distress syndrome and multiple organ failure. *BMC Infect Dis* 11: 79.
37. O'Connell K, Fennell J, Callaghan J, Rowaiye B, Cormican M (2009) A fatal case of *Pasteurella multocida* epiglottitis. *Ir J Med Sci* 178: 541-542.
38. Su FH, Chen PT, Chiu YC, Chen JW (2003) Salmonella retropharyngeal abscess in a child: case report and literature review. *Pediatr Infect Dis J* 22: 833-836.
39. Van Hoecke H, Piette A, De Leenheer E, Lagasse N, Struelens M, Verschraegen G, Dhooge I (2009) Destructive otomastoiditis by MRSA from porcine origin. *Laryngoscope* 119: 137-140.

40. Bhavana K, Tyagi I, Kapila RK (2008) Chikungunya virus induced sudden sensorineural hearing loss. *Int J Pediatr Otorhinolaryngol* 72: 257-259.
41. Pahlitzsch R, Hammarin AL, Widell A (2006) A case of facial cellulitis and necrotizing lymphadenitis due to cowpox virus infection. *Clin Infect Dis* 43: 737-742.
42. Engin A, Yildirim A, Kunt T, Bakir M, Dokmetas I, Ozdemir L (2008) Clinical investigation of the transient evoked otoacoustic emission test in Crimean-Congo hemorrhagic fever. *Int J Infect Dis* 12: 162-165.
43. Javer AR, Elliott HF, Longridge NS (1998) Hantavirus infection: a possible cause of delayed sensorineural hearing loss. *Otolaryngol Head Neck Surg* 118: 697-701.
44. Steele NP, Myssiorek D (2006) West Nile virus induced vocal fold paralysis. *Laryngoscope* 116: 494-496.
45. Dunand VA, Hammer SM, Rossi R, Poulin M, Albrecht MA, Doweiko JP, DeGirolami PC, Coakley E, Piessens E, Wanke CA (1997) Parasitic sinusitis and otitis in patients infected with human immunodeficiency virus: report of five cases and review. *Clin Infect Dis* 25: 267-272.
46. Casero R, Laconte L, Fraenza L, Iglesias N, Quinteros Greco C, Villablanca M (2010) Recidivant laryngeal leishmaniasis: an unusual case in an immunocompetent patient treated with corticosteroids. *Rev Argent Microbiol* 42: 118-121.
47. Karimbil SK, Kumari S, Celine MI, Joy A (2010) A chronic mutilating rhinopathy with a delayed diagnosis of mucocutaneous leishmaniasis. *Int J Dermatol* 49: 426-429.
48. Prokopakis EP, Panagiotaki IE, Papadakis IA, Vardouniotis AS, Lagoudianakis GM, Velegrakis GA (2010) Immunocompromised patient with an ulcerated nasolabial skin lesion. *BMJ* 340: c1444.
49. Pau M, Atzori L, Aste N (2009) Two cases of primary endonasal leishmaniasis in Sardinia (Italy). *Dermatol Online J* 15: 5.
50. Fsadni C, Fsadni P, Piscopo T, Mallia Azzopardi C (2007) Laryngeal leishmaniasis in Malta. *J Infect* 54: e61-63.
51. Diaz Sastre MA, Padilla Parrado M, Morales Puebla JM, Jimenez Antolin JA, Caro Garcia MA, Chacon Martinez J, Menendez Loras LM, Orradre Romeo JL (2007) [Laryngeal leishmaniasis]. *An Otorrinolaringol Ibero Am* 34: 17-25.
52. Grasa JM, Lorente J, Crego F, Naches S, Subirana FX, Calderon JR, Pollan C, Encarnacion LF, Quesada P (2000) [Nasal leishmaniasis in an HIV-positive patient]. *Acta Otorrinolaringol Esp* 51: 169-173.
53. Cascio A, Antinori S, Campisi G, Mancuso S (2000) Oral leishmaniasis in an HIV-infected patient. *Eur J Clin Microbiol Infect Dis* 19: 651-653.
54. Antinori S, Cascio A, Parravicini C, Bianchi R, Corbellino M (2008) Leishmaniasis among organ transplant recipients. *Lancet Infect Dis* 8: 191-199.
55. Schroeder D, Foguena AK, Cometta A, Greub G, Cavassini M (2010) A 48-year-old man with laryngeal mass and vocal cord palsy. *Clin Infect Dis* 50: 1680-1631.
56. Richter J, Hanus I, Haussinger D, Loscher T, Harms G (2011) Mucosal *Leishmania infantum* infection. *Parasitol Res* 109: 959-962.
57. Shashy RG, Pinheiro D, Olsen KD (2006) Toxoplasmosis lymphadenitis presenting as a parotid mass: a report of 2 cases. *Ear Nose Throat J* 85: 666-668.
58. Mohamad I, Abdullah B, Salim R, Rajet KA, Naik VR (2010) Cryptococcosis: a rare fungal infection of the tongue. *Southeast Asian J Trop Med Public Health* 41: 1188-1191.
59. Butt AA, Carreon J (1997) *Histoplasma capsulatum* sinusitis. *J Clin Microbiol* 35: 2649-2650.
60. Laccourreye O, Mirghani H, Brasnu D, Badoual C (2010) Imported acute and isolated glottic paracoccidioidomycosis. *Ann Otol Rhinol Laryngol* 119: 89-92.
61. Franco-Paredes C, Dismukes R, Nicolls D, Hidron A, Workowski K, Rodriguez-Morales A, Wilson M, Jones D, Manyang P, Kozarsky P (2007) Persistent and untreated tropical infectious diseases among Sudanese refugees in the United States. *Am J Trop Med Hyg* 77: 633-635.

Corresponding author

Prof. Alfonso Rodriguez-Morales
 Faculty of Health Sciences, Universidad Tecnologica de Pereira
 Pereira, Colombia
 Phone: +57 3008847448
 Email: arodriguez@utp.edu.co

Conflict of interests: No conflict of interests is declared.