



Case Report

Response to Ibrutinib of a Refractory IgA Lymphoplasmacytic Lymphoma Carrying the *MYD88* L265P Gene Mutation

Francesca Maria Quaglia^{1,2}, Gian Matteo Rigolin², Elena Saccenti², Massimo Negrini³, Eleonora Volta², Melissa Dabusti², Maria Ciccone², Antonio Urso², Michele Laudisi² and Antonio Cuneo².

¹ Stem Cell Research Laboratory, Section of Hematology, Department of Medicine, University of Verona, Verona, Italy.

² Hematology Section, Department of Medical Sciences, Azienda Ospedaliero-Universitaria, Arcispedale S. Anna, University of Ferrara, Ferrara, Italy.

³ Department of Morphology, Surgery and Experimental Medicine, University of Ferrara, Ferrara, Italy.

Competing interests: AC speaker bureau and advisory board (ABBVIE, GILEAD, JANSSEN, ROCHE); GMR: speaker bureau (ABBVIE, GILEAD) and research support (GILEAD).

Abstract. In 2014 a 66-year-old woman presented with anemia and an IgAk monoclonal spike. Bone marrow (BM) biopsy showed 80% lymphocytes and lymphoplasmacytoid cells. Computed Tomography (CT) scan documented neither adenopathy nor splenomegaly. Diagnosis of IgA lymphoplasmacytic lymphoma was made. After three lines of treatment, progressive disease with adenopathies, splenomegaly, and ascites were documented on a CT scan. Our patient developed thrombocytopenia, transfusion-dependent anemia, and clinical deterioration. We performed genetic studies of peripheral blood lymphocytes with the NGS approach. Given the identification of *MYD88* L265P mutation, in February 2018 our patient started ibrutinib off-label. Hb and PLT improved from day +35. In July 2018 no ascites and 50% reduction of adenopathies and spleen were shown on a CT scan. In April 2019 the patient was still on ibrutinib with transfusion independence and good performance status.

Keywords: IgA-secreting lymphoplasmacytic lymphoma; Ibrutinib; *MYD88*.

Citation: Quaglia F.M., Rigolin G.M., Saccenti E., Negrini M., Volta E., Dabusti M., Ciccone M., Urso A., Laudisi M., Cuneo A. Response to ibrutinib of a refractory IgA lymphoplasmacytic lymphoma carrying the *MYD88* L265P gene mutation. *Mediterr J Hematol Infect Dis* 2019, 11(1): e2019057, DOI: <http://dx.doi.org/10.4084/MJHID.2019.057>

Published: September 1, 2019

Received: June 19, 2019

Accepted: August 16, 2019

This is an Open Access article distributed under the terms of the Creative Commons Attribution License (<https://creativecommons.org/licenses/by-nc/4.0>), which permits unrestricted use, distribution, and reproduction in any medium, provided the original work is properly cited.

Correspondence to: Gian Matteo Rigolin. Hematology Section, Department of Medical Sciences, Azienda Ospedaliero-Universitaria, Arcispedale S. Anna, University of Ferrara, Via Aldo Moro, 8, 44124, Cona, Ferrara, Italy. Tel. +39 0532 239674, Fax +39 0532 236049. E-mail: rfgmt@unife.it

Introduction. Lymphoplasmacytic lymphoma (LPL) is a rare chronic lymphoproliferative neoplasm characterized by the proliferation of B lymphocytes with varying degrees of plasmacytic differentiation involving bone marrow (BM), lymph nodes, or spleen.¹ Waldenstrom macroglobulinemia (WM) is a subset of LPL that has a detectable level of monoclonal IgM gammopathy, with BM involvement by LPL.^{2,3} Indeed in over 95% of LPL cases, the malignant clone produces an IgM paraprotein consistent with WM.⁴ However, the remaining LPL cases do not fulfill the

diagnostic criteria of WM. These conditions are mainly represented by rare cases of primary nonsecretory lymph node-based presentations of LPL or by lymphoplasmacytic B-cell proliferation in the BM associated with IgA or IgG gammopathies.^{1,5} Accurate diagnosis of LPL can be difficult because of the absence of morphologic, immunophenotypic, or chromosomal markers, especially in non-WM cases where there is no IgM gammopathy to support the diagnosis.¹ The identification of the *MYD88* L265P gene mutation represented a major advance in the

diagnosis of LPL^{3,5} although the real incidence of this mutation in LPL patients is unknown and a small number of WM patients with unmutated *MYD88* exist. Indeed in a study by Treon et al.⁶ about 90% of WM or LPL have *MYD88* L265P mutation and a small subgroup of patients with marginal zone lymphoma (MZL) were shown to carry this genetic lesion.⁶ In contrast, *MYD88* L265P mutation was absent in tissue samples from patients with myeloma, including samples from patients with IgM secreting myeloma.⁶ *MYD88* L265P mutation may, therefore, be useful in distinguishing LPL from B-cell disorders showing partially overlapping clinicopathological features.⁶ Few cases of non-IgM LPL have been reported demonstrating the presence of *MYD88* L265P.^{5,7-11}

MYD88 L265P triggers survival signaling through BTK and HCK, and *MYD88* L265P expressing cell lines undergo apoptosis in response to ibrutinib, which targets both of these kinases.⁴ Moreover, Ibrutinib has demonstrated significant activity in patients with relapsed/refractory B-Cell malignancies.^{12,13} In 2015, the FDA and the EMA approved ibrutinib for the treatment of symptomatic WM but not for LPL, based on a clinical trial in previously treated patients. The patients with LPL not fulfilling the diagnostic criteria of WM were excluded from WM trials and should be treated as the other indolent lymphoproliferative neoplasms, while recent guidelines¹⁴⁻¹⁷ included

recommendations on the usage of ibrutinib specifically for WM. For these reasons, the use of ibrutinib in non-IgM LPL has not yet been reported. We present here the first report of a patient with *MYD88*-mutated IgA LPL who underwent salvage therapy with ibrutinib.

Case Report. In September 2014 a 66-year-old woman presented with symptomatic anemia (Hemoglobin, Hb: 9 g/dl), with IgA/k monoclonal spike (1.6 g/dl) (**Figure 1**) and an otherwise unremarkable serum chemistry profile. A Computed Tomography (CT) scan documented neither adenopathy nor splenomegaly. BM biopsy showed an 80% infiltrate by lymphocytes and lymphoplasmacytoid cells with admixed atypical plasma cells (25%). Flow cytometry showed a kappa-restricted B-cell population (strong sIg kappa positivity) that expressed CD20, CD19, CD22, CD38, CD138, FMC7, and was negative for CD5, CD3, CD10, CD56, CD79a, CD23. The malignant plasma cells showed IgA+ kappa-restriction. The karyotype on BM cells was normal and so, no t(4,14), t(14,16), t(11,14), or del(17p) aberrations were detected by fluorescence in situ hybridization (FISH) using a probe-panel for multiple myeloma (MM); a deletion of 13q14 DLEU was detected by FISH using a 5 probe-panel for CLL (13q14, chromosome-12 centromere, 11q22, 17p13, 6q21). A diagnosis of IgA-secreting LPL was made.

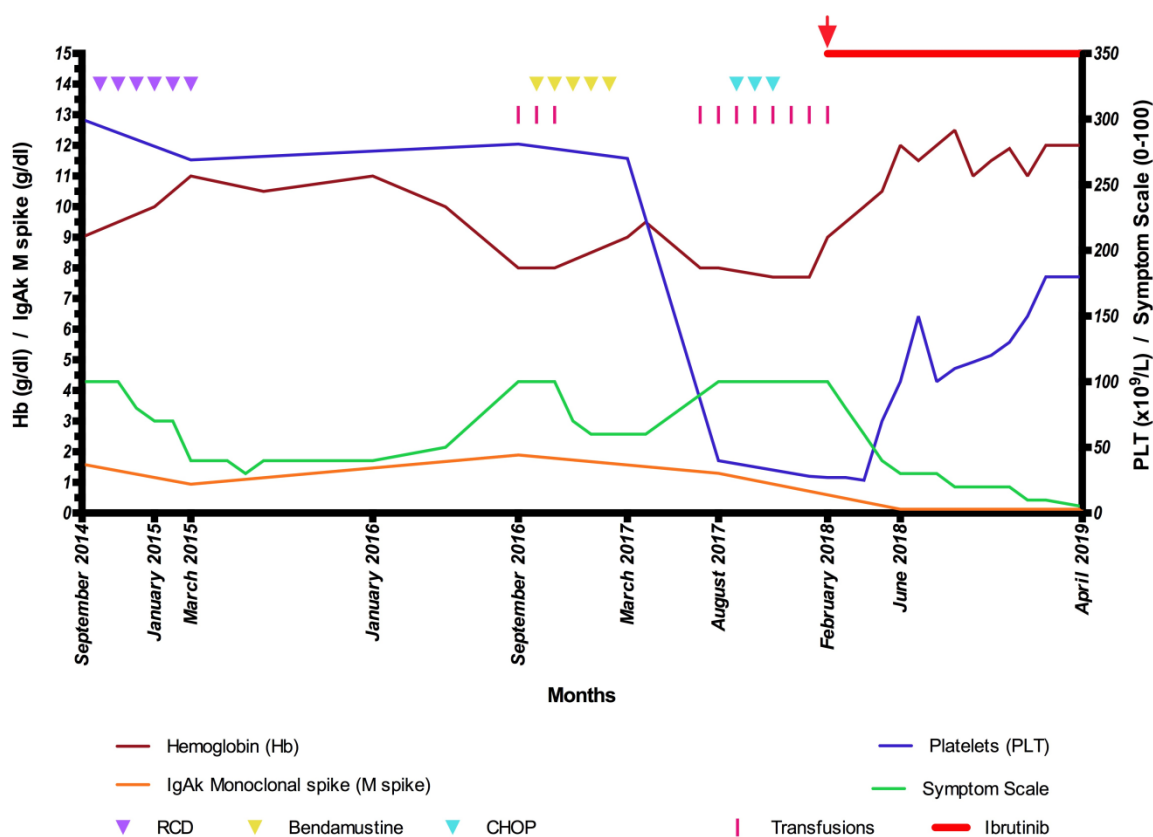


Figure 1. The diagram illustrates modifications in hemoglobin (Hb) and IgAk monoclonal spike (left Y axis), platelets (PLT) and symptoms (right Y axis) by treatment in our patient. Symptom Scale: 0–100-point scale, based on patient’s reported symptoms. Higher scores indicate more severe symptoms. RCD: Rituximab-Cyclophosphamide-Dexamethasone; CHOP: Cyclophosphamide-Doxorubicin-Vincristine-Prednisone. Red arrow: initiation of ibrutinib.

The patient was treated with rituximab-cyclophosphamide-dexamethasone (RCD regimen) with Partial Response (PR)¹⁸ (**Figure 1**). Eighteen months later the patient, who presented with progressive disease (PD) (Hb 8 g/dl, lymphocytes 3.56 x 10⁹/L with 80% lymphoplasmacytic cells, IgAk monoclonal spike 1.9 g/dl), was treated with bendamustine. In January 2017, after five cycles, the BM aspirate showed 90% lymphoid cells and adenopathies, splenomegaly and ascites were noted on a CT scan. Thus, cyclophosphamide-doxorubicin-vincristine-prednisone (CHOP) was started and, after three cycles, the patient developed thrombocytopenia (Platelets, PLT: 30 x 10⁹/L), transfusion-dependent anemia (Hb 7.7 g/dl), persistent lymphocytosis (Lymphocytes: 7.15 x 10⁹/L) in the peripheral blood (PB) and clinical deterioration (**Figure 1**). We performed genetic studies of PB lymphocytes (after separation over a Ficoll gradient, yielding >80% clonal B lymphocytes) with a targeted NGS approach detecting mutations in 20 genes frequently mutated in CLL (*ATM, BIRC3, BRAF, CDKN2A, PTEN, CDH2, DDX3X, FBXW7, KIT, KLHL6, KRAS, MYD88, NOTCH1, NRAS, PIK3CA, POT1, SF3B1, TP53, XPO1, ZMYM3*). The *MYD88* L265P mutation was identified in 65.7% of the reads. Given the identification of *MYD88* L265P in the peripheral blood, ibrutinib appeared a reasonable option. In February 2018, our patient started ibrutinib off-label, 420 mg once daily (**Figure 1**). Hb and PLT improved from day +35 (Hb 10-12 g/dl, PLT > 100 x 10⁹/L). In July 2018 no ascites and 50% reduction of adenopathies and spleen were shown on a CT scan. In April 2019, the patient was still on full dose ibrutinib with transfusion independence and good performance status.

This patient is unique in that it represents - to the best of our knowledge - the first reported case of response to ibrutinib in symptomatic aggressive IgA secreting LPL with *MYD88* mutation refractory to multiple lines of treatment. Guidelines for treatment of WM pose indication for ibrutinib in relapsed or untreated patients who are not candidates for chemoimmunotherapy.¹⁴⁻¹⁷ Our case clearly indicates that ibrutinib may represent a valuable therapeutic option for chemorefractory LPL not fulfilling the diagnostic criteria of WM. Our patient had previously been exposed to alkylators, immunomodulators, anti-CD20 monoclonal antibodies and steroids. Her therapeutic options at the time of her most recent relapse were limited and given the identification of the *MYD88* L265P mutation in the peripheral blood, ibrutinib appeared as a reasonable option. In our patient, ibrutinib produced a response within 4–6 weeks, that is a typical time-frame during which a response is usually observed. The partial response has been sustained for approximately 15 months at the time of this report. The kinetics of response in different disease compartments (blood, nodal, extranodal, spleen) were similar to those observed in WM patients^{15,19} and CLL patients on single-agent ibrutinib²⁰ with few treatment emergent adverse events consisting in grade 1 bruising, arthralgias and diarrhea, which improved and resolved with continued treatment.

In conclusion, we present the case of a heavily pretreated patient with *MYD88*-mutated IgA LPL, who has obtained a partial response to ibrutinib that is ongoing after more than one year of therapy. This observation suggests that ibrutinib appears to be potentially effective in this difficult-to-treat-condition.

References:

- Naderi N, Yang DT. Lymphoplasmacytic Lymphoma and Waldenstrom Macroglobulinemia. Arch Pathol Lab Med. 2013;137:580-585; <https://doi.org/10.5858/arpa.2012-0034-RS> PMID:23544948
- Mazzucchelli M, Frustaci AM, Deodato M, Cairoli R, Tedeschi A. Waldenstrom's macroglobulinemia: an update. Mediterr J Hematol Infect Dis . 2018; 10 (1): e2018004. <https://doi.org/10.4084/mjhjhid.2018.004> PMID:29326801 PMCID:PMC5760071
- Swerdlow SH, Campo E, Pileri SA, Harris NL, Stein H, Siebert R, Advani R, Ghielmini M, Salles GA, Zelenetz AD, Jaffe ES. The 2016 revision of the World Health Organization classification of lymphoid neoplasms. Blood. 2016; 9;127(20):2375-2390. doi: 10.1182/blood-2016-01-643569. Epub 2016 Mar 15. <https://doi.org/10.1182/blood-2016-01-643569> PMID:26980727 PMCID:PMC4874220
- Castillo JJ, Ghobrial IM, Treon SP. Response to ibrutinib in a patient with IgG lymphoplasmacytic lymphoma carrying the *MYD88* L265P gene mutation. Leuk Lymphoma. 2016;57(11):2699-2701. DOI: 10.3109/10428194.2016.1157875. <https://doi.org/10.3109/10428194.2016.1157875> PMID:26980069
- Martino G, Marra A, Ascani S, Sportoletti P. Uncommon lymphoplasmacytic lymphoma with IgA paraproteinemia: a challenging clinical diagnosis solved by *MYD88* mutation analysis. Ann Hematol. 2018. <https://doi.org/10.1007/s00277-018-3545-9> PMID:30426157
- Treon SP, Xu L, Yang G, Zhou Y, Liu X, Cao Y, Sheehy P, Manning RJ, Patterson CJ, Tripsas C, Arcaini L, Pinkus GS, Rodig SJ, Sohani AR, Harris NL, Laramie JM, Skifter DA, Lincoln SE, Hunter ZR. *MYD88* L265P Somatic Mutation in Waldenström's Macroglobulinemia. N Engl J med. 2012;367(9):826-833. <https://doi.org/10.1056/NEJMoa1200710> PMID:22931316
- Mori N, Ohwashi M, Yoshinaga K, Mitsuhashi K, Tanaka N, Teramura M, Okada M, Shiseki M, Tanaka J, Motoji T. L265P mutation of the *MYD88* gene is frequent in Waldenstrom's macroglobulinemia and its absence in myeloma. PloS One. 2013;8(11):e80088. <https://doi.org/10.1371/journal.pone.0080088> PMID:24224040 PMCID:PMC3818242
- Swerdlow SH, Kuzu I, Dogan A, Dirnhofer S, Chan JKC, Sander B, Ott G, Xerri L, Quintanilla-Martinez L, Campo E. The many faces of small B cell lymphomas with plasmacytic differentiation and the contribution of *MYD88* testing. VirchowsArch. 2016;468(3):259-275. <https://doi.org/10.1007/s00428-015-1858-9> PMID:26454445 PMCID:PMC5002945
- Cao X, Medeiros LJ, Xia Y, Wang X, Thomas SK, Loghavi S, Li X, Shah JJ, Gustafson SA, Weber DM, Miranda RN, Xu-Monette ZY, Orłowski RZ, Young KH. Clinicopathologic features and outcomes of lymphoplasmacytic lymphoma patients with monoclonal IgG or IgA paraprotein expression. Leuk Lymphoma. 2016;57(5):1104-13.

- <https://doi.org/10.3109/10428194.2015.1096357>
PMid:26421453
10. Jiménez C, Sebastián E, Chillón MC, Giraldo P, Mariano Hernández J, Escalante F, González-López TJ, Aguilera C, de Coca AG, Murillo I, Alcoceba M, Balanzategui A, Sarasquete ME, Corral R, Marín LA, Paiva B, Ocio EM, Gutiérrez NC, González M, San Miguel JF, García-Sanz R. MYD88 L265P is a marker highly characteristic of, but not restricted to, Waldenström's macroglobulinemia. *Leukemia*. 2013;27:1722-1728.
<https://doi.org/10.1038/leu.2013.62>
PMid:23446312
 11. King RL, Gonsalves WI, Ansell SM, Greipp PT, Frederick LA, Viswanatha DS, He R, Kyle RA, Gertz MA, Kapoor P, Morice WG, Howard MT. Lymphoplasmacytic Lymphoma With a Non-IgM Paraprotein Shows Clinical and Pathologic Heterogeneity and May Harbor MYD88 L265P Mutations. *Am J Clin Pathol*. 2016;145(6):843-851.
<https://doi.org/10.1093/ajcp/aqw072>
PMid:27329639
 12. Advani RH, Buggy JJ, Sharman JP, Smith SM, Boyd TE, Grant B, Kolibaba KS, Furman RR, Rodriguez S, Chang BY, Sukbuntherng J, Izumi R, Hamdy A, Hedrick E, Fowler NH. Bruton Tyrosine Kinase Inhibitor Ibrutinib (PCI-32765) Has Significant Activity in Patients With Relapsed/Refractory B-Cell Malignancies. *J Clin Oncol*. 2013; 31(1):88-94.
<https://doi.org/10.1200/JCO.2012.42.7906>
PMid:23045577 PMCid:PMC5505166
 13. Noy A, de Vos S, Thieblemont C, Martin P, Flowers CR, Morschhauser F, Collins GP, Ma S, Coleman M, Peles S, Smith S, Barrientos JC, Smith A, Munneke B, Dimery I, Beaupre DM14, Chen R15. Targeting Bruton tyrosine kinase with ibrutinib in relapsed/refractory marginal zone lymphoma. *Blood*. 2017; 129(16):2224-2232.
<https://doi.org/10.1182/blood-2016-10-747345>
PMid:28167659 PMCid:PMC5399483
 14. Leblond V, Kastritis E, Advani R, Ansell SM, Buske C, Castillo JJ, García-Sanz R, Gertz M, Kimby E, Kyriakou C, Merlini G, Minnema MC, Morel P, Morra E, Rummel M, Wechalekar A, Patterson CJ, Treon SP, Dimopoulos MA. Treatment recommendations from the Eighth International Workshop on Waldenström's Macroglobulinemia. *Blood*. 2016;128:1321-8.
<https://doi.org/10.1182/blood-2016-04-711234>
PMid:27432877
 15. Treon SP, Tripsas CK, Meid K, Warren D, Varma G, Green R, Argyropoulos KV, Yang G, Cao Y, Xu L, Patterson CJ, Rodig S, Zehnder JL, Aster JC, Harris NL, Kanan S, Ghobrial I, Castillo JJ, Laubach JP, Hunter ZR, Salman Z, Li J, Cheng M, Clow F, Graef T, Palomba ML, Advani RH. Ibrutinib in Previously Treated Waldenström's Macroglobulinemia. *N Engl J Med*. 2015; 372(15): 1430-1440.
<https://doi.org/10.1056/NEJMoa1501548>
PMid:25853747
 16. Castillo JJ, Palomba ML, Advani R, Treon SP. Ibrutinib in Waldenström macroglobulinemia: latest evidence and clinical experience. *Ther Adv Hematol*. 2016; 7(4):179-186.
<https://doi.org/10.1177/2040620716654102>
PMid:27493708 PMCid:PMC4959643
 17. Kastritis E, Leblond V, Dimopoulos MA, Kimby E, Staber P, Kersten MJ, Tedeschi A, Buske C. ESMO Guidelines Committee. Waldenström's macroglobulinaemia: ESMO Clinical Practice Guidelines for diagnosis, treatment and follow-up. *Ann Oncol*. 2018;29(Supplement 4):iv41-iv50.
<https://doi.org/10.1093/annonc/mdy146>
PMid:29982402
 18. Cheson BD, Fisher RI, Barrington SF, Cavalli F, Schwartz LH, Zucca E, Lister TA; Alliance, Australasian Leukaemia and Lymphoma Group; Eastern Cooperative Oncology Group; European Mantle Cell Lymphoma Consortium; Italian Lymphoma Foundation; European Organisation for Research; Treatment of Cancer/Dutch Hemato-Oncology Group; Grupo Español de Médula Ósea; German High-Grade Lymphoma Study Group; German Hodgkin's Study Group; Japanese Lymphoma Study Group; Lymphoma Study Association; NCIC Clinical Trials Group; Nordic Lymphoma Study Group; Southwest Oncology Group; United Kingdom National Cancer Research Institute. Recommendations for initial evaluation, staging, and response assessment of Hodgkin and non-Hodgkin lymphoma: the Lugano classification. *J Clin Oncol*. 2014 Sep 20;32(27):3059-68.
<https://doi.org/10.1200/JCO.2013.54.8800>
PMid:25113753 PMCid:PMC4979083
 19. Dimopoulos MA, Trotman J, Tedeschi A, Matous JV, Macdonald D, Tam C, Tournilhac O, Ma S, Oriol A, Heffner LT, Shustik C, García-Sanz R, Cornell RF, de Larrea CF, Castillo JJ, Granel M, Kyrtonis MC, Leblond V, Symeonidis A, Kastritis E, Singh P, Li J, Graef T, Bilotti E, Treon S, Buske C; iNNOVATE Study Group and the European Consortium for Waldenström's Macroglobulinemia. Ibrutinib for patients with rituximab-refractory Waldenström's macroglobulinaemia (iNNOVATE): an open-label substudy of an international, multicentre, phase 3 trial. *Lancet Oncol*. 2017 Feb;18(2):241-250.
[https://doi.org/10.1016/S1470-2045\(16\)30632-5](https://doi.org/10.1016/S1470-2045(16)30632-5)
 20. Ahn IE, Farooqui MZH, Tian X, Valdez J, Sun C, Soto S, Lotter J, Housel S, Stetler-Stevenson M, Yuan CM, Maric I, Calvo KR, Niernan P, Hughes TE, Saba NS, Marti GE, Pittaluga S, Herman SEM, Niemann CU, Pedersen LB, Geisler CH, Childs R, Aue G, Wiestner A. Depth and durability of response to ibrutinib in CLL: 5-year follow-up of a phase 2 study. *Blood*. 2018;131(21):2357-2366.
<https://doi.org/10.1182/blood-2017-12-820910>
PMid:29483101 PMCid:PMC5969380