

Case Report

The difficulties in identifying and grafting an intramuscular coronary artery

Andre' Navarro, David Sladden, Aaron Casha, Alexander Manche

Abstract

Myocardial bridging involves tunnelling of one of the coronary arteries through the myocardium, resulting in what are known as intramyocardial coronaries. While most patients with intramyocardial coronary vessels are asymptomatic, there is evidence that myocardial bridging may be the cause of sudden death. Given the low detection rate on coronary angiography, myocardial bridging may complicate coronary artery bypass grafting (CABG). This case report discusses a 72-year-old gentleman who underwent CABG, during which an undiagnosed intramuscular left anterior descending (LAD) coronary artery was found. With only the tapering end of the LAD visible at the apex of the heart, a small incision was made at this site and a 1mm probe inserted. At the uppermost reach of the probe the tip was felt to point superficial and therefore a second more proximal incision was performed. The left internal thoracic artery (LITA) was then successfully anastomosed with the proximal arteriotomy and a length of saphenous vein was used for anastomosis with the distal arteriotomy where the probe was originally inserted. The patient was discharged home 5 days post operatively.

Introduction

Myocardial bridging occurs when a segment of epicardial coronary artery is situated beneath a band of myocardium, resulting in intramyocardial coronary vessels. It was first described in 1737 at autopsy and first detected on angiography in 1960.¹⁻² The prevalence quoted in the literature varies greatly and an exhaustive anatomical study of over 1000 cadavers identified intramuscular coronaries in 26%.³ The detection rates using conventional coronary angiography is significantly lower, at just 12%.⁴ CT angiographic studies have identified myocardial bridges in up to 60% of people.⁵⁻⁶ These rates are significantly higher than the detection rates on coronary angiography.⁷ This is likely due to the fact that the features on angiography are more difficult to identify.

The importance of this anatomical variation is widely debated. Since the majority of coronary blood flow occurs in diastole the systolic compression rarely causes ischaemia. However there is some equivocal evidence that atherosclerosis is accelerated immediately proximal to the segment being compressed by the bridge, whilst the intramyocardial and distal portions are usually disease free.⁸⁻⁹

The commonest artery to be compressed by myocardial bridges is the LAD at 62.5%, with the marginal branch of the right coronary artery coming in second at 16.7%.¹⁰ The length of artery covered by myocardium varies considerably from around 3mm to 40mm.⁷

Characteristically the intramyocardial coronary vessel is seen to buckle inwards during systole and in 7% of these is also seen to temporarily narrow during systole.¹¹⁻¹² These angiographic findings were described by Portmann in 1960 and currently still remain the most common method of diagnosing myocardial bridging. However more advanced technologies such as coronary CT, intravascular ultrasound, intracoronary Doppler and fractional flow reserve, can help quantify the degree of compression.¹⁰

Andre' Navarro*
andre.navarro@gov.mt

David Sladden

Aaron Casha

Alexander Manche

**Corresponding Author*

Case Report

While most agree that these anomalies are harmless when in isolation, there is no data on the prognosis of myocardial bridges in the context of coronary artery disease. There is anecdotal evidence of myocardial bridging potentially causing sudden cardiac death, with several studies noting them present in healthy young people who died suddenly with no other cause found at autopsy.¹³ The LAD seems to be a culprit artery in these cases of sudden death, as is the length of artery covered and the depth of muscle it lies within.¹⁴

Case Presentation

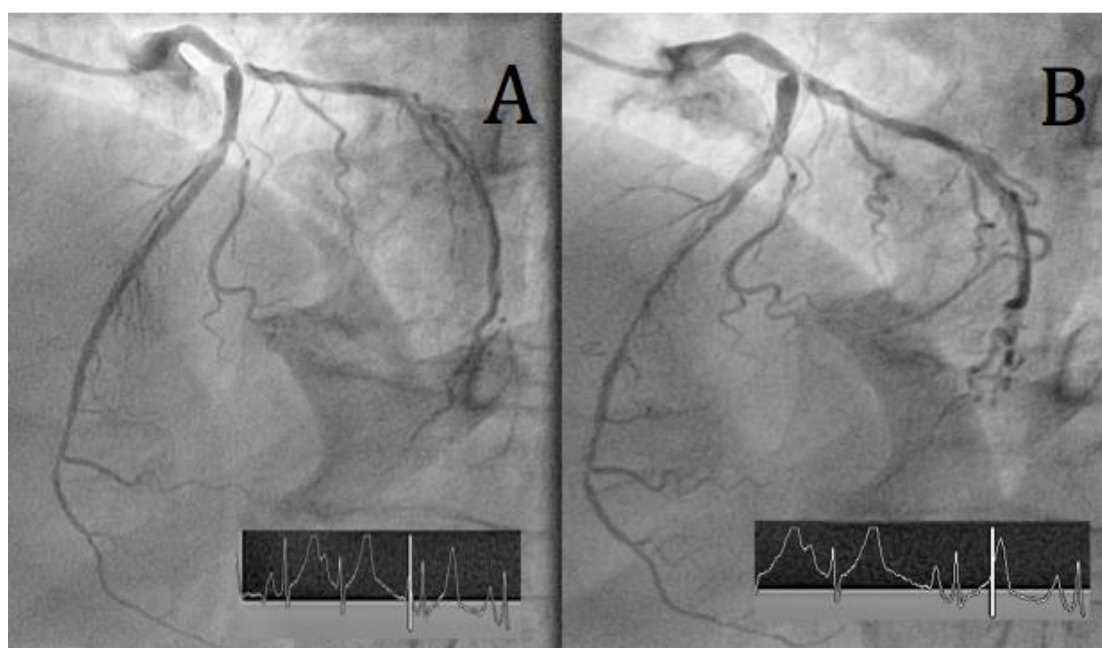
A 72 year-old male presented with angina. He was not a smoker and not diabetic, and presented with features suggestive of Parkinsonism. An exercise stress test was positive and a coronary angiogram was performed. This showed a tight stenosis of the distal left main coronary artery, systolic compression of a long-segment of the mid-LAD, with further stenotic disease at the origin of this segment (figure 1). His ejection fraction on echocardiography was 82%, Parsonnet score of 15 and logistic Euroscore of 3.26%. The patient was prepared for a CABG, with planned grafts to the LAD and the obtuse marginal (OM) branch of the circumflex artery.

Standard median sternotomy was performed with harvest of the LITA and simultaneous minimally-invasive long saphenous vein harvest from the thigh. Surgery was performed with conventional atrio-aortic cardiopulmonary bypass at normothermia and myocardial protection was with antegrade cold blood cardioplegia. The native vessels were inspected and while the OM was clearly visible the LAD was not. On closer inspection the tapered end of the LAD was visible at the apex of the heart. This was considered an unsuitable site for grafting as the LITA was not long enough and the calibre of the distal LAD very small.

Following the OM anastomosis a limited opening was made in the LAD at the apex and a 1mm metal probe was inserted retrogradely. The proximal LAD was then exposed proximally by cutting deep into the myocardium, using the probe as a guide. The LITA was anastomosed at this site and a further length of saphenous vein anastomosed to the distal LAD arteriotomy.

The patient was discharged home after 5 days without complications. At six months follow-up he remains well with good exercise tolerance and no recurrence of angina.

Figure 1: Left anterior oblique (LAO) 45 degrees and Cranial 20 degrees angiographic view showing the LAD artery in diastole (A) and in systole (B). The ECG tracings show at which point of the cardiac cycle the image was taken. Note the change in vessel calibre between the two images.



Discussion

This case highlights two key points in the process of grafting an intramuscular coronary artery. The first is the pre-operative identification of such an anomaly, which may be missed on angiography. Localised bridging is usually identified with a short segment that takes a deeper course and may exhibit contraction during systole.¹⁵ When the bridging is long and covers an extensive segment of the intramuscular coronary artery the angiographic signs may be subtle. Our case highlights one of the subtle signs on standard coronary angiography, which is the compression of the coronary artery along its intramuscular length during systole. This is also known as the 'milking effect' and is very often missed especially if the recording speed is too low (<25 frames/second).¹³ Computed Tomography has been shown to be an excellent method of visualising the intramuscular coronary artery preoperatively, and may be used in cases where this situation is suspected.¹⁶

The second important topic regards the intraoperative proceedings. Intramuscular coronary arteries are often discovered at operation. Locating and exposing the intramuscular artery is a key step in performing the operation. With short myocardial bridges the coronary artery is usually visible proximal and distal to the buried segment, which may be de-roofed by dividing the muscular fibres. When the entire artery is intramuscular it is only visible as a small vessel at the heart apex.⁷ Several alternative techniques have been described. Aydin U. et al utilised intraoperative fluoroscopic identification of the left anterior descending artery using a radio-opaque graded marker on the myocardial surface and an antegrade root injection of contrast via the cardioplegia line.¹⁷ High frequency ultrasound probes were first used to detect coronary arteries embedded in fat in 1986. More recently, linear ultrasound transducers have been put to use in detection of intramyocardial LAD arteries.¹⁸⁻¹⁹ The sterile epicardial ultrasound probe is used on doppler setting to identify the mid-portion of the intramyocardial coronary artery and using a sterile surgical marker a mark is made to guide the incision to expose the artery.¹¹

On-table coronary angiography and the use of a specially made radio-opaque marker strip on the surface of the heart has also been described.¹⁷ These techniques all involve imaging and add to the complexity of the operating room setup.

Oz M.C. et al describe a method when the great cardiac vein overlies the anterior descending artery. A deep elastic traction stitch mounted on a blunt needle is placed around both structures and traction is applied to mobilise the artery to the side and superficially, thereby facilitating its dissection.²⁰ This technique carries the risk of damaging the artery and also entering the right ventricle.

The method we here describe is similar to that outlined by Robinson in 1973 and requires no additional equipment.²¹ A small arteriotomy is performed distally, allowing the retrograde insertion of a probe to identify the proximal LAD. Depending on the calibre of the vessel and the proximity to the apex the surgeon may opt to close the arteriotomy or anastomose a graft to this segment, thereby revascularising an important territory distal to the intramuscular segment. This method relies on a rigid probe to identify a proximal portion of LAD and is, in our opinion, easier than relying on imaging techniques. Both our method as well as imaging methods may be used to de-roof a long segment of the buried LAD. However, the risk of entering the right ventricle is increased and we prefer, instead to apply a second, distal graft where indicated.

References

1. Reymann HC. Disertatio de vasis cordis propriis. *Bibl Anat.* 1737;2:359–75.
2. Portmann WC, Iwig J. Die intramurale koronarie im angiogramm. *Fortschr Rontgenstr.* 1960;92:129–32.
3. Risse M, Weiler G. [Coronary muscle bridge and its relations to local coronary sclerosis, regional myocardial ischemia and coronary spasm. A morphometric study]. *ZKardiol.* 1985;74:700–5.
4. Soran O, Pamir G, Erol C, Kocakavak C, Sabah I. The incidence and significance of myocardial bridge in a prospectively defined population of patients undergoing coronary angiography for chest pain. *Tokai J Exp Clin Med [Internet].* 2000;25:57–60. Available from: <http://www.ncbi.nlm.nih.gov/pubmed/11127508>
5. Zeina AR, Odeh M, Blinder J, Rosenschein U, Barmer E. Myocardial bridge: Evaluation on MDCT. *Am J Roentgenol.* 2007;188(April):1069–73.
6. Poláček P. Relation of myocardial bridges and loops on the coronary arteries to coronary occlusions. *Am Heart J [Internet].* 1961;61:44–52. Available from: <http://www.scopus.com/inward/record.url?eid=2-s2.0-0001773691&partnerID=tZOtx3y1>
7. Lujinović A, Kulenović A, Kapur E, Gojak R. Morphological aspects of myocardial bridges. *2013;13(4):212–7.*

Case Report

8. Erbel R, Ge J, Möhlenkamp S. Myocardial bridging: A congenital variant as an anatomic risk factor for myocardial infarction? *Circulation*. 2009;120:357–9.
9. Chatzizisis YS, Giannoglou GD. Myocardial bridges spared from atherosclerosis: overview of the underlying mechanisms. *Can J Cardiol* [Internet]. 2009;25(4):219–22. Available from: <http://www.pubmedcentral.nih.gov/articlerender.fcgi?artid=2706759&tool=pmcentrez&rendertype=abstract>
10. Lee MS, Chen CH. Myocardial Bridging: An Up-to-Date Review. *J Invasive Cardiol* [Internet]. 2015;27:521–8. Available from: <http://www.ncbi.nlm.nih.gov/pubmed/25999138>
11. Olearchyk AS, Nayar AP. Use of a handheld epicardial ultrasonic Doppler flow detector to locate an intramyocardial coronary artery encased in inflamed neoplastic pericardium. *Tex Hear Inst J* [Internet]. 2004;31:425–8. Available from: http://www.ncbi.nlm.nih.gov/entrez/query.fcgi?cmd=Retrieve&db=PubMed&dopt=Citation&list_uids=15745297
12. Olearchyk AS. Intramyocardial Coronary Arteries: Dissection During Coronary Artery Bypass Surgery in 70 Patients. *Vasc Endovascular Surg* [Internet]. 1992;26:649–55. Available from: <http://ves.sagepub.com/cgi/doi/10.1177/153857449202600808>
13. Brusckhe AVG, Veltman CE, de Graaf MA, Vliegen HW. Myocardial bridging: What have we learned in the past and will new diagnostic modalities provide new insights? Vol. 21, *Netherlands Heart Journal*. 2013. p. 6–13.
14. Morales AR, Romanelli R, Tate LG, Boucek RJ, de Marchena E. Intramural left anterior descending coronary artery: Significance of the depth of the muscular tunnel. *Hum Pathol*. 1993;24:693–701.
15. Endo M, Woo Lee Y, Hayashi H, Wada J. Angiographic evidence of myocardial squeezing accompanying tachyarrhythmia as a possible cause of myocardial infarction. *Chest*. 1978;73:431–3.
16. Donkol RH, Saad Z. Myocardial bridging analysis by coronary computed tomographic angiography in a Saudi population. *World J Cardiol* [Internet]. 2013;5(11):434–41. Available from: <http://www.pubmedcentral.nih.gov/articlerender.fcgi?artid=3857236&tool=pmcentrez&rendertype=abstract>
17. Aydin U, Kocogullari CU. A method for locating embedded left anterior descending coronary arteries. *Ann Thorac Surg* [Internet]. 2013;95:360–1. Available from: <http://www.ncbi.nlm.nih.gov/pubmed/23272867>
18. Hiratzka LF, McPherson DD, Brandt B, Lamberth WC, Marcus ML, Kerber RE. Intraoperative high-frequency epicardial echocardiography in coronary revascularization: Locating deeply embedded coronary arteries. *Ann Thorac Surg*. 1986;42.
19. Miwa S, Nishina T, Ueyama K, Kameyama T, Ikeda T, Nishimura K, et al. Visualization of intramuscular left anterior descending coronary arteries during off-pump bypass surgery. *Ann Thorac Surg*. 2004;77:344–6.
20. Oz MC, Cooper MM, Hickey TJ, Rose EA. Exposure of the intramyocardial left anterior descending artery. *Ann Thorac Surg* [Internet]. 1994;58:1194–5. Available from: [http://dx.doi.org/10.1016/0003-4975\(94\)90495-2](http://dx.doi.org/10.1016/0003-4975(94)90495-2)
21. Robinson G. Location of the proximal left anterior descending coronary artery. *The Annals of thoracic surgery*. 1973 Mar 31;15(3):299-300.