

Contents lists available at ScienceDirect

International Journal of Surgery

journal homepage: www.theijs.com

Review

Management of external small bowel fistulae: Challenges and controversies confronting the general surgeon

Daniel E. Wainstein ^{a,*,†}, Victoria Tüngler ^{b,†}, Constanza Ravazzola ^c, Osvaldo Chara ^{c,d,e}^a *Cirugía General, Hospital E. Tornú, Buenos Aires, Argentina*^b *Charité - Universitätsmedizin Berlin, Germany*^c *Departamento de Fisiología y Biofísica, Facultad de Medicina, Universidad de Buenos Aires - UBA, Buenos Aires, Argentina*^d *Instituto de Física de Fluidos y Sistemas Biológicos - IFLYSIB (CONICET, UNLP, CIC), La Plata, Argentina*^e *Center for Information Services and High Performance Computing, Dresden University of Technology, 01062 Dresden, Germany*

ARTICLE INFO

Article history:

Received 24 June 2010

Received in revised form

26 October 2010

Accepted 8 November 2010

Available online 24 November 2010

Keywords:

Small bowel

Enterocutaneous fistula

Sub-atmospheric pressure

ABSTRACT

Background: External small bowel fistulae (ESBF) are serious complications that represent a major challenge for general surgeons. They are still associated with significant morbidity and mortality. This article reviews the management of ESBF with emphasis on the treatment using sub-atmospheric pressure as well a timing, strategies and techniques of reconstructive surgery.

Methods: Relevant articles from 1960 to 2010 were identified using various electronic databases to review randomized controlled trials, prospective observational studies, retrospective studies and case reports and highlight key references.

Conclusions: External small bowel fistulae require multidisciplinary management and multimodal approaches with a primary essential focus on early recognition and diminishment of mortality factors such as sepsis and malnutrition. In most cases, the initial treatment is conservative, including clinical and nutritional recovery, output control and extensive local wound care. At this stage, the application of local negative pressure is highly effective. This procedure also allows for a spontaneous closure in many patients. Other cases require careful consideration of surgical reconstruction, knowing that success rates are variable and largely dependent on the patient's condition as well as on local aspects of the lesion. Best surgical results are obtained via intra-peritoneal access with extensive enterolysis, resection of the bowel segment from which the fistulae originate and direct abdominal wall closure.

© 2010 Surgical Associates Ltd. Published by Elsevier Ltd. All rights reserved.

1. Introduction

Enterocutaneous fistulae (ECF) are associated with high morbidity and mortality and its management remains a difficult challenge. In 1960 Edmunds and co-workers reported a global mortality rate of 43% of 157 patients suffering ECFs.¹ At present, most publications show mortality rates ranging from 5% to 30%.^{2–4} Nonetheless, in presence of coexisting aggravating factors like sepsis, malnutrition and large abdominal wall defects the mortality rate rises and can exceed 60%.^{5–7}

The aim of this review is to outline the current status in the management of postoperative ECF, which involves the small bowel. Special emphasis is placed on the output control of conservative

treatment based on sub-atmospheric pressure, as well as strategies and techniques of reconstructive surgery.

2. Methods

The bibliographical search was conducted using different electronic databases (incl. PubMed, Embase, Scopus, Biosis Previews and Cochrane Library) with keywords including [enterocutaneous fistula], [management of enterocutaneous fistulae], [small bowel fistula], [sub-atmospheric pressure] and/or [vacuum assisted closure]. Key citations of related topics from the past 50 years (1960–2010) were scrutinized, and together with personal experience provide the basis for this review. The literature covering information about diagnosis, management as well as outcome of external small bowel fistulae (ESBF) was analyzed for methodological quality, and data on surgical technique, mortality, morbidity, fistula closure and recurrence were reviewed.

2.1. Definition and characterization

An enterocutaneous fistula is defined as an abnormal communication between hollow viscera and the skin or abdominal wound.³ In order to identify its characteristics, three main aspects must be considered: anatomy, aetiology and pathophysiology.⁸

* Corresponding author.

E-mail address: dwainstein@telered.com.ar (D.E. Wainstein).

† DEW and VT contributed equally to this work.

Considering the anatomical site of origin, jejunal as well as ileal fistulae can be divided into two types: lateral, when the intestinal defect partially interrupts visceral continuity, or terminal, when there is complete intestinal discontinuity. Furthermore they are classified as superficial or deep fistulae depending on the length of their tract (lower or higher than 2 cm), which in turn can be simple or complex according to their shape.

The pathologic-anatomical features are an important guideline for the management and prognosis. Frequently complicating attributes hinder or impede spontaneous closure (Table 1).^{9–11}

Most commonly (75–90%) ESBF develop as a postoperative complication of abdominal surgery with an incidence of 0.5–1.5%. Less frequently (10–25%) they occur as complication of chronic intestinal diseases such as Crohn's disease, radiation enteritis, malignancies, trauma or ischemia.^{5,12}

Fistulae are further defined according to their output into low or high output fistulae depending on whether their drainage is lower or higher than 500 ml/24-hours.⁵ An important consequence of a high output enterocutaneous fistula is a hydroelectrolyte imbalance that may lead to dehydration and metabolic disorders.¹³ The loss of nutrients along with hypercatabolism due to sepsis and the reduced dietary intake leads to further malnutrition. The impact of these events leads to ileus prolongation, increased likelihood of wound dehiscence, muscle atrophy, complications related to hospitalization and, consequently, increased mortality.¹³

Intestinal fluid emanating from the ESBF irritates the abdominal wall, causes chemical dermatitis which in turn renders the musculoaponeurotic tissue more susceptible to infection. Once a severe infection of this tissue has established appearance of sepsis is the rule rather than the exception. Nevertheless, sepsis can also originate from extra-intestinal sources such as intravenous catheters, pulmonary and urinary tract. This is important because sepsis constitutes the principal independent predictor of mortality.

2.2. Diagnosis

A detailed evaluation of the patient's clinical condition and the fistula characteristics are necessary for further decisions regarding the treatment. Special attention should be given to the primary underlying pathology (e.g. cancer) and previous surgical protocols as well as preexisting images should be reevaluated.

While the assessment of the nutritional status is an essential diagnostic measure, there is no consensus on the best method for its accurate evaluation. In the past, a patient was considered severely malnourished if the plasma albumin concentration was less than 3 g/dl and the weight loss greater than 20% of its theoretical value.¹³ A considerable body of evidence including an assessment using dual-energy X-ray absorptiometry, has demonstrated that decreased serum albumin does not serve as an indicator of isolated protein-energy malnutrition since it neither correlates with the lean mass, appendicular skeletal muscle mass, nor body cell mass indexes.¹⁴ However, it could be shown that serum albumin functions as a predictor for greater risk of mortality, morbidity, length of stay and complication rate.^{14,15} Fluid imbalance influences anthropometric measurements, and many of the classical biologic parameters including prealbumin and transferrin, are affected by non-nutritional factors such as inflammation and are thus inappropriate indicators in ESBF patients, who often suffer from fistula-associated inflammatory complications or chronic diseases. Along with other authors we suggest, that until new analytical approaches with surrogate markers to assay malnutrition become available, a combination of clinical and biochemical parameters along with subjective criteria should be used to estimate the presence of malnutrition in order to design adequate delivery of nutrients and evaluate the response to treatment.^{16–18} The presence of sepsis should in first place call attention to an abdominal focus. In the absence of evidence of intra-abdominal infection, it should not be overlooked that the source might also derive from an extra-abdominal origin. If, after thorough diagnostic inspection, a cause can still not be determined, the possibility of intra-abdominal interloop abscesses should be reconsidered. Intra-abdominal abscesses were found in 50% of 203 patients undergoing definitive surgery of ECF, which had gone undiagnosed in previous computational imaging.¹⁹ Abscesses may be multiple, small and located in an abdomen that may entail significant anatomical changes as consequence of preceding surgery. Given that multiple prior surgeries may decrease the effectiveness of a CT scan, laparotomy may also be indicated.

Table 1
Anatomic factors which influence the possibility of spontaneous closure.

Favourable	Unfavourable
Deep fistula	Superficial fistula
No adjacent abscess	Adjacent abscess
Free distal passage	Distal occlusion
Healthy adjacent intestine	Diseased adjacent intestine
Preserved intestinal continuity	Intestinal dehiscence
Defect minor than 1 cm	Defect major than 1 cm
Single fistula	Multiple fistulae
Intact abdominal wall	Abdominal wall defect

2.3. Imaging

Ultrasound and CT scan should be initially used to evaluate whether the intestinal fluid passing through the fistula is leaking completely out of the body or remains partially retained in the abdominal cavity, either freely or forming abscess.

Fistulography allows for a better understanding of anatomical characteristics, especially in the case of deep fistulae. By injection of a hydrosoluble contrast agent through the external orifice, the paths to the intestinal tract can be visualized providing information about its length, shape, eventual intermediate cavities and origin site. Distal obstructions and foreign bodies can also be detected. Small bowel tract contrast, barium enema, and endoscopy studies offer complementary information revealing the status of the remainder of the digestive tract.^{20,21}

2.4. Management guideline

While variations in treatment may be appropriate according to the needs of individual patients, guideline of ESBF treatment can be summarized in a four-stage protocol adapted from Chapman that describes, with some modifications, possible therapeutic procedures alternatively [Fig. 1].²²

Stage 0—Decision. Having identified the fistula with its diagnostic characteristics, the team should decide on whether to follow a conservative treatment or an urgent surgical procedure. The conservative path may lead to spontaneous fistula closure or aim to stabilize the patient in order to face definitive surgery. Surgery is initially necessary in cases of acute abdomen such as septic peritonitis, bowel obstruction or underlying concomitant urgent surgical pathology. Surgical treatment may also be of initial choice in patients with early postoperative fistulae in good clinical condition.

Stage 1—Stabilization. The stabilization phase requires the re-establishment of the electrolyte balance, circulating volume. Another goal is to reduce fistula output to less than 500 ml/day. Intra-abdominal infections should be ruled out or, when detected, adequately drained.

Stage 2—Improvement. The stabilized patient is better able to receive and to incorporate nutritional support. Contrast studies during the progress will indicate fistula anatomy to anticipate the possibility of spontaneous closure or to help for further eventual changes in treatment strategies e.g. reconstructive surgery.

Stage 3—Resolution. In the absence of wound healing, visibly by granulation, a spontaneous closure may not occur and reconstructive surgery may be required.

2.5. Conservative treatment and application of local sub-atmospheric pressure

Since the 1960s there has been a general consensus that surgery in patients with sepsis, malnutrition and/or hydroelectrolytic disorders bear high risks of fistula recurrence, morbidity and mortality.^{1,22} Therefore, conservative treatment, consisting of hydroelectrolyte imbalance correction, treatment of sepsis and nutritional support, constitutes the standard initial approach to most ECFs. Adjunctive surgical measures include appropriate output control and wound care.

Once sepsis has been successfully eradicated it is possible to optimize the nutritional support. Preferentially, patients should receive enteral nutrition. It promotes intestinal integrity, prevents mucosal atrophy, bacterial translocation and consequently reduces the chance of sepsis reappearance. However, parenteral support may initially be necessary until a transition to total enteral nutrition is possible. Evidence shows that fistula output, mortality and spontaneous closure are

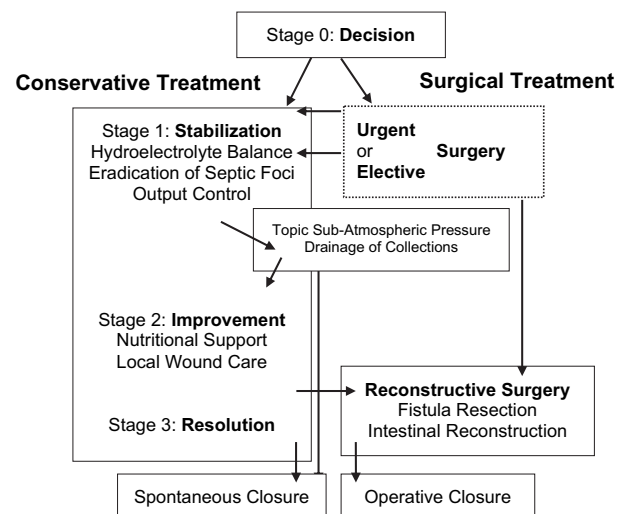


Fig. 1. ESBF Treatment Guide. Schematic diagram of practical therapeutic ESBF management.

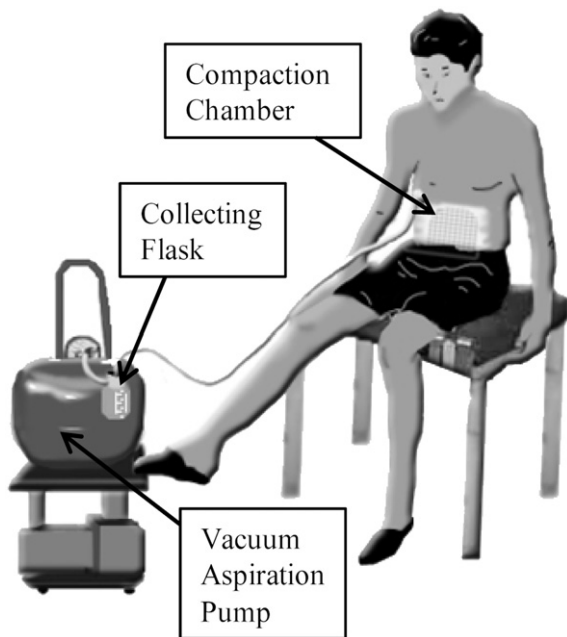


Fig. 2. Sub-atmospheric Pressure (Vacuum-Compaction) System. Illustration of the technical device applying sub-atmospheric pressure.

all improved with adequate nutritional support.^{2,23} But what is adequate? Answering this question exceeds the purpose of this manuscript which is why we would like to recommend the following literature, where this relevant aspect are addressed in its necessary extent: Evenson & Fischer, 2006; Chintapatla & Scott, 2002; Osborn & Fischer, 2009; Slater, 2009.^{3,24–26}

During the last twenty years several methods have been developed in order to try to diminish fistula leakage. These methods include biological fibrin glue, porcine small intestine submucosa and fast hardening amino acid solution, among others. Although first results seem encouraging, their efficacy has still yet to be proven.^{9,27–29}

Consolidated therapeutic approaches to reduce the enteric fluid loss are suppression of oral intake, administration of total parenteral nutrition (TPN) and exocrine-suppressing somatostatin analogues, which inhibit the release of numerous gut hormones and decrease splanchnic and portal flow.^{30,31} Initial problems with somatostatin treatment, more precisely, the short plasma half-life and the "bouncing effect", which by discontinuation led to undesired increase of insulin, glucagon and growth-hormone secretion, have been overcome by the long-acting somatostatin analogue octreotide.³² It has been widely used in the management of ESBFs for now two decades. However, enthusiasm for its use recently decreased since results of a randomized double-blind placebo-controlled trial have become available which demonstrated that although octreotide is able to diminish output and time of closure in some cases, it fails to demonstrate significant increase in spontaneous closures or a decrease in mortality.³³

In 1989, Chariker et al. reported on the first series of patients with ECFs treated with sub-atmospheric pressure.³⁴ In 1992, Fernandez et al. developed a technique that used compaction with high sub-atmospheric pressure, values exceeding 400 mm Hg, in order to compact and occlude intestinal communications with the skin [Figs. 2 and 3].¹¹ There remains controversy as to the optimal values of sub-atmospheric pressure for the treatment. Several groups administered sub-atmospheric pressure values between 80 and 120 mm Hg.^{35,36} These low values are based on first approaches carried out by Russian scientists, who treated chronic wounds (not ECF) with sub-atmospheric pressure to obtain tissue healing. This effect was not reproduced with lower levels of pressure. Also other groups concluded that high sub-atmospheric pressure is needed to achieve complete fistula closure.^{11,37,38} Results obtained by mathematical modelling, where a numerical relationship between the fistula compressibility and closure time of enterocutaneous fistulae was established, justify the debate on pressure values.³⁹ The model simulations revealed that the magnitude of pressure which needs to be exposed in order to achieve fistula closure is significantly determined by the tissue elasticity and consequential compressibility of the fistula. Tissue elasticity in turn is closely related to the intestinal wall structure (e.g. collagen content) and thickness including villi height, crypt depth, and the thickness of mucosa, submucosa and muscle. Since different pathologies (inflammation, cancer, fasting etc.) and different stages of wound healing process generate changes in the structure of the intestine, it is to be expected that the biomechanical properties change as well.⁴⁰ The model predicted that fistulae with a higher elasticity index are associated with a higher success rate of fistula closure.³⁹

Different authors describe favourable outcomes when applying topical sub-atmospheric pressure. It has been helpful in cases where regular conservative treatment was ineffective as well as in improving the patient's nutritional status prior to surgery.⁴¹ The technique offers various benefits; by shielding the skin from the corrosive gut secretions, it helps to maintain skin integrity around the fistula and lowers the frequency of requirements in dressing changes. The sub-atmospheric pressure in the compaction chamber undermines bacterial growth and supports absorption of superficial abscesses yet encourages angiogenesis with ensuing granulation. The output reduction facilitates the balance of fluid and electrolyte and accelerates the initiation of oral food intake. Also, the system may have long silicon drains or a portable pump allowing the patient to move which benefits to the recovery process and has positive psychological impact.

Thus, the vacuum method offers different types of results: curative in the case of achievement of spontaneous closure, temporizer when the patient's clinical condition improves enough to afford surgery for reconstruction or palliative offering a better life quality in advanced neoplastic pathologies. Additionally, treatment with sub-atmospheric pressure does not require sophisticated resources and seems to have a superior cost-benefit relationship when compared with treatments based on TPN alone or in combination with octreotide.³⁴

While in our experience the application of local sub-atmospheric pressure seems promising, there is not enough pooled data available to draw definitive conclusions regarding its outcome measures. Attempts thus far to statistically evaluate fistula closure with or without the use of sub-atmospheric pressure (Student *t* test, N.S., mean standard error), studies hitherto, listed in Table 2, show no significant difference between the two treatments (7.8 ± 3.2 with as opposed to 28.9 ± 14.5 without its application). It also seems as if topical sub-atmospheric pressure does not affect mortality rates (16.0 ± 3.7 as opposed to 14.8 ± 2.6 without its use). Yet we think that this would be a wrong conclusion, since the studies differ in a variety of important parameters which strongly influence the final results such as the length of the fistula path, the volume of output and the presence or absence of abdominal wall defects. Paying closer attention, sub-atmospheric pressure was mostly applied where conventional treatment has failed, and it is consequently not unbiased to compare the outcome of one study with another.

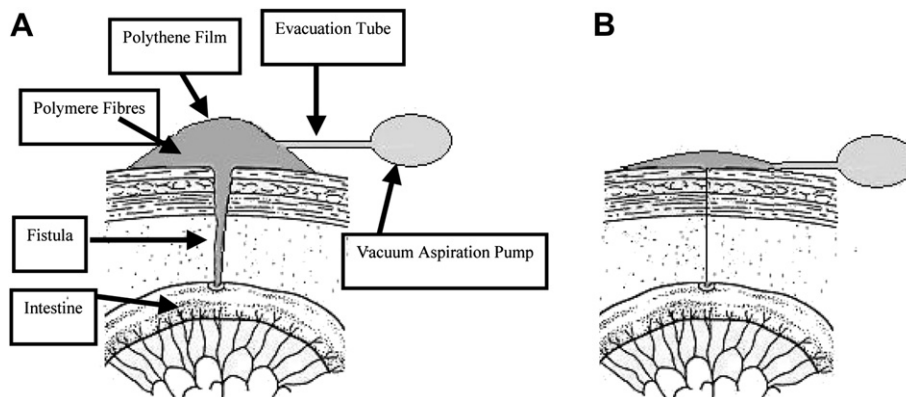


Fig. 3. Compaction Chamber. A) Karaya paste is spread on the skin of the abdomen. The paste is then covered with a coat of polymer fibers where the evacuation tubes are embedded and finally sealed with polythene film. B) Application of sub-atmospheric pressure leads to polymer contraction. This causes tension on the fistula orifice and forces the wound edges together.

Table 2
Conservative treatment outcomes and study parameters.

Authors	Levy et al. ⁷	Campos et al. ⁵	Li et al. ⁴	Hollington et al. ²	Martinez et al. ⁴³	Vischers et al. ¹⁶	Fernandez et al. ¹¹	Hyon et al. ⁵⁶	Dionigi et al. ⁴⁸	Wainstein et al. ³⁸
N	335	188	1168	277	174	135	14	21	19	91
Type of fistula	ESBF	ECF	ECF	ECF	ECF	ECF	ECF	ECF	ECF	ECF
Sub-atmospheric pressure	No	No	No	No	No	No	Yes	Yes	Yes	Yes
Postoperative origin	Yes	Yes	Yes	Yes	Yes	Yes	Yes	Yes	Yes	Yes
Non-surgical origin	Yes	Yes	Yes	Yes	No	Yes	No	No	No	No
Abdominal wall defect	No	n.m.	n.m.	Yes	n.m.	Yes	Yes	Yes	Yes	Yes
Spontaneous closure (%)	97 (29)	59 (31)	420 (36)	55 (20)	65 (37)	21 (16)	11 (79)	5 (23)	0 (0)	46 (42)
Mortality (%)	65 (25)	58 (31)	66 (6)	30 (11)	23 (13)	13 (10)	1 (7)	3 (14)	4 (21)	7 (17)

n.m. = not mentioned.

2.6. Reconstructive surgery

Despite best efforts, there are a 30–75% of patients with ESBF requiring surgery for its definite repair.^{16,23,42,43} In such cases, the aim of further treatment is to obtain fistula closure by surgical means.

2.6.1. Timing of surgery

The right timing of the surgical procedure remains controversial. For a long time it was convention to wait 4–6 weeks for a spontaneous resolution and then, in case of persistence, to proceed with reconstructive surgery.^{1,36} First, it should be pointed out that fistula closure has been achieved in some cases, after this time period, with the assistance of innovative treatments such as sub-atmospheric pressure.^{36,38,44} Second, the previously defined time span, usually, is not enough to obtain an adequate clinical and nutritional condition in order to perform complex reconstructive surgery. Infectious complications such as sepsis from central line catheter and pulmonary infection may delay nutritional recovery, as well as surgical opportunity. Lynch et al. conclude in favour of delaying surgery for at least 12 weeks to decrease chances of recurrence, though their statistical analysis of timing in relation to fistula recurrence did not demonstrate a significant difference.¹⁹ Many authors share his opinion and caution against early reoperation. They reason that dissection in a dense peritoneal reaction is prone to cause hemorrhages and bears high fistula recurrence rates.⁴⁵ In particular after multiple laparotomies for severe intra-abdominal infection, awaiting consolidation and the formation of neoperitoneum seems comprehensible. Signs, such as the return of a soft abdomen with residual induration limited to the perifistula region, as well as prolapsing of the fistulating bowel could be indicators of an adequate moment to approach surgery again.² The time spectrum of the latest studies ranges from 2 to 11 months.^{16,46} Quite the reverse is the conclusion drawn by Brenner and colleagues when specifying the issue of timing and recurrence of ECF after operative repair in their recent study. In contrast to the above authors, her results indicate a significant increase of recurrence if repair is delayed past 36 weeks. Despite employing meticulous statistical analysis, also exact interpretations of these results are limited (due to selection of patients) and lack specific protocols.⁴⁷ It appears as though prospective studies are needed that specify timing of operation in a more detailed manner to identify which factors are responsible for increasing the risk for ECF recurrence. Meanwhile we believe that the timing of surgery should be considered on the basis of day-to-day patient characteristics instead of fixating a set time period as has been proposed elsewhere.¹⁶

2.6.2. Strategy and technique

The surgical procedure involves three main steps: access, intestinal treatment and abdominal wall closure. The access to the peritoneal cavity needs be wisely chosen. The incision must anticipate potential necessity for abdominal wall reconstruction with tissue of good vascular supply and provision of abdominal wall structures with adequate strength to reduce the risk of wound disruption.⁴² The abdomen may be accessed by a vertical midline above the previous incision, across healthy tissue. Another possibility is to incise surrounding the fistula in order to perform a resection en-bloc together with the surrounding granulation tissue and the overlying skin.⁴⁸ It is not advisable to execute various parallel incisions. Adding new injury, they interfere with blood irrigation at the wound edges and become an obstacle for the eventual ostomy exteriorization.^{8,49,50} The enterolysis should be extensive, if possible from the duodenojejunal flexure to the ileocecal valve, in order to obtain broad and clear vision of the anatomy, to reduce the possibility of immediate postoperative obstruction and to adequately liberate the adherent bowel from the abdominal wall. This will facilitate abdominal closure and drainage of small abscesses, which otherwise could remain overlooked.^{3,42,51}

The resection of the bowel segment containing the fistula should be reduced to the minimum length which still allows the apposition of two intact and healthy intestinal stumps. In presence of multiple lesions, it is essential to perform as few anastomoses as possible with attention to the length of the residual intestine, since in patients with previous resections there is the potential risk of short intestine

syndrome as a sequel, especially if there is no ileocecal valve.^{12,16} Current evidences are still insufficient to clearly demonstrate superiority of a particular technique concerning the types of anastomosis and mechanic sutures.^{19,47,52} Wedge repair and bypass with fistula exclusion are alternatives that lead to suboptimal results and should not be employed except in cases of extreme necessity, e.g. when unable to mobilize the fistulized bowel segment.^{19,47,52} In these cases it should be considered to protect the repair with a proximal stoma. Patients with ESBF frequently have a serious wall defect, either due to multiple prior surgical interventions, open abdomen or evisceration. An inadequate strategy during abdominal closure time may increase the risk of fistula recurrence.^{51,53} In an attempt to minimize such complication risk, primary abdominal wall closure has been shown to be the best option, even with components separation techniques if necessary.⁵¹ Numerous types of meshes have been developed to optimize the repair of abdominal wall defects, which can be classified according to their pore size and composition of material based on polymers (typically polypropylene, polyester, or expanded polytetrafluoroethylene).⁵⁴ They can be absorbable or non-absorbable. Non-absorbable mesh ensures durable abdominal wall prosthesis. However, the application of a non-absorbable mesh is associated with an increased risk of infection mainly in contaminated abdominal wall. In many cases, often due to prior operations, there is not sufficient omentum which can be interposed between mesh and bowel in order to prevent that the implanted mesh damages exposed bowel.^{3,51} For this reason, currently the use of absorbable mesh achieves generally higher approval.^{12,46} Yet, despite advances, especially regarding their biomechanical resistance, mesh application in general is still prone to complications such as the formation of adhesions, small bowel obstruction and fistula recurrence.⁴⁶

In recent years, new types of prostheses to optimize the treatment of large abdominal wall defects have appeared. These meshes are composed of a core component that provides non-absorbable biomechanical resistance and secondary component designed to prevent bowel adhesions to the prosthesis. Biological prostheses are allografts or heterografts that, specifically processed, lose their cellular component and keep the absence of omentum serving this extracellular matrix structure, or framework, for the infiltration of connective tissue whose regeneration is sought. Efforts have been made with both types of meshes, the benefits of rapid integration cell and at the same time have a cover to prevent adhesions and intestinal fistulae.⁵⁵ Nevertheless, for application in the contaminated open abdomen as with intestinal fistulae, experience to date has been limited and yielded mixed results. Reconstructive surgery by means of musculocutaneous flaps, using e.g. the tensor fasciae latae, is suited for a stable coverage of the abdominal wall and has the advantage that it offers a good local blood supply that provides protection against infections, possibly leading to fistula reopening.⁵³ The procedure is complicated, long-lasting and associated with considerable morbidity at both the donor and the recipient sites and reoperations are common, which is why it should be used as a last resort method in patients, where prosthetic repair is contraindicated (e.g. infectious contamination).

2.6.3. Morbidity and mortality

Surgical reparation of an intestinal fistula is associated with high morbidity (30–83%).^{10,42,46} The most frequent complications are: infection of surgical site, respiratory complications and recurrence.^{46,48} The incidence of the latter is between 13 and 33% and the mortality rate between 9 and 30%. This may be related to wedge repair without intestinal resection and the impossibility to achieve primary abdominal wall closure, especially when viscera covering omentum is not feasible. Both early recurrence and abdominal wall defects are significantly related to higher mortality rates.^{6,12,46}

3. Conclusions

Bearing in mind the referenced studies cited in the literature and our own experience, the principles that should govern the

management of small intestine external fistulae can be summarized as follows:

1. Small bowel fistulae initially require aggressive treatment and in most cases may be managed conservatively.
2. Mortality rates and recovery can be improved by early accurate diagnosis and treatment of septic patients.
3. Adequate output control has a significant impact on clinical and nutritional recovery. Here the topic application of sub-atmospheric pressure to achieve vacuum assisted closure seems to be promising.
4. Once the patient is stabilized, efforts must be made to optimize nutritional recovery. Malnutrition hampers fistula closure and any necessary reconstructive surgery involves a high risk of recurrence.
5. Complicated and persistent fistulae require reconstructive surgery, yet should only be attempted when feasible. The timing of surgical intervention should be adapted to each particular case depending on the clinical and nutritional state along with the pathological and surgical history of the patient.

In recent years, a progress has been made in the management of this complication. Improved diagnostic methods, better control and treatment of sepsis, nutritional support and new resources for local wound care have, to some extent, reduced concomitant mortality. Nevertheless, due to not only substantial differences between patients within one study but also inter-study variations in the currently available data, it is difficult to draw definite conclusion on their respective treatment effect. It seems, therefore, necessary that multidisciplinary teams gather detailed information to be able to collectively pool the data in order to reach firm conclusions.

Conflict of interest statement

None to declare.

Funding

None.

Acknowledgements

The authors would like to thank the two anonymous reviewers for their valuable questions, comments and suggestions. They also thank to Profs. Richard Denniston and Iris Roldan for their helpful advice and collaboration.

References

1. Edmunds Jr LH, Williams GM, Welch CE. External fistulas arising from the gastrointestinal tract. *Ann Surg* 1960;152:445–71.
2. Hollington P, Mawdsley J, Lim W, Gabe SM, Forbes A, Windsor AJ. An 11-year experience of enterocutaneous fistula. *Br J Surg* 2004;91(12):1646–51.
3. Evenson AR, Fischer JE. Current management of enterocutaneous fistula. *J Gastrointest Surg* 2006;10(3):455–64.
4. Li J, Ren J, Zhu W, Yin L, Han J. Management of enterocutaneous fistulas: 30-year clinical experience. *Chin Med J (Engl)* 2003;116(2):171–5.
5. Campos AC, Andrade DF, Campos GM, Matias JE, Coelho JC. A multivariate model to determine prognostic factors in gastrointestinal fistulas. *J Am Coll Surg* 1999;188(5):483–90.
6. Schein M, Decker GA. Gastrointestinal fistulas associated with large abdominal wall defects: experience with 43 patients. *Br J Surg* 1990;77(1):97–100.
7. Levy E, Frileux P, Cugnenc PH, Honiger J, Ollivier JM, Parc R. High-output external fistulae of the small bowel: management with continuous enteral nutrition. *Br J Surg* 1989;76(7):676–9.
8. Berry SM, Fischer JE. Classification and pathophysiology of enterocutaneous fistulas. *Surg Clin North Am* 1996;76(5):1009–18.
9. Draus Jr JM, Huss SA, Harty NJ, Cheadle WG, Larson GM. Enterocutaneous fistula: are treatments improving? *Surgery* 2006;140(4):570–6. discussion 6–8.
10. Schein M. What's new in postoperative enterocutaneous fistulas? *World J Surg* 2008;32(3):336–8.

11. Fernandez ER, Cornalo AO, Gonzalez D, Villilla V. Nuevo enfoque en el tratamiento de las fistulas enterocutaneas postquirurgicas. *Rev Argent Cirug* 1992;62:117–27.
12. Wainstein DE, Delgado D, Serafini V, et al. Fistulas externas complejas de intestino delgado. Cirugía reconstructiva del tracto digestivo. *Rev Argent de Cirug* (in process).
13. Makhdoom ZA, Komar MJ, Still CD. Nutrition and enterocutaneous fistulas. *J Clin Gastroenterol* 2000;31(3):195–204.
14. Bouillanne O, Dupont-Belmont C, Hay P, Hamon-Vilcot B, Cynober L, Aussel C. Fat mass protects hospitalized elderly persons against morbidity and mortality. *Am J Clin Nutr* 2009;90(3):505–10.
15. Goldwasser P, Feldman J. Association of serum albumin and mortality risk. *J Clin Epidemiol* 1997;50(6):693–703.
16. Visschers RG, Olde Damink SW, Winkens B, Soeters PB, van Gemert WG. Treatment strategies in 135 consecutive patients with enterocutaneous fistulas. *World J Surg* 2008;3:445–53.
17. Meguid MM, Campos AC. Nutritional management of patients with gastrointestinal fistulas. *Surg Clin North Am* 1996;76(5):1035–80.
18. Devakonda A, George L, Raouf S, Esan A, Saleh A, Bernstein LH. Transthyretin as a marker to predict outcome in critically ill patients. *Clin Biochem* 2008;41(14–5):1126–30.
19. Lynch AC, Delaney CP, Senagore AJ, Connor JT, Remzi FH, Fazio VW. Clinical outcome and factors predictive of recurrence after enterocutaneous fistula surgery. *Ann Surg* 2004;240(5):825–31.
20. Kerlan Jr RK, Jeffrey Jr RB, Pogany AC, Ring EJ. Abdominal abscess with low-output fistula: successful percutaneous drainage. *Radiology* 1985;155(1):73–5.
21. Pickhardt PJ, Bhalla S, Balfe DM. Acquired gastrointestinal fistulas: classification, etiologies, and imaging evaluation. *Radiology* 2002;224(1):9–23.
22. Chapman R, Foran R, Dunphy JE. Management of intestinal fistulas. *Am J Surg* 1964;108:157–64.
23. Fischer PE, Fabian TC, Magnotti LJ, Schroepfel TJ, Bee TK, Maish 3rd GO, et al. A ten-year review of enterocutaneous fistulas after laparotomy for trauma. *J Trauma* 2009;67(5):924–8.
24. Chintapatla S, Scott NA. Intestinal failure in complex gastrointestinal fistulae. *Nutrition* 2002;18(11–12):991–6.
25. Osborn C, Fischer JE. How I do it: gastrointestinal cutaneous fistulas. *J Gastrointest Surg* 2009;13(11):2068–73.
26. Slater R. Percutaneous endoscopic gastrostomy feeding: indications and management. *Br J Nurs* 2009;18(17):1036–43.
27. Rabago LR, Ventosa N, Castro JL, Marco J, Herrera N, Gea F. Endoscopic treatment of postoperative fistulas resistant to conservative management using biological fibrin glue. *Endoscopy* 2002;34(8):632–8.
28. Schultz DJ, Brasel KJ, Spinelli KS, Rasmussen J, Weigelt JA. Porcine small intestine submucosa as a treatment for enterocutaneous fistulas. *J Am Coll Surg* 2002;194(4):541–3.
29. Eleftheriadis E, Kotzampassi K. Therapeutic fistuloscopy: an alternative approach in the management of postoperative fistulas. *Dig Surg* 2002;19(3):230–5. discussion 6.
30. Fazio VW, Coutsoftides T, Steiger E. Factors influencing the outcome of treatment of small bowel cutaneous fistula. *World J Surg* 1983;7(4):481–8.
31. Sancho JJ, di Costanzo J, Nubiola P, Larrad A, Beguiristain A, Roqueta F, et al. Randomized double-blind placebo-controlled trial of early octreotide in patients with postoperative enterocutaneous fistula. *Br J Surg* 1995;82(5):638–41.
32. Hesse U, Ysebaert D, de Hemptinne B. Role of somatostatin-14 and its analogues in the management of gastrointestinal fistulae: clinical data. *Gut* 2001;49(4):iv11–21.
33. Alvarez C, McFadden DW, Reber HA. Complicated enterocutaneous fistulas: failure of octreotide to improve healing. *World J Surg* 2000;24(5):533–7.
34. Chariker ME, Jeter KF, Tintle TE, Bottsford JE. Effective management of incisional and cutaneous fistulae with closed suction wound drainage. *Contemp Surg* 1989;34:59–63.
35. Erdmann D, Drey C, Heller L, Wong MS, Levin SL. Abdominal wall defect and enterocutaneous fistula treatment with the Vacuum-Assisted Closure (V.A.C.) system. *Plast Reconstr Surg* 2001;108(7):2066–8.
36. Cro C, George KJ, Donnelly J, Irwin ST, Gardiner KR. Vacuum assisted closure system in the management of enterocutaneous fistulae. *Postgrad Med J* 2002;78(920):364–5.
37. Medeiros AC, Aires-Neto T, Marchini JS, Brandao-Neto J, Valenca DM, Egitto ES. Treatment of postoperative enterocutaneous fistulas by high-pressure vacuum with a normal oral diet. *Dig Surg* 2004;21(5–6):401–5.
38. Wainstein DE, Fernandez E, Gonzalez D, Chara O, Berkowski D. Treatment of high-output enterocutaneous fistulas with a vacuum-compaction device. A ten-year experience. *World J Surg* 2008;32(3):430–5.
39. Cattoni DI, Chara O. Vacuum effects over the closing of enterocutaneous fistulae: a mathematical modeling approach. *Bull Math Biol* 2008;70(1):281–96.
40. Dou Y, Gregersen S, Zhao J, Zhuang F, Gregersen H. Morphometric and biomechanical intestinal remodeling induced by fasting in rats. *Dig Dis Sci* 2002;47(5):1158–68.
41. Boulanger K, Lemaire V, Jacquemin D. Vacuum-assisted closure of enterocutaneous fistula. *Acta Chir Belg* 2007;107(6):703–5.
42. Schecter WP, Hirschberg A, Chang DS, Harris HW, Napolitano LM, Wexner SD, et al. Enteric fistulas: principles of management. *J Am Coll Surg* 2009;209(4):484–91.
43. Martinez JL, Luque-de-Leon E, Mier J, Blanco-Benavides R, Robledo F. Systematic management of postoperative enterocutaneous fistulas: factors related to outcomes. *World J Surg* 2008;32(3):436–43. discussion 44.

44. Woodfield JC, Parry BR, Bissett IP, McKee M. Experience with the use of vacuum dressings in the management of acute enterocutaneous fistulas. *ANZ J Surg* 2006;**76**(12):1085–7.
45. Conter RL, Roof L, Roslyn JJ. Delayed reconstructive surgery for complex enterocutaneous fistulae. *Am Surg* 1988;**54**(10):589–93.
46. Connolly PT, Teubner A, Lees NP, Anderson ID, Scott NA, Carlson GL. Outcome of reconstructive surgery for intestinal fistula in the open abdomen. *Ann Surg* 2008;**247**(3):440–4.
47. Brenner M, Clayton JL, Tillou A, Hiatt JR, Cryer HG. Risk factors for recurrence after repair of enterocutaneous fistula. *Arch Surg* 2009;**144**(6):500–5.
48. Dionigi G, Dionigi R, Rovera F, Boni L, Padalino P, Minoja G, et al. Treatment of high output entero-cutaneous fistulae associated with large abdominal wall defects: single center experience. *Int J Surg* 2008;**6**(1):51–6.
49. Gomez Portilla A, Martinez DeLecea C, Cendoya I, Olabarria I, Kvadatze M. Tratamiento de las fistulas enterocutaneas complejas mediante la técnica de herida-abdomen abierto en vacío (open vacuum-pack) como mejor alternativa terapéutica. *R Cir Esp* 2009;**85**(4):253–63.
50. Demetriades D. A technique of surgical closure of complex intestinal fistulae in the open abdomen. *J Trauma* 2003;**55**(5):999–1001.
51. Wind J, van Koperen PJ, Slors JF, Bemelman WA. Single-stage closure of enterocutaneous fistula and stomas in the presence of large abdominal wall defects using the components separation technique. *Am J Surg* 2009;**197**(1):24–9.
52. Kirkpatrick AW, Baxter KA, Simons RK, Germann E, Lucas CE, Ledgerwood AM. Intra-abdominal complications after surgical repair of small bowel injuries: an international review. *J Trauma* 2003;**55**(3):399–406.
53. de Vries Reilingh TS, Bodegom ME, van Goor H, Hartman EH, van der Wilt GJ, Bleichrodt RP. Autologous tissue repair of large abdominal wall defects. *Br J Surg* 2007;**94**(7):791–803.
54. Eriksen JR, Gogenur I, Rosenberg J. Choice of mesh for laparoscopic ventral hernia repair. *Hernia* 2007;**11**(6):481–92.
55. Brandi CD. Tratamiento de los defectos de la pared abdominal. *Rev Argent Cirug*; 2009. NE. Relato oficial del LXXX Congreso Argentino de Cirugía.
56. Hyon SH, Ceballos C, Argibay PF. Método de compactación y vacío: Tratamiento de fistulas intestinales y extensión de sus indicaciones a heridas quirúrgicas complejas. *Rev Argent Cirug* 2005;**87**(5–6):188–99.