



## Original Article

# DeVega versus ring annuloplasty in severe functional tricuspid insufficiency and their impact on the right ventricle

Yasser Hamdy, Mohammed Mahmoud Mostafa, Ahmed Elminshawy

Department of Cardiothoracic Surgery, Faculty of Medicine, Assuit University, Assuit, Egypt

### Abstract

**Background:** Functional tricuspid valve regurgitation secondary to left-sided valve disease is common. DeVega repair is simple, but residual regurgitation with subsequent impairment of the right ventricular function is a concern. This study aims to compare tricuspid valve repair using DeVega vs. ring annuloplasty and their impact on the right ventricle in the early postoperative period and after six months.

**Methods:** This is a prospective cohort study of 51 patients with rheumatic heart disease who underwent tricuspid valve repair for secondary severe tricuspid regurgitation. Patients were divided into two groups: group A; DeVega repair (n=34) and group B; ring annuloplasty repair (n=17). Patients were assessed clinically and by echocardiography before discharge and after six months for the degree of tricuspid regurgitation, right ventricular diameter and tricuspid annular plane systolic excursion (TAPSE).

**Results:** Preoperative echocardiographic assessment showed no difference in left ventricular end-systolic diameter, end-diastolic diameter, ejection fraction and right ventricular diameter, however; group A had significantly better preoperative right ventricular function measured by TAPSE ( $1.96 \pm 0.27$  vs  $1.75 \pm 0.31$  cm;  $p=0.02$ ). Group B had significantly longer cardiopulmonary bypass time ( $127.65 \pm 13.56$  vs  $111.74 \pm 18.74$  minutes;  $p=0.003$ ) and ischemic time ( $99.06 \pm 11.80$  vs  $87.15 \pm 16.01$  minutes;  $p=0.009$ ). Pre-discharge, there was no statistically significant difference in the degree of tricuspid regurgitation, but the right ventricular diameter was significantly lower in group B ( $2.66 \pm 0.41$  and  $2.40 \pm 0.48$  cm;  $p=0.049$ ). After six months of follow up, the degree of tricuspid regurgitation ( $p=0.029$ ) and the right ventricular diameter were significantly lower in the ring annuloplasty group ( $2.56 \pm 0.39$  and  $2.29 \pm 0.44$  cm;  $p=0.029$ ). Although there was a statistically significant difference in preoperative TAPSE, this difference disappeared after six months.

**Conclusion:** Both DeVega and ring annuloplasty techniques were effective in the early postoperative period, ring annuloplasty was associated with lesser residual regurgitation and better right ventricular remodeling in severe functional tricuspid regurgitation than DeVega procedure after 6-months of follow up.

### KEYWORDS

Functional tricuspid regurgitation; DeVega repair; Ring annuloplasty; Right ventricular function.

### Article History

Submitted: 23 July 2019

Revised: 2 Aug 2019

Accepted: 22 Aug 2019

Published: 1 Oct 2019



## Introduction

The tricuspid valve (TV) is commonly known as the forgotten valve because it is less frequently addressed in the literature [1]. Functional tricuspid valve regurgitation (TR) secondary to left-sided valve lesion is a common cause of TV disease [2]. A growing body of evidence suggests that ignoring a significant functional tricuspid regurgitation (TR) at the time of surgery for left-sided lesions will negatively affect the long-term outcome of the patient [3, 4].

The American College of Cardiology/American Heart Association (ACC/AHA), as well as the European Society of Cardiology (ESC) guidelines for management of valvular heart disease, agreed that intervention for functional tricuspid regurgitation is indicated in patients with severe TR, moderate TR with either tricuspid annular dilatation (greater than 40 mm) or tricuspid index higher than 21 cm/m<sup>2</sup> [5, 6].

Non-prosthetic DeVega repair is a simple repair technique; however, there are concerns regarding residual TR, recurrence of symptoms, right ventricular functional impairment and subsequent poor patient functional status which lead to the introduction of prosthetically supported repairs [7, 8].

Current recommendations of TV repair technique remain controversial. This study aims to assess the early and midterm outcome of DeVega versus ring annuloplasty in severe functional tricuspid and their impact on right ventricular function and dimension in the early postoperative period and after six months.

## Patients and Methods:

### Patients cohort

After institutional review boards (IRB) approval, we performed a prospective cohort study of 51 consecutive rheumatic patients with severe functional TR who presented in the period between 2016-2019 for mitral valve or mitral and aortic valve surgery. Informed consent was obtained from all patients enrolled in the study. We excluded ischemic heart disease patients, organic TV disease, and patients with associated congenital anomalies from our study. We divided patients into two groups (group A) who had DeVega repair (n=34) and (group B) who had ring

annuloplasty repair (n=17). We compared the clinical and echocardiographic data before discharge and after six months of follow up.

### Preoperative data.

In group A, 12 patients complained of dyspnea grade II; on the other hand, six patients in group B had grade II dyspnea. Twenty-one patients in group A had grade III dyspnea in contrast to 10 patients in group B. One patient in each group had grade IV dyspnea. There was no statistically significant difference between both groups in clinical data. There was no significant difference in both groups regarding left ventricular end-systolic diameter (LVESD), left ventricular end-diastolic diameter (LVEDD), ejection fraction (EF), pulmonary artery systolic pressure (PASP), and right ventricular diameter (RVD). The transannular plane systolic excursion (TAPSE) was significantly higher in DeVega group (P value= 0.017) (Table 1).

### Operative technique

All patients had the operation performed through a median sternotomy, cardiopulmonary bypass, and antegrade crystalloid cardioplegia with systemic cooling. Mitral valve replacement was performed in all patients. Three patients in group A had concomitant aortic valve replacement in contrast to one patient in group B. After completion of left-sided valve surgery, both vena cavae were snared, and the right atrium was opened to repair the tricuspid valve on the arrested heart. In DeVega patients, a double-armed 3-0 poly-propylene stitch with Teflon pledgets was used starting at the posteroseptal commissure reaching the anteroseptal commissure aiming to decrease the annulus size at the level of posterior and anterior leaflets. The degree of narrowing of the annulus was controlled over a valve sizer, (25- 29 mm).

In the ring annuloplasty group, we used Contour 3D Annuloplasty rings (Medtronic, California, US). U shaped 2-0 braided polyester stitches were applied to the annulus from the anteroseptal commissure to the posteroseptal commissure. The size of the ring was determined by the length of the septal leaflet. Stitches were applied to the ring and tied. The intra-operative

Table 1: The preoperative clinical characteristics and echocardiographic data. (continuous variables are presented as mean  $\pm$  standard deviation and categorical variables as number and percent)

	Group A (n= 34)	Group B (n= 17)	P-value
Male	11 (32.4%)	6 (35.3%)	0.834
Age (years)	43.79 $\pm$ 14.87	45.53 $\pm$ 14.47	0.694
Mitral valve disease	34 (100.0%)	17 (100.0%)	--
Mitral stenosis	11 (32.4%)	6 (35.3%)	0.503
Mitral regurgitation	7 (20.6%)	5 (29.4%)	0.834
Double mitral lesion	16 (47.1%)	6 (35.3%)	0.424
Aortic valve disease	3 (8.8%)	1 (5.9%)	>0.99
Severe Tricuspid regurgitation	34 (100.0%)	17 (100.0%)	--
LVESD (cm)	3.91 $\pm$ 0.61	4.02 $\pm$ 0.47	0.520
LVEDD (cm)	5.18 $\pm$ 0.66	5.38 $\pm$ 0.68	0.324
EF%	57.82 $\pm$ 5.30	56.06 $\pm$ 5.76	0.281
TAPSE (cm)	1.96 $\pm$ 0.27	1.75 $\pm$ 0.31	0.017
PASP	58.26 $\pm$ 14.44	64.24 $\pm$ 20.95	0.239
RV diameter (cm)	2.72 $\pm$ 0.46	2.46 $\pm$ 0.49	0.076

LVESD; left ventricular end-systolic diameter, LVEDD; left ventricular end-diastolic diameter, EF; ejection fraction, TAPSE; trans annular plane systolic excursion, PASP; pulmonary artery systolic pressure, RV; right ventricle

assessment was done by bulb syringe test, and in most cases repair was desirable.

### Definitions

Dyspnea was assessed according to New York Heart Association (NYHA) functional classification [9]. We determined the severity of tricuspid regurgitation by 2D echocardiography and classified it as trace, mild (<5cm<sup>2</sup>), moderate (5-10 cm<sup>2</sup>) severe (>10 cm<sup>2</sup>) according to the regurgitant jet area [10]. We determined the RV function according to TAPSE value. Normal value is more than 1.7cm. Right ventricular (RV) diameter was measured at the mid cavity [11].

### Statistical analysis

Data entry and analysis were performed using SPSS version 19 (Statistical Package for Social Science, IBM Corp- Chicago- IL- USA). Data were presented as numbers, percentage, mean, and standard deviation. Chi-square test and Fisher Exact test were used to compare qualitative variables. Independent samples t-test test was used to compare two quantitative variables in both groups. Paired samples t-test was done to compare preoperative and postoperative quantitative variables in the same group. P-value was considered statistically significant when < 0.05.

Table 2: Operative and postoperative outcomes. (continuous variables are presented as mean $\pm$  standard deviation and categorical variables as number and percent)

	Group A (n= 34)	Group B (n= 17)	P-value
CPB time (min)	111.74 $\pm$ 18.74	127.65 $\pm$ 13.56	0.003
Cross clamp time (min)	87.15 $\pm$ 16.01	99.06 $\pm$ 11.80	0.009
Post-operative bleeding	3 (8.8%)	0	0.542
Re-exploration for bleeding	3 (8.8%)	0	0.542
Duration of MV (hours)	6.71 $\pm$ 3.54	5.94 $\pm$ 2.14	0.418
ICU stay (days)	2.44 $\pm$ 0.70	2.59 $\pm$ 1.28	0.597
Hospital stay (days)	9.79 $\pm$ 1.87	9.24 $\pm$ 3.56	0.464

CPB; cardiopulmonary bypass, MV; mechanical ventilation, ICU; intensive care unit

## Results

Cardiopulmonary bypass and ischemic times were higher in group B (p-value= 0.003 and 0.009; respectively). There were no mortalities in both groups. All patients had a smooth postoperative course, as summarized in Table 2.

### Pre-discharge clinical data

In group A, two patients complained of dyspnea grade II, and no patient had lower limb edema. In group B, one patient complained of dyspnea grade II, and no patient had lower limb edema.

### Pre-discharge echocardiographic data

Echo data before discharge showed that all patients had well-functioning prosthetic mitral and aortic valves. Both TAPSE (P=0.050) and RV diameter (P =0.049) were higher in group A, as shown in Table 3.

### Clinical data after six month

In group A, two patients had dyspnea grade II, and two patients had lower limb edema. Two patients had hospital readmission for right-sided heart failure. In group B, no patient had dyspnea, lower limb edema, or hospital readmission for right-sided heart failure. There was no significant difference in clinical data between both groups (p=0.5).

Table 3: Echocardiographic data before discharge. (continuous variables are presented as mean± standard deviation and categorical variables as number and percent)

	Group A (n= 34)	Group B (n= 17)	P-value
<b>Degree of tricuspid regurgitation</b>			
Trace	5 (14.7%)	4 (23.5%)	0.719
Mild	19 (55.9%)	9 (52.9%)	
Moderate	10 (29.4%)	4 (23.5%)	
<b>LVEDD (cm)</b>	3.83 ± 0.56	3.94 ± 0.48	0.486
<b>LVEDD (cm)</b>	5.02 ± 0.56	5.11 ± 0.74	0.616
<b>EF (%)</b>	56.62 ± 3.30	55.12 ± 3.94	0.158
<b>TAPSE (cm)</b>	2.05 ± 0.27	1.86 ± 0.40	0.05
<b>EPASP (mmHg)</b>	34.82 ± 5.70	36.24 ± 7.40	0.454
<b>RV diameter (cm)</b>	2.66 ± 0.41	2.40 ± 0.48	0.049

LVEDD; left ventricular end-systolic diameter, LVEDD; left ventricular end-diastolic diameter, EF; ejection fraction, TAPSE; trans annular plane systolic excursion, EPASP; estimated pulmonary artery systolic pressure, RV; right ventricle

### Echocardiographic data after six months

All patients in group A and B had well-functioning prosthetic valves after six months. RV diameter was significantly higher in group A (P-value = 0.029). There was a significant difference in residual tricuspid regurgitation between both groups, which was better in group B (P=0.029), as shown in Table 4.

Right ventricular function as measured by TAPSE improved significantly in the early postoperative period and after six months in both groups (p< 0.005). Although there was a statistically significant difference in preoperative and early postoperative TAPSE, this difference disappeared after six months (Figure 1). PASP improved in the early postoperative period and after six months in both groups (p< 0.005) (Figure 2).

### Discussion

Management of moderate or lesser degree of functional tricuspid valve regurgitation secondary to left-sided valve disease is still controversial. However, the long-term outcome is improved after correction of severe tricuspid regurgitation during left-sided valve surgery. The ideal repair technique is still a subject of ongoing researches.

Table 4: Echocardiographic data after six months. (continuous variables are presented as mean± standard deviation and categorical variables as number and percent)

	Group A (n= 34)	Group B (n= 17)	P-value
<b>Degree of tricuspid regurgitation</b>			
Trace	4 (11.8%)	7 (41.2%)	0.029
Mild	17 (50%)	9 (52.9%)	
Moderate	9 (26.5%)	1 (5.9%)	
Severe	4 (11.8%)	0	
<b>ESD (cm)</b>	3.70 ± 0.49	3.88 ± 0.45	0.198
<b>EDD (cm)</b>	4.92 ± 0.54	5.11 ± 0.49	0.245
<b>EF (%)</b>	58.15 ± 2.95	57.47 ± 3.57	0.475
<b>TAPSE (cm)</b>	2.11 ± 0.25	1.99 ± 0.28	0.137
<b>PASP (mmHg)</b>	31.38 ± 6.72	31.59 ± 5.94	0.915
<b>RV diameter (cm)</b>	2.56 ± 0.39	2.29 ± 0.44	0.029

LVESD; left ventricular end-systolic diameter, LVEDD; left ventricular end-diastolic diameter, EF; ejection fraction, TAPSE; trans annular plane systolic excursion, PASP; pulmonary artery systolic pressure, RV; right ventricle

Some investigators reported a high incidence of recurrence after DeVega repair, particularly in patients with severe annular dilatation, and they recommended the use of annuloplasty rings to obtain a more durable repair [7,8]. Few studies reported the effect of each repair on right ventricular function and remodeling, which may have an impact on long-term survival. In our research, we examined the effect of each repair technique on TAPSE and RV diameter.

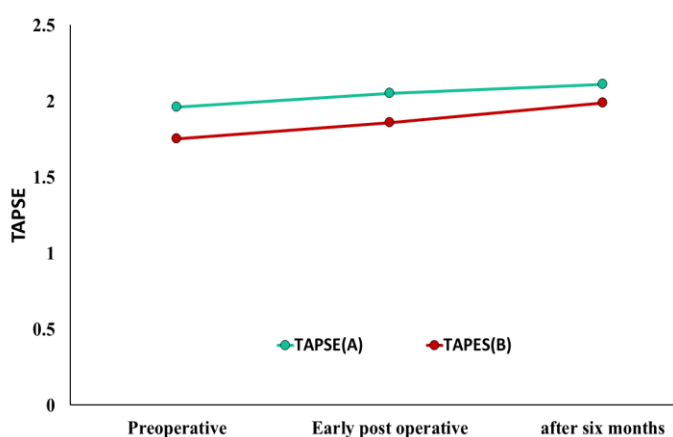


Figure 1: Tricuspid annular plane systolic excursion (TAPSE) at the baseline, early postoperative period, and after six months of follow up

This study shows no statistically significant difference between DeVega repair and ring annuloplasty in term of degrees of tricuspid regurgitation in the early postoperative period ( $p=0.719$ ), but there was significant difference after

six months between both groups which was better with ring annuloplasty ( $p$  value= 0.029). Additionally, there was significant difference in bypass and ischemic time which was higher in ring group ( $p$  values= 0.003 and 0.009; respectively), but the longer ischemic time is accepted for the more durable repair of the tricuspid valve.

Our result is consistent with Basel and colleagues [12] who studied 129 patients with severe secondary tricuspid regurgitation and found that the number of patients who developed residual TR was significantly lower in the ring group. Ren and colleagues [13] found that ring annuloplasty was associated with improved survival, decreased TR recurrence and higher quality of life in rheumatic heart disease patients undergoing tricuspid valve repair combined with mitral and/or aortic valve replacement. Matsuyama and colleagues [14] retrospectively studied 45 patients who underwent surgery for secondary TR, and they found that there was a significant difference in TR recurrence between the groups ( $p = 0.027$ ), but no significant difference in NYHA class. These results are consistent with our results. On the other hand, Khallaf and colleagues [15], Abdelfattah and colleagues [16], and Dokhan and colleagues [17] found that there was no statistically significant difference between DeVega and ring repair in the early postoperative period and during follow up.

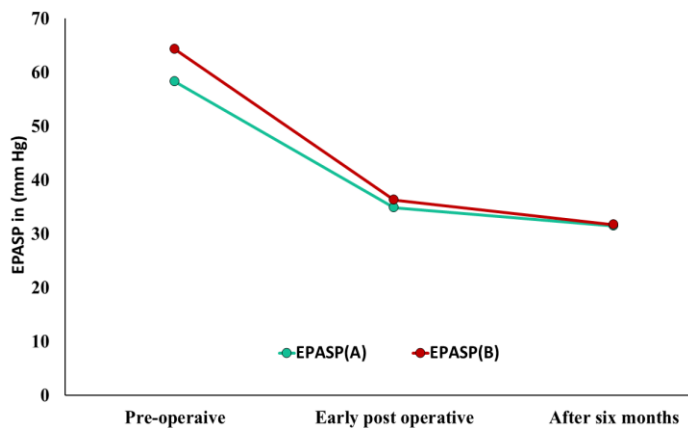


Figure 2: Pulmonary artery systolic pressure (PASP) at baseline, early postoperative, and after six months

We found that the right ventricular function measured by TAPSE improved significantly in the early postoperative period and after six months in both groups. The immediate improvement in TAPSE in the early postoperative period may be attributed to the reduction in PASP and RV afterload in both groups postoperatively. Although there were statistically significant differences in preoperative and early postoperative TAPSE between both groups, this difference disappeared after six months. Desai and colleague [18] studied right ventricular function after mitral valve surgery with or without concomitant tricuspid valve repair, and they found that in patients with mitral valve disease and severe TR, mitral valve repair alone was associated with improved TR and right ventricular function early after surgery, as mitral valve surgery with concomitant tricuspid valve repair do.

After TV repair, this improvement continued, but without TV repair, RV function started to progressively decline at six months in parallel with the return of TR to the preoperative level. At three years, TAPSE was normal after TV repair. However, without TV repair, both TR and RV dysfunction had returned to preoperative levels. This study reflects the importance of competent repair on TAPSE and RV function on long-term outcome.

In our study, we found a statistically significant difference in RV diameter between both groups early and after six months ( $p$  value= 0.049 and 0.029; respectively), despite improvement in both groups. These results support that concomitant tricuspid valve repair secondary to the left-sided lesion is vital for right ventricular remodeling and remodeling is better with ring repair. Philippe and colleagues [19] found similar results when they

observed the change in RV geometry in TV repair patients. Only in control patients, indexed RV end-diastolic area increased significantly. In TV repair patients, there was a significant decrease in RV end-diastolic area, and they concluded that adding TV repair to mitral valve surgery in patients with more than moderate TR leads to favorable changes in RV geometry and prevents postoperative RV dilation.

### Study limitations

This study has the following limitations: first, it is a single-center study of small numbers of patients. Secondly, the method of tricuspid repair was chosen by the operating surgeon; therefore, there is a possibility of selection bias. Lastly, the study is not a randomized clinical trial, and several factors could have affected the outcome other than the repair method. However, the study evaluated the two repair techniques in a special subset of patients with rheumatic heart disease who are understudied in the literature.

### Conclusion

Both DeVega and ring annuloplasty techniques for management severe functional secondary tricuspid regurgitation are effective in the early postoperative period. However, ring annuloplasty was associated with lesser residual regurgitation, and better right ventricular remodeling in 6-months follow up.

**Conflict of interest:** Authors declare no conflict of interest.

### References

1. Avierinos JF. [Tricuspid valve: the forgotten valve?](#) Rev Prat. 2009; 59 (2): 215–217.
2. Ruel M, Rubens FD, Masters RG, Pipe AL, Bédard P, Mesana TG. [Late incidence and predictors of persistent or recurrent heart failure in patients with mitral prosthetic valves.](#) J Thorac Cardiovasc Surg. 2004; 128 (2): 278–283.
3. Yoda I, Tani K, Shimono T, Shikano K, Okabe M, Kusagawa M. [Preoperative evaluation and surgical treatment of tricuspid regurgitation associated with acquired valvular heart disease. The Kay-Boyd method versus the Carpentier - Edwards ring method.](#) J Cardiovasc Surg. 1990; 31 (6): 771-777.

4. Konishi Y, Taksuta N, Mirami K, et al. [Comparative study of Kay- boyd's, Devega's and Carpentier annuloplasty in the management of functional tricuspid regurgitation](#). *Jpn Circ J*, 1983; 47 (10): 1167-1172.
5. Baumgartner H, Falk V, Bax JJ, et al. ESC Scientific Document Group. 2017 ESC/EACTS Guidelines for the management of valvular heart disease. *Eur Heart J*. 2017; 38: 2739-91.
6. Nishimura RA, Otto CM, Bonow RO, et al. [2017 AHA/ACC Focused Update of the 2014 AHA/ACC Guideline for the Management of Patients With Valvular Heart Disease: A Report of the American College of Cardiology/American Heart Association Task Force on Clinical Practice Guidelines](#). *Journal of the American College of Cardiology*. 2017; 70(2): 252-89.
7. Lapar DJ, Mulloy DP, Stone ML, et al. [Concomitant tricuspid valve operations affect outcomes after mitral operations: a multi institutional, statewide analysis](#). *Ann Thorac Surg*. 2012; 94 (1): 52–58.
8. Sarralde JA, Bernal JM, Llorca J, et al. [Repair of rheumatic tricuspid valve disease: predictors of very long-term mortality and reoperation](#). *Ann Thorac Surg*. 2010; 90 (2): 503–508.
9. Dolgin M and New York Heart Association. *Nomenclature and Criteria for Diagnosis of Diseases of the Heart and Great Vessels* (9th ed.). Boston: Little, Brown & Co. 1994: 253–256.
10. Lancellotti P, Moura L, Pierard LA, et al., [European Association of Echocardiography recommendations for the assessment of valvular regurgitation. Part 2: mitral and tricuspid regurgitation \(native valve diseases\)](#). *Eur J Echocardiogr* , 2010; 11 (4): 307-332.
11. Lang RM, Badano LP, Mor-Avi V, et al. [Recommendations for cardiac chamber quantification by echocardiography in adults: an update from the American Society of Echocardiography and the European Association of Cardiovascular Imaging](#). *European Heart Journal-Cardiovascular Imaging*. 2015; 16 (3): 233-271.
12. Basel H, Aydin U, Kutlu H, et al. [Outcomes of De Vega versus biodegradable ring annuloplasty in the surgical treatment of tricuspid regurgitation \(mid-term results\)](#). *Heart Surg Forum*. 2010; 13 (4): 233–237.
13. Wen-Jun R, Ben-Gui Z, Jia-Sheng L, Yong-Jun Q, Ying-Qiang G. [Outcomes of tricuspid annuloplasty with and without prosthetic rings: a retrospective follow-up study](#). *Journal of Cardiothoracic Surgery*, 2015; 10 (81): 1-7.
14. Matsuyama K, Matsumoto M, Sugita T, et al. [De Vega annuloplasty and Carpentier-Edwards ring annuloplasty for secondary tricuspid regurgitation](#). *J Heart Valve Dis*. 2001; 10 (4): 520–4.
15. Khallaf AN, Saleh HZ, Elnaggar AM, Rasekh FS. [Tricuspid valve repair by DeVega technique versus ring annuloplasty in patients with functional severe tricuspid regurgitation](#). *J Egyptian Soc Cardio-Thorac Surg*. 2016; 24 (2): 131-134
16. Abdelfattah I, Omar A. [Early outcome of tricuspid repair for functional tricuspid regurgitation associated with rheumatic mitral valve disease. Modified flexible band annuloplasty versus suture annuloplasty](#). *J Egypt Soc Cardio-thorac Surg*, 2014; 22 (3): 13-17.
17. Dokhan AL, Ibrahim IM, Alkhateeb Y, Mohamed H. [Concomitant repair of moderate tricuspid regurgitation in patients undergoing mitral valve surgery](#). *Menoufia Medical Journal*. 2015; 28 (1): 34-37.
18. Desai RR, Abello LMV, Klein AL, et al. [Tricuspid regurgitation and right ventricular function after mitral valve surgery with or without concomitant tricuspid valve procedure](#). *J Thorac Cardiovasc Surg*. 2013; 146 (5): 1126–1132.
19. Bertrand P.B., Koppers G., Verbrugge F.H, et al. [Tricuspid annuloplasty concomitant with mitral valve surgery: Effects on right ventricular remodeling](#). *J Thorac Cardiovasc Surg*. 2014; 147 (4): 1256-1264.