

**Original Article****Chest wall reconstruction still has place in Today's modern practice:" a tertiary center experience"****Amr Ibrahim Abd Elaal Osman<sup>1</sup>, Mohamed A. K. Salama Ayyad<sup>2</sup>, Hussein Elkhayat<sup>1</sup>, Ali A. Elwahab<sup>2</sup>**<sup>1</sup> Cardiothoracic Surgery Department, Assuit University Hospitals, Assuit, Egypt<sup>2</sup> Cardiothoracic Surgery Department, Assuit University, Assuit, Egypt**Abstract**

**Background:** The key factor following chest wall resection is the preservation of the stability and integrity of the chest wall to support the respiration and protect the underlying organs. The present study aims to evaluate the use of the available grafts and prosthetic materials at our center in chest wall reconstruction with adherence to the proper surgical techniques, good perioperative and postoperative care to obtain good results.

**Methods:** This is a retrospective single center study that concludes all patients underwent chest wall reconstruction for a variety of defects resulting from resection of tumors, trauma due to primarily firearms or motor car accidents, resection of radio necrotic tissues, infection and dehiscence of median sternotomy wounds after cardiac surgery.

**Results:** Study population consisted of 30 patients between January 2015 and may 2018, among them were 20 male (70%) and 10 female patients (30%), with a median age of  $43 \pm 16.3$  years, resection and reconstruction was performed in 23 cases (15 neoplastic, 5 infective and 3 firearm cases) while reconstruction alone was performed in 7 (traumatic flail chest) cases. Eighteen patients, underwent rib resection with an average  $4.18 \pm 2.2$  ribs (range 2-6). Associated lung resection was performed in 5 patients (27.8 %): diaphragmatic resection was done in 2 cases in addition total sternal resection was performed in 5 cases. Most of the patients (96.7%) had primary healing of their wounds. there was one death (3.3%) in the early postoperative period. The average length of hospital stay for all patients was 8.7 days (range: 5–15). Respiratory complications occurred in three cases in the form of atelectasis and pneumonia at the ipsilateral side of reconstruction. Three cases suffered wound seroma which successfully managed by daily dressing and antibiotic coverage.

**Conclusions:** according to our study and the analysis of similar studies, adequate perioperative preparation of patient undergoing chest wall resection and reconstruction with adherence to effective surgical techniques allowed us to use the available materials at our center for chest wall reconstruction with good and effective results without adding burden in terms of cost on the patient.

**KEYWORDS**Chest wall reconstruction;  
Prosthetic materials;  
Omental flap**Article History**

Submitted: 20 Feb 2019

Revised: 10 Apr 2019

Accepted: 23 Apr 2019

Published: 1 July 2019



## Introduction

Meanwhile the 1980s, there is a wide range of prosthetic materials including polypropylene mesh, polypropylene mesh–methyl methacrylate composites and polytetrafluoroethylene, and also the use of myocutaneous flaps have allowed effective reconstruction of chest wall defects including the large one [1]. The importance of chest wall reconstruction has been highlighted by old reports and revised recently, and there are still arguments as which chest wall defects should be reconstructed, the site of the defect, the number of the resected ribs (other than the length of resection), and the amount of sternal resection also influence the need for reconstruction. Other tissues resection (lung and diaphragm) and any concomitant disease (heart failure, chronic lung disease) should also be taken into account [2, 3].

The defects of the chest wall can be categorized into acquired and congenital ones. They can include soft tissues, bony structures or both. Numerous pathological processes such as neoplasm, trauma, radiation injury and infection can contribute to the development of acquired defects. Congenital defects such as, sternal defects or Poland Syndrome, these defects are less common and usually asymptomatic, but they can cause cosmetic or cardiopulmonary embarrassment and still poses a reconstructive challenge.

Initial efforts for chest wall resection were affected by the presence of appropriate materials for reconstruction. Original materials used for chest wall reconstruction included autogenous tissue such as rib grafts, fascia lata grafts and large cutaneous grafts. after the first recognized chest wall resection in the 18th century, various modifications in surgical techniques including the improvement in reconstruction techniques and also the advances in anesthesia, with the development of new antibiotics and the extended use of ventilatory support have allowed the performance of chest wall resection even the extensive one with a great improvement in outcome [4].

The selection of reconstructive prostheses is confusing. Various materials are available, and they work with the same goal. Most of the choices are affected by the surgeon's preference. What should be used in clean wounds, and what for

unclean ones, PM is more tough than PTFE to expand and seal without folds and surface irregularities and does not accomplish a watertight closure of the pleural space. In contrast, PTFE, can be sutured, stretched, and molded into the wound at ease and provides a watertight closure of the pleural space [5].

Most up-to-date chest wall resections methods have been approached via customized titanium implants, fabricated by selective laser sintering (SLM) or, most recently, by (3D) printed technology. Constructing a 3D model of bone structures by using CT image data have the advantage of both accurate prosthesis design and also allows proper perioperative visualization of the defect for decision making and detailed planning of the repair [6].

We evaluated the use of the available grafts and prosthetic materials at our center in chest wall reconstruction with adherence to the proper surgical techniques, good perioperative and postoperative care to obtain good results.

## Patients and Methods:

This is a "retrospective single center observational study" conducted in cardiothoracic surgery department at Assiut University hospitals in the period between January 2015 and May 2018. After receiving approval from our ethics committee and an informed written consent was obtained, all the patients with thoracic wall defects who require concomitant reconstruction were included in the study. Cases were divided into three groups based on their indication for chest wall resection and reconstruction, group I (chest wall tumor n=15) group II (chest wall trauma n=10) group III (chest wall infection n=5).

Complete data from these patients were collected for analysis. Patients with Comorbidities (heart failure or the presence of contralateral lung disease), pregnancy and disseminated disease stage were excluded from the study. All patients in the study were subjected to full medical history and thorough examination for all systems especially chest examination for raised JVP or cervical lymphadenopathy, the breathing pattern and use of accessory muscles- Inspection for abnormalities in shape or the presence of any scar-Mass (site, size, shape, mobility, consistency and invasion to underlying ribs) also Abdominal

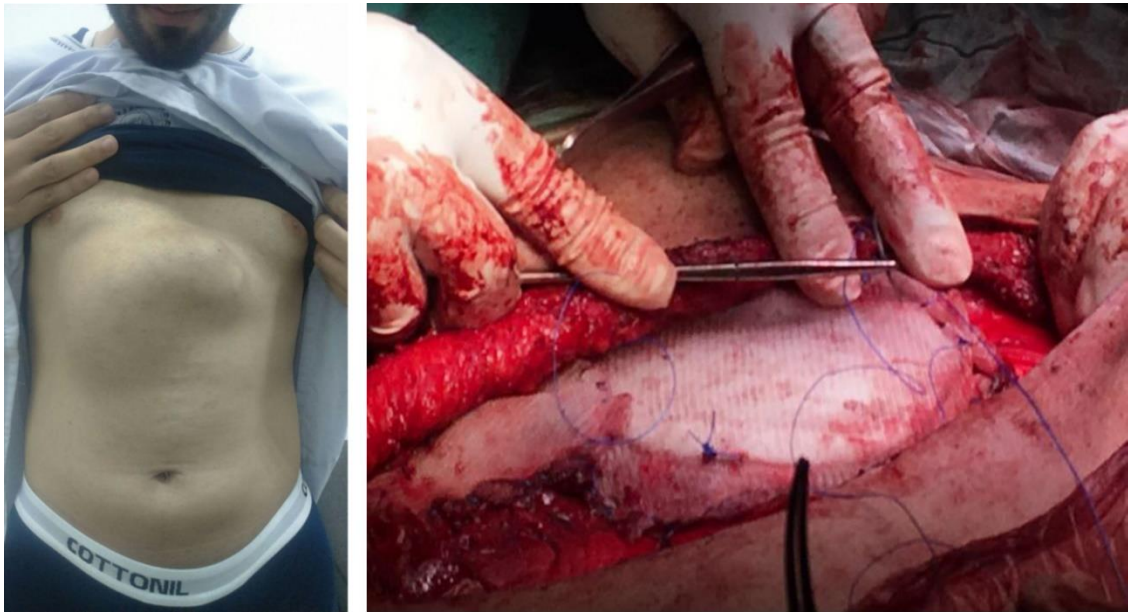


Figure 1: Sternal Tumor (liposarcoma) in male patient 40 years old with total sternal resection and reconstruction by methylmethacrylate and double proline mesh fixed to the costal cartilages.

examination- for any surgical scar, muscle condition or any palpable organs.

#### Pre-operative workup

Routine Laboratory investigations: radiological imaging including Chest X-ray anteroposterior and lateral view, CT scan and/or MRI, Pulmonary function test perioperative to determine the baseline of the patient, Perioperative biopsy from the mass or the ulcer and Metastatic work up to exclude any distant metastasis as abdominal ultrasound, C.T scans of the whole body and bone scan, Blood gases analysis was the corner-stone in

patient's evaluation either preoperatively or postoperatively In cases of chest trauma, and Culture and sensitivity for the appropriate antibiotic and eradication of the organisms before surgery In cases of chest wall infection.

#### Surgical procedure

All surgical interventions were performed under general anesthesia and intrathecal morphia to ameliorate postoperative pain, single or double lumen endobronchial tube was used according to lung involvement. After induction, antibiotic prophylaxis was given.

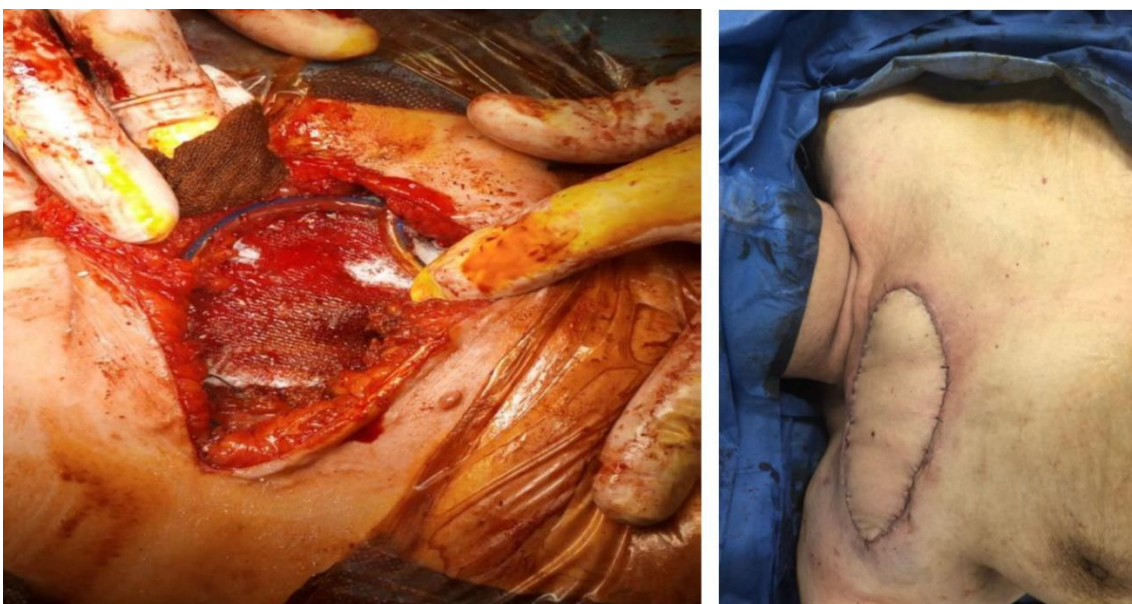


Figure 2: Female patient with recurrent chondrosarcoma reconstructed by proline mesh and split skin graft, intercostal tube and subcutaneous drain removed after five days the patient discharged home after one week.



### Chest wall resection

All cases were approached via thoracotomy in the lateral decubitus position except for anterior lesion or sternal lesion the patient was in supine position. Patient position may be changed according to site of the flap to allow flap harvest. The incision and interspace through which the thoracotomy is made were carefully planned by viewing the CT scan so as not to disrupt the tumor. In cases of trauma, the incision was made over the affected area either longitudinal or transverse or the standard thoracotomy incision. The surgery was started with an examination of the skin and subcutaneous tissue, if the skin and subcutaneous tissues were adherent or infiltrated; a full-thickness chest wall resection is often indicated. Also, the previous biopsy needle tracts and scars were excised.

The surgical resection was started from one side of the mass to the other side with the removal of chest wall muscle, the affected ribs together with the parietal pleura, the safety margin include rib above and below with the anterior and posterior margins transected about one and a half inch. The lung and mediastinal structures which were involved were resected in bloc.

In cases of trauma, Patients with gunshot were operated upon as emergency cases. After patient positioning usually in the lateral decubitus position, the ipsilateral thoracic cavity was explored and managed for any lesion of the lung and pleural cavity, then the intercostal tube was inserted, Area deficient of rib and intercostal muscle was debrided adequately with the removal of all devitalized ribs and muscles.

Patients with poststernotomy mediastinitis were managed perioperatively by frequent dressing and appropriate antibiotics until the wound appear clean then the patient was subjected to surgery. During surgery, the wound was opened through the previous incision, the sternum is not totally adherent to the heart and bypass grafts so wide debridement with resection of affected costal cartilages on both sides and part of pectoralis major muscle were done.

In cases of Osteoradionecrosis, first the malignancy should be excluded, then wound care start by daily dressing with antibiotics according to culture and sensitivity for two weeks until the

infection disappears, then the patients were prepared to surgery. All Patients where operated in the supine position and under general anesthesia, the ulcer was excised until a healthy margin was reached and all necrotic ribs were excised.

### Chest wall Reconstruction

The chest wall reconstruction modality was determined for each case individually; considering the patient's requirements, the chest wall defect characteristics, and the surgeon's expertise. The type and the cost of the material, flexible or rigid and absorbable or non-absorbable characteristics, a porous or solid consistency, the ease of suturing, the risks of implant infection, the influence on pulmonary mechanics, and cosmetics were all important considerations. Reconstruction of chest wall defects was carried out using prosthetic materials (Polypropylene mesh - Composite prosthesis - Plates and screws) (Figure 1 & Figure 2) and autologous materials. (Omental patch - Transverse rectus abdominis myocutaneous flap - latissimus dorsi muscle flap).

### Postoperative Management

All patients were extubated immediately after surgery and transferred to the recovery room for control during the first 6-8hours where they were evaluated for the need for ICU, mechanical ventilation or booster dose of intrathecal morphia.

Early Postoperative Studies: If the patient was transferred to the ICU the details of the ICU course was recorded including; ICU stay, ventilation hours and oxygen saturation. If no complications were recognized, the patient was returned to the ward where physical activity was initiated in the morning after surgery. Then patients were followed up during hospital stay including the need for supplemental oxygen, cough reflex whether by pharmacological or by self, duration of internal chest drainage and postoperative pulmonary function.

### Complications

Postoperative complications were considered early if it occurred within 30 days and included:

- Pulmonary in the form of pneumonia or atelectasis as identified by X-ray or CT of the chest.

- Local wound infections were defined as culture positive infections within the cavity adjacent to the reconstructed chest wall.
- Wound seroma was defined as wound discharge without fever and without culture positive identification of a pathogenic organism.

**Statistical analysis**

Data entry and data analysis were done using SPSS version 19 (IBM SPSS 17, 18 and 19: A Guide for Social Scientists. New York: Routledge). Data were presented as number, percentage, mean, standard deviation. Wilcoxon Signed Rank Test was done to compare quantitative variables between pre and post-operative data in case of non-parametric data. Multiple logistic regression analysis was done to measure the risk factors. P-value considered statistically significant when P < 0.05.

**Results**

**Preoperative data**

Study population consisted of 30 patients among them were 20 male (70%) and 10 female patients (30%), with a median age of 43 ± 16.3 years.

Chest wall tumor was the most common indication for chest wall reconstruction (50%), followed by traumatic lesions (33.3%) and infective lesions represented (16.7%) (Table 1).

Table 1: Indications for chest wall resection

Indications	No. (30)	%
Tumor	15	50
Traumatic	10	33.3
Infection	5	16.7

Table 2: Associated medical condition.

Associated medical condition	No. (30)	%
DM	1	3.3
HTN	2	6.7
DM & HTN	6	20
IPF	1	3.3
COPD	1	3.3
No	19	63.3

DM: Diabetes mellitus; HTN: Hypertension; IPF: Interstitial pulmonary fibrosis; COPD: Chronic obstructive pulmonary disease

Co-morbidities included chronic obstructive pulmonary disease (COPD) in one patient, diabetes mellitus (DM) in one patient,

hypertension in two patients, diabetes and hypertension in six patients (Table 2).

**Surgical data**

Chest wall resection and reconstruction were performed in 23 cases while chest wall reconstruction alone was performed in 7 (traumatic flail chest) cases. eighteen patients, (tumor, trauma, and infection), underwent rib resection with an average 4.18 ± 2.2 ribs (rang 2-6) (Table 3 & Table 4).

Table 3: Distribution of lesions in different sites of chest wall

Indications	No. (30)	%
Anterolateral	15	50
Lateral	9	30
Central	5	16.7
Posterolateral	1	3.3

Concomitant lung resection was performed in 5 patients (27.8%) three wedge resections, one lobectomy and one bilobectomy. diaphragmatic resection was done in 2 cases in addition total sternal resection was carried out in 5 cases. Immediate reconstruction was undertaken in all patients, with the double proline mesh with myocutaneous flap (TRAM and latissimus dorsi) were the commonly employed for closure of the defect (Table 5).

**Immediate (early) Postoperative Data**

Immediate postoperative extubation was performed in all patients, with no need for postoperative mechanical ventilation as indicated by arterial blood gases and oxygen saturation These patients were transported to intermediate care and were closely observed 48 hours postoperatively for respiratory movement, signs of respiratory distress, restlessness and irritability. one female patient with osteoradinecrosis developed chest infection which was managed by non-invasive ventilation which was ineffective and progressed to invasive one, also she developed ischemia due to venous congestion of the musculocutaneous flap requiring an additional procedure from the plastic surgeons but the patient died at postoperative day 5.

**Hospital stays:**

Patients were discharged at a mean of 9 days. Most of the patients (96.7%) had primary healing

Table 4: Causes of chest wall defects

<b>Etiology</b>	<b>No. (30)</b>	<b>%</b>
<b>Chest wall tumor</b>		
Chondrosarcoma	7	23.3
Osteogenic sarcoma	2	6.7
Round cell malignancy	2	6.7
Sternal liposarcoma	2	6.7
Rhabdomyosarcoma	1	3.3
Mesothelioma invading the chest wall	1	3.3
<b>Chest wall trauma</b>		
Gunshot (loss of chest wall)	4	13.3
MCA (flail chest)	6	20
<b>Chest wall infection</b>		
Poststernotomy mediastinitis	3	10
Radionecrosis	2	6.7

of their wounds. there was one death (3.3%) in the early postoperative period,

### Complications

There were 11 patients developed postoperative complications 3 of them developed wound infection, one patient developed a hematoma, 3 patients developed Respiratory complications in the form of atelectasis and pneumonia at the ipsilateral side of reconstruction, one patient developed an abdominal incisional hernia after omental transposition and 3 patients developed wound theroma (Table 6).

### Follow up

Follow up was complete in 24 out of 30 patients and ranged from (6-40 months) (four chest wall tumor cases and two trauma cases were lost at follow up). The survival rate at 12 months was 88.3%and at 24 months it was 78.4 %.

### Recurrence rate

The recurrence was reported in one case out of 15 tumor cases. The patient did not complete his chemo and radiotherapy course, the recurrence was on the same side and of the same malignancy (round cell malignancy).

### Discussion

Chest wall reconstruction should be approached in an algorithmic fashion that involves a multi-step process. First the patient general medical condition should be evaluated with special consideration of the cardiac, pulmonary and nutritional status. Preoperative adjustment of cardiac, pulmonary and nutritional insufficiencies can enhance recovery and reduce complications in the postoperative period.it is well known that some degree of pulmonary dysfunction is almost invariably seen in the postoperative period, identification of patients at risk for development of postoperative respiratory problems, such as failed extubation and prolonged ventilator dependence is paramount [7].

Table 5: Methods of chest wall reconstruction

<b>Method of reconstruction:</b>	<b>No. (30)</b>	<b>%</b>
Double proline mesh with flap	13	43.3
Methyl methacrylate	4	13.3
Muscle flap (latissmuss and pectoralis)	3	10
Omental patch	3	10
Stainless steel wires	3	10
Plates and screws	4	13.3

Table 6: Post-op complications after chest wall resection

Complication	(N= 11)	%
Wound infection (positive culture)	3	10
Respiratory	3	10
Seroma (negative culture)	3	10
Wound hematoma	1	3.3
Donor site morbidity	1	3.3

The present study included 30 patients treated by chest wall resection and reconstruction, with the most common indication for chest wall resection was a primary chest wall neoplasm (50%), and followed by chest wall trauma (33.3%) and finally chest wall infections (16.7%) .in our study chest wall reconstruction has been done by using both prosthetic and autologous materials. Prosthetic materials included (double proline mesh (43.3%), methylemethacrylate (13.3%), plates and screws (13.3%) and stainless-steel wires (10%). Autologous materials included (muscle flap (10%) and omental patch (10%).

The studied group did not have the need for postoperative mechanical ventilation except for one patient(3.3%) with osteoradionecrosis who was extubated on table but developed postoperative chest infection and transmitted to the intensive care on the 2<sup>nd</sup> day postoperative ,ventilated and developed septic complications and died on the 5th day postoperative , we did not employ postoperative mechanical ventilation in our groups, this might be attributed to careful perioperative evaluation of the pulmonary status of every patient to anticipate postoperative complication, also there was no massive pulmonary contusion in trauma cases or any hemodynamic instability requiring perioperative intubation this allowed them to be extubated on table postoperatively.

following chest wall extensive resection, reconstruction plays a critical part in determining postoperative outcome [8-10]. Generally, reconstruction is not required for small defects that measures 5 cm irrespective of their location and posterior defects that measures 10 cm., while reconstruction is required for larger defects and most defects in the anterior region. A wide range of prosthetic materials used for a non-rigid reconstruction including Prolene mesh, Marlex mesh, and PTFE [10,11]. To prevent chest wall

collapse following chest wall resection various materials as bone cement sandwich, silicone, Teflon, or acrylic materials have been used to maintain stability and integrity of the chest wall [12]. During respiration, flail chest is seen after major resection [11] and is associated with pulmonary insufficiency. This paradoxical movement could be prevented by the usage of rigid prosthetic materials. Nagayasu and colleagues used a 2-mm Dual Mesh for reconstruction in 11 patients and concluded that the use of dual mesh for chest wall reconstruction had acceptable durability and biocompatibility, even after long-term follow-up [13].

Regarding this study, double proline mesh and methylmethacrylate composite were the most commonly used materials for chest wall reconstruction. This approach was used by others, [10, 14, 15], and Daigeler and associates [16] have mentioned moderate reduction in pulmonary function without considerable relation to the location or size of the resection. They revealed that chest wall reconstruction by these materials offers excellent stability to maintain pulmonary function.

Recently, the titanium rib bridge system that restore the rib continuity in combination with the dual-sided e-PTFE mesh, which used to cover the pleural defect has been used for chest wall reconstruction following oncologic chest wall resections, Berthet and colleague [17] used this technique in 19 patients with similar results including one early death (pulmonary embolism) and median in hospital stay 10.8 days. Regarding our results we also have one early death due to respiratory and septic infection, while the mean hospital stay was 9 days.

Omentoplasty is another reconstruction modality that can be used especially for sternal dehiscence following poststernotomy osteomyelitis. Milano and Colleagues, [18] Concluded that its proximity to the sternum makes omentoplasty the gold standard reconstruction flap. In our study, the omental flap was used in 3 patients to reconstruct a recurrent sternal osteomyelitis after failed previous attempts of reconstruction.

There is no doubt that flail chest with large flail segment can yields a high mortality rate even with

good analgesia and positive ventilation so and according to Granetzny and colleagues, [19] surgical fixation can help significantly in reducing the duration of ventilator support and in conserving the pulmonary function.

Ahmed and Mohyuddin [20] in a study included 64 cases of flail chest injury, internal fixation of ribs by using Kirshner wires as a method of fixation of non-comminuted fractured ribs was applied in 26 cases. Paris and colleagues [21] described the use of different types of stainless-steel struts for surgical stabilization of traumatic flail chest. They classified their patient into four groups in which group III involved four patients managed by surgical stabilization only, on admission, these patients were in good condition for surgical treatment. They concluded that surgical stabilization can avoid the use of the ventilator or at least reduce the interval of intermittent positive pressure ventilation in severely injured patient. We used to fix cases of flail chest either by stainless steel wires or plates and screws and we selected the patients who were a good candidate for surgical intervention in terms of absence of cerebral injury or massive pulmonary contusion

According to literature, complications after chest wall resection are common and range from 46% to 69% in two of the largest recent series of chest wall resection [15,22]. Respiratory complications, including pneumonia, acute respiratory distress syndrome (ARDS), and atelectasis are by far the most common [8]. In our study, complications occurred in 11 patients (36.7%) and respiratory complications were found in 3 patients (33.3 %).

Wound complications were reported to occur in 8 to 20 % of the patient group [23, 24]. The most common complications include infection, dehiscence, and hematoma regarding our study, wound complications occurred in 36.7 % of the patients. The most common complication was seroma after double proline mesh reconstruction of the bony chest wall. Deschamps et al. [22] reported that seroma occurred in 64 patients (32.5 %) following a polypropylene mesh reconstruction and occurred in 133 patients (67.5 %) following a polytetrafluoroethylene reconstruction.

In a report by Gonfiotti [25], chest wall integrity was achieved by a synthetic material,

rigid and non-rigid, and a muscular flap and a polytetrafluoroethylene patch as non-rigid material. He stated the absence of major pulmonary or septic complications; only two patients suffered a seroma and were managed conservatively with no consequences. Also, two patients developed local recurrence at 15 and 26 months where they subjected to surgery for excision of a desmoid tumor and a high-grade chondrosarcoma. the average hospital stay in his study was 8.6 days (rang 5-14 days) [25]. Regarding our study, mean hospital stay varied from (8-12) days, local recurrence occurred in one patient out of 15 cases (6.6 %,) the recurrence was on the same side and of the same malignancy (round cell malignancy).

Considering recent advances, several centers have described the use of new techniques such as the tailored metallic rib plating systems and biomaterials that become fully incorporated during the healing process [26,27]. Practically, these materials have the advantages of maintenance the physical characteristics essential for normal chest wall dynamics and decrease the undesirable effects that can occur with foreign bodies. Although the use of new technologies may be associated with improved outcome, our interest must also be tempered by the extreme costs that originate from their use. The ideal chest wall reconstruction method should be biomimetic, safe for patients and efficient in terms of cost.

#### Study limitations:

The outcome of the current study is exposed to several restrictions. First the total number of cases may not be sufficient for assessment by multivariate logistic regression analysis. In addition, the patients are not homogeneous because of the wide spectrum and the different behaviors of chest wall defects.

#### Conclusion

The choice of reconstruction modality was determined for each case individually; considering the patient's requirements, the chest wall defect characteristics, and the surgeon's expertise. The classic and well-tested double proline mesh or methylemethacrylate composite technique still remains a valuable technique of minimal cost.

**Acknowledgment:** we would also like to express our sincere gratitude & respects for the valuable guidance of Prof. Kamal A Mansour, Professor of



Thoracic Surgery, Emory University, USA for his active participation in this work and ask our god to bless his soul.

**Conflict of interest:** Authors declare no conflict of interest.

### References

1. Pairolero PC. [Extend resections for lung cancer. How far is too far?](#) Euro J Cardiothoracic Surg 1999; 16:S48–S50.
2. Arnold PG, Pairolero PC. Reconstruction of the radiation imaged chest wall. Surg Clin North Am.1999; 69:1081.
3. Gonfiotti A, Santinia PF, Campanacci D, et al. [Malignant primary chest-wall tumors: techniques of reconstruction and survival.](#) Euro J Cardiothoracic Surg 2010; 38:39–45.
4. McCormack PM. [Use of prosthetic materials in chest-wall reconstruction.](#) Surg Cline North Am 1989; 69:965–76.
5. Rivas B, Carrillo JF, Escobar G. [Reconstructive management of advanced breast cancer.](#) Ann Plast Surg.2001; 47:234.
6. Xiaopeng W, Shan G, Guangjian Z. [Chest wall reconstruction with a customized titanium-alloy prosthesis fabricated by 3D printing and rapid prototyping.](#) J cardiothoracic surgery.2018;13:4.
7. Momeni A, Kovach SJ. [Important consideration in chest wall reconstruction.](#) j surg oncol.2016 jun ;113(8):913
8. Incarbone M, Pastorino U. [Surgical treatment of chest wall tumors.](#) World journal of surgery, 2001; 25(2), 218-230.
9. Weyant M, Bains M, Venkatraman E et al. [Results of chest wall resection and reconstruction with and without rigid prosthesis.](#) Ann Thorac Surg, 2006; 81(1):279–285
10. Lardinois D, Muller M, Furrer M et al. [Functional assessment of chest wall integrity after methylmethacrylate reconstruction.](#) Ann Thorac Surg; 2000, 69(3):919–923
11. Athanassiadi K, Kalavrouziotis G, Rondogianni D, Loutsidis A, Hatzimichalis A, Bellenis I. [Primary chest wall tumors: early and long-term results of surgical treatment.](#) Eur J Cardiothorac Surg, 2001; 19(5):589–593
12. Miller D, Mansour K. Chest wall reconstruction, 7th edn.Lippincott Williams & Wilkins, Philadelphia, 2010; p 679
13. Nagayasu T, Yamasaki N, Tagawa T et al. [Long-term results of chest wall reconstruction with DualMesh.](#) Interact Cardiovasc Thorac Surg, 2010; 11 (5): 581–5841.
14. Kilic D, Gungor A, Kavukcu S et al. [Comparison of mersilene mesh-methyl metacrylate sandwich and polytetrafluoroethylene grafts for chest wall reconstruction.](#) J Invest Surg, 2006; 19 (6): 353–360
15. Mansour KA, Thourani VH, Losken A, et al. [Chest wall resections and reconstruction: a 25-year experience.](#) Ann Thoracic Surg. 2002; 73:1720.
16. Daigeler A, Druecke D, Hakimi M, et al. [Reconstruction of the thoracic wall-long-term follow-up including pulmonary function tests.](#) Langenbecks Arch Surg, 2009; 394(4):705–715
17. Berthet JP, Canaud L, D’Annoville T, Alric P, Marty-Ane CH. [Titanium plates and Dualmesh: a modern combination for reconstructing very large chest wall defects.](#) The Annals of thoracic surgery. 2011; 91(6):1709–1716.
18. Milano CA, Georgiade G, Muhlbaier LH, Smith PK, Wolfe WG. [Comparison of omental and pectoralis flaps for post sternotomy mediastinitis.](#) Ann thoracic Surg 1999; 67:377–80.
19. Granetzny A, Abd El-Aal M, Emam E, Shalaby A, Boseila A. [Surgical versus conservative treatment of flail chest. Evaluation of the pulmonary status.](#) Interact cardiovascular thoracic Surg. 2005; 4:583-7.
20. Ahmed Z, Mohyuddin Z. [Management of flail chest injury: internal fixation versus endotracheal intubation and ventilation.](#) J thoracic Cardiovascular Surg. 1995; 110:1676-80.
21. Paris F, Tarazona V, Blasco E et al. [Surgical stabilization of traumatic flail chest.](#) Thorax. 1975; 30:521-7.
22. Deschamps C, Tirnaksiz BM, Darbandi R et al. [Early and long-term results of prosthetic chest wall reconstruction.](#) Thorac Cardiovasc Surg 1999; 117: 588 –91.
23. Hsu P, Hsu H, Lee H et al. [Management of primary chest wall tumors: 14 years' clinical experience.](#) J Chin Med Assoc, 2006; 69(8):377–382
24. Burt M. [Primary malignant tumors of the chest wall.](#) The Memorial Sloan-Kettering Cancer

- Center experience. *Chest Surg Clin N Am*, 1994; 4(1):137–154
25. Gonfiotti A, Santini P, Campanacci D et al. [Malignant primary chest-wall tumours: techniques of reconstruction and survival](#). *Eur J Cardiothorac Surg*, 2010; 38(1):39–45
26. Aranda JL, Jimenez MF, Rodriguez M, Varela G. [Tridimensional titanium-printed custom-made prosthesis for sternal costal reconstruction](#). *Euro J Cardiothoracic Surg* 2015; 48:92–4.
27. Boerma LM, Bemelman M, van Dalen T. [Chest wall reconstruction after resection of a chest wall sarcoma by osteosynthesis with the titanium Matrix RIB \(Synthesis\) system](#). *J thoracic Cardiovascular Surg* 2013; 146:37–40.