



## Original Article

### Video assisted minimally invasive mitral valve replacement in rheumatic valve disease: an initial experience

Heba Abdel-Kareem<sup>1</sup>, Mohammed Alaa<sup>1</sup>, Mahmoud Khairy<sup>1</sup>, Ali Abdel-Wahab<sup>1</sup>, Morsi Mohammed<sup>2</sup>

<sup>1</sup> Cardiothoracic Surgery department, Assiut University, Assiut, Egypt; <sup>2</sup> General Surgery department, Assiut University, Assiut, Egypt

#### Abstract

**Background:** Minimal invasive cardiac surgery is cosmetically attractive to the patient; however, debate still exists regarding its safety and the effective exposure during the technique. We present our local experience in video assisted minimally invasive mitral valve replacement, for the surgically challenging rheumatic valve disease, still endemic among Egyptian population.

**Methods:** This prospective single center study was conducted on 20 rheumatic heart patients, presenting with severe mitral regurgitation (8 patients; 40%), severe mitral stenosis (8 patients; 40%) or combined lesion (4 patients; 20%). The patients underwent video assisted minimally invasive mitral valve replacement, through a right mini-thoracotomy via: an infra-mammary incision (13 patients; 65%), periareolar incision (4; 20%) or limited right anterolateral mini-thoracotomy (3 patients; 15%). Early postoperative quality of life was evaluated using SF 36 questionnaire.

**Results:** Mean length of skin incision was ( $6.60 \pm 1.35$  cm). Mean durations of operation, cardiopulmonary bypass, and cross-clamp times were:  $4.32 \pm 1.08$ ,  $2.85 \pm 0.75$  and  $1.78 \pm 0.47$  hrs; respectively. The mean amount of blood loss was  $398.50 \pm 245.79$  ml, with two patients (10%) requiring re-exploration. At discharge, all patients had normal prosthetic mitral valve function with no regurgitation by echocardiography. Four patients (20%) had atrial fibrillation postoperatively. Total durations of ICU stay and hospital stays were:  $2.35 \pm 1.14$  and  $6.45 \pm 1.43$  days, and 90% of patients return to daily work and full activity within 4 weeks.

**Conclusions:** Video assisted minimally invasive mitral valve surgery in rheumatic valve disease has low surgical trauma, blood loss, and pain, which translates into a short hospital stay and rapid return to normal activities.

#### KEYWORDS

Video assisted;  
Minimally invasive;  
Rheumatic

#### Article History

Submitted: 2 Dec 2018  
Revised 1: 8 Dec 2018  
Revised 2: 17 Dec 2018  
Accepted: 25 Dec 2018  
Published: 5 Jan 2019



## Introduction

Over the last decade; different institutions have tried minimally invasive mitral valve surgery (MIMVS) and have published hopeful results as single-center studies [1]. Rheumatic fever increases valve thickness and contracture, making surgery more difficult in rheumatic than in degenerative valve disease [2]. Furthermore, due to the low prevalence of rheumatic fever in the western world, few reports have studied minimally invasive cardiac surgery in rheumatic patients [3]. This study presents our initial experience in MIMVS with video assistance for rheumatic mitral valve disease and evaluation of its early results and postoperative quality of life.

## Patients and Methods:

This prospective single center descriptive study was conducted at Assiut University hospitals in the period between October 2015 and June 2018. After ethical committee approval and informed written consent, 20 rheumatic patients presenting with either: mitral regurgitation (MR) (8 patients; 40%), mitral stenosis (MS) (8 patients; 40%) or combined mitral valve lesion (4 patients; 20%) were selected for this study. Patients were all candidates for first time isolated mitral valve replacement, of both sexes, with no limits of age. Preoperative data collected included; age, BMI, diabetes mellitus, and NYHA class. ECG was analyzed and echocardiography data were reported including left atrial (LA) dimension, left ventricular (LV) dimension, LV ejection fraction, mitral valve (MV) pathology, associated valve pathology and pulmonary hypertension. Patients older than 40 years benefited from a preoperative diagnostic coronary angiography to exclude associated coronary artery disease. Exclusion criteria were need of additional coronary artery bypass grafting or low ejection fraction <40%. Patients were also excluded for an expected technical burden in case of a previous right thoracotomy, femoral surgery or heavily calcific mitral valve annulus or deep annular abscess.

After intravenous anesthesia including sufentanil and propofol, an arterial pressure line was placed in the right radial artery. Patients were then positioned in a supine position with the right

side of the chest slightly elevated and right arm slightly abducted to clean out the axillary region for possible ports of the transthoracic aortic cross-clamp (Chitwood clamp) (Scanlan International, St Paul, MN, USA) and telescope. The right shoulder was slightly elevated 30 degrees. Defibrillation pads were placed externally. Single lumen endotracheal tube was used in all cases. Tidal volume was reduced temporary by deflating the lung if necessary, until the lungs were disconnected after full cardiopulmonary bypass (CBP).

Right 6-8 cm infra-mammary incision was carried out in 13 patients, right 5 cm periareolar incision of length in 4 patients and 5-8 cm right limited anterolateral thoracotomy incision of length in 3 patients. The chest was entered via the 3rd or 4th intercostal space and a small pad is used to displace and retract the right lung. Synchronous exposure of femoral vessels through a 3cm supra inguinal oblique incision. The right femoral artery and vein were surgically exposed. After systemic heparinization, a femoral arterial cannula (12F to 14F) was inserted to the femoral artery. Repair of this femoral arteriotomy was done, by 6/0 polypropylene suturing at the end of the operation. A standard multistage femoral venous cannula (22- 24F) was placed in the femoral vein and advanced to the right atrium. 5/0 polypropylene purse suture was used to secure the cannula and closure of the vein at the end of surgery in almost all cases.

The pericardial sac was opened 3 cm above the right phrenic nerve and parallel to it. The pericardium was fixed to the skin with three stay retraction sutures, with pulling the heart slightly to the right side and into the field to expose the roof of the left atrium. Aortic occlusion was achieved by either a transthoracic cross-clamp (Chitwood clamp; Scanlan International, St Paul, MN, USA) or via the same operative incision using a flexible or inflexible aortic clamp. A conventional cardiopulmonary bypass system was used under moderate hypothermia (28 to 30° C) then, the lungs were deflated. The Cardioplegic solution was delivered into ascending aorta.

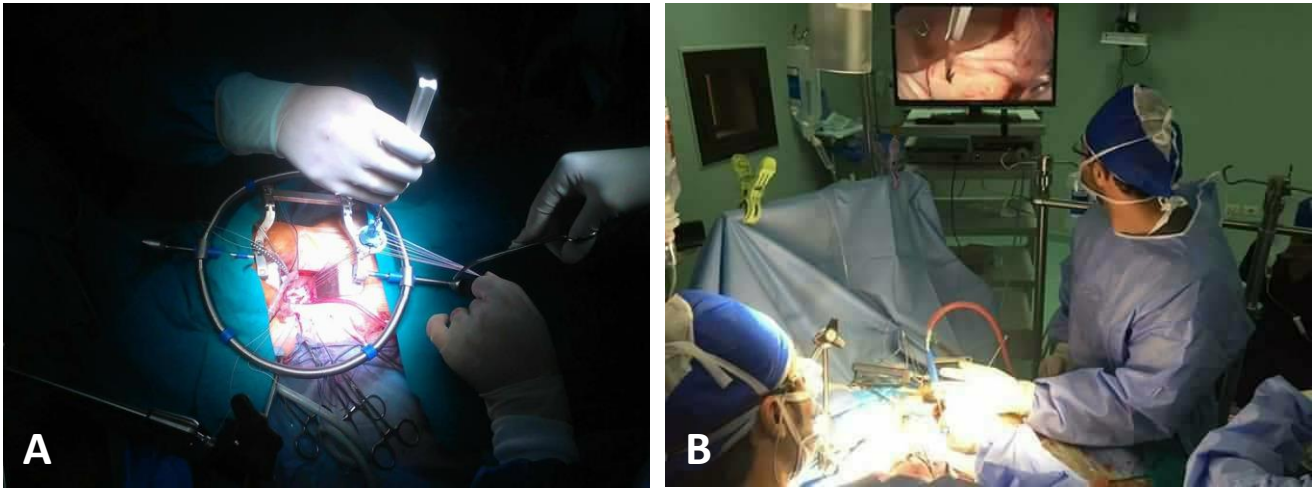


Figure 1: Mitral valve replacement performed: A) combination of direct vision & thoracoscopic assistance, with the use of (Obadia) set of minimally invasive instruments; B) Video-assisted minimally invasive mitral valve replacement through right mini-thoracotomy

After complete cardiac arrest, the left atrium was opened and the mitral valve was exposed. Mitral valve replacement was performed with partial or total chordal preservation and under a combination of direct vision and thoracoscopic assistance through three-dimensional videoscopic guidance, with the use of special set of minimally invasive instruments, (OBADIA set) (created by Obadia J F, Hôpital Louis Pradel - Lyon - France) (Figure 1A). We performed some surgical steps with video assistance, such as placement of sutures on the anterior annulus of the mitral valve, or the area of the posteromedial commissure.

After completion of the procedure, the left atrium was closed by a continuous suturing. Dearing was achieved by filling the left atrium with saline before its closure or by suction via the cardioplegic cannula into the ascending aorta. It was associated with the inflation of the lungs. After appropriate reperfusion, the arterial and venous cannulas were removed and the femoral vessels reconstructed. The chest wound was closed after putting a drainage tube.

All patients were assessed regarding bleeding, postoperative pain, respiratory complications, wound healing, pericardial effusion, total hospital, and ICU stay in days. Complications related to femoral cannulation like ischemia, emboli or bleeding were recorded.

All patients were assessed postoperatively and before discharge using echocardiography regarding prosthetic mitral valve function and pressure gradient, paravalvular leak, LV function, and pericardial effusion. SF-36 questionnaire for the quality of life was applied to each patient from one month to three months postoperatively. The SF-36 Health Survey is a multi-purpose, short-form health survey which contains 36 questions. It yields an eight-scale profile of scores as well as summary physical and mental measures [4].

#### Statistical analysis:

Data were expressed as numbers (%) for categorical variables or mean + SD and range for continuous variables.

#### Results:

The study population included 20 patients who underwent video-assisted minimally invasive mitral valve surgery at Cardiothoracic Surgery Department - Assiut University Hospital. Patients' demographic data are presented in Table 1.

#### Operative data

All mitral valve operations were Video-assisted through right mini-thoracotomy (Figure 1B). 13 patients (65%) were via infra-mammary incisions (Figure 2A), 4 patients (20%) were via periareolar incision (Figure 2B) and three patients (15%) were via limited anterolateral mini-thoracotomy, the length of incision was between 5 to 10 cm with (Mean  $\pm$  SD= 6.60  $\pm$  1.35 cm) with the last 17

patients having incisions of 6 cm or less. No reported patients needed conversion to an enlarged thoracotomy incision, a mini-sternotomy or complete sternotomy.

Table 1: Demographic data of the studied population

	No. (n= 20)	%
<b>Age (years)</b>		
Mean ± SD	35.50 ± 13.83	
Range	16.0 - 66.0	
<b>Sex</b>		
Male	5	25.0
Female	15	75.0
<b>Body surface area (Kg/m<sup>2</sup>)</b>		
Mean ± SD	1.64 ± 0.26	
Range	1.2 - 2.2	
<b>Diabetes mellitus</b>		
Diabetic	3	15.0
Non-diabetic	17	85.0
<b>NYHA class</b>		
Class III	15	75.0
Class IV	5	25.0
<b>ECG</b>		
AF	6	30.0
Sinus	14	70.0
<b>Echo</b>		
Severe MR	8	40.0
Severe MS	8	40.0
Severe MR &	4	20.0
<b>EF%</b>		
Mean ± SD	61.15 ± 6.58	
Range	43.0 - 70.0	

Mean duration of operation, cardiopulmonary bypass, and cross-clamp times were ( $4.32 \pm 1.08$ ,  $2.85 \pm 0.75$  and  $1.78 \pm 0.47$  hr.) respectively, with range (2.5 - 6.0, 2.0 - 5.0 and 1.0 - 2.5 hr.) respectively.

Nineteen patients (95%) underwent femoro-femoral cannulation and one patient (5%) underwent aorto-bicaval cannulation. Fifteen patients (75%) underwent mitral valve replacement (MVR) by St-Jude medical mechanical valve size 27 and 5 patients (5%) by size 25 (St. Jude Medical, Inc., Minnesota, USA);

according to intraoperative sizing of the mitral annulus (Table 2).

### Post-operative data

Primary ventilation time was between 1.0 - 4.0 hours, (mean  $\pm$  SD =  $2.00 \pm 0.79$  hrs.). ICU stay ranged between 1.0 - 3.0 day with (mean  $\pm$  SD =  $2.35 \pm 1.14$ ), and hospital stay ranged between 5.0 - 7.0 days with (mean  $\pm$  SD =  $6.45 \pm 1.43$ ).

The amount of blood loss ranged between 170.0 - 1000.0 ml (mean  $\pm$ SD =  $398.50 \pm 245.79$ ) with two patients requiring re-exploration for bleeding through the same primary operative incision. About 13 patients (65%) didn't need blood transfusion, 4 patients (20%) needed 1- 2 units and 3 patients (15%) needed more than 2 units.

All patients had no incidence of neurological events. 16 patients (80%) were in sinus rhythm and 4 patients (20%) had AF postoperatively without the need for external defibrillations. At discharge, all patients had normal prosthetic mitral valve function with no regurgitation, no paravalvular leakage.

Mean pressure gradient (PG) ranged between 4 -5 mmHg (mean  $\pm$  SD =  $4.40 \pm 0.50$ ), as shown on postoperative echocardiography. No patient had pleural effusion or wound infection.

In 18 patients, wound healing at the groin was uncomplicated. Two patients had a lymphatic collection in the groin, which was treated conservatively (Table 3).

### SF-36 Questionnaire for Quality of Life:

In our study, quality of life was measured for all patients from 1 to 3 months postoperatively by SF-36 Questionnaire. The SF-36 Questionnaire Health Survey contains 36 questions and gives eight-scale profile as well as summary physical and mental measures (Table 4; Figure 3).

### Discussion

The Society of thoracic surgeons (STS) defined minimally invasive (MI) surgery as any technique not including full sternotomy [5]. In recent years, MI surgery is preferable to the patients because of the minimal trauma, small incision and quick



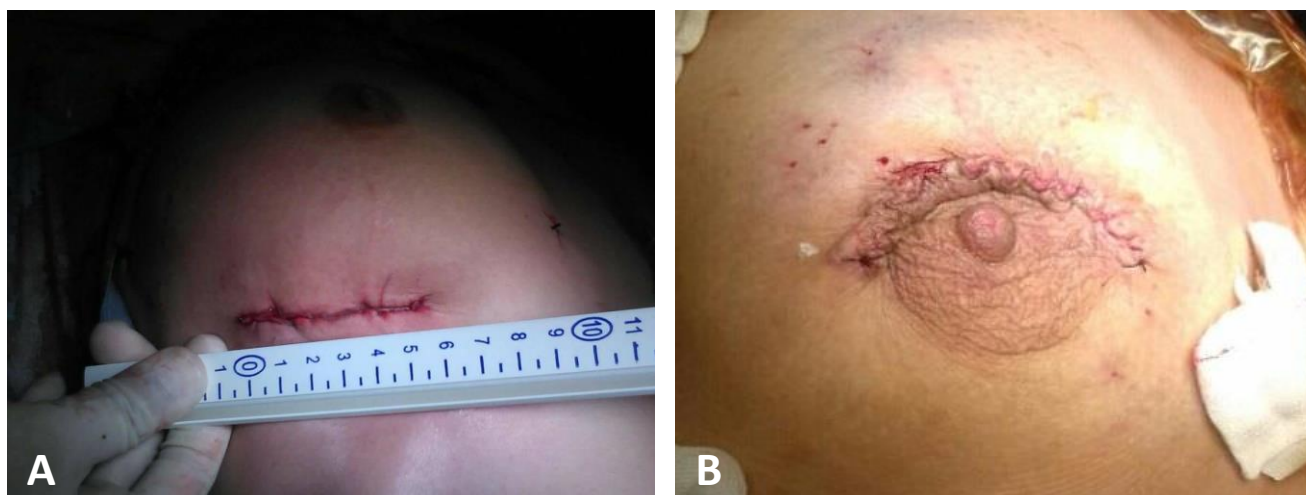

Figure 2: Right mini-thoracotomy via: A) infra-mammary 6-cm incision, B) Periareolar incision

Table 2: Operative data

	No. (n= 20)	%
<b>Type of incision</b>		
Right mini-thoracotomy via an infra-mammary	13	65.0
Right mini-thoracotomy via a periareolar incision	4	20.0
Right anterolateral mini-thoracotomy	3	15.0
<b>length of Incision (cm)</b>		
Mean $\pm$ SD	6.60 $\pm$ 1.35	
Range	5.0 - 10.0	
<b>Operative time (hours)</b>		
Mean $\pm$ SD	4.32 $\pm$ 1.08	
Range	2.5 - 6.0	
<b>Bypass time (hours)</b>		
Mean $\pm$ SD	2.85 $\pm$ 0.75	
Range	2.0 - 5.0	
<b>Cross-clamp time (hours)</b>		
Mean $\pm$ SD	1.78 $\pm$ 0.47	
Range	1.0 - 2.5	
<b>Cannulation</b>		
Femoro-femoral	19	95.0
Aorto-femoral bicaval	1	5.0
<b>Procedure</b>		
MVR by St-Jude medical	15	75.0
MVR by St-Jude medical	5	25.0

recovery [6]. We have adopted minimally invasive cardiac surgery at our hospital since 2011 and used it to treat ASD cases without video assistance. Then, after getting a good initial experience with the technique, we applied the technique on more demanding pathology.

In spite of the improvement in healthcare and living standards in recent years, rheumatic fever is still endemic among Egyptian population. Rheumatic valvular lesions are thick and cause calcification and adhesion of valve leaflets, so their surgical manipulation is difficult, in comparison with other pathologies [7]. All our patients had rheumatic mitral valve disease, while previous studies focused mainly on patients having a degenerative disease or mixed pathology. Seventy percent of the patients of Mattia and associates who benefited from MIMVS through the right anterolateral thoracotomy presented with degenerative mitral valve pathology, compared to only 9.4% being of rheumatic origin. [8]. Few recent minimally invasive studies were reported on rheumatic valves; Junyu Zhai, and associates [7], a Chinese study that used thoracoscope for removal the damaged native mitral valve only; Vivek Kanhere and colleagues [9], an Indian study without video assistance and Noedir Antonio and associates [10], a Brazilian study used thoracoscope mainly for commissurotomy of stenotic mitral valve. The procedure was technically feasible in all our cases, with mean operative, ischemic and bypass times that were comparable to those reported by other studies [11].

Table 3: Post-operative data

	No. (n= 20)	%
<b>Amount of blood transfusion (unit)</b>		
None	13	65.0
1 - 2	4	20.0
> 2	3	15.0
<b>Ventilation time (hours)</b>		
Mean ± SD	2.00 ± 0.79	
Range	1.0 - 4.0	
<b>ICU stay (days)</b>		
Mean ± SD	2.35 ± 1.14	
Range	1.0 - 3.0	
<b>Hospital stay (days)</b>		
Mean ± SD	6.45 ± 1.43	
Range	5.0 - 7.0	
<b>Amount of bleeding (cc)</b>		
Mean ± SD	398.50 ± 245.79	
Range	170.0 - 1000.0	
<b>ECG</b>		
AF	4	20.0
No	16	80.0
<b>Prosthetic valve PG mean (mmHg)</b>		
Mean ± SD	4.40 ± 0.50	
Range	4.0 - 5.0	

In the study of Mohr FW and colleagues, patients underwent video-assisted minimally invasive mitral valve replacement through a right lateral mini-thoracotomy, the mean length of incision was (5.4 ± 1.8 cm) (range 3.8 to 8 cm) [11]. Although the mean length of our incisions was larger, yet all incisions were 6 cm or smaller in the last 17 patients (85%), providing a favorable cosmetic for the patients. None of our patients needed conversion to an enlarged thoracotomy incision, a mini-sternotomy or complete sternotomy.

Minimally invasive approaches appear to be associated with faster recovery, earlier discharge, and reduced use of rehabilitation facilities [12]. Mihaljevic and colleagues [13] reported a shorter hospital stay with a minimally-invasive approach. Also, Mohr FW and colleagues [11] revealed that mean duration of intensive care and hospital stays were 2 days (range 1 to 36 days) and 13 days (10 to 36 days) respectively. Our patients benefited from a comparable ICU stay and even shorter total hospital stay that varied between 5 and 7 days.

Small incisions significantly reduce morbidity and mortality associated with transfusions and bleeding re-exploration [14].

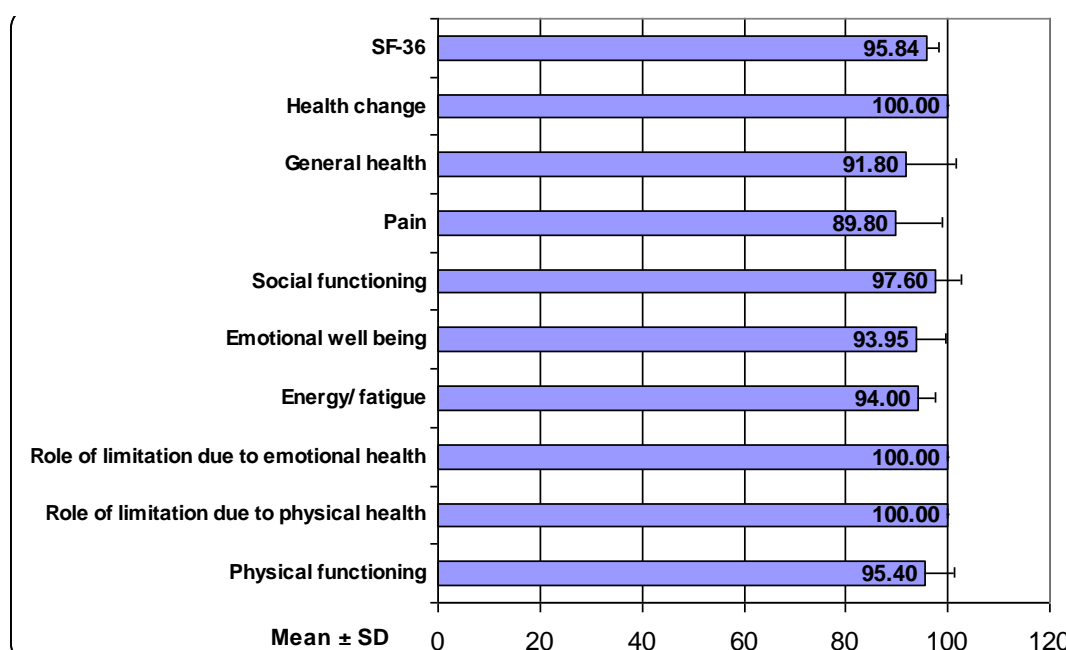


Figure 3: The score of SF-36 Questionnaire for Quality of Life

Some studies showed no difference in blood transfusion requirements [15], whereas Dogan and associates [16] reported a significant reduction in postoperative bleeding in the minimally invasive group in comparison with the traditional group. Two-thirds of our patients did not need any blood transfusion and only 2 cases required re-exploration for non-surgical bleeding, without requiring to enlarge the incision.

Due to the physical limitations of minimally invasive surgery, inadequate de-airing leading theoretically to a higher incidence of neurological complications [6]. We did not encounter any neurological complications among our small group of patients. In the early series, Seeburger and associates [17] observed postoperative neurological complications in 41 of 1,339 patients (3.1%) who underwent MIMVS, with 28 minor and 13 major events. Also, in Mattia Glauber and colleagues [8] a total of 1604 consecutive patients underwent MIMVS through a right anterolateral thoracotomy, he found excellent outcomes. On the other hand, prolonged cross-clamp and cardiopulmonary bypass times were associated with a higher incidence of neurological events, aortic dissection; Gaudiani VA and associates [18] reported no difference in the incidence of stroke.

Theoretically, it has been suggested that a less traumatic surgical approach would trigger less

post-operative AF. However, a meta-analysis of 4 eligible studies revealed no significant difference between minimally invasive and sternotomy approaches about AF [6]. In their study on 1000 patients who underwent minimally invasive mitral valve surgery, Scott McClure and associates detected postoperative AF in as much as 20% of patients [19]. In our study, the percentage of AF decreased after surgery. Out of 6 patients presented with AF before surgery, AF persisted in only four cases postoperatively, with the remaining 16 patients (80%) being in sinus rhythm. On the other hand, there is a general agreement that minimal invasive surgery permits excellent visualization for leaflet resection and to perform uncomplicated mitral valve replacement [11].

Postoperative echocardiographic studies showed normal prosthetic valve function in all cases, with minimal or no regurgitation.

The right thoracotomy approach may be associated with more respiratory complications [8,11]. Mattia and colleagues pulmonary complications in as much as 41 patients (2.5%) [8]. Mohr and colleagues reported 2 mortalities from severe pneumonia at the 6th postoperative day in one case and from pulmonary embolism on the 24th postoperative day, despite adequate anticoagulation [11]. None of our 20 cases has encountered any respiratory complication.

Table 4: SF-36 Questionnaire for Quality of Life

	Mean ± SD	Range
<b>Physical functioning</b>	95.40 ± 6.03	83.0 - 100.0
<b>Role of limitation due to physical health</b>	100.00 ± 0.00	100.0 - 100.0
<b>Role of limitation due to emotional health</b>	100.00 ± 0.00	100.0 - 100.0
<b>Energy/ fatigue</b>	94.00 ± 3.48	90.0 - 100.0
<b>Emotional well being</b>	93.95 ± 5.72	80.0 - 100.0
<b>Social functioning</b>	97.60 ± 4.92	88.0 - 100.0
<b>Pain</b>	89.80 ± 9.08	78.0 - 100.0
<b>General health</b>	91.80 ± 9.98	56.0 - 100.0
<b>Health change</b>	100.00 ± 0.00	100.0 - 100.0
<b>SF-36</b>	95.84 ± 2.31	91.2 - 99.6

The incidence of septic complications and wound infections is lower with a thoracotomy than with a median sternotomy [20]. Grossi and colleagues [20] reported an incidence of 0.9% for mini-thoracotomy and 5.7% for sternotomy cases. This had increased to 1.8% and 7.7% respectively in elderly patients, whereas Felger and associates [21] reported no significant differences between groups. It is important to note that there is an additional risk of groin complications associated with minimally invasive surgery. Mohr and colleagues [11] reported three patients with groin healing complication, two patients had a small residual hematoma and one patient had a lymph fistula in the right groin; all of which were treated conservatively. In our study, only one patient developed groin lymphatic collection but all our thoracotomies were clean.

Jeronimo A F Junior and associates [22] observed better cosmetic results, reduced postoperative pain and rapid recovery after the thoracotomy approach. Casselman and associates [23] reported that approximately 99% of patients thought that their right thoracotomy scar was esthetically pleasing. In our study, improved cosmeses are one of the benefits of minimally invasive surgery and 95% of our patients were appreciated the cosmetic appearance of their scar.

Postoperative pain and quality of life were evaluated by Leipzig group of Walther and associates from 1996 to 1997 using different scoring systems [24]. Another study assessed Quality of life by using modification of the Nottingham Health Questionnaire (NHQ) [25]; with analysis of different aspects of QOL (Quality of life), mainly social status, mobilization, emotional state, level of activities, pain, and sleeping disorders. That group found less pain starting from the third postoperative day after a lateral mini-thoracotomy. It is suggested that better stability of the bony thorax leads to earlier mobilization and return to daily activities [24]. Casselman and associates [23] reported that no or mild postoperative pain in 94% of their patients and 46% returned to work within 3 weeks. Yamada and colleagues compared the early postoperative

quality of life in minimally invasive valve surgery and conventional surgery. They found earlier recovery of daily activities after minimally invasive surgery. It provides an improved quality of life and reduced use of pain medication [15]. In our study, 90% of patients return to daily work and full activity within 4 weeks.

#### Limitations of the study:

Although the study reported the feasibility of the technique in rheumatic patients, yet the number of cases and absence of a comparative group are limitations of this study.

#### Conclusion:

Our preliminary study revealed that video assisted minimally invasive mitral valve replacement is safe and applicable in rheumatic patients. The results in this series are comparable to the world literature. It is effective in reducing hospital stay, blood transfusion, and postoperative pain. It provides a good cosmetic appearance and fast recovery of usual activities.

**Conflict of interest:** None declared

#### References

1. Cao C, Gupta S, Chandrakumar D, et al. [A meta-analysis of minimally invasive versus conventional mitral valve repair for patients with degenerative mitral disease](#). *Ann Cardiothorac Surg* 2013; 2: 693–703.
2. Levy MJ, Vidne B. [Rheumatic valve disease in childhood and adolescence: surgical treatment](#). *Chest* 1973; 63: 933–6.
3. Miceli A, Murzi M, Canarutto D, et al. [Minimally invasive mitral valve repair through right minithoracotomy in the setting of degenerative mitral regurgitation: early outcomes and long-term follow-up](#). *Ann Cardiothorac Surg* 2015; 4: 422–7.
4. John E, Ware Jr, and Barbara G. [Overview of the SF-36 Health Survey and the International Quality of Life Assessment \[IQOLA\] Project](#). *J Clin Epidemiol*. 1998; 51 (11): 903–912.
5. STS Database. Spring 2007 Executive Summary. Durham, NC: Duke Clinical Research Institute, 2007.
6. Schmitto JD, Mokashi SA, Cohn LH. [Minimally-Invasive Valve Surgery](#). *Journal of the American College of Cardiology*. 2010; 56 (6): 455 – 462.



7. Zhai J, Wei L, Huang B, Wang C, Zhang H, Yin K. [Minimally invasive mitral valve replacement is a safe and effective surgery for patients with rheumatic valve disease: A retrospective study.](#) *Medicine*. 2017; 96 (24):e7193.
8. Glauber M, Miceli A, Canarutto D, et al. [Early and long-term outcomes of minimally invasive mitral valve surgery through right mini thoracotomy: a 10-year experience in 1604 patients.](#) *Journal of Cardiothoracic Surgery*. 2015; 10:181.
9. Kanhere V, Pendse N, Narkhede V. [Results of minimally invasive approach for rheumatic mitral valve disease.](#) *J Cardiothorac Surg*. 2015; 10 (suppl 1): A 240.
10. Stolf NA, Brandao CM, Pomerantzeff PM, Filho OL, Grinberg M. Initial experience with minimally invasive video-assisted rheumatic mitral valve disease surgery. Poster presentation at the Annual Meeting of The International Society for Minimally Invasive Cardiothoracic Surgery, 2010.
11. Mohr FW, Falk V, Diegeler A, Walther T, Van Son JAM, Autschbach R, Borst HG. [Minimally invasive port-access mitral valve surgery.](#) *J Thorac Cardiovasc Surg*. 1998; 115 (3):567-576.
12. Ryan WH, Dewey TM, Mack MJ, Herbert MA, Prince SL. [Mitral valve surgery using the classical heart port 'technique.](#) *J Heart Valve Dis* 2005; 14 (6):709–714.
13. Mihaljevic T, Cohn LH, Unic D, Aranki SF, Couper GS, Byrne JG. [One thousand minimally invasive valve operations: early and late results.](#) *Ann Surg* 2004; 240 (3):529–234.
14. Murphy GJ, Reeves BC, Rogers CA, Rizvi SI, Culliford L, Angelini GD. [Increased mortality, postoperative morbidity and cost after red blood cell transfusion in patients having cardiac surgery.](#) *Circulation*. 2007; 116 (22):2544–2552.
15. Yamada T, Ochiai R, Takeda J, Shin H, Yozu R. [Comparison of early postoperative quality-of-life in minimally invasive versus conventional valve surgery.](#) *J Anesth* 2003; 17 (3):171–176.
16. Dogan S, Aybek T, Risteski PS, Detho F, Rapp A, Wimmer-Greinecker G, Moritz A. [Minimally invasive port-access versus conventional mitral valve surgery: prospective randomized study.](#) *Ann Thorac Surg*. 2005; 79 (2):492– 498.
17. Seeburger J, Borger MA, Falk V, et al. [Minimal invasive mitral valve repair for mitral regurgitation: results of 1339 consecutive patients.](#) *Eur J Cardiothoracic Surg*. 2008; 34 (4):760–765.
18. Gaudiani VA, Grunkemeier GL, Castro LJ, Fisher AL, Wu Y. [Mitral valve operations through standard and smaller incisions.](#) *Heart Surg Forum*. 2004; 7 (4): E 337– 342.
19. McClure RS, Athanasopoulos LV, McGurk S, Davidson MJ, Couper GS, Cohn LH. [One thousand minimally invasive mitral valve operations: Early outcomes, late outcomes, and echocardiographic follow-up.](#) *The Journal of Thoracic and Cardiovascular Surgery*. 2013; 145 (5): 1199 – 1206.
20. Grossi EA, Galloway AC, Ribakove GH, et al. [Impact of minimally invasive valvular heart surgery: a case-control study.](#) *Ann Thorac Surg*. 2001; 71 (3):807–810.
21. Felger JE, Nifong LW, Chitwood Jr WR. [The evolution of and early experience with robot-assisted mitral valve surgery.](#) *Surg Laparosc Endosc Percutan Tech*. 2002; 12 (1):58–63.
22. Fortunato Júnior JA, Pereira ML, Martins AL, et al. [Video-assisted cardiac surgery: 6 years of follow up.](#) *Brazilian Journal of Cardiovascular Surgery* 2012; 27 (1): 24 – 37.
23. Casselman FP, Van Slycke S, Wellens F, et al. [Mitral valve surgery can now routinely be performed endoscopically.](#) *Circulation*. 2003; 108 (Suppl 2): 48–54.
24. Walther T, Falk V, Metz S, Diegeler A, Battellini R, Autschbach R, Mohr FW. [Pain and quality-of-life after minimally invasive versus conventional cardiac surgery.](#) *Ann Thorac Surg* 1999; 67 (6):1643–1647.
25. Hunt SM, McKenna SP, McEwen J, Backett EM, Williams J, Papp E. [A quantitative approach to perceived health status: a validation study.](#) *J Epidemiol Comm Health* 1980; 34 (4):281– 286.