

Occipital Condyle Fracture – A Diagnosis Requiring High Suspicion

PRAKASH KAFLE,¹ GOPAL SEDAIN,² SUSHIL KRISHNA SHILPAKAR,³ MOHAN RAJ SHARMA,⁴ AMIT B. PRADHANANG,⁵ BINOD RAJBHANDARI,⁶ DIPENDRA SHRESTHA⁷

¹Department of Neurosurgery, Nobel Medical College, Biratnagar, Nepal

²⁻⁷Institute of Medicine, Tribhuvan University Teaching Hospital, Kathmandu Nepal

ABSTRACT

Traumatic injury causing occipital condyle fractures (OCF) are very rare. They are of critical clinical importance owing to important anatomical structures that need considerations of the occiput-atlantoaxial joint complex. Early diagnosis is of paramount importance since there may be associated lower cranial nerve palsies along with cervical spinal instability. Sometimes, this can be a diagnostic challenge in acute stage because of the inability to diagnose this injury with plain radiographs. To avoid this, high index of suspicion and relevant investigation of the craniocervical junction is indicated. Hence it helps in early recognition and diagnosis of OCF thus preventing possible neurological impairment. Here, we report a case of a 58-year-old male who presented with complaints of neck pain and headache following physical assault.

Keywords: Cranial nerve palsy, Occipital condyle fracture, Spinal instability.

INTRODUCTION

Bell in 1817, described the occipital condylar fractures for the first time during post-mortem examination of a trauma victim.¹The incidence of this fracture vary widely in the literature. According to Hanson² the incidence of OCF has been reported to be 1 to 2/1000 in patients with an injury severity score more than 8. In a Study of Bloom³, the reported incidence is 19% but the other study by Noble and Smoker⁴ reported an incidence of 1% after examination of CT scans of trauma patients. Here, we report the case of Anderson-Montesano type II occipital condylar fracture who was managed conservatively in our institute.

Case Detail

A 58-year right handed gentleman presented to our emergency department (ED) complaining severe neck pain and global headache following physical assault in an election rally. He had presented one day after the event. Pain was progressive in nature which was more during neck movements. He had vomiting and loss of consciousness for about 1 hour. Past medical and

surgical history were insignificant. On examination vitals were stable. There was significant neck tenderness while examining his neck along with a boggy swelling over the right occipital region and lacerated scalp. There was a profound sensorineural hearing loss and XIIth Cranial nerve palsy noted on the right side. Other lower cranial nerves were intact. Motor and sensory examination revealed no focal deficits in limbs. Radiological imaging with CT scan having 3mm cuts for cranial fossa and 5 mm cuts for supratentorial compartments of the brain revealed a linear fracture in right occipital bone in right paramedian location. Fracture was seen in right occipital condyle with cranial migration of the fracture fragment (Fig. 1A & B). There was a hypodense area with few hypodensity in the right cerebellum suggestive of contusion with effacement of fourth ventricle. Cervical spine CT was normal. Neck pain subsided and was able to walk without support after 5 days. He walked home on 14th day of admission with hard cervical collar.

On follow up at 1 month in OPD, he had no added neurological deficits. Tongue deviation was still

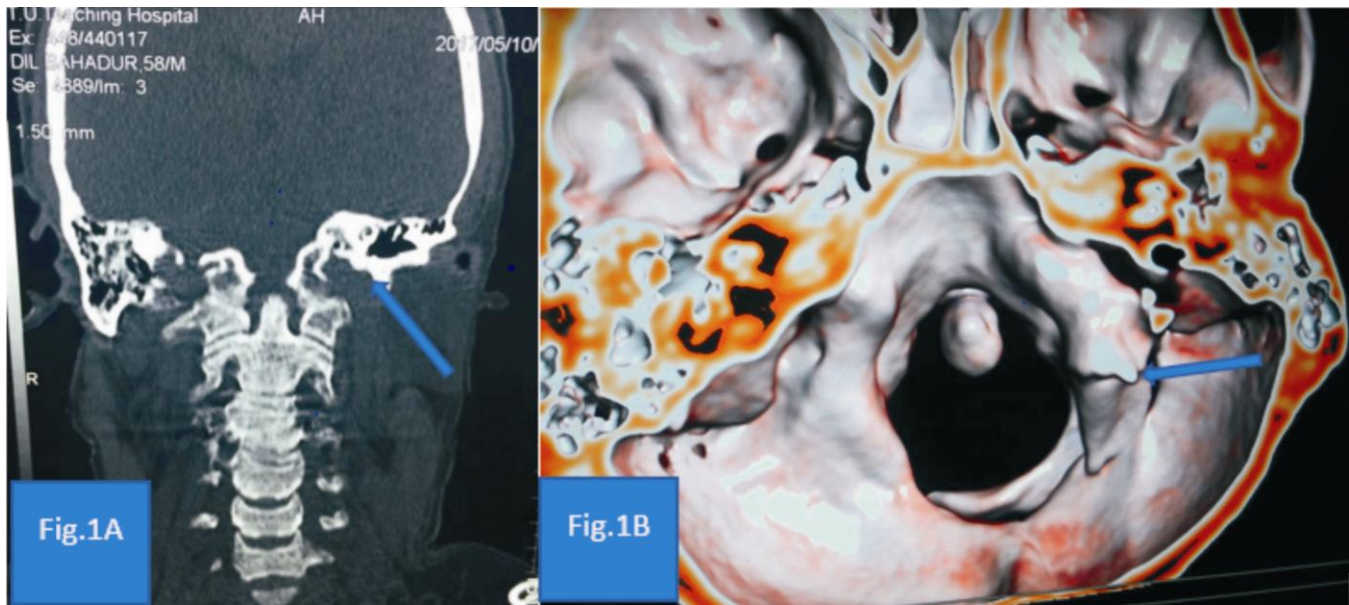


Fig. 1: Computed tomography. Coronal view of right occipital condylar fracture arrow head (A) and Axial 3D reconstructed image showing fracture line arrow head (B).

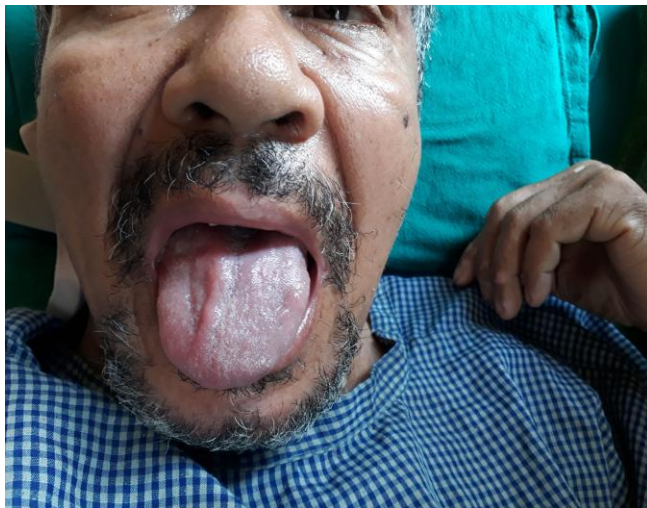


Fig. 2: Patient with weakness of right half of tongue with deviation

present (Fig. 2) but the hearing on the right had improved to some extent. Other cranial nerves were intact. No myelopathy was seen.

DISCUSSION

Fracture of the occipital condyle are rare entities. It is further more less common in pediatric age group.⁵The most common cause of OCF is road traffic accident.⁶ The possibility of having this injury increases when

there is presence of lower cranial nerves palsies. It is rarely diagnosed based on classic plain X-ray images alone. Therefore, the diagnosis should be extended with CT-scan of the head with the visualization of the superior part of the cervical segment of the spine in every case with suspicion for OCF. CT-scan of the head is the initial diagnostic tool for early confirmation of the diagnosis.⁷ Prompt diagnosis and early treatment are critical in these cases. There is no obvious robust guideline in the literature claiming the role of MRI as the diagnostic tool in the occipital condyle fractures.⁸ However, MRI constitutes supplement to CT-scan, as it helps in evaluating damage in the soft tissue injuries like ligamentous apparatus of the craniovertebral junction and potential damage of the vital structures like medulla oblongata/the spinal cord at same level. MRI also serves as a source of information in case of accompanying neurological deficits, particularly at the side of the cranial nerves and in case of suspicion of co-existing vascular damage.

There are two commonly used classification systems for occipital condylar fractures Anderson-Montesano and Tuli et al.⁹

Anderson-Montesano classification defines three types of fractures.

Type -I: Comminuted fracture of the condyle due to axial compression.

Type-II: Basilar skull fracture that extends to the

occipital condyle.

Type -III: Avulsion fractures as a result of disruption of various size of bone fragment of the condyle near the alar ligament. This type of fracture is usually unstable in nature.

In the present case fracture was of type II.

Tuli's classification of OCF.

Type-I: Undisplaced and stable fractures.

Type-II:

Type IIA: Displaced, stable fractures.

Type IIB: Displaced, unstable there is instability at the level of occiput-C1/C2.

CONCLUSION

OFC are of clinical importance because of its proximity to lower cranial nerves. However, diagnosis is frequently missed and needs close evaluation. Many injuries can be managed conservatively. Early diagnosis helps to prevent neurological deficits, provides early intervention and helps in prognostication.

Conflict of Interests

There is no conflict of interest.

Address for Correspondence:

Gopal Sedain, Assistant Professor, Department of Neurosurgery, Institute of Medicine, Tribhuvan University Teaching Hospital, Kathmandu Nepal

REFERENCES

1. Bell C. Surgical observations. *Middlesex Hosp J.* 1817; 4: 469-70.
2. Bloom AI, Neeman Z, Slasky BS, et al. Fracture of the occipital condyles and associated craniocervical ligament injury: incidence, CT imaging and implications. *Clin Radiol.* 1997; 52: 198-202.
3. Wessels LS. Fracture of the occipital condyle: a report of 3 cases. *S Afr J Surg.* 1990; 28: 155-6.
4. Noble ER, Smoker WR. The forgotten condyle: the appearance, morphology, and classification of occipital condyle fractures. *AJNR Am J Neuroradiol.* 1996; 17: 507-13.
5. J.M. Aulino, L.K. Tutt, J. J. Kaye, P.W. Smith, and J. A. Morris Jr., "Occipital condyle fractures: clinical presentation and imaging findings in 76 patients," *Emergency Radiology*, 2005; 11 (6): 342-47.
6. S. Momjian, A. R. Dehdashti, P. Kehrl, D. May, and B. Rilliet, "Occipital condyle fractures in children," *Pediatric Neurosurgery*, 2003; 38 (5): 265-70.
7. T. Kapapa, C. A. Tschan, K. K'onig et al., "Fracture of the occipital condyle caused by minor trauma in child," *Journal of Pediatric Surgery*, 2006; 11 (10): 1774-76.
8. F. J.Mueller, B. Fuechtmeier, B. Kinner et al., "Occipital condyle fractures. Prospective follow-up of 31 cases within 5 years at a level 1 trauma centre," *European Spine Journal*, 2012; 21 (2): 289-94.
9. A. Leone, A. Cerase, C. Colosimo, L. Lauro, A. Puca, and P. Marano, "Occipital condylar fractures: a review," *Radiology*, 2000; 216 (3): 635-44.

AUTHORS DATA

Name	Post	Institution	E-mail	Role of Authors
Dr. Prakash Kafle		Department of Neurosurgery, Nobel Medical College, Biratnagar, Nepal		Review of Paper
Dr. Gopal Sedain	Assistant Professor	Department of Neurosurgery, Institute of Medicine, Tribhuvan University Teaching Hospital, Kathmandu Nepal	newron79@gmail.com	Paper Writing
Dr. Sushil Krishna Shilpakar				Data Collection
Dr. Mohan Raj Sharma				Literature Search
Dr. Amit B. Pradhanang				Typing
Dr. Binod Rajbhandari				Proof Reading
Dr. Dipendra Shrestha				Figures

Date of Submission: 31-10-2018

Date of Printing: 15-12-2018