

# Surgical Outcome of Anterior Skull Base Approach for Combined ENT and Neurosurgical Lesions

FAZAL-I-WAHID,<sup>1</sup> HABIB-UR-REHMAN,<sup>1</sup> MUHAMMAD SALEEM<sup>1</sup>

Mumtaz Ali,<sup>2</sup> Zahid Khan<sup>2</sup>

<sup>1</sup>Departments of ENT, Head and Neck Surgery and <sup>2</sup>Neurosurgery  
Postgraduate Medical Institute, Lady Reading Hospital, Peshawar – Pakistan

## ABSTRACT

**Objective:** To determine surgical outcome of Anterior Skull Base approach for combined ENT and Neurosurgical Lesions.

**Material and Methods:** This descriptive study was conducted at the departments of ENT, Head, Neck Surgery and Neurosurgery Postgraduate Medical Institute (PGMI) Lady Reading Hospital Peshawar from March 2003 to Feb. 2008, with a total duration of five years. All these patients were admitted in ENT department. These patients were evaluated in terms of detailed history, thorough examination and radiological investigations. Incisional biopsy of the nasal mass was taken in cases where angiofibroma was excluded clinically, and then proper approach for excision of the lesion was planned. A well informed consent was taken from patient explaining the procedure, its risks, benefits and associated complications. The intracranial lesion was completely excised by neurosurgeons with help of microscope while the extracranial portion of the lesion was excised by ENT surgeon. The specimen of the lesions was examined by Histopathologist.

**Results:** This study included 23 patients in the age range of 12 – 51 years, mean age 25 years. Eighteen patients were male and five were female with female to male ratio of 1:3.6. These patients presented mainly with complaints of nasal obstruction, epistaxis and headache. CT scans were performed in all 23 cases (100%) while MRI in 5 cases (21.73%). These patients presented with advanced disease on radiological findings and they were treated by combined approach by Neurosurgeons and Otorhinolaryngologists. On histopathology of the specimen angiofibroma was on top. Two patients were subjected to radiotherapy postoperatively. There was no mortality and no recurrence of the disease.

**Conclusion:** The anterior skull base approach has good surgical outcome in terms of complete clearance of the disease and minimum morbidity for combined neurosurgical and ENT lesions irrespective of the nature of the lesion.

**Key Words:** Fungal rhino sinusitis, combined skull base approach, advanced angiofibroma, Anterior skull base, Esthesioneuroblastoma.

## INTRODUCTION

The skull base surgery is one of the most demanding surgeries.<sup>1</sup> It is very important for the surgeon to choose the right approach in order to reach the lesion without harming the other intact structures.<sup>1,2</sup> Due to the pioneering work of Cushing, Hirsch, Yasargil, Krause and Dandy, it is possible to address the tumor and other lesions in the anterior cranial base.<sup>1-3</sup> During

the last 20 years different skull base approaches are described for various neurosurgical lesions. The selection of an approach may differ from country to country.<sup>3,4</sup> With the transsphenoidal, the frontolateral and pterional approach nearly every region of the anterior skull base is exposable.<sup>2</sup>

Most of the lesions involving the anterior cranial fossa arise from the nose, sinuses and orbits. The

tumors of the anterior skull base may be benign or malignant.<sup>4,5</sup> The common benign tumors in this group include tumors that arise in the nasal cavity and paranasal sinuses i.e. juvenile angiofibroma, inverted papilloma while malignant tumors include lymphoma, nasopharyngeal carcinoma and esthesioneuroblastoma.<sup>3</sup> Nowadays there is a growing incidence of fungal infection at the anterior skull base.<sup>5,6</sup>

The clinical presentation of skull base lesions varies greatly and relates directly to the location of the lesion and the growth rate. They may include nasal obstruction, headache, recurrent sinusitis, cranial nerve palsies, hearing loss, shortness of breath, CSF rhinorrhea, and hoarseness. Headache and diplopia are the most common occurring in approximately 60 – 65% of patients. Facial weakness, loss of taste and otalgia may occur.<sup>2,7</sup>

The diagnosis of these lesions depend on detailed clinical information, radiological investigation and tissue biopsy.<sup>6,8</sup> The basic principle underlying anterior skull base approach is en bloc resection of the lesion and to get a tumor – free margin of at least 1 cm.<sup>9</sup> Because of the propensity for spread of malignant cells, quick debulking is needed. Preoperative and postoperative radiotherapy in cases involving radiosensitive tumors such as esthesioneuroblastoma and ethmoid cell cancer is performed.<sup>8,9</sup> The anterior skull base approach has several advantages. (1) It affords a broad exposure of the anterior skull base. (2) It provides an excellent access to the medial orbital walls and to the sphenoidal, nasal and paranasal cavities. (3) It allows simultaneous intradural and extradural tumor removal and safe reconstruction of dural defects. (4) It does not require facial incisions. (5) It is performed with minimal frontal lobe manipulation.<sup>10,11</sup>

**MATERIAL AND METHOD**

This descriptive study was conducted at the departments of ENT, Head, Neck Surgery and Neurosurgery Postgraduate Medical Institute (PGMI) Lady Reading Hospital Peshawar from March 2003 to Feb. 2008, with a total duration of five years. The patients of all age and both sex were included in the study while those who had previous intervention or refused surgery were excluded and the study was approved by ethical committee of the institute. All these patients were admitted in ENT department and were evaluated in terms of detailed history, thorough examination and radiological investigations. Incisional biopsy of the nasal mass was taken in cases where angiofibroma was

excluded clinically, and then proper approach for excision of the lesion was planned. CT scans were performed in all cases and MRI where it needed. As these patients were in advanced stage of the diseases so they were discussed with neurosurgical colleagues. A well informed consent was taken from patient explaining the procedure, its risks, benefits and associated complications. These patients were operated in Neurosurgical Operation Theatre and a combined approach to the anterior skull base by Neurosurgeon and ENT surgeon was adopted. The intracranial lesion was completely excised by neurosurgeons with help of microscope while the extracranial portion of the lesion was excised by ENT surgeon in same setting. The specimen of the lesions was examined by Histopathologist.

**RESULTS**

This study included 23 patients in the age range of 12-51 years, mean age 25 years. Eighteen patients were male and five were female with female to male ratio of 1:3.6. These patients presented mainly with complaints of nasal obstruction, epistaxis and headache (Table 1). CT scans were performed in all 23 cases (100%) while MRI in 5 cases (21.73%). These patients presented with advanced disease on radiological findings (Table 2). These patients were treated by combined approach by Neurosurgeons and Otorhinolaryngologists and two cases were subjected to radiotherapy postoperatively. Blood was transfused in 23 cases (100%) pre-operatively while in 8 cases (34.78%) postoperatively

**Table 1:** Clinical features of the Patients (n = 23).

S. No.	Symptoms	No. of Cases	Percentage
1.	Nasal Obstruction	21	91.30%
2.	Epistaxis	11	47.82%
3.	Frontal Headache	09	39.13%
4.	Impaired Vision	05	21.73%
5.	Decreased Hearing	03	13.04%
	<b>Signs</b>		
1.	Nasal Mass	15	65.21%
2.	Proptosis	06	26.08%
3.	Diplopia	04	17.39%
4.	Dull T. Membrane	02	08.69%

with average amount of 1050 ml. Palatal fistulae were developed in 2 cases (8.6%) while fits was observed post-operatively in one case (4.3%). There was no mortality and no recurrence of the disease. Combined Neurosurgical and ENT procedures were performed in these patients for excision of lesions (Table 3). Angiofibroma was on top on histopathology study of the specimens (Graph 1).

**DISCUSSION**

Different surgical approaches for anterior skull base lesions have been performed since a longtime.<sup>12</sup> During the 1970s and 1980s several institutions around the world pioneered open procedures to the anterior skull base.<sup>13,14</sup> The frontal, bifrontal, pterional approaches, and their variations like expanded bifrontal,

**Table 2:** Radiological findings of the Patients (n = 23).

S. No.	Sites Involvement by Lesions	No. of Cases	Percentage
1.	Nose, Nasopharynx, Sinuses	23	100%
2.	Pterygopalatine fossa, Infratemporal fossa, Cheek, Orbit	15	65.21%
3.	Middle Cranial Fossa	13	56.52%
4.	Anterior Crania Fossa	10	43.47%

**Table 3:** Surgical procedures adopted in this study (n = 23).

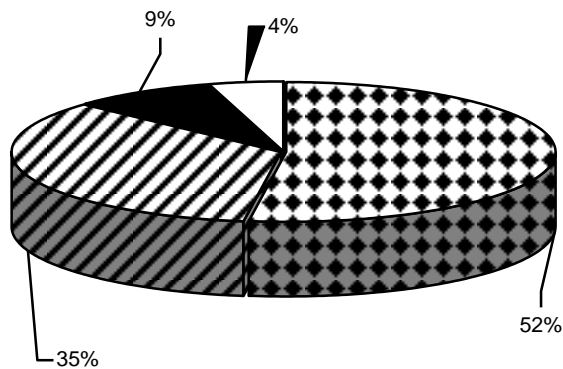
S. No.	Procedure	No. of Cases	Percentage
1.	Trans basal Sub Frontal	23	100%
2.	Transpalatal	11	47.82%
3.	Lateral Rhinotomy	09	39.13%
4.	Midfacial Degloving	03	13.04%

results of Pan Jian – wei and colleagues who reported nasal obstruction (78.9%), epistaxis (45.82) , headache and dizziness (35.98%) and visual regression in 5 (23.8%).<sup>18,19</sup>

The indication of anterior skull base approach in our study was angiofibroma 12 cases (52%), fungal infection 35% and one case of Teratocarcinosarcoma (4.3%) and Arbolay OL reported angiofibroma 43% and fungal infection 29%.<sup>20,21,23</sup> The benign lesions in our study were 12 cases (52%) and malignant diseases were 11 cases (47.82%) treated by surgery are comparable with study conducted by Zimmer LA<sup>11</sup> who reported benign diseases 48% and malignant tumors 41.34%. The esthesioneuroblastoma was 2 cases (8.6%) in our study which is comparable with Vrionis FD and colleagues<sup>1</sup> study that also found esthesioneuroblastoma 3% and treated by excision followed by chemoradiotherapy.

As in our study a combination of approaches by Neurosurgeon and ENT surgeon for anterior skull base is also adopted in other institutes as stated by scholz M and colleagues.<sup>4,21</sup>

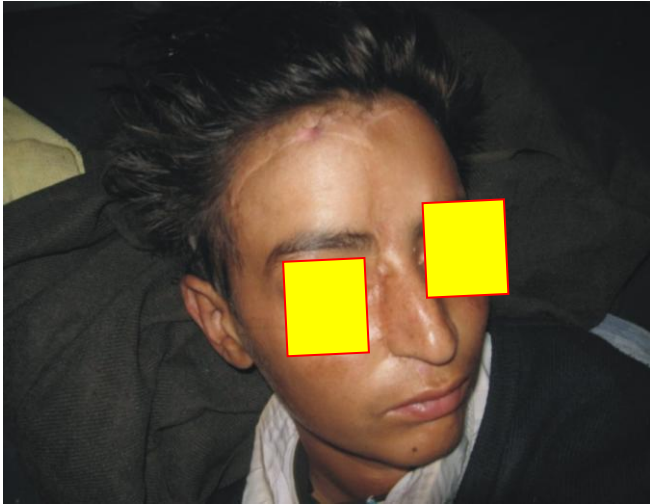The complication in our study were fistulae in 2 cases (8.6%) while fits was observed postoperatively in one case (4.3%) which are in keeping with study of Chandler JP<sup>10,22</sup> who reported cerebrospinal fluid leak 11% and post-op seizure 8%. These patients were followed regularly and no recurrence was noted which



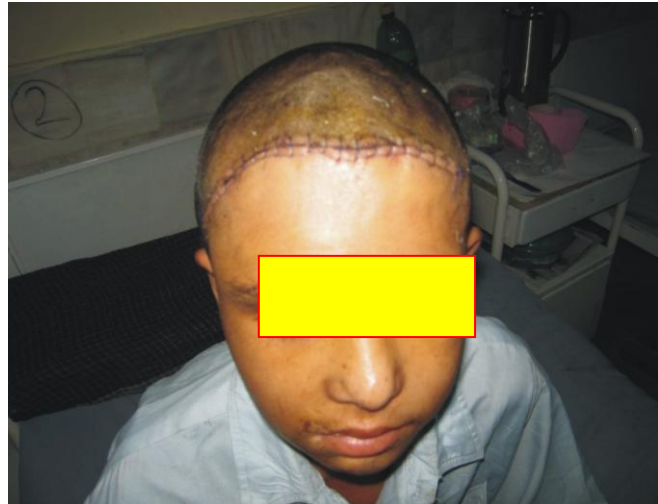**Graph 1:** Distribution of diseases in this study (n = 23).

frontotemporal, orbitozygomatic, and transbasal are the most common open transcranial procedures.<sup>15</sup> The anterior skull base approach play a fundamental role in modern neurosurgery by reducing surgical morbidity and mortality.<sup>16,17</sup>

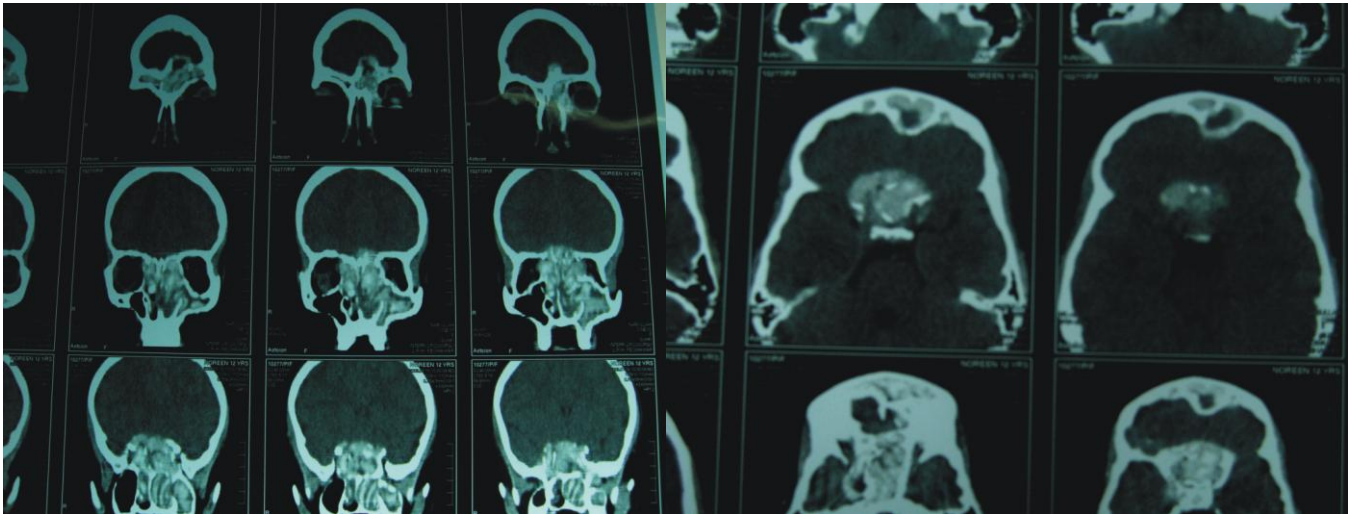
The presentation of patients in our study were nasal obstruction (91.30%), Epistaxis (47.82%) and headache was 39.13% which are comparable with



**Fig 1:** Post op picture of patient showing scars of Lateral Rhinotomy and Frontal Craniotomy.



**Fig 2:** Post op picture of the patient showing scar of Frontal Craniotomy.



**Fig. 3:** CT scans paranasal sinuses and brain showing heterogeneous lesion (Fungus) with intracranial extension.

is contradictory to the study of Erik WM<sup>23</sup> study who reports recurrence in 2.3%, the reason may be complete clearance of the lesion followed by adequate chemoradiotherapy in our study.

As nowadays the trend of less invasive surgery is evolving round the world but in our set up due to lack of sophisticated technology we are dependent on traditional techniques. If proper expertise is available one can treat anterior skull base benign and malignant lesions adequately as we dealt with. The reason for minimum morbidity in our study was proper pre-op evaluation, adequate operative techniques and meticulous post-op care.

## CONCLUSION

The anterior skull base approach has good surgical outcome in terms of complete clearance of the lesion and minimum morbidity for combined neurosurgical and ENT lesions irrespective of the nature of the lesion.

*Address for correspondence:*

*Dr. Fazal-I-Wahid*

*Junior Registrar*

*Department of ENT, Head & Neck Surgery*

*PGMI / LRH, Peshawar*

Contact No. 091-9211430. (ext. 3065)

Mobile No. 0343-9083224.

E-Mail: drfazal58@yahoo.com

## REFERENCES

1. Vrionis FD, Kienstra MA, Rivera M, and Padhya TA. Malignant Tumors of the Anterior Skull Base. *Cancer Control* 2004; 11: 144-51.
2. Hammad OU, Ali AK, Ezzat WA, Elbahy K, El Hakim AH. Mini Craniotomy for Anterior Skull base Lesions. *E.J.N.S.* 2006; 21: 103-14.
3. Kellman RM, Marentette L. The Transglabellar / Subcranial Approach to the Anterior Skull Base: A Review of 72 Cases *Arch Otolaryngol Head Neck Surg.* 2001; 127: 687-690.
4. Scholz M, Parvin R, Thissen J, Löhnert C, Harders A and Blaeser K. Skull base approaches in neurosurgery. *Head and Neck Oncology* 2010; 2: 2-9.
5. Serbetci E., Sengor GA. Transnasal endoscopic approach for anterior skull base angiomatosis complicated by a meningocele. *Kulak Burun Bogaz Ihtis Derg* 2008; 18: 242-245.
6. Ozlen F, Abuzayed B, Dashti R, Isler C, Tanriover N, Sanus GZ. Low – Profile 1 – Piece Bifrontal Craniotomy for Anterior Skull Base Approach and Reconstruction. *Journal of Craniofacial Surgery* 2010; 21: 1, 233-238.
7. Kasliwal MK, Yerramneni VK, Kiran NAS, Suri A, Mahapatra AK, Sharma MC et al. Giant sphenothmoidal nasopharyngeal schwannoma with anterior skull base extension managed by a total anterior transbasal approach. *Neurology India*; 2007; 55: 429-31.
8. Jho HD, Ha HG. Endoscopic endonasal skull base surgery: Part 3 – the clivus and posterior fossa. *Minim Invasive Neurosurg* 2004; 47: 16-23.
9. Banerji D, Behari S, and Tyagi I, Pandey T, Jain VK, Chhabra DK. Extended frontobasal approach to the skull base. *Neurol India* 2001; 49: 253-57.
10. Chandler JP, Silva Fe. Extended Transbasal Approach to Skull Base Tumors. *Oncology* 2005; 19: 3-10.
11. Zimmer LA, Theodosopoulos PV. Anterior skull base surgery: open versus endoscopic. *Current Opinion in Otolaryngology and Head and Neck Surgery* 2009; 17: 75-78.
12. David SY Wong, Chiu TW, George KC Wong, XL Zhu, Micky WT Kwok, and CM Ho, Andrew DR Burd. Epithelioid haemangioendothelioma of the anterior skull base: what is the optimal treatment? *Hong Kong Med J* 2009; 15: 308-10.
13. Carlos Suarez C, Llorente JL, Leon RFD, Maseda E and Lopez A. Prognostic Factors In Sinonasal Tumors Involving The Anterior Skull Base. *Wiley Periodicals, Inc. Head Neck* 2004; 26: 136–144.
14. Kuhn, Frederick A, Javer and Amin R. Low – Grade Fibrosarcoma of the Anterior Skull Base: Endoscopic Resection and Repair. *American Journal of Rhinology* 2003; 17: 347-350.
15. Batra, Pete S, Citardi, Martin J, Worley, Sarah et al. Resection of Anterior Skull Base Tumors: Comparison of Combined Traditional and Endoscopic Techniques *American Journal of Rhinology*, 2005; 19: 521-528.
16. Moon SK, Huh SK, Shin MS, Lee KS, Jung N. Supra-orbital Approach to Anterior Skull Base and Intraorbital Lesions. *J Korean Neurosurg Soc.* 1995; 24: 272-277.
17. Gil Z, Fliss DM. Practical Tips to Perform the Subcranial Approach. *Pearls and Pitfalls in Head and Neck Surgery* 2008; 4: 130–131.
18. Venkataramana NK, Anantheswar YN. Pediatric anterior skull base tumors: Our experience and review of literature. *J Pediatr Neurosci* 2010; 5: 1-11.
19. Pan Jian-Wei, Zhan Ren-Ya, Tong Ying, Zheng Jie – Sheng, Wan Shu, Huang Hong – Guang et al. Treatment of skull base communicating tumor with endoscope – assisted microneurosurgery and diode laser. *Chinese Medical Journal* 2007; 120: 342-44.
20. Trivedi NP, Kuriakose MA, and Iyer S. Reconstruction in skull base surgery: Review of current concepts. *Indian J Plast Surg* 2007; 40: 52-9.
21. Arbolay OL, Gonzalez JG, Gonzalez RH and Galvez YH. Extended Endoscopic Endonasal Approach to the Skull Base. *Minim Invasive Neurosurg* 2009; 52: 114-118.
22. Erik WM, Heinrich I and Alessandro B. Transcranial Combined Neurosurgical Approach to the Paranasal Sinuses for Anterior Skull Base Malignancies. *Skull base* 2009; 19: 151-158.
23. Tommasi AD, Cascardi P, Tommasi CD, Luzzi S and Ciappettas P. Emergency surgery in a severe penetrating skull base injury by a screwdriver: case report and literature review. *World Journal of Emergency Surgery* 2006; 1: 10-36.