

ORIGINAL ARTICLE

# Micro-endoscopic Disectomy: Early Experience and Results

**AHMED TASHFEEN ASHRAF***Department of Neurosurgery, PNS Shifa, Karachi*

## ABSTRACT

**Objective:** This prospective study was conducted to assess results and experience with microscopic endoscopic disectomy (MED).

**Study Design:** This is a prospective study carried out at PNS Shifa, which is a tertiary care hospital, from July 2011 to June 2012.

**Methods:** Thirty eight patients underwent surgery in which the MED system was used; all procedures were performed under general anesthesia. All patients were followed prospectively. MED system used in this study consisted of tubular retractors and an endoscope with xenon light source and HD image system by Karl Storz co. Germany. Outcomes were measured using Macnab criteria.

**Results:** Thirty eight patients (27 males, 11 females) underwent MED for prolapsed lumbar intervertebral disc. Mean operating time was 80 minutes. Follow up ranged from 3 to 12 months with a mean follow up 7.8 months. Thirty two patients had an excellent outcome while three had a good outcome. Three patients had a poor outcome. One patient with a big dural tear required conversion to a standard microdiscectomy and was excluded from outcome assessment. Three complications were noted and were all related to dural tears.

**Conclusions:** Minimally invasive surgery using MED is clinically effective and reliable. Patient satisfaction is high and complications rates are comparable with those associated with traditional microdiscectomy procedures.

**Abbreviations:** MED: Microendoscopic disectomy, HD: High Definition.

**Key Words:** lumbar herniated disc • microdiscectomy • minimally invasive surgery • operating microscope.

## INTRODUCTION

The surgical treatment of prolapsed lumbar intervertebral disc has evolved since the initial report of lumbar disectomy by Mixer and Barr in 1934.<sup>1</sup> Caspar<sup>2</sup> in 1977 and Williams<sup>3</sup> in 1978 reported refinements in approach. Microsurgical disectomy or microdiscectomy is the currently accepted surgical procedure for lumbar disc prolapse with which all other techniques are compared.<sup>4</sup> In recent years new minimally invasive technologies have come up which have been applied to spinal surgery. The advantages of minimally invasive techniques have included smaller incision, less perioperative pain, early ambulation, short hospital stay and early return to work.<sup>5,6</sup> We report our results in 38 patients who underwent minimally invasive disectomy using MED with a new tubular dilator system.

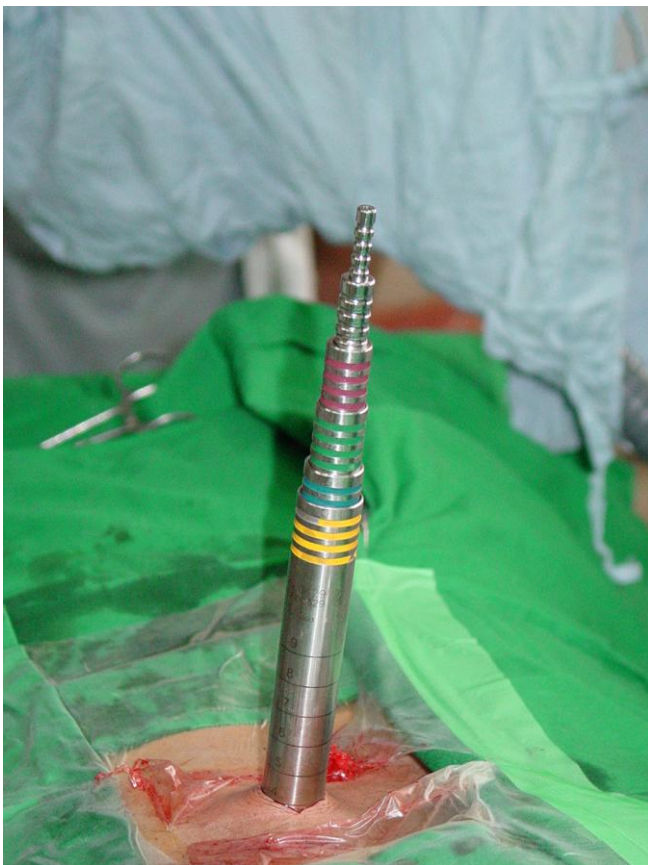## MATERIAL AND METHODS

Thirty eight patients with prolapsed lumbar intervertebral disc who were seen at our institution between May 2007 and April 2008 were included in the study. Data was collected prospectively. Pre-operatively all patients had a trial of conservative therapy before surgery was offered. This included a minimum period of 6 weeks of analgesics and rest. All patients had a pre-operative MRI of the lumbar spine. Lateral recess stenosis at the involved level was not a contraindication to MED. Informed written consent was taken from all patients. All patients completed a consent form and Patient Questionnaire – A form, prior to surgery. Detailed history and neurological examination were undertaken. Bladder and bowel dysfunction were specifically asked. Office follow-up visits were conducted at

2 weeks, 6 weeks, and 3 months. Office follow up was extended when clinically indicated.

### Operative Technique

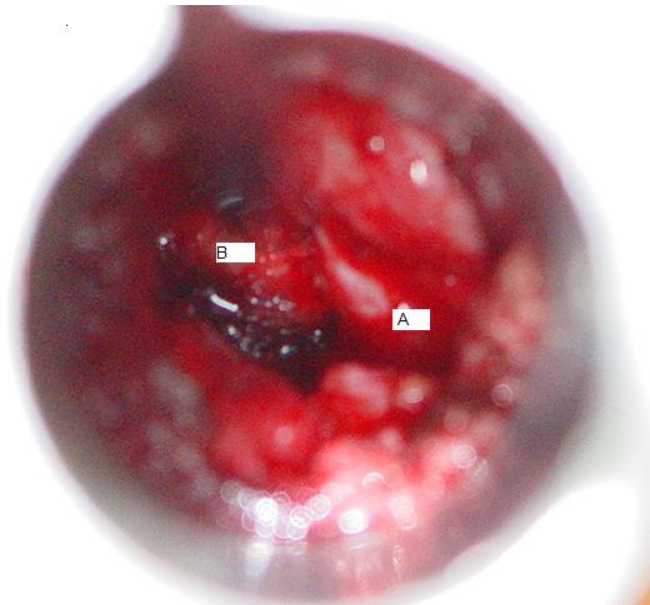
Under general anesthesia the patient was positioned prone on spinal frame. Skin preparation was done with povidone iodine. The MED system used for the procedure consisted of 19 mm tubular retractor system, endoscope with xenon light source and High definition image system. Under X-ray control a spinal needle was placed paramedian (1 cm lateral to midline) on the side of disc herniation and the position of the needle was adjusted till it was parallel to the center of the involved disc space. Subsequently a small incision was made and a K wire was placed under X-ray control at the offending disc level parallel to the disc space. Serial dilators were then passed over this Fig. 1.



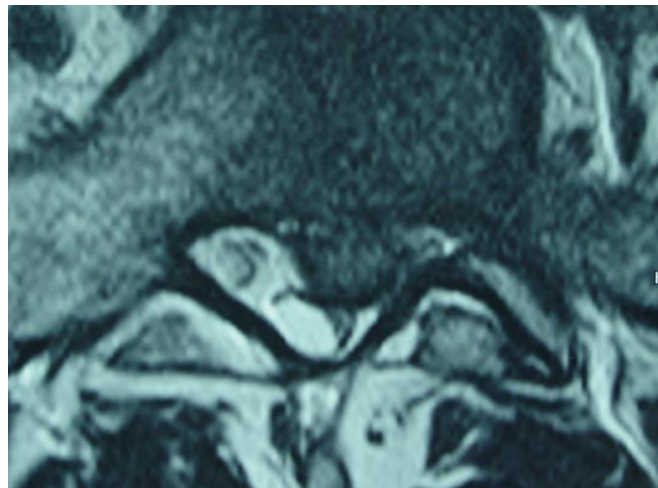
**Fig. 1:** Tubular dilators being inserted.

Finally, the largest 20 mm dilator was placed and fixed to the holding arm. Endoscope was then attached to the tubular retractor and rest of the procedure was

done under endoscopic control. The laminae, facet and ligamentum flavum were identified and a proper orientation and focus was achieved. Laminotomy and medial facetectomy was done using Kerrison punches. Ligamentum flavum was then cut using a knife and flavectomy achieved using a Kerrison rongeur. The nerve root and dural tube and protruded disc were identified Fig. 2.



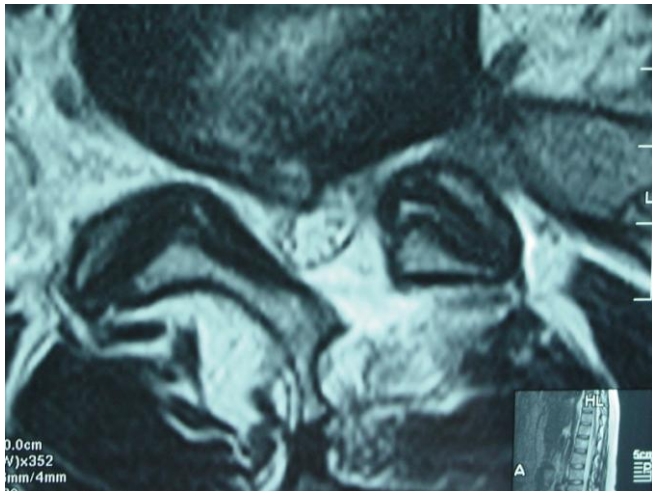
**Fig. 2:** View from inside the tubular retractor A: Nerve root; B: Protruded disc.



**Fig. 3:** L<sub>5</sub> – S<sub>1</sub> Disc prolapsed.

Discectomy and rhizolysis of the involved nerve root was carried out. Where necessary posterior osteo-

phytes could also be removed and lateral recess could also be adequately decompressed. Closure involved sub-cuticular absorbable stitches. Peri-operative antibiotics were given for 48 hours. The patients were ambulated as soon as the effects of general anaesthesia wore off (usually within 6 hours of the surgery) and were discharged on the 2<sup>nd</sup> post operative day. Post-operative MRI was done in early cases in the series to assess the postoperative status Fig. 3, Fig. 4.



**Fig. 4:** Post op status.

Outcome assessment was done using the modified Macnab criteria.<sup>5</sup> (Table 1).

**Table 1:** Modified Macnab criteria to assess clinical outcome following MED.

|                  |   |
|------------------|---|
| <b>Excellent</b> | Free of pain<br>No restriction of mobility<br>Able to return to normal work and activities  |
| <b>Good</b>      | Occasional nonradicular pain<br>Relief of presenting symptoms<br>Able to return to modified work  |
| <b>Fair</b>      | Some improved functional capacity<br>Still handicapped and / or unemployed  |
| <b>Poor</b>      | Continued objective symptoms of root involvement, Additional operative intervention needed at the index level, irrespective of repeat or length of post operative follow up |

## RESULTS

Thirty eight patients underwent MED at our institution between July 2011 and June 2012. There were 27 males and 11 females. The age group ranged from 22 years to 58 years. All patients had a virgin posterolateral disc herniation and of these 2 patients also had associated lateral recess stenosis. L<sub>4</sub> – L<sub>5</sub> and L<sub>5</sub> – S<sub>1</sub> were the most commonly involved levels (Table 2). All patients were ambulated within 6 hours of the surgery and were discharged within 48 hours of the surgery. During the latter part of series, patients were discharged within 24 hours of surgery. This excluded the patient with long dural tear in whom a conversion to the open procedure was done. Duration of post-operative follow up ranged from 3 months to 12 months with a mean follow up of 7.8 months. Most of the patients were able to return to work within six weeks. Although some of them could return to work as early as 15 days, the average time was around 28 days. There were a total of 3 complications (7.89%). All three were cases of dural tears and one was big enough to warrant conversion to open standard discectomy. The patient with dural tear which required conversion to the standard microdiscectomy was excluded from outcome assessment. Thirty two patients had excellent outcome, three patients had a good outcome and three had a fair outcome. Thus, overall success rate was 92.1% in our series. The mean operative time was 100 minutes. The cases done early in the series took a longer time of up to 160 minutes, however after gaining experience, the average time taken for surgery came down to about 80 minutes. The difficult cases which included migrated fragments and those with associated stenosis took a longer time, even after familiarization with the technique and equipment.

**Table 2:** Levels of herniated disc noted in patients included in our study (n = 38).

| Level of Herniation             | No. |
|---------------------------------|-----|
| L <sub>3</sub> – L <sub>4</sub> | 2   |
| L <sub>4</sub> – L <sub>5</sub> | 22  |
| L <sub>5</sub> – S <sub>1</sub> | 14  |

## DISCUSSION

The relationship between lumbar disc herniation and the syndrome of lumbago / sciatica has been well recognized since the 1930's.<sup>1</sup> Since then it has been a

constant endeavour to achieve the decompression of the offending nerve root by various operative techniques and innovations. Undoubtedly, the gold standard for lumbar disc surgery – microsurgical disectomy, was introduced by Yasargil<sup>8</sup> and Casper<sup>9</sup> separately in 1977. There have been several percutaneous systems introduced for lumbar disc prolapse such as chemonucleolysis,<sup>10</sup> percutaneous lumbar disectomy (manual<sup>11</sup> and automated<sup>12</sup>) and percutaneous laser assisted disectomy.<sup>13</sup> The advantages cited for these techniques have been surgery under local anesthesia, early mobilization, non disturbance of posterior structures such as laminae, facet and ligamentum flavum, less manipulation in the intraspinal space thus reducing the possibility of epidural fibrosis. The indications for these procedures are discogenic back pain and sciatica secondary to contained disc prolapse. These procedures cannot be used in cases of extruded disc fragments causing compression of the nerve root and they do not address the concomitant bony and ligamentous compression of the nerve root. The results of these procedures have been very variable and satisfactory results have ranged from 29 to 92%.<sup>4</sup> One randomized controlled trial comparing automated percutaneous lumbar disectomy (APLD) with microdisectomy for contained lumbar disc herniation showed that only 29% of the patients undergoing APLD had a satisfactory outcome when compared to 80% undergoing microdisectomy.<sup>14</sup>

The technique of microendoscopic disectomy using tubular retractors was described by Foley et al in 1997.<sup>7</sup> The indications for this procedure are posterolateral disc herniation with or without lateral recess stenosis and foraminal and extra-foraminal disc herniations.<sup>5,6,15</sup> It has also been successfully used for recurrent disc prolapsed,<sup>16</sup> decompression of lumbar stenosis and lateral recess stenosis secondary to facet or ligamentum flavum hypertrophy. Its use is also being extended for cervical foraminotomies and minimally invasive spinal instrumentation. The advantages of MED over standard microdisectomy include smaller incision, lesser post operative pain, early ambulation, short hospital stay, shorter time to return to work and lesser cost of treatment.<sup>5</sup> The patient's ability to return to the previous employment is a measure of success of the surgical procedure. As newer and more innovative techniques and systems for minimally invasive disc surgery are being developed, it has become important to analyse the impact of these techniques on the time taken by the patients to return to work. Bookwalter et al<sup>17</sup> reported that 40% of their patients retur-

ned to work in fewer than 5 weeks after microdisectomy while Casper et al<sup>18</sup> reported a mean return-to-work time of 18.6 weeks. Palmer<sup>11</sup> reported a mean return-to-work time of 32 days following this procedure, while Perez – Cruet et al<sup>5</sup> reported a mean return-to-work time of 17 days. In our series the patients were able to return to work as early as 15 days while the average time being 28 days. One study comparing the intraoperative electromyography (EMG) in the lower limb between MED and standard microdisectomy showed that there was lesser irritation of the nerve root in the former group.<sup>19</sup> Good to excellent outcomes have been reported in up to 94% of patients undergoing microdisectomy using tubular retractors.<sup>6,11</sup> This correlates well with the success rate seen in current series (92.4%). There are no reported randomized clinical trials comparing MED and conventional microdisectomy but there is one non-randomized prospective study in which the authors have compared MED with conventional microdisectomy.<sup>20</sup> In this study the average low back pain outcome score improvement was of clinical significance in both patient groups and there was no difference between the two groups. However, patients in the MED group required less postoperative analgesia during their stay. The authors concluded that MED is as effective as microsurgical disectomy for the treatment of uncontained or large contained disc herniations. The complications reported in patients undergoing MED<sup>6,10,11,20</sup> include wound infections (0 – 0.8%), discitis (0.8%), dural tears (2.3 – 7.1%) and recurrent disc prolapse (2.6 – 2.9%). The complications reported in large series with patients undergoing microdisectomy<sup>21</sup> are also similar and include wound infections (0 – 7.2%), discitis (0 – 0.8%), dural tears (0.7%) and recurrent disc prolapse (3 – 14%). The complications seen in our series is comparable to the other MED series.

## CONCLUSIONS

Microendoscopic Disectomy through tubular dilators is a safe and effective procedure for the treatment of prolapsed lumbar intervertebral disc. Its results are comparable to standard microdisectomy. The current indications for this procedure include posterolateral disc herniations and/or lateral recess stenosis.

*Address for Correspondence:  
Ahmed Tashfeen Ashraf  
Department of Neurosurgery  
PNS Shifa, Karachi*



## REFERENCES

1. Mixer WJ, Barr JS. Rupture of the intervertebral disc with involvement of the spinal canal. *N Eng J Med* 1934; 211: 210-5.
2. Finneson BE. Lumbar Disc Excision. In: Schmidek HH, Sweet WH, editors. *Operative Neurosurgical Techniques*. 3rd ed. WB Saunders: Philadelphia; 1995. p. 1905-23.
3. Hardy RW. Extradural cauda equina and nerve root compression from benign lesions of the lumbar spine. In: Youmans JR, editor. *Neurological Surgery*. 4th ed. WB Saunders: Philadelphia; 1996: p. 2357-74.
4. Maroon JC. Current concepts in minimally invasive discectomy. *Neurosurgery* 2002; 51: S137-45.
5. Perez – Cruet MJ, Foley KT, Isaacs RE, and Rice – Wyllie L, Wellington R, Smith MM, et al. Microendoscopic Lumbar Discectomy: Technical Note. *Neurosurgery* 2002; 51: S129-36.
6. Palmer S. Use of a tubular retractor system in microscopic lumbar discectomy: 1 year prospective results in 135 patients. *Neurosurg Focus* 2002; 13: E5.
7. Foley KT, Smith MM. Microendoscopic Discectomy. *Tech Neurosurg* 1997; 3: 301-7.
8. Yasargil MG. Microsurgical operation for herniated lumbar disc. In: Wullenweber R, Brock M, Hamer J, Klinger M, Spoerri O, editors. *Advances in Neurosurgery*. Springer – Verlag: Berlin; 1977: p. 81.
9. Caspar W. A new surgical procedure for lumbar disc herniation causing less tissue damage through microsurgical approach. In: Wullenweber R, Brock M, Hamer J, Klinger M, Spoerri O, editors. *Advances in Neurosurgery*. Springer – Verlag: Berlin; 1977: p. 74-7.
10. Smith L, Brown JE. Treatment of lumbar intervertebral disc lesion by direct injection of chymopapain. *J Bone Joint Surg Br* 1967; 49: 502-19.
11. Hijikata S. Percutaneous nucleotomy. A new concept technique and 12 years' experience. *Clin Orthop Relat Res* 1989; 238: 9-23.
12. Onik G, Helms CA, Ginsberg L, Hoaglund FT, Morris J. Percutaneous lumbar discectomy using a new aspiration probe. *Am J Roentgenol* 1985; 144: 1137-40?
13. Choy DS, Ascher PW, Ranu HS, Saddekni S, Alkatis D, Leibler W, et al. Percutaneous laser disc decompressions: A new therapeutic modality. *Spine* 1992; 17: 949-56.
14. Chatterjee S, Foy PM, Findlay GF. Report of a controlled clinical trial comparing automated percutaneous lumbar discectomy and microdiscectomy in the treatment of contained lumbar disc disease. *Spine* 1995; 20: 734-8.
15. Foley KT, Smith MM, Rampersaud YR. Microendoscopic approach to far lateral lumbar disc herniation. *Neurosurg Focus* 1999; 7: 5.
16. Isaacs RE, Podichetty V, Fessler RG. Microendoscopic discectomy for recurrent disc herniations. *Neurosurg Focus* 2003; 15: 11.
17. Bookwalter JW 3rd, Busch MD, Nicely D. Ambulatory surgery is safe and effective in radicular disc disease. *Spine* 1994; 19: 526-30.
18. Caspar W, Campbell B, Barbier DD, Kretschmmer R, Gotfried Y. The Caspar microsurgical discectomy and comparison with a conventional standard lumbar disc procedure. *Neurosurgery* 1991; 28: 78-87.
19. Schick U, Dohnert J, Richter A, Konig A, Vitzthum HE. Microendoscopic lumbar discectomy versus open surgery: An intraoperative EMG study. *Eur Spine J* 2002; 11: 20-6.
20. Schizas C, Tsiridis E, Saksena J. Microendoscopic Discectomy Compared with Standard Microsurgical Discectomy for Treatment of Uncontained or Large Contained Disc Herniations. *Operative Neurosurgery Supplement* 4. *Neurosurgery* 2005; 57: 357-60.
21. Ebeling U, Reichenberg W, Reulen HJ. Results of microsurgical lumbar discectomy. Review on 485 patients. *Acta Neurochir (Wien)* 1986; 8: 45-52.