

ORIGINAL ARTICLE

Variables that Predict Significant Intracranial Damage in Mild Head Injury

ADIL AZIZ, SADIA AZIZ KHAN, ATIF KAZMI

*Khaleeq-uz-Zaman**Department of Neurosurgery, Fauji Foundation Hospital, Rawalpindi*

ABSTRACT

Objective: To identify patients, at risk of intracranial complications, after mild head injury.

Study Design: It was an observational study.

Place and Duration: Patients received at the emergency department or OPD or referred to Pakistan institute of Medical Sciences, Islamabad were included in the study. Pakistan institute of Medical Sciences is a tertiary care hospital that recruits patients from Punjab and northern areas. The data was collected over a period of six months from 1st August 2008 till 31st January 2009. A total of 206 patients were included in our study.

Methodology: Data were analyzed relating to a consecutive series of 206 patients who presented to the emergency department of Pakistan Institute of Medical Sciences, Islamabad. Data was collected through non-probability convenience sampling. Characteristics studied, were age, gender, mode of trauma, level of consciousness and CT scan brain findings.

Result: Our study included 206 patients with mild head injury. Their age ranged from 1 to 90 years with a mean age of 32.06 ± 19.86 years. Maximum patients (59 patients 28.6%) were in the age range of 21 – 30 years. Only 34 (16.5%) patients were above 50 years of age and 26 (12.6%) were below the age of 10 years. 163 (79%) were males and remaining 43 (21%) were females. 124 (60.2%) were due to road traffic accidents, 62 (30.1%) were due to falls, 18 (8.7%) were assault injuries and 2 (0.9%) were sports injuries. All patients had a GCS score of 13 – 15; with a mean score of 14.35 ± 0.902 . Majority of the patients (132 patient, 64%) had a GCS of 15, 14 (6.8%) had a GCS of 14 and 60 (29%) had a GCS of 13. 127 (61.7%) patients presented with vomiting after head injury and 79 (38.3%) patients did not vomit. 49 (23.8%) vomited once and 78 (37.9%) vomited on multiple occasions. CT scan was done without contrast in all patients. It was reported as normal in 68 (33%) patients, 39 (18%) had extradural hematoma, 15 (7.3%) had subdural hematoma, 4 (1.9%) showed intracerebral hemorrhage, 30 (14.6%) had cerebral contusion, 6 (2.9%) had subarachnoid hemorrhage, 20 (9.7%) had diffuse axonal injury and 9 (11.7%) patients had skull fracture.

Conclusion: Our study was conducted to derive and validate a set of criteria that could be used to identify patients with minor head injury in whom CT could be forgone. It concluded that men, in their twenties, suffered from mild head injury, most commonly from a road traffic accident and were more likely to have an intracranial surgical lesion, such as an extra dural haematoma.

Keywords: Mild head injuries, vomiting, CT scan brain.

INTRODUCTION

Head injury can be defined as any alteration in mental or physical functioning related to a blow to the head. Loss of consciousness does not need to occur. The

severity of head injuries most commonly is classified by the initial post resuscitation Glasgow Coma Scale (GCS) score, which generates a numerical summed score for eye, motor, and verbal abilities. A score of

13 – 15 indicates mild injury, a score of 9 – 12 indicates moderate head injury, and a score of 8 or less indicates severe head injury. Concussion and mild head injury are synonymous.¹

The majority of TBI is classified as mild, and around 8 – 10% is classified as moderate or severe.² Patients with mild TBI have a good prognosis providing treatable complications are not missed. Overall mortality in this group is around 0.1% and is associated predominantly with missed intra-cranial haemorrhage.³ Although many patients may return to work after mild TBI,⁴ around 50% of survivors have moderate or severe disability as assessed by the Glasgow Outcome Scale (GOS) or the disability outcome scale;⁵ this represents significant morbidity.

In the United States, 1.5 million individuals per year suffer from a head injury. Of these injuries, 75% are classified as mild.⁶ Almost half of these are children less than 15 years old and males outnumber females by more than two to one. Most injuries are due to a fall (41%), followed by an assault (20%); the importance of road traffic accidents increases with the severity of injury, they cause only 13% in those attending hospital but account for a third of patients transferred to neurosurgery and 58% of deaths.⁷ Road traffic accidents, involving motor vehicle drivers, its occupants, cyclists, and pedestrians are the main risk factor for head injuries.⁸ Assaults in economically underdeveloped regions and during wartime are other major risk factors.⁹ Athletic participation, especially football and soccer, is another important cause of these injuries.^{10,11}

There is evidence that patients with mild TBI can be selected for CT scan based on clinical criteria. Two such criteria have been developed and prospectively validated. The Canadian CT head rule requires a head CT for patients with mild TBI and any one of the following: GCS < 15 two hours after injury, suspected open or depressed skull fracture, any sign of basilar skull fracture: hemotympanum, raccoon eyes (intra-orbital bruising), Battle's sign (retroauricular bruising), or cerebrospinal fluid leak, oto- or rhinorrhea, two or more episodes of vomiting, 65 years of age or older, amnesia before impact of 30 or more minutes, dangerous mechanism (pedestrian struck by motor vehicle, occupant ejected from motor vehicle, fall from ≥ 3 feet or ≥ 5 stairs).¹²

The goal of our study was to develop and validate a simple set of criteria for identifying patients with minor head injury who should undergo CT scanning.

MATERIALS AND METHODS

An observational study was carried out at the Pakistan institute of Medical Sciences, Islamabad. The data was collected over a period of six months from 1st August 2008 till 31st January 2009 with a total of 206 patients included in our study. Data was collected through non-probability convenience sampling. Patients of all ages and both genders, patients with traumatic brain injury having a GCS between 13 – 15 were included. Patients whose guardian and attendants did not give consent to participate in the study, patients with moderate or severe head injury, and those with polytrauma were excluded.

After taking permission from the hospital ethical committee all the patients fulfilling the criteria were enrolled in the study. Written informed consent was taken from the relatives. All patients with a GCS between 13 – 15, during the first 24 hours of traumatic brain injury were referred for a CT scan to the department of radiology at Pakistan institute of Medical Sciences and were reported by the radiologist. All patients were admitted for indoor assessment and treatment. The relatives were asked questions regarding age, mode of trauma and GCS according to the proforma. Data was entered and analyzed using SPSS 12. Descriptive statistics were used to calculate mean, standard deviation for age and GCS score.

Categorical variables included age group, gender, GCS and, anatomical findings of intracranial lesion on CT scan.

RESULTS

Our study included 206 patients with mild head injury.

Age Incidence

Their age ranged from 1 to 90 years with a mean age of 32.06 ± 19.86 years.

Maximum patients (59 patients 28.6%) were in the age range of 21 – 30 years. Age distribution was as follows (Figure 1).

Sex Incidence

163 (79%) were males and remaining 43 (21%) were females.

Modes of Trauma

Modes of trauma were as follows (Figure 2).

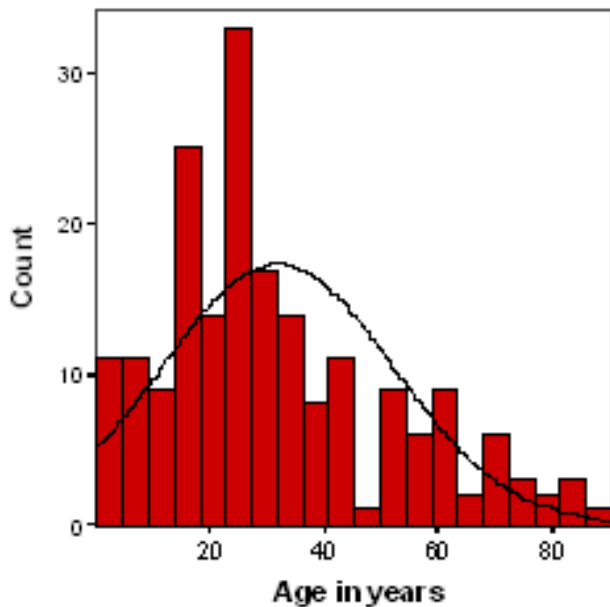


Fig. 1: Histogram showing age distribution of study group (n = 206).

Table 1:

Age Range	Frequency	Percent
0 – 10 years	26	12.6
11 – 20 years	37	18.0
21 – 30 years	59	28.6
31 – 40 years	26	12.6
41 – 50 years	24	11.7
51 – 60 years	17	8.3
61 – 70 years	6	2.9
71 – 80 years	7	3.4
81 – 90 years	4	1.9
Total	206	100.0

GCS

All patients had a GCS score of 13 – 15; with a mean score of 14.35 ± 0.902 . Majority of the patients (132 patient, 64%) had a GCS of 15, 14 (6.8%) had a GCS of 14 and 60 (29%) had a GCS of 13 (Figure 3).

CT scan was done without contrast CT Scan findings in all patients, the outcome were as follows (Table 2).

Table 2: CT scan diagnosis in study group (n: 206).

CT Scan Diagnosis	Percentage
Normal	33%
Extradural hematoma	7.3%
Subdural hematoma	1.9%
Intracerebral hemorrhage	14.6%
Cerebral contusion	2.9%
Acute subarachnoid hemorrhage	9.7%
Diffuse axonal injury	11.7%
Skull fracture	18%

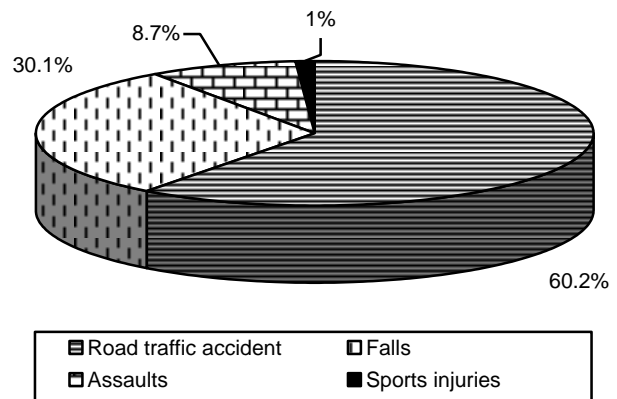


Fig. 2: Cause of head injury in the study group (n = 206).

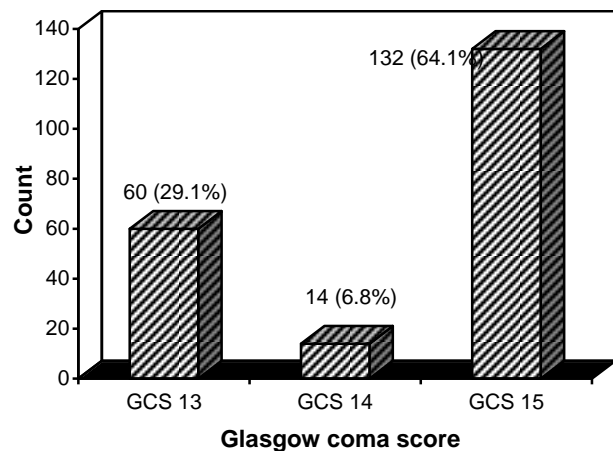


Fig. 3: Bar graph showing Glasgow coma score of study group (n = 206).

DISCUSSION

Among moderate and severe head injury a poor conscious level mandates imaging of the brain but in mild

head injury cases we need other predictors that can help us in deciding about the CT scanning of brain. We conducted this study to evaluate various variables as a predictor of intracranial lesion after mild head injury.

Mild Head Injury occurs as a result of external force, with reversible brain damage and without any structural damage. It is the most common type of head injury people suffer from. Although patients with MHI have a good Glasgow coma scale of 13 – 15, they still suffer from definite morbidity and mortality.

In our study road traffic accidents were the commonest cause in adults and fall were more common among children. In previous studies most childhood head injuries are secondary to falls.¹³ A smaller number follow road traffic accidents where, unlike adults the majority are pedestrians or cyclists. Assaults are rare and occur mostly in infants (non-accidental injuries) and teenagers. Our data supported this distribution of etiology.

In our study 61.7% patients presented with vomiting after head injury and 38.3% patients did not vomit. Our results supplement previous observations that vomiting is a common symptom after head trauma, occurring in approximately 1 of every 6 patients.¹⁴⁻¹⁶

Approximately two thirds of patients with head trauma in the United States are classified as having minor head injury¹⁷ less than 10 percent of patients with minor head injury have positive findings on CT scanning, and less than 1 percent require neurosurgical intervention.^{18,19} The options for evaluation have included skull radiography, CT scanning, and observation in the emergency department or hospital. Several studies have concluded that patients with normal findings on neurological examination and CT scanning can be safely discharged from the emergency department.²⁰⁻²² CT is the preferred imaging study for patients with minor head injury, although magnetic resonance imaging (MRI) is more sensitive in detecting subtle lesions.²³ As MRI becomes more widely available, it may have a greater role in the evaluation of patients with minor head injury.²⁴

The question of which patients with head trauma should undergo scanning has remained controversial since the introduction of computed tomography (CT) in the early 1970s. Initially, CT was a scarce resource reserved for severely injured patients. As CT scanners became more widely available, numerous studies of CT have focused on patients with minor head injury who have intracranial lesions. In the early 1990s, seve-

ral retrospective studies of patients with minor head injury reported substantial proportions with intracranial lesions on CT (17 to 20 percent). These studies included patients with scores of 13 to 15 on the Glasgow Coma Scale, indicating little or no impairment in consciousness. The authors concluded that CT was indicated in all patients with minor head injury.²⁵⁻²⁷ In subsequent prospective studies of patients with a score of 15 on the Glasgow Coma Scale, the rate of intracranial lesions on CT was much lower (6 to 9 percent).²⁸

Further studies are required to formulate guidelines based on clinical features after mild head injury that would predict high probability of an intracranial lesion.

CONCLUSION

Our study derived the conclusion that men in their twenties were more likely to suffer from a road traffic accident and appear stable with mild head injury but apparently harbor a lethal extradural haematoma and die from it, if not recognized and treated. By keeping in mind the simple predictors such as age, gender, mode of injury, and level of consciousness we can identify those patients who are at a low risk of intracranial complications and safely discharge them. The remainder would form the high risk group requiring combination of imaging and admission.

Address for Correspondence:

Dr. Adil Aziz Khan

*House No. 25, PAF Base Road, Askari – 8
Chaklala, Rawalpindi.*

E-Mail Address: khanadil_1@hotmail.com

Phone Number: 0305-5550335

REFERENCES

1. Bazarian JJ, McClung J, Shah MN. Mild traumatic brain injury in the United States, 1998 – 2000. *Brain Inj* Feb 2005; 19: 85-91.
2. Yates PJ, Williams WH, Harris A, Round A, Jenkins R. An epidemiological study of head injuries in a UK population attending an emergency department. *J Neurol Neurosurg Psychiatry* 2006; 77: 699–701.
3. Klauber MR, Marshall LF, Luerssen TG, Frankowski R, Tabaddor K, Eisenberg HM. Determinants of head injury mortality: importance of the low risk patient. *Neurosurgery* 1989; 24: 31–6.
4. Van der Naalt J, Van Zomeren AH, Sluiter WJ, Minderhoud JM. One – year outcome in mild to moderate head injury: the predictive value of acute injury characteri-

Variables that Predict Significant Intracranial Damage in Mild Head Injury

- stics related to complaints and return to work. *J Neurol Neurosurg Psychiatry* 1999; 66: 207–13.
5. Vos PE, Battistin L, Birbamer G. EFNS guideline on mild traumatic brain injury: report of an EFNS task force. *Eur J Neurol* 2002; 9: 207–19.
 6. Thurman DJ, Alverson C, Dunn KA. Traumatic brain injury in the United States: A public health perspective. *J Head Trauma Rehabil* 1999; 14: 602-15.
 7. Tennant A. Admission to hospital following head injury in England: incidence and socio-economic associations. *BMC Public Health* 2005; 5: 21.
 8. Heng KW, Lee AH, Zhu S. Helmet use and bicycle – related trauma in patients presenting to an acute hospital in Singapore. *Singapore Med J* 2006; 47: 367-72.
 9. Swann IJ, MacMillan R, Strong I. Head injuries in an inner city accident and emergency department. *Injury* 1980; 12: 274-8.
 10. Centers for Disease Control and Prevention. Sports – related recurrent brain injuries – United States. *MMWR Morb Mortal Wkly Rep* 14 1997; 46: 224-7.
 11. Matser JT, Kessels AG, Jordan BD. Chronic traumatic brain injury in professional soccer players. *Neurology* 1998; 51: 791-6.
 12. Smits M, Dippel DW, de Haan GG. External validation of the Canadian CT head rule and the New Orleans criteria for CT scanning in patients with minor head injury. *JAMA* 2005; 294: 1519.
 13. Pascucci RC. Head trauma in the child. *Intensive Care Med* 1988; 14: 185–95.
 14. Barabas G, Matthews WS, Ferrari M. Childhood migraine and motion sickness. *Pediatrics* 1983; 72: 188-90.
 15. Apley J, Naish N. Recurrent abdominal pains: a field survey of 1000 school children. *Arch Dis Child* 1958; 33: 165-70.
 16. Abu – Arafeh I, Russel G. Recurrent limb pain in school children. *Arch Dis Child* 1996; 74: 336-9.
 17. Kraus J, Nourjah P. The epidemiology of mild uncomplicated brain injury. *J Trauma* 1988; 28: 1637-43.
 18. Miller EC, Holmes JF, Derlet RW. Utilizing clinical factors to reduce head CT scan ordering for minor head trauma patients. *J Emerg Med* 1997; 15: 453-7.
 19. Jeret JS, Mandell M, Anziska B. Clinical predictors of abnormality disclosed by computed tomography after mild head trauma. *Neurosurgery* 1993; 32: 9-15.
 20. Stein SC, O'Malley KF, Ross SE. Is routine computed tomography scanning too expensive for mild head injury? *Ann Emerg Med* 1991; 20: 1286-9.
 21. Shackford SR, Wald SL, Ross SE. The clinical utility of computed tomographic scanning and neurologic examination in the management of patients with minor head injuries. *J Trauma* 1992; 33: 385-94.
 22. Livingston DH, Loder PA, Koziol J, Hunt CD. The use of CT scanning to triage patients requiring admission following minimal head injury. *J Trauma* 1991; 31: 483-7.
 23. Kelly AB, Zimmerman RD, Snow RB, Gandy SE, Heier LA, Deck MD. Head trauma: comparison of MR and CT – experience in 100 patients. *AJNR Am J Neuroradiol* 1988; 9: 699-708.
 24. Doezema D, King JN, Tandberg D, Espinosa MC, Orri-son WW. Magnetic resonance imaging in minor head injury. *Ann Emerg Med* 1991; 20: 1281-5.
 25. Stein SC, Ross SE. The value of computed tomographic scans in patients with low-risk head injuries. *Neurosurgery* 1990; 26: 638-40.
 26. Stein SC, Ross SE. Mild head injury: a plea for routine early CT scanning. *J Trauma* 1992; 33: 11-3.
 27. Harad FT, Kerstein MD. Inadequacy of bedside clinical indicators in identifying significant intracranial injury in trauma patients. *J Trauma* 1992; 32: 359-61.
 28. Jeret JS, Mandell M, Anziska B. Clinical predictors of abnormality disclosed by computed tomography after mild head trauma. *Neurosurgery* 1993; 32: 9-15.