

ORIGINAL ARTICLE

Role of Ventriculoperitoneal Shunt for Haemorrhagic or Ischemic Strokes Causing Hydrocephalus

MUHAMMAD JUNAID MUSHTAQ, MUHAMMAD ANWAR, DR. ATTIQ-UR-REHMAN

*Dr. Ibrahim Khalid**Departments of Neurosurgery, CMH Lahore, CMH Multan, Farooq Hospital, Lahore
Bolan Medical College, Quetta*

ABSTRACT:

Posterior fossa hemorrhagic involve or infract associated hydrocephalus are serious neurosurgical emergencies which requires immediate and prompt action.

Purpose: To highlight the role of VP shunt in the management plan of Hydrocephalus caused by spontaneous hemorrhagic or ischemic infarcts.

Material and Methods: This is retrospective study of 16 cases over a period of 4 years from March 2007 to March 2011 conducted simultaneously at Neurosurgical departments of CMH Lahore, CMH Multan and Farooq Hospital Lahore.

Results: A total of 16 cases were included in this study and all those patients underwent some sort of CSF diversion procedure for obstructive hydrocephalus. Ten Patients (62.5%) were male and six (37.5%) patients were female. The age ranged from 32 – 70 years with mean age of 53.4 years. Clinically all patients presented with headache, vomiting and neck pain followed by loss of consciousness. Glasgow coma scale ranged from 5/15 to 12/15. The radiological findings were those of hemorrhagic or ischemic infarcts causing obstructive hydrocephalus. Patients were broadly divided into two main groups with eight patients in each group. **Group A** included 6 males and 2 females, all these patients were managed conservatively for the hemorrhagic or ischemic strokes while they underwent VP Shunt for the obstructive hydrocephalus. Two of these patients (a male and a female) had thalamic bleed (hemorrhagic stroke) with third ventricular blockade. These two patients were also managed by VP Shunt only. Outcome of patients in group A was excellent in 7 patients whereas one patients developed complications with prolonged hospital stay but ultimately recovered and discharged. **Group B** included 8 patients (4 male and 4 female) who underwent hematoma evacuation of cerebellar bleed along with placement of external ventricular drain (EVD). EVD was converted to VP Shunt in six patients when they deteriorated after blocking EVD on 5th post operative day. 2 patients out of these eight did not deteriorate on EVD blockade and VP Shunt was not passed in these patients and they had excellent recovery. One patient died in group B. One patient required redo surgery due to Shunt Blockade and had poor recovery whereas two more patients had poor recovery due to other reasons including poor neurological status pre operatively. Two patients had fairly good recovery after converting EVD into VP Shunt.

Conclusion: Obstructive hydrocephalus caused by hemorrhagic stroke or infarcts is a relatively rare entity requiring some sort of CSF diversion. Patients who are having smaller hematomas with hydrocephalus and GCS more than 8/15 can be managed with VP Shunt alone.

Keywords: Cerebellar hematoma, intracranial hematoma, ischemic infract, hydrocephalus, ventriculoperitoneal shunt.

Abbreviations: EVD: External ventricular drain. VP Shunt: Ventriculoperitoneal shunt, GCS: Glasgow coma scale, ICP: intracranial pressure.

INTRODUCTION

A spectrum of treatment modalities are available for the management of hemorrhagic or ischemic intracranial stroke. These lesions if located near the midline in the supratentorial compartment or in the posterior cranial fossa can cause obstructive hydrocephalus due to blocked of CSF flow through 3rd or 4th ventricles or in the Sylvian aqueduct.¹ These patients require some urgent surgical procedure as they may deteriorate very rapidly. The cause of spontaneous intracranial hematomas and infarcts in these locations include hypertension, vascular malformation, coagulopathies, tumours and thromboembolic phenomenon.² Due to the critical anatomical position such lesions even if small by the supratentorial standards can prove lethal due to potential of raised ICP in a very short time with possible tonsillar herniation. These patients often have co-morbid conditions requiring intensive management by multi speciality care in an intensive care unit with availability of a ventilator.³ These patients require a regular follow up for the functioning of VP Shunt as well as the management of their general medical conditions. Patients who do not undergo CSF diversion in the initial phase of treatment may develop chronic hydrocephalus for which they may need a VP Shunt at a later stage so a continuous follow up is mandatory.⁴

MATERIAL AND METHODS

This is a retrospective study of 16 cases over a period of 4 years from March 2007 to March 2011 conducted simultaneously at Neurosurgical Departments of CMH Lahore, CMH Multan and Farooq Hospital Lahore and Bolan Medical Quetta. Only those patients who had developed obstructive hydrocephalus after spontaneous intracerebral hematomas or ischemic infarcts were included in this study. The common feature among all these patients was the irregular / ineffective control of hypertension. There were only 2 patients who had large ischemic cerebellar infarcts along with perifocal edema leading to obstructive hydrocephalus. Patients were divided into two equal groups depending upon the treatment modalities they underwent.

Group A included eight patients who underwent VP shunt for obstructive hydrocephalus and conservative management of the hematoma or infarct.

Group B This Group also included eight patients who underwent surgical evacuation of the cerebellar hematoma along with immediate placement of external ventricular drain (EVD) for obstructive hydrocephalus. Six of these patients under went removal of EVD and

placement of ventriculoperitoneal shunt whereas in two patients EVD was removed and no VP shunt was passed.

All the patients were admitted to the hospitals through emergency or were shifted from the medical wards. Routine investigations were carried out to rule out other medical conditions. For definite diagnosis patients underwent CT scan brain plain, revealing the site and size of intracranial bleed or infarct as well as the presence of hydrocephalus. They all were managed in the intensive care units with close monitoring of their GCS and management for other medical conditions. Any patient who deteriorated underwent immediate CT Scan brain.

RESULTS

Sex Incidence

There were a total of 16 cases, 10 (62.5%) were male and 6 (37.5%) were females.

Table 1: Sex Incidence.

Sex	Number	Percentage
Male	10	62.5
Female	6	37.5
Total	16	100

Age Range

The age of the patients ranged from 32 – 70 years with mean age of 53.4 years.

Clinical Presentation

The common feature among all the 16 patients was their irregular and at times ineffective management for hypertension that they all suffered from, causing large variations in their blood pressure. They all presented with severe headache, neck pain accompanied by nausea and vomiting followed by loss of consciousness. Twelve patients were admitted through emergency departments whereas four patients were shifted from the medical wards. Diabetes mellitus was present in ten patients and out of these five were insulin dependent. Thirteen patients who were above 45 years were using some kind of anti-platelet therapy though infrequently.

Initial GCS at the time of hospitalizations ranged from 5/15 – 12/15. Four patients whose GCS was below 7/15 underwent tracheotomy.

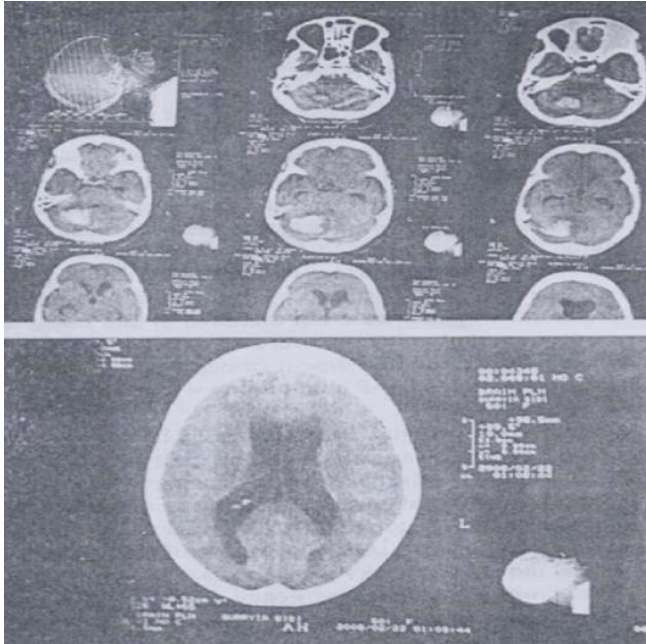


Fig. 1a-b: a: Preoperative CT Scan brain showing cerebellar haematoma with obstructive hydrocephalus.

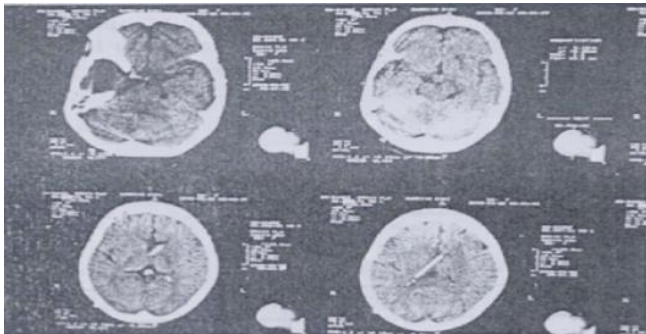


Fig. 2b: Postoperative CT Scan brain showing V.P. Shunt cerebellar clot had resolved.

They all were managed in the intensive care units where they had continuous monitoring of general and neurological signs along with daily laboratory investigations.

Investigations

Baseline investigations were carried out to assess their general well being as well as fitness for general anaesthesia. Two patients were anemic who were transfused blood before they underwent surgical procedure. The diabetic patients were put on sliding scale insulin. The main diagnostic investigation was plain CT scan brain, which was carried out to see the site and size of

the hemorrhagic or ischemic infarct. CT scan was repeated in those patients who did not improve or deteriorated after improving.

Surgical Procedures and Recovery

Patients were divided into two groups according to the surgical procedure.

Group A: There were eight patients in this group with 5 males in 3 females. All these patients had hydrocephalus for which VP shunt was passed. Their primary pathologies (spontaneous hemorrhagic or ischemic infarcts) were managed conservatively. Out of these eight patients four had cerebellar hematomas, 2 had large cerebellar infarcts whereas the other two patients had thalamic bleed. During VP shunt per-operatively one patient revealed blood stained CSF for which CSF was drained and ventricle was washed with saline through ventricular catheter. Once clear CSF flow was confirmed the catheter was attached with the chamber.

Out of these eight patients seven were discharged within two weeks with excellent recovery.

One patient had a fair outcome with prolonged hospitalization. She was 63 years old insulin dependent diabetic who was having ischemic heart disease as well. Her initial GCS was 5/15. She underwent tracheostomy under the same anaesthesia when VP shunt was passed. Post-operatively patient developed pneumonia. Patient recovered gradually and was discharged six weeks later after closing her tracheostomy. She still requires constant nursing care.

Group B: There were eight patients in group B who all underwent surgical evacuation of the cerebellar hematomas. In all these patients an external ventricular drain was placed for obstructive hydrocephalus. These patients were managed in intensive care units. Post-operatively on 5th day the EVD was blocked and patients were observed for any neurological deterioration. Two patients did not show any deterioration and their EVD were removed. They had good recovery and were discharged in the third week. Six patients deteriorated and developed obstructive hydrocephalus, VP shunt was passed in all these patients. Two patients out of these six made good recovery and were fairly independent for most of their daily chores. Two patients made fair recovery as they had persistent cerebellar signs and were wheelchair bound and required significant assistance. One patient had a poor outcome, he was 68 years old insulin dependent diabetic male with massive cerebellar bleed with initial GCS of 5/15. He

Table 2: *Clinical Presentation and Outcome of Patients in Group A.*

Case No	Age / Sex	Initial GCS	CT Scan Finding	Surgery	Complications	Out come
1.	32 / Male	12/15	Cerebellar Hematoma	VP Shunt		Excellent Discharged on 10 th Post op day.
2.	44 / Male	11/15	Cerebellar Hematoma	VP Shunt		Excellent Discharged on 11 th Post op day.
3.	50 / Male	10/15	Cerebellar Infarct	VP Shunt		Excellent Discharged on 13 th Post op day.
4.	52 / Male	8/15	Thalamic Bleed	VP Shunt	Hemiplegia	Fairly Good
5.	40 / Male	11/15	Cerebellar Hematoma	VP Shunt		Excellent
6.	63 / Female	5/15	Cerebellar Hematoma	VP Shunt + Tracheostomy	MI Pneumonia	Fair Discharged after Six weeks
7.	51 / Female	9/15	Thalamic Bleed	VP Shunt		Excellent
8.	50 / Male	12/15	Cerebellar Infarct	VP Shunt		Excellent

Table 3: *Clinical Presentation and Outcome of Patients in Group B.*

Case No	Age / Sex	Initial GCS	CT scan finding	Surgery	Complications	Out come
1.	55 / Male	12/15	Left Cerebellar Hematoma	Craniectomy + EVD		Excellent
2.	70 / Female	5/15	Massive Cerebellar Hematoma	Craniectomy + EVD VP Shunt Tracheostomy	Infection MOF	Dead
3.	61 / Male	5/15	Massive Cerebellar Hematoma	Craniectomy + EVD VP Shunt	Dysarthria Dysphasia Imbalance	Fair
4.	56 / Female	12/15	Cerebellar Hematoma	Craniectomy + EVD		Excellent
5.	48 / Female	11/15	Cerebellar Hematoma	Craniectomy + EVD VP Shunt		Good Recovery
6.	58 / Male	10/15	Cerebellar Hematoma	Craniectomy + EVD VP Shunt	Wheel Chair Bound	Fair
7.	55 / Male	10/15	Cerebellar Hematoma	Craniectomy + EVD VP Shunt		Good
8.	68 / Male	5/15	Massive Cerebellar Bleed	Craniectomy + EVD VP Shunt + Tracheostomy	Blocked VP Shunt Re-Operated	Poor Recovery

underwent tracheostomy during same anesthesia. Post-operatively his condition improved and his GCS became 11/15 and EVD was converted to VP shunt on 7th post operative day. His GCS dropped to 7/15 six days later, clinical examination and CT scan revealed blo-

cked VP shunt. Ventricular catheter was readjusted and washed. His GCS improved to 12/15. His tracheostomy was not removed due to debilitated general condition and repeated chest infections. He remained bed ridden and his outcome was considered poor.

We lost one patient who was 70 years old diabetic lady with chronic obstruction airway disease (COAD) and uncontrolled hypertension. She underwent evacuation of hematoma, EVD and tracheostomy as her GCS was 6/15. Her GCS improved initially to 8/15 and VP shunt was passed on 8th post operative day. Her condition deteriorated and she developed respiratory embarrassment for which she was intubated and put on ventilatory support. She started having high grade fever which did not respond to any treatment and the patient went into multi organ failure and died of the complications.

DISCUSSION

The treatment of spontaneous cerebellar hemorrhage is still discussed controversially.⁴ These hematomas and infarctions in the cerebellum carry a high morbidity and mortality, if accompanied by hydrocephalus the gravity of the condition is further compounded. As these patients usually have hypertension which is often complicated by other medical conditions i.e., diabetes mellitus, the management is multi disciplinary. These patients have to be managed in an intensive care unit with facility of ventilator. The most important factors in determining the outcome of the patients can be summarized as the age and general physical condition of the patient, the initial neurological condition and GCS along with presence or absence of hydrocephalus. The hematoma size solely, as thought previously, is not the predictive for clinical outcome.⁵

Patients with good clinical status having moderate sized cerebellar infarct along with hydrocephalus underwent VP shunt procedure with significantly good results. Such line of management has been reported in other international studies as well.^{3,7} Cerebellar hematomas have been divided into three main groups according to a tomographic classification. Group 1 includes patient having 4th ventricle not shifted and normal looking. Group 2 includes patients with 4th ventricle shifted or obliterated. Group 3 patients have intraventricular blood. Each group is further sub-divided into A (No hydrocephalus) and B (hydrocephalus), (Dammann P et al 1984).¹ According to these studies the position of the 4th ventricle is important in the final outcome of the patients.

Similarly other neurosurgeons have emphasized the significance of Quadrigeminal cistern on CT scan where a compressed cistern invariably signifies a grave outcome. Similarly deformity or obliteration / compression of the prepontine and ambient cisterns on CT

scan can be assessed which can predict the outcome of the patient.⁸ Patients with large hematomas along with hydrocephalus undergo evacuation of the hematoma and placement of temporary external ventricular drain under good antibiotic cover.

In our experience the EVD should be either removed or converted to a proper VP shunt by the end of 1st week and this protocol is sported by international studies as well.^{5,7}

Role of minimal access surgery i.e., Keyhole evacuation of cerebellar hematoma is yet to be established and is still not popular at most of the neurosurgical centers. Recently there have been studies about endoscopic placement of EVD after removal of cerebellar hematoma (endoscopically) with significantly short operative time and lesser morbidity.⁶ According to one study, endoscopic EVD placement did not require VP shunt later on.⁹

Ishikawa T et al had published his experience of spontaneous cerebellar hematomas with hydrocephalus where he treated two patients with VP shunt alone and the hematoma resolved with time.^{8,9}

Neurologically intact patients with small hematomas are treated conservatively and surgery is reserved only for secondary deterioration or hydrocephalus.

CONCLUSION

From the results of this study we can conclude that the acute obstructive hydrocephalus complicating the spontaneous hemorrhagic or ischemic infarcts can be successfully managed by VP shunt of initially alone EVD which can be converted to VP shunt at a later stage in case of prolonged hydrocephalus. The evacuation of the cerebellar hematoma itself depends upon the volume of the hematoma, in our study hematomas larger than 40 ml were evacuated.

Address for correspondence:

Lt. Col. Muhammad Junaid Mushtaq

Consultant Neurosurgeon CMH, Multan

E-mail: junaidmushtaq@email.com

Cell: 0321-4311224

REFERENCES

1. Dammann P, Asgari S, Bassiouni H, Gasser T, Panagiotopoulos V, Gizewski ER, Stolke D, Sure U, Sandalcioğlu IE, Spontaneous Cerebellar hemorrhage experience with 57 surgically treated patients and review of

- the literature. *Neurosurg Rev* 2011 Jan, 34 (1) 77-86 Epub 2010 Aug.
2. Perez – Nunez A, Alday R, Rivas JJ, Lagares A, Gomez PA, Alen JF, Arresse I, Lobato RD, Surgical Treatment of spontaneous intracerebral hemorrhage – Part II infratentorial Hematomas. *Neurocirugia (Astur)* 2008.
 3. Kirillos RW, Tyag AK, Ross SA, van Hille PT, Mark PV. Management of spontaneous Cerebellar hematomas. A prospective treatment protocol. *Neurosurgery* 2001 Dec. 49 (6): 1368-78 discussion 1368.
 4. Czernicki T, Marchel A. Result of treatment of non traumatic cerebellar hemorrhages. *Neurol Neurochir Pol.* 2002 Jul – Aug, 36 (4): 683-96.
 5. Van Loon J, Van Calenbergh F, Goffin J, Plets C. Controversies in the management of spontaneous cerebellar hemorrhage. A consecutive series of 49 case and review of literature. *Acta Neurochir (Wien)* 1993; 122(3-4): 187-93.
 6. Tokimura H, Tajitsu K, Taniguchi A, Yamaha H, Tsuchiya M, Takayama K, Shinsato T, Arita K. Efficacy and safety of key hole craniotomy for the evacuation of spontaneous cerebellar hemorrhage. *Neurol Med Chir (Tokyo)* 2010; 50 (5): 367-72.
 7. Mathew P, Teasdale G, Bannan A, Oluoch- Olunva D. Neuro surgical management of cerebellar hematoma and infract. *Acta Neurochir (Wien)* 1994; 131 (1 – 2): 59-66.
 8. Yanaka K, Meguro K, Fujita K, Narushima K, Nose T. Prospective brainstem high intensity is correlated with poor outcome for patients with spontaneous cerebellar hemorrhage. *Neurosurgery* 1999 Dec; 45 (6): 1323-7 discussion 1327-8.
 9. Yamamoto T, Nakao Y, Mori K, Maeda M. Endoscopic hematoma evacuation for hypertensive cerebellar hemorrhage. *Minim Invasive Neurosurg* 2006 June; 49 (3): 173-8.