

ORIGINAL ARTICLE

## Combined Approach for Excision of Advanced Angiofibroma : A Study of 12 Cases

FAZAL-I-WAHID, HABIB-UR-REHMAN, MUMTAZ ALI

*Isteraj Khan Shahabi**Department of ENT, Post Graduate Medical Institute / Lady Reading Hospital, Peshawar*

### ABSTRACT

**Objective:** To determine effectiveness of combined skull base approach for excision of advanced angiofibroma.

**Materials and Methods:** This study was conducted at the Department of Ear, Nose, Throat, Head and Neck Surgery and Neurosurgery, Post Graduate Medical Institute Lady Reading Hospital Peshawar. This was retrospective observational study. The duration of the study was 5 years from Jan., 2003 to Dec., 2008. This study included 12 cases with advanced (stage IIIA and IVB) of Nasopharyngeal angiofibroma. These cases were assessed in terms of detailed history, through examination and radiological investigations to stage according to the Fisch classification. The tumour was completely excised by combined approach of a team of Neurosurgeons and ENT surgeons. No recurrence found in 30 months post-op observation.

**Results:** This study included 12 cases. All were male. Age of the patients was in range of 14 to 19 years with mean of 16.5 years. They belonged to lower and middle class of society. They presented with history of unilateral nasal obstruction (100%) while MRI where needed. The disease was involving nose, nasopharynx, sinuses and had Extracranial and intracranial extension. Nine cases (75%) were in stage IIIB and 3 cases (25%) in stage IVA according Fisch classification. The procedure time was average 7.5 hours and average 700 ml blood was transfused. Platal fistula formed in one case (8.3%) and no recurrence found on 18 months follow up.

**Conclusion:** The cooperation of neurosurgeons and otorhinolaryngological doctors provides a good way to minimize invasiveness in skull base surgery. Sufficient preoperative preparation, well equipped theatre and surgical expertise are necessary for complete resection of benign tumor like angiofibroma.

**Key Words:** Angiofibroma, combined skull base approach, advanced angiofibroma.

### INTRODUCTION

Recognized since ancient times by Hippocrates, juvenile angiofibroma is an uncommon, benign and extremely vascular tumour predominantly occurring in male adolescent. The term "angiofibroma" was first used by Friedberg in 1940.<sup>1-3</sup> It is responsible for less than 0.05% of all head and neck tumors. The tumor usually originates from the superior border of the sphenopalatine foramen, which is formed by the junction of the trifurcation of palatine bone, horizontal wing of vomer, and the roof of pterygoid plates but rarely it can arise from nasal septum, middle turbinate, hard palate, and alveolar ridge.<sup>2,3</sup> The origin of the

tumor is of the greatest importance because it elucidates its pattern of distribution.<sup>3,4</sup> The exact etiology of this tumour is unknown and various theories has been presented. A hormonal theory has been suggested because of the lesion's occurrence in adolescent males. Other theories include a desmoplastic response of the nasopharyngeal periosteum or the embryonic fibrocartilage between the basiocciput and the basisphenoid. Etiology from nonchromaffin paraganglionic cells of the terminal branches of the maxillary artery has also been suggested. Comparative genomic hybridization analysis of these tumors revealed deletions of chromosome 17, including regions for the tumor

suppressor gene *p53* as the *Her-2/neu* oncogene.<sup>4,5</sup> Despite its histologically benign features, approximately 20 to 30% of the cases will present with intracranial extension,<sup>3-5</sup>

Typically, patients present with unilateral nasal obstruction and recurrent epistaxis. As the disease progresses facial deformities, proptosis, blindness and cranial nerve palsies may occur. The diagnosis of juvenile nasopharyngeal angiofibroma is essentially based on a careful history, and nasal endoscopic examination, supplemented by imaging studies using CT and MRI. Magnetic Resonance Imaging studies using CT and MRI. Magnetic Resonance Imaging studies are probably more accurate than CT in assessing intracranial extension and definitive diagnosis is established by angiography which also serves as therapeutic modality for embolization of feeding vessels of tumour.<sup>5,7,9</sup> Over time, angiofibroma will eventually erode bone and invade the infratemporal fossa, orbit, and middle cranial fossa. The blood supply to these benign tumors is most commonly from the internal maxillary artery, but may also be supplied by the external carotid artery, the internal carotid artery, the common carotid artery, or the ascending pharyngeal artery. Histologically, angiofibroma originates from myofibroblasts. The tumor lacks a capsule and spreads submucosally and also bleeds profusely. It is composed of a fibrous abundance of single endothelial cell lined vascular channels. These channels are surrounded by a collagenous tissue network and lack a complete muscular layer.<sup>6-8</sup>

The preferred way of treating the angiofibroma is surgical, though radiotherapy and chemotherapy is been tried for extremely unrespectable tumour, but this also needs surgical treatment later on. Many surgical approaches are described in literature but, it all depends upon the extent of tumour and the surgeon's experience.<sup>7-9</sup> There are many classification described in literature although none is universally accepted.<sup>4,9,10</sup> We adopted Fisch classification in this study.

## MATERIAL AND METHOD

This retrospective, observational study was conducted at the department of Ear, Nose, Throat, Head, Neck Surgery and Neurosurgery Postgraduate Medical Institute Lady Reading Hospital Peshawar from Jan. 2003 to Dec. 2008 with a total duration five years. All the patients were male and belonged to lower and middle class of society. The diagnostic criteria were detailed history, thorough examination and radiological investi-

gations. CT scans were performed in all cases and MRI where it needed. The patients were staged according to fish classification and 9 patients were in stage IIIB while three patients were in stage IVA. As these patients were in advanced stage of the diseases so they were discussed with neurosurgical colleagues and a combined approach for excision of angiofibroma was planned. A well informed consent was taken from patient explaining the procedure, its risks, benefits and associated complications. Tran basal Sub-Frontal craniotomy with Trans palatal approach was adopted in six, Trans basal Sub-Frontal craniotomy with lateral rhinotomy in three cases while Trans-basal Frontolateral craniotomy with midfacial degloving approach was used in three cases. The intracranial tumour was completely excised by neurosurgeons with help of microscopic use. The Extracranial portion of tumour was excised by ENT surgeon after intracranial surgery was completed by neurosurgeons in same setting. These patients were recovered uneventfully and about 700 – 1000 ml blood were transfused per and post operatively depending upon the situation. There was no intra operative complication but palatal fistula was formed in one case as both palatine arteries were damaged during surgery. The patient were kept in three monthly follow up scheme having CT scans and they were observed for minimum of 18 months. They are disease free so far.

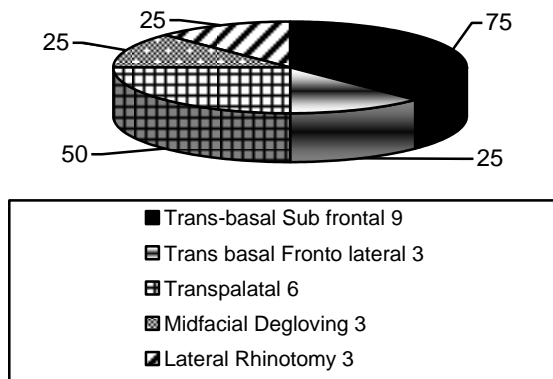
## RESULTS

This study included 12 male patients in the age range of 14 – 19 years, mean age 16.5 years. They belonged to the lower and middle class of society. These patients presented mainly with complaints of nasal obstruction, recurrent epistaxis and cheek swelling (Table 1). CT scans were performed in all 12 cases (100%) while MRI in 5 cases (41%). These patients presented with advanced tumour on radiological

**Table 1:** *Clinical Features (N = 12).*

S. No.	Clinical Features	No. of Cases	Percentage
1.	Nasal obstruction	12	100%
2.	Epistaxis	11	91.6%
3.	Cheek swelling	07	58.3%
4.	Proptosis	01	8.3%
5.	Headache	05	41.6%

findings (Table 2). The tumour was staged according to Fisch classification, 9 cases (75%) were in stage IIIB and 3 cases (25%) in stage IVA. Among these 10 cases (83%) had primary tumour while 2 cases (16.6%) had previous surgery for angiofibroma in other Teaching Hospitals of the country but not cured. These patients were treated by combined approach by Neurosurgeons and Otorhinolaryngologists (Graph 1). Blood was transfused in 12 cases (100%)



Graph 1: Surgical Procedures Adopted in this Study.

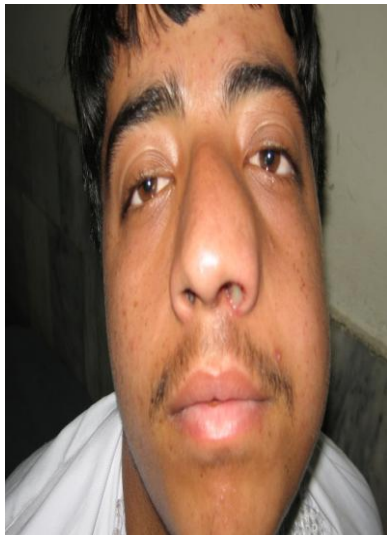

Fig. 1: Patient with Swelling of Nose, Mild Proptosis Left Eye, Fullness of Left Cheek and Mass in Nose with Slough Over Mass in Left Nostril.

preoperatively while in 8 cases (66.6%) postoperatively with average amount of 700 ml in each case. Palatal fistula was formed in one case but no recurrence found postoperatively in these cases.

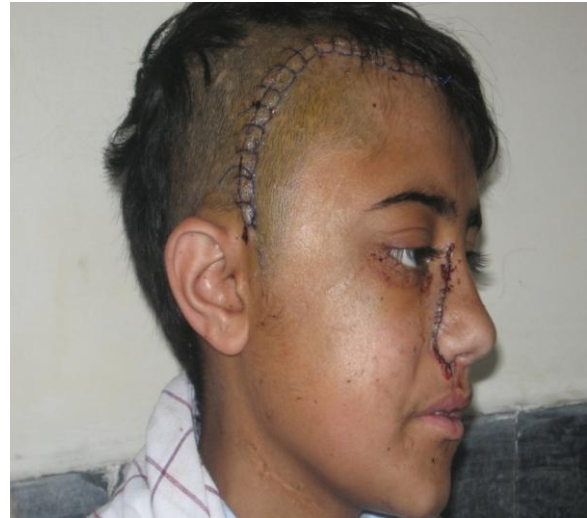

Fig. 2: Patient with Scars of Frontolateral Craniotomy and Lateral Rhinotomy.

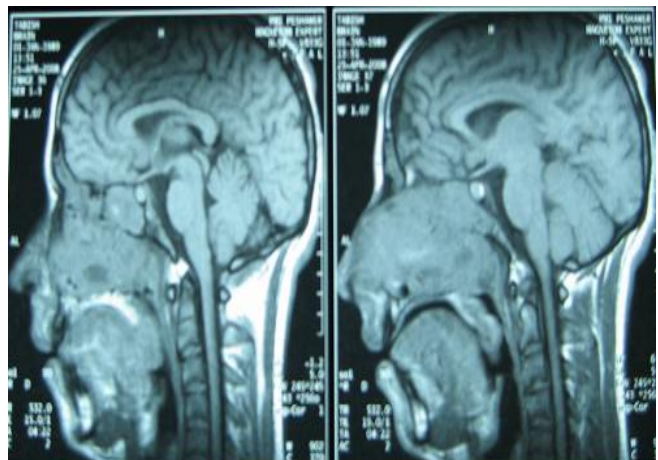
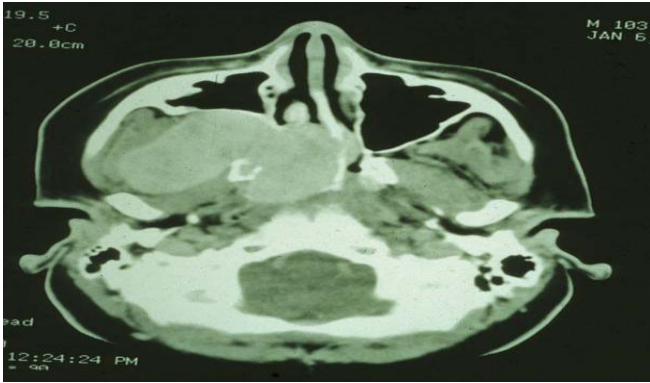


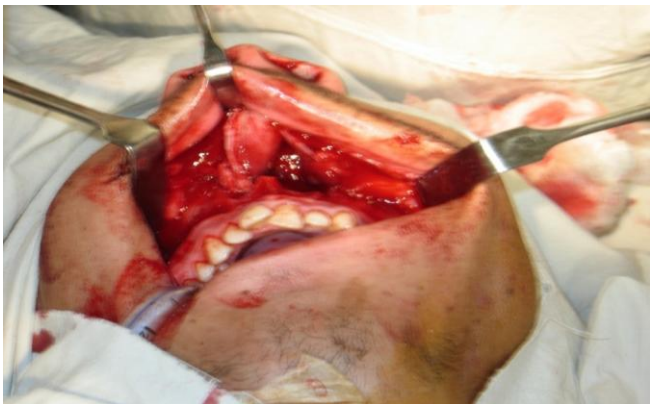Fig. 3: MRI Nose, Nasopharynx, Par Nasal Sinuses and Brain Saggital View showing Isointense Mass Involving Nose, Nasopharynx with Extension into Skull Base.

Table 2: Radiological Findings (N = 12).

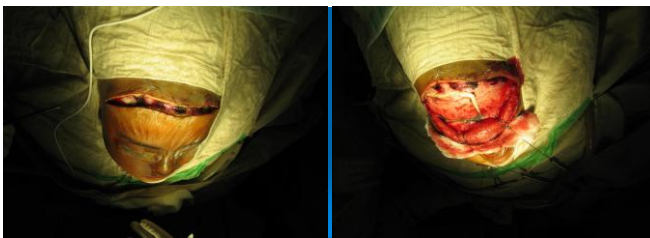
S. No.	Sites Involvement by Tumour	No. of Cases	Percentage
1.	Nose, Nasopharynx, Sinuses	12	100%
2.	Pterygopalatine fossa, Cheek, Infratemporal fossa, Orbit	09	75%
3.	Middle Cranial Fossa	10	83.33%
4.	Anterior Crania Fossa	02	16.66%



**Fig. 4:** CT Scan of Nose, Nasopharynx, Para Nasal Sinuses and Skull Base Axial View with Contrast showing ISO Dense Mass Involving Right Nasal Cavity, Nasopharynx, Pterygopalatine Fossa and Infratemporal Fossa.



**Fig. 5:** Picture showing Incision of Midfacial Degloving Approach as Myocutaneous Flap of Face is Elevated.



**Fig. 6:** Picture showing Incision of Frontal Craniotomy, Scalp Flap is Elevated and Cranium is Exposed.

## DISCUSSION

Angiofibroma is the most frequent benign tumour of nasopharynx in young males. The mean age at presentation is 14 years given by Harison. The entire patients in our series were males and the mean age at

presentation was 16.5 years which is at part with most published studies. The trial of nasal obstruction recurrent epistaxis and mass nasopharynx in an adolescent male should be investigated seriously because it might be angiofibroma which requires early treatment. In our study every patient presented with nasal obstruction, recurrent epistaxis and cheek swelling which is in accordance with other studies.<sup>9-12</sup> Treatment options for angiofibroma include surgery, radiation therapy, chemotherapy, and hormonal therapy. Surgery is the gold standard of treatment. External beam radiation is generally reserved for larger and / or unresectable tumors and tumors that are life threatening due to their location. The reason for limited use of radiation as a treatment modality is due to the potential carcinogenic side effects of radiation. Local control rates and recurrence rates are comparable to surgical results, however severe complications are encountered including growth retardation, temporal lobe radionecrosis, panhypopituitarism, cataracts, and radiation induced keratopathy.<sup>10-14</sup> In the recent years much interest has been focused on transnasal endoscopic techniques for resection. Endoscopic surgeries permit a minimally invasive resection of the tumor with minimal blood loss and complications. The endoscopic approach is mostly used for early stage tumor, although some centers with extensive experience in endoscopic techniques have used them in selected cases of Stage III disease. The primary disadvantage of an endoscopic approach is restricted access and difficulty of converting to an alternative approach if there is excessive bleeding.<sup>5,11,13</sup> Our patients were in advanced stages of the disease and endoscopic facility was also not available in our province so we adopted open surgical procedures.

The surgical approach should be determined by tumor location, tumor size, and effectiveness of tumor embolization.<sup>11,12,14</sup> Skull base surgery for angiofibroma extending intracranially was first reported in 1972 by English et al, followed by Krekorian and Kato and then Close et al, who recommended intracranial excision instead of radiation therapy. Bales et al, described surgical removal of Stage IIIB tumors (with intracranial extension) via an infratemporal fossa approach, zygomatic osteotomy, subtemporal craniectomy, and a facial translocation approach. Donald et al, reported the surgical results of 5 patients with angiofibroma extending intracranially for whom they used the middle fossa approach, the anterior craniofacial approach, and the subcranial approach. Complete tumor removal was achieved in all the cases.<sup>12,15,16</sup>

Traditional approaches for angiofibroma include transoral, transfacial, and combined craniofacial approaches more specifically transpalatal, transantral, transnasal, lateral rhinotomy, midfacial degloving, LeFort I osteotomy and infratemporal fossa approaches.<sup>17-19</sup> Qualities shared by these approaches include oral and / or facial incisions and the need to remove or divide bone to gain access to the tumor.<sup>13,20,21</sup> The combined approach adopted in our study has results in terms of complete excision of tumours are comparable with other national and international studies.<sup>14,15,22</sup> Tyagi and colleagues conducted similar study and they concluded that Infratemporal, pterygopalatine, orbital and intracranial extensions of angiofibroma (Stage IIIa and IIIb) can be removed by combined transpalatal and transmaxillary approach by Lazy S incision without producing any facial asymmetry.<sup>22,23</sup> Conservative lateral infratemporal approach is required in very large lateral extensions or where angiofibroma is extending intracranially.<sup>20,23,24</sup> Staged fronto-temporal craniotomy should be done in Stage Iva tumors. In Stage IVb tumors (invading cavernous sinus), usually residual tumor remains which should be followed subsequently.<sup>15,23,25</sup>

We observed no recurrence in our study although the no of cases was limited but tumour was meticulously excised which is also reported by Howard and Colleagues that meticulous removal of angiofibroma infiltrating the pterygoid canal and basisphenoid is paramount to avoid "recurrence."<sup>17,19</sup> The operative time in our study was average of 7.5 hours and average blood loss was about 700 ml which are comparable to other international studies.<sup>18,21,26</sup>

## CONCLUSION

Our experience showed that surgery for angiofibroma at advances stage is difficult. The cooperation of neurosurgeons and otorhinolaryngologists provides a good way so minimize invasiveness in skull base surgery. Sufficient preoperative preparation, well – equipped theatre and expertise are necessary. The tumor can be completely excised with intention of cure being patients are properly evaluated and proper approach is selected.

*Address for Correspondence:  
Dr. Fazal-I-Wahid*

*Department of ENT, Post Graduate Medical  
Institute / Lady Reading Hospital, Peshawar*

*Contact No. 091-9211430 (Ext. 3065)*

*Mobile: 0343-9083224*

*E-Mail: drfazal58@yahoo.com*

## REFERENCES

1. Twefik TL, Tan AKW, Chowdhury K and Ramond J. Juvenile Nasopharyngeal Angiofibroma. The Journal of Otolaryngology, 1999; 28: 30-8.
2. Windfuhr JP, Remmert S. Extranasopharyngeal angiofibroma : etiology, incidence and management. Acta Oto-laryngologica, 2004; 124: 880-9.
3. Sivanandan R, Fee JR WE. Benign and malignant tumors of the nasopharynx. In : Cummings CW, Flint PW, Harker LA, et al, editors. Cummings otolaryngology head and neck surgery. 4<sup>th</sup> ed. New York : Elsevier, Mosby; 2005: P. 1559-972.
4. Batsakis JG. Vasoformative tumors. In : Batsakis JG, editor. Tumors of the head and neck clinical and pathological considerations. 2<sup>nd</sup> ed. Baltimore : Williams and Wilkins, London Publ; 1999: P. 773-7.
5. Mistry RC, Qureshi SS, Gupta S, Gupta S. Juvenile nasopharyngeal angiofibroma : A single institution study. Indian J Cancer 2005; 42: 35-9.
6. Breme JW, Neel HB III, De Santo LW, et al. Angiofibroma : Treatment trends in 150 patients during 40 years. Laryngoscope 1986; 96: 1321-1329.
7. Pradhan B and Thapa N. Juvenile angiofibroma and its management. Nepal Med Coll J 2009; 11 (3): 186-188.
8. Ahmed Z, Mutiullah S, Rahim D and Marfani MS. Juvenile Nasopharyngeal Angiofibroma : Stage and Surgical Approach. JLUMHS 2009; 8: 37-40.
9. Gohar MS, Rashid D and Ahmed B. Common presenting symptoms diagnosis and management of angiofibroma – A study of twenty cases. Pak J Med Sci 2004; 20: 377-80.
10. Enepekides DJ. Recent advances in the treatment of juvenile angiofibroma. Curr Opin Otolaryngol Head Neck Surg. 2004; 12: 495-499.
11. Scholtz AW, Appenroth E, Jolly KK, Scholtz LU, Thumfart WF. Juvenile Nasopharyngeal Angiofibroma : Management and Therapy. The Laryngoscope 2001; 11: 681-7.
12. Margalit N, Wasserzug O, Row AD, Abergel A, Fliss DM and Gil Z. Surgical treatment of juvenile nasopharyngeal angiofibroma with intracranial extension. Journal of Neurosurgery Pediatrics 2009; 4: 113-17.
13. Mann WJ, Jecker P, Amedee RG. Juvenile angiofibromas : changing surgical concept over the last 20 years. Laryngoscope, 2004; 114: 291-293.
14. FU Ji-di, LIU Hao-cheng, ZHAO Shang-feng, ZHANG Jia-liang, LI Yong, NI Xin, YU Chun-jiang. Craniotomy with endoscopic assistance in the treatment of nasopharyngeal fibroangioma. Chinese Medical Journal 2010; 123: 1289-94.

15. Umar AE, Ragab A and Sharnoby MM. Surgical resection of type III juvenile angiofibroma without preoperative embolization. *International Journal of Pediatric Otorhinolaryngology* 2006; 70: 1715-1723.
16. Tyagi I, Syal R, Goyal A. Staging and surgical approaches in large juvenile angiofibroma Study of 95 cases. *International Journal of Pediatric Otorhinolaryngology* 2006; 70: 1619-27.
17. Howard DJ, Lioyd G, Lund V. Recurrence and its avoidance in Juvenile Angiofibroma. *Laryngoscope*, 2001; 111: 1509-11.
18. Wang YF, Lin CZ. Nasopharyngeal Angiofibroma. *Chinese Medical Journal (Taipei)* 2001; 64: 39-46.
19. Cristina B, Mark K, Laurie A. L, Mouwafak A R, Gregory W, Robert H et al. Craniofacial Resection of Advanced Juvenile Nasopharyngeal Angiofibroma. *Arch Otolaryngol Head Neck Surg.* 2002; 128: 1071-1078.
20. Alamgir MA, Malakar M, Rabbani SMG, Yasmeen N, Islam S. Extensive nasopharyngeal angiofibroma – case report. *Bangladesh J Otorhinolaryngol* 2009; 15 (2): 75-77.
21. Ardehali MM, Ardestani SHS, Yazdani N, Goodarzi H, Shahin B. Endoscopic approach for excision of juvenile nasopharyngeal angiofibroma : complications and outcomes. *American Journal of Otolaryngology – Head and Neck Medicine and Surgery* 2009; 2: 1-7.
22. Angelito JU, Hardillo, Velden IV and Knecht PP. Denker operation is an effective surgical approach in managing juvenile nasopharyngeal angiofibroma. *Ann Otol Rhinol Laryngol* 2004; 113: 946-950.
23. Naraghi M, Kashfi A. Endoscopic resection of nasopharyngeal angiofibromas by combined transnasal and transoral. *Am J Otolaryngol*, 2003; 24: 149-54.
24. Koshy S, George M, Gupta A, Daniel RT. Extended osteoplastic maxillotomy for total excision of giant multicompartmental juvenile nasopharyngeal angiofibroma. *Indian J Dent Res* 2008; 19: 366-9.
25. Midilli R, Karci B, Akyildiz. Juvenile nasopharyngeal angiofibroma : Analysis of 42 cases and important aspects of endoscopic approach, 2009; 73: 401-8.
26. Mona Thornton, Bangalore N. Mahesh, John Lang. *Journal of Laparoendoscopic and Advanced Surgical Techniques* 2005; 15: 194-196.