

ORIGINAL ARTICLE

## Efficacy of Endoscopic Third Ventriculostomy for Obstructive Hydrocephalus

FAHEEM USMANI, ZUBAIR AHMED, AMIR AZIZ

*Khurram Ishaque, Tariq Salah-ud-Din**Department of Neurosurgery, Postgraduate Medical Institute, Lahore General Hospital, Lahore*

### ABSTRACT

**Objective:** To assess efficacy of Endoscopic Third Ventriculostomy for Obstructive Hydrocephalus.

**Study Design:** Cross – sectional observational study.

**Materials and Methods:** This study was conducted from July 2012 to June 2014 at the department of Neurosurgery, PGMI, Lahore General Hospital, Lahore. Patients with obstructive hydrocephalus due to aqueductal stenosis, tectal and non-tectal tumor and already shunted patients for obstructive hydrocephalus presented with blocked shunt were included in the study. The exclusion criteria consisted of patient's age < 6 months, previous history of ETV, recurrent tumor, patients with congenital hydrocephalus and secondary to meningitis or intra ventricular hemorrhage. Endoscopic third Ventriculostomy was performed in all patients. Success, complications and mortality was noted. Data was analyzed by descriptive statistics using SPSS software version 17.

**Results:** Out of 60 patients, 34 (56.6%) were males and 26 (43.4%) were females, ranging in age from 1 – 45 years. The maximum numbers of patients were in their two decade of life. ETV had successful outcome in 46 (76.7%) patients. Complications were observed in 14 (23.3%) cases including inadequate Ventriculostomy (8.33%), CSF leak (1.7%), ventricular bleed (1.7%), meningitis (1.7%) and seizures (6.67%). Two patients (3.33%) died in our study on follow up.

**Conclusion:** Endoscopic Third Ventriculostomy is a very effective procedure for the treatment of obstructive hydrocephalus.

**Keywords:** Endoscopic Third Ventriculostomy, non-communicating hydrocephalus, effectiveness.

**Abbreviations:** ETV: Endoscopic Third Ventriculostomy. CSF: Cerebrospinal Fluid. OHC: Obstructive Hydrocephalus.

### INTRODUCTION

Hydrocephalus can be defined broadly as a disturbance of cerebrospinal fluid (CSF) formation, flow, or absorption, leading to an increase in volume occupied by this fluid in the central nervous system (CNS).<sup>1</sup> Incidence of human hydrocephalus is 1 – 1.5%. It occurs in infancy due to the various forms of congenital malformations. And in adulthood, mostly resulting from normal pressure hydrocephalus. Adult hydrocephalus represents approximately 40% of total cases of hydrocephalus.<sup>2</sup>

Hydrocephalus can be classified as purely obstructive, purely communicating or due to combinations of pathologies (obstruction in addition to defective absorption). Both forms can be either congenital or acquired. Communicating hydrocephalus, also known as non-obstructive hydrocephalus, is caused by impaired cerebrospinal fluid resorption in the absence of any CSF – flow obstruction between the ventricles and subarachnoid space.<sup>3</sup> Non-communicating hydrocephalus, or obstructive hydrocephalus, is caused by a CSF – flow obstruction ultimately preventing CSF

from flowing into the subarachnoid space (either due to external compression or intraventricular mass lesions e.g. Tuberculosis, Trauma etc).<sup>4</sup>

Hydrocephalus treatment is surgical, generally utilizing various types of cerebral shunts. Extra cranial approach involves the placement of a ventricular catheter (a tube made of silastic), into the cerebral ventricles to bypass the flow obstruction/ malfunctioning arachnoidal granulations and drain the excess fluid into other body cavities, from where it can be resorbed.<sup>5</sup> Complications associated with it are blockage, over drainage and infection. Endoscopic Third Ventriculostomy (ETV), intracranial approach in which a perforation is made to connect the third ventricle to the subarachnoid space, has been used in the initial treatment of selected cases of obstructive hydrocephalus and as an alternative to shunt placement.<sup>6</sup> Complications like fever and hemorrhage are rare.

A local study reported overall effectiveness of endoscopic Third Ventriculostomy for obstructive hydrocephalus was 78.4%<sup>7</sup> while efficacy of endoscopic Third Ventriculostomy in another study was 70%.<sup>8</sup> The efficacy measured in terms of improvement in Glasgow Coma Scale by at least two points measured preoperatively and at 72 hours after Ventriculostomy. Two more studies reported the efficacy of ETV 68%<sup>9</sup> and 87.1%.<sup>10</sup>

**MATERIALS AND METHODS**

This study was conducted from July 2012 to June 2014 at the department of Neurosurgery, PGMI, Lahore General Hospital, Lahore. Patients with obstructive hydrocephalus secondary to posterior fossa lesion, brain stem glioma, CP angle tumor, pineal tumor, aqueductal stenosis and patients with blocked shunt previously treated for obstructive hydrocephalus were included. The exclusion criteria consisted of patient’s age < 6 months, previous history of ETV, recurrent tumor, patients with congenital hydrocephalus and secondary to meningitis or intra ventricular hemorrhage. CT and/or MRI brain was done in all the cases to confirm hydrocephalus and its cause. Endoscopic Third Ventriculostomy was performed in all patients. Success, complications and mortality was noted. ETV was considered successful in clinically improved patient with and without radiological improvement. Data was collected on proforma and analyzed by SPSS software version 17.

**RESULTS**

**Sex Incidence**

Out of 60 patients, 34 (56.6%) were males and 26 (43.4%) were females.

**Age Incidence**

Ranging in age from 1 – 45 years. The maximum numbers of patients were in their two decade of life.

**Etiology**

The most common cause of obstructive hydrocephalus is posterior fossa tumors and aqueductal stenosis as shown in figure below.

**Outcome**

ETV had successful outcome in 46 (76.7%) patients.

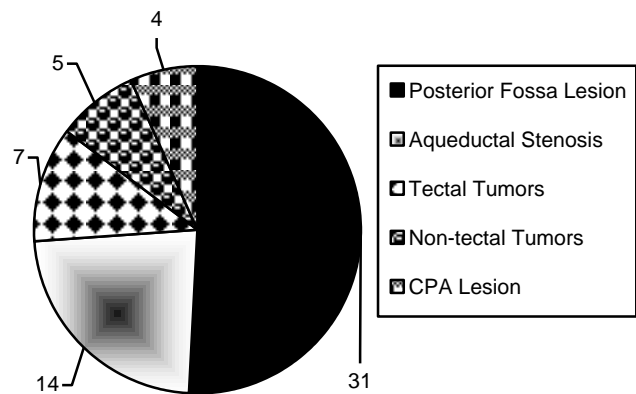


Fig. 1: Causes of Obstructive Hydrocephalus.

**Complications**

Complications were observed in 14 (23.3%) cases including inadequate Ventriculostomy (8.33%), seizures (6.67%), CSF leak (5%), ventricular bleed

Complications of endoscopic third Ventriculostomy		
Complication	Number	Percentage
Inadequate Ventriculostomy	05	(8.33%)
Seizure	04	(6.67%)
CSF leak	03	(5%)
Ventricular bleed	01	(1.7%)
Meningitis	01	(1.7%)
Total	14	(23.3%)

(1.7%) and meningitis (1.7%) as shown in table below. Two patients (3.33%) died in our study on follow up.

## DISCUSSIONS

The management of hydrocephalus needs diversion, either extra-cranial (shunts) or intracranial (third Ventriculostomy).<sup>11</sup> Extra-cranial shunts are subject to complications such as infection, blockage and over drainage, often necessitating repeated surgical revisions of shunt.<sup>12</sup> Endoscopic Third Ventriculostomy obviates all these complications and has been accepted as the procedure of choice for the treatment of obstructive hydrocephalus (OHC) in children and adults.<sup>13</sup> The Ventriculostomy has been performed by Torkildsen,<sup>14</sup> microsurgical,<sup>15</sup> stereotactic<sup>16</sup> or by fluoroscopic methods.<sup>17</sup> Endoscopic third Ventriculostomy is recently added in the armamentarium of hydrocephalus treatment. The ETV bypasses an aqueduct stenosis or fourth ventricular outlet by perforating the third ventricular floor to deviate the CSF flow into the inter-peduncular and pre-pontine cisterns. Apart from ETV, neuro endoscopy may be useful in the management of intraventricular and paraventricular lesions and cystic lesions of the brain. Septum pellucidotomy or sept-ostomy can be performed endoscopically to treat isolated lateral ventricles.<sup>18</sup> Multi-loculated hydrocephalus can also be managed by multiple fenestrations.

In our study, ETV was performed successfully with good outcome in 46/60 (76.7%) patients with obstructive hydrocephalus. There was no permanent morbidity related to ETV. The success rate of ETV in adults depends on the etiology of HCP and is calculated as 68% to 83%.<sup>19,20</sup> In our group we estimate the initial success rate as around 76.7% which is supporting other local studies showing success rate of (71%) 19, (78.4%) 17 and 83.07%.<sup>21</sup> The success rate is also comparable with that of *Hopf et al*, have reported a success rate of 76% for ETV in severe hydrocephalus secondary to posterior fossa tumor,<sup>22</sup> Similarly *Valenzuela S et al*, also reported a 76% success rate for ETV in severe hydrocephalus before posterior fossa tumor surgery.<sup>23</sup>

The ETV is a relatively safe procedure in experienced hands but carries the risk of complications such as hypothalamic or thalamic injury.<sup>24</sup> The technique can be augmented by the use of neuronavigation or stereotactic guidance.<sup>25</sup> In our study group, complication rate were observed in 14 (23.3%) cases including inadequate Ventriculostomy (8.33%), seizures

(6.67%), CSF leak (5%), ventricular bleed (1.7%) and meningitis (1.7%). According to *Bouras T et al*, who conducted a review on complications of ETV, the overall complication rate was (8.8%).<sup>26</sup>

Mortality rate in our study was (3.33%) due to ventricular bleed and CSF leak with meningitis which is comparable to (1.93%) by *Ali M. et al*.<sup>27</sup>

## CONCLUSION

The Endoscopic Third Ventriculostomy is a minimally invasive procedure, safe and especially effective and useful in obstructive (non-communicating) hydrocephalus.

*Address for Correspondence;  
Dr. Faheem Usmani*

*Department of Neurosurgery, Postgraduate Medical  
Institute, Lahore General Hospital, Lahore  
Email: zoobby890@gmail.com*

## REFERENCES

1. ReKate HL. The definition and classification of hydrocephalus: a personal recommendation to stimulate debate. *Cerebrospinal Fluid Research*, 2009; 5: 9-15.
2. Vinchon M, ReKate H, Kulkarni AV. Pediatric hydrocephalus outcomes: a review. *Fluids Barriers CNS*, 2012; 9 (1): 18-28.
3. Durnford AJ, Kirkham FJ, Mathad N, Sparrow OC. Endoscopic third ventriculostomy in the treatment of childhood hydrocephalus: validation of a success score that predicts long-term outcome: Clinical article. *Journal of Neurosurgery: Pediatrics*, 2011; 8 (5): 489-93.
4. Nimjee SM, Powers CJ, McLendon RE, Grant GA, Fuchs HE. Single-stage bilateral choroid plexectomy for choroid plexus papilloma in a patient presenting with high cerebrospinal fluid output: Case report. *Journal of Neurosurgery: Pediatrics*, 2010; 5 (4): 342-5.
5. Yadav YR, Parihar V, Sinha M. Lumbar peritoneal shunt. *Neurology India*, 2010; 58 (2): 179-84.
6. Dusick JR, McArthur DL, Bergsneider M. Success and complication rates of endoscopic third ventriculostomy for adult hydrocephalus: a series of 108 patients. *Surgical Neurology*, 2008; 69 (1): 5-15.
7. Mian IuH, Khan SA, Raja RA, Ahmed E. Efficacy of endoscopic third ventriculostomy in non-communicating hydrocephalus. *J Ayub Med Coll Abbottabad*, 2012; 24 (2): 144-6.
8. Sokal P, Birski M, Rusinek M, Paczkowski D, Zieliński P, Harat A. Endoscopic third ventriculostomy in treatment of hydrocephalus. *Videosurgery and Other Minimally Invasive Techniques*, 2012; 7 (4): 280-5.

9. Buxton N, Turner B, Ramli N, Vloeberghs M. Changes in third ventricular size with neuroendoscopic third ventriculostomy: a blinded study. *Journal of neurology, neurosurgery, and psychiatry*, 2002; 72 (3): 385-7.
10. Gangemi M, Mascari C, Maiuri F, Godano U, Donati P, Longatti PL. Long-term outcome of endoscopic third ventriculostomy in obstructive hydrocephalus. *Minimally invasive neurosurgery: MIN*. 2007; 50 (5): 265-9.
11. Singh D, Gupta V, Goyal A, Singh H, Sinha S, Singh A, Kumar S. Endoscopic third ventriculostomy in obstructed hydrocephalus. *Neurol India*, 2003; 51: 39-42.
12. Idowu OE, Falope LO, Idowu AT. Outcome of endoscopic third ventriculostomy and Chhabra shunt system in noncommunicating non-tumor childhood hydrocephalus. *J Pediatr Neurosci*. 2009; 4: 66-9.
13. Rieken S, Gaiser T, Mohr A, Welzel T, Witt O, Kulozik AE et al. Outcome and prognostic factors of desmoplastic medulloblastoma treated within a multidisciplinary treatment concept. *BMC Cancer*, 2010; 10: 450.
14. Torkildsen A. New palliative operation in cases of inoperable occlusion of the sylvian aqueduct. *Acta Psychiatr Neurol Scand*. 1939; 82: 117-23.
15. Erik J. van Lindert. Microsurgical third ventriculocisternostomy as an alternative to ETV: report of two cases *Child Nerv Syst*. 2008; 24: 757-61.
16. Dalrymple SJ, Kelly PJ. Computer-assisted stereotactic third ventriculostomy in the management of noncommunicating hydrocephalus. *Stereotact Funct Neurosurg*. 1992; 59: 105-10.
17. Guiot G, Derome P, Hertzog E, Bamberger C, Akerman M. Ventriculo-cisternostomy under radioscopy control for obstructive hydrocephalus. *Presse Med*. 1968; 76: 1923-26.
18. Schroeder HW, Oertel J, Gaab MR. Endoscopic treatment of cerebrospinal fluid pathway obstructions. *Neurosurgery*, 2008; 62: 1084-92.
19. Ali M, Usman M, Khan Z, Khan KM, Hussain R, Khanzada K. Endoscopic third ventriculostomy for obstructive hydrocephalus. *J Coll Physicians Surg Pak*. 2013; 23 (5): 338-41.
20. McLaurin RL: Disadvantages of the preoperative shunt in posterior fossa tumors. *Clin Neurosurg*. 1983; 30: 286-292.
21. Rehman ZU, Khanzada K, Husain R, Ali M, Ali M. Experience with endoscopic third ventriculostomy in the management of hydrocephalus secondary to posterior fossa tumor. *J Postgrad Med Inst*. 2013; 27 (4): 433-8.
22. Hopf NJ, Grunert P, Fries G. Endoscopic third ventriculostomy: outcome analysis of 100 consecutive procedures. *Neurosurg* 1999; 44 (4): 795-804; Discussion, 804-806.
23. Valenzuela S, Trellez A. Pediatric neuroendoscopy in Chile. Analysis of the first 100 cases. *Childs Nerv Syst*. 1999; 15: 457-460.
24. Papo I, Caruselli G, Luongo A: External ventricular drainage in the management of posterior fossa tumors in children and adolescents. *Neurosurg*. 1982; 10 (1): 13-15.
25. Taylor WAS, Todd NV, Leighton SEJ: CSF drainage in patients with posterior fossa tumours. *Acta Neurochir (Wien)*, 1992; 117: 1-6.
26. Bouras T1, Sgouros S. Complications of endoscopic third ventriculostomy. *J Neurosurg Pediatr*. 2011; 7 (6): 643-9.
27. Ali M, Usman M, Khan Z, Khan KM, Hussain R, Khanzada K. Endoscopic third ventriculostomy for obstructive hydrocephalus. *J Coll Physicians Surg Pak*. 2013; 23 (5): 338-41.

**AUTHORS DATA**

Name	Post	Institution	E-mail
Dr. Faheem Usmani		Department of Neurosurgery, Postgraduate Medical Institute, Lahore General Hospital, Lahore	
Dr. Zubair Ahmed			zoobby890@gmail.com
Dr. Amir Aziz			
Dr. Khurram Ishaque			
Dr. Tariq Salah-ud-Din			