

ORIGINAL ARTICLE

Incidental Durotomy in Lumbar Microdiskectomy; Incidence, Management and Early Sequelae

RAMZAN HUSSAIN, BILAL KHAN, AKRAM ULLAH

Ikram Alam, Mohammad Idris Khan, Mumtaz Ali

Department of Neurosurgery, Lady Reading Hospital, Peshawar

ABSTRACT

Objective: To know about the incidence, management and early sequelae of incidental durotomy during lumbar microdiskectomy.

Materials and Methods: This was a retrospective study. The duration of the study was six months from January 24th to 20th July 2013. The charts and records of the patient from the operation notes were reviewed and the parameters like the age, sex, side and location of the disc, mean hospital stay and any documented leak or neural deficit were recorded on a designed proforma. All patients undergoing lumbar microdiskectomy for the first time were included in the study and the patients having a repeated surgery as well as other indications (stenosis, tumor, trauma) excluded from the study.

Results: A total of 147 patients were included in the study including 87 males and 60 females with a male to female ratio of 1.5 to 1. The age range was 18 – 63 years with a mean age of 34 ± 6 years. The most common level was L₄ – L₅. Right side was more common than the left side and the four patients (2.7%) had an incidental durotomy which was repaired intra-operatively. The patient with an incidental have any focal deficit apart from the prolongation of the hospital stay.

Conclusion: Incidental durotomy is an infrequent complication of lumbar microdiskectomy and there is little early clinical sequelae apart from prolongation of hospital stay.

Keywords: Incidental durotomy, microdiskectomy, sequelae.

INTRODUCTION

Incidental durotomy is an unintentional tear in the dura during spine surgery.¹ The frequency of incidental durotomy is most common among the thoracic anterior and cervical posterior approaches, minimum for the cervical anterior while the incidence for the lumbar spine is in between the two.² Incidental durotomy has an impact on the surgical outcome as it increases the operative time and usually a laminectomy is performed to repair the dura.²⁻⁴ The durotomy can be primarily repaired with the suture, hemostats like surgical and spongoston or by the help of fibrin glue.^{4,5,9,13} Inadequately treated durotomy has several consequences; postural headaches, vertigo, posterior neck pain, neck and / or stiffness, nausea, diplopia, photophobia, tinni-

us, and blurred vision.^{3,5,6} This has been due to a persistent leak of the cerebrospinal fluid from the durotomy site.^{5,6,7,14} Long term prognosis of patients with durotomies is poor compared to those without a durotomy.⁸⁻¹¹ The purpose of this study was to have an audit of the incidental durotomies during lumbar disc surgeries in our unit and know about clinical impact in a quest to further rectify our operative strategy.

MATERIALS AND METHODS

This was a retrospective study conducted in the department of neurosurgery PGMI / Lady Reading Hospital, Peshawar. The duration of the study was six months from January to July 2013. The records of the patient

from the operation notes were reviewed and the parameters like the age, sex, side and location of the disc were recorded on a predesigned proforma. All patients undergoing lumbar microdiscectomy for the first time were included in the study and the patients having a repeated surgery were excluded from the study. All patients had undergone lumbar disc procedure for the herniated lumbar disc, about 97% were elective and 5 (3%) of them were done on an emergency basis. The patients were observed peroperatively as having an incidental dural tear by observing the cerebrospinal fluid flow in the operative field or seeing the nerve roots with an obvious rent in the dura.

Operative Procedure

All the patients with the durotomy were repaired primarily during the procedure with silk 4/0 and hemostat such as spongston was placed on the site. No muscle, fascia or fat graft was used. The wound was closed in three layers; fascia with vicryl 1 continuous water tight, subcutaneous with vicryl 2/0 interrupted, and skin with prolene 2/0. The patients with an incidental durotomy had been in the hospital for two days and those without a durotomy were having a mean hospital stay of only one day.

RESULTS

A total of 147 patients were included in the study who had undergone surgery in the study period. This included 87 males and 60 females with a male to female ratio of 1.5 to 1. The age range was 18 – 63 years with a mean age of 34 ± 6 years. The most common level was L₄ – L₅ followed by L₅ – S₁ (table 1). The right side was more common than the left side.

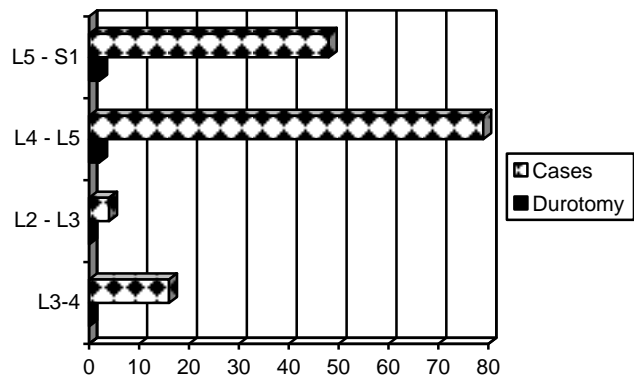
All the patients had undergone fenestration which

Table 1: Frequency and percentages of the various levels herniated lumbar disc.

Disc Level	Frequency	Percent
L ₂₋₃	4	2.7
L ₃₋₄	16	10.8
L ₄₋₅	79	45.6
L _{5-S1}	48	25.9
Total	147	100.0

was converted to laminectomy in case of an incidental durotomy.

They were observed post-operatively for two days in the hospital. The durotomy was equally distributed i.e. at L₄ – L₅ and L₅ – S₁ levels (graph 1). Patients with a durotomy were having a prolonged hospital stay compared to those without a durotomy (48 vs 24 hours). No focal neurological deficit were observed in patients having an incidental durotomy.



The graphical representation of the incidental durotomy and the lumbar disc level surgery performed.

DISCUSSION

Lumbar discectomy is the most common surgical procedure performed for the low back pain with an estimated 358,900 surgeries performed annually in the United States in 2002 alone.¹⁵ Incidental durotomy is among its common intra-operative complications apart from the wrong level, missed pathology, bleeding, nerve root injury and least commonly anterior visceral and vessels injury.¹⁶ Incidental durotomy prolongs hospital stay and bears the potential hazards of post operative CSF leak, pseudomeningocele and dural cutaneous CSF fistula, development of postoperative headache. Other complications like nerve root entrapment with resultant neurological damage, meningitis, and arachnoiditis and the incidence of deep wound infection reported to be as high as 8.1%.⁵⁻⁸

This has been one of the significant reasons for medical malpractice lawsuits against the neurosurgeons.⁷ The incidental durotomy during spinal procedures varies and depends upon the nature of surgery, the procedure performed, the level of the disc surgery.

The incidence is the highest for the posterior cervical and the thoracic spine while it is the lowest for the anterior cervical procedures.⁴ The incidence is also high among the repeat surgery for the spinal problem due to the formation of the adhesion and moribund anatomy.^{2,3}

The incidence of durotomy in our series was 4 (2.72%) and the reported range in literature is from 3.72%¹³ to 4%^{3,4} for lumbar discectomy. The incidence of incidental durotomy in repeat spinal surgeries range from 8.1% to 17%.^{1,2,14,19} The rate was equal for the L₄ – L₅ and L₅ – S₁ level; 2 durotomies in each group although the frequency was higher for L₅ – S₁ 2/48 (4.1%) than L₄ – L₅ 2/79 (2.53%) for the same level surgery. This was a bit different from the results by Desai A et al¹³ where L₅ – S₁ was the most common level more than 56% of surgeries performed. In his series the durotomies were in 12 for each L₄ – L₅ and L₅ – S₁ level but there was increase in the L₄ – L₅ (4.1%) level than L₅ – S₁ (2.8%) for the same level surgeries. He had a greater cohort of patients than ours. Incidental durotomy doubles the operative time, increases the blood loss by six times, rises the chance of an intraoperative transfusion by four times and there is two and a half times increase in the duration of the mean hospital stay.¹³

Incidental durotomy is marked by the appreciation of clear fluid in the operative field or by visible rent in the dura.¹⁷ Clear fluid in the operative field can be from a wet cottonoid, synovial facet fluid, previous lumbar puncture or the rent from a previous myelogram which is not a common practice nowadays.^{16,17} Unfortunately the clear fluid most of the time is CSF unless proved otherwise. Most commonly it occurs during incision of the ligamentum flavum and can happen when the ligamentum flavum is very thin, which occurs in lumbosacral anomalies or when a disc herniation pushes the dural sac posteriorly, right under the ligamentum flavum.^{16,17} Therefore a two – step flavotomy with a special semisharp dissector is recommended.¹⁸

The dural tear should be repaired primarily^{2,13,14} as we did in all cases either with suture and placed blood soaked spongoston. We used silk 4/0 while 58% of surgeons used Prolene (Ethicon, Inc., Somerville, NJ), 30% used a different stitch, and 12% did not repair the dural tear as reported by Tafazal and Sell.²⁰ There are other means of repairing the dural tear like the use of spongoston, blood soaked Surgicel (Ethicon, Inc., Somerville, NJ), fibrin Glue and fat pad or fascia graft.^{10,11} After the repair Valsalva maneuver was

given and the site was observed for any leak.^{12,13} We did not place any drain and the use of it is controversial according to Eismont⁹, need to insert basis by Cammisa et al,¹ used in most cases by Khan et al¹⁴ and considered mandatory by Wang et al.¹⁸ The fascia was closed water tight with running vicryl 1 as recommended.² No CSF leak¹³ was observed in any case in the post operative period nor there had been any re-exploration for the problem. We did not noticed any significant difference in the wound infection, nerve injury, recurrent disc herniation and repeat spinal surgery in patients with or without a durotomy as reported.¹³

CONCLUSION

Incidental durotomy is an infrequent complication of lumbar microdiscectomy, should be repaired primarily and there are little clinical sequelae in the early post op period apart from prolongation of hospital stay.

Address for Correspondence:

Dr. Bilal Khan

Room#B2, New TMO Hostel, Lady Reading Hospital, Peshawar. E-mail; Bkafriidi675@yahoo.com

REFERENCES

1. Cammisa FP Jr, Girardi FP, Sangani PK, Parvataneni HK, Cadag S, Sandhu HS: Incidental durotomy in spine surgery. *Spine*, 2000; 25: 2663–7.
2. Guerin P, et al. Incidental durotomy during spine surgery: Incidence, management and complications. A retrospective review. *Injury* (2011).
3. Chaves C, Freidberg SR, Lee G et al. Cerebral vasospasm following intracranial hypotension caused by cerebrospinal fluid leak from an incidental lumbar durotomy. Case report. *J Neurosurg*; 2005; 102: 152–5.
4. Finnegan WJ, Fenlin JM, Marvel JP, Nardini RJ, Rothman RH: Results of surgical intervention in the symptomatic multiply- operated back patient. Analysis of sixty seven cases followed for three to seven years. *J Bone Joint Surg Am*, 1979; 61: 1077–82.
5. Goodkin R, Laska LL: Unintended “incidental” durotomy during surgery of the lumbar spine: medicolegal implications. *Surg Neurol* 1995; 43: 4–14.
6. Mayfield FH, Kurokawa K. Watertight closure of spinal dura mater: technical note. *J Neurosurg*, 1975; 43: 639–40.
7. Mokri B. Spontaneous cerebrospinal fluid leaks: from intracranial hypotension to cerebrospinal fluid hypovolemia—evolution of a concept. *Mayo Clin, Proc* 1999; 74: 1113–23.

8. Jones AA, Stambough JL, Balderston RA, Rothman RH, Booth RE Jr: Long-term results of lumbar spine surgery complicated by unintended incidental durotomy, 1989; *Spine* 14: 443–446.
9. Eismont FJ, Wiesel SW, Rothman RH. Treatment of dural tears associated with spinal surgery. *J Bone Joint Surg*, 1981; 63: 1132–6.
10. Shaffrey CI, Spotnitz WD, Shaffrey ME, Jane JA. Neurosurgical applications of fibrin glue: augmentation of dural closure in 134 patients. *Neurosurgery*, 1990; 26: 207–10.
11. Saxler G, Krämer J, Barden B, Kurt A, Pförtner J, Bernsmann K: The long-term clinical sequelae of incidental durotomy in lumbar disc surgery. *Spine*, 2005; 30: 2298–302.
12. Hodges SD, Humphreys SC, Eck JC, et al. Management of incidental durotomy without mandatory bedrest: a retrospective review of 20 cases. *Spine*, 1999; 24: 2062–4.
13. Desai A, Ball PA, Bekelis K et al. Outcomes after incidental durotomy during first-time lumbar Discectomy. *J Neurosurg Spine*, 2011; 14: 647–53.
14. Khan MH, RhinJ, Steele G, et al. Postoperative management protocol for incidental dural tears during surgery: a review of 3183 consecutive degenerative lumbar cases. *Spine*, 2006; 31 (22): 2609–13.
15. Sherman J, Cauthen J, Schoenberg D. Economic impact of improving outcomes of lumbar discectomy. *The Spine J*, 2010; 10: 108–16.
16. Kraemer K, Wild A, Haak H, et al. Classification and management of early complications in open lumbar microdiscectomy. *Eur Spine J*, 2003; 12: 239–46.
17. McCulloch J, Young PH. *Essentials of spinal microsurgery* 1998. Lippincott – Raven, Philadelphia.
18. Wang JC, Bohlman HH, Riew DK. Dural tears secondary to operations on the lumbar spine: Management and results after a two-year-minimum follow-up of eighty-eight patients. *J Bone Joint Surg Am*, 1998; 80: 1728.
19. Stolke D, Sollmann W, Seifert V. Intra and post operative complications in lumbar disc surgery. *Spine*, 1989; 14: 56–9.
20. Tafazal S.I., Sell PJ. Incidental durotomy in lumbar spine surgery: incidence and management. *Eur Spine J*, 2005; 14: 287–90.