

A REPORT OF THREE DENTAL IMPLANT FRACTURE AND LITERATURE REVIEW

Ahmad Rohanian

Assistant Professor, Department of Prosthodontics, School of Dentistry,
Tehran University of Medical Sciences

Abbas Taher

Professor of OMF Surgery, Dean of Faculty of Dentistry, University of Kufa,
Kufa-Najaf-Iraq

Ammar Albujeer Shawki

DDS Student School of Dentistry, and Scientific Research Centre,
Tehran University of Medical Science

Salma Pirmoazzen

Department Of Endodontics ,School Of Dentistry,
Tehran University Of Medical Sciences, Tehran Iran

Abstract

Implant fracture is one of the rare complications in Implant Dentistry. Such fractures pose important problems to both the patient and the dental surgeon. According to most literature sources, the prevalence of dental implant fractures is very low (approximately 2 fractures per 1000 implants in the mouth). However, considering that implant placement is becoming increasingly popular, an increase in the number of failures due to late fractures is to be expected. Clearly, careful treatment can contribute to reducing the incidence of fracture. An early diagnosis of the signs alerting to implant fatigue, such as loosening, torsion or fracture of the post screws and prosthetic ceramic fracture, can help prevent an undesirable outcome. Also, it is important to know and apply the measures required to prevent implant fracture. Therefore, the present literature reported three cases with fractured implants. It also discusses the management options and the possible causal mechanisms underlying such failures. In addition, the factors believed to contribute to implant fracture with literatures review were also discussed.

Keywords: Dental implants, implant fracture, failed dental restoration, overload

Introduction

The problem associated with osseointegration are two types; biologic (soft tissues and bone) and mechanical problems. The mechanical problems involves the implant fracture itself or the abutment screw .The Implant fracture is one of the rare mechanical complications in the dental implant, and it is less than 1% of all complications that may happen.(1-5).

Causes of implant fracture may be divided into three categories: (1) defects in the design of the material, (2) non-passive fit of the prosthetic structure, and (3) biomechanical or physiologic overload. However, failure in the production and design of dental implants, bruxism, or large occlusal forces, superstructure design, implant localization, implant diameter, metal fatigue, and bone resorption around the implant can be regarded as a cause of implant fracture. In addition, the galvanic activity of metals used in prosthetic restorations can also be cited as a cause. (5-7)

The overloading of dental implants during functional and parafunctional activity are the major factors affecting malocclusion, i.e. improper fit in the implant. Para function is known as the main etiology. (6-11).

Case Reports:

Case No.1: A 45 years old woman was referred to our centre due to her complaints of mobility in her LL6 implant. She had two separated implant; 4mm cervical diameter and two separated crowns in the lower left 6 and 7 area (fig. 1). The opposite arch which had full decoded teeth with no history of para function was evaluated. Then, after about 2 years, she complained of pain and mobility in the area (fig. 2). The clinical examination showed that the implant of the first molar tooth replacement fractured from the distal part of the teeth (fig. 3).

In addition, the broken part was removed using trepan technique (fig. 4, 5)

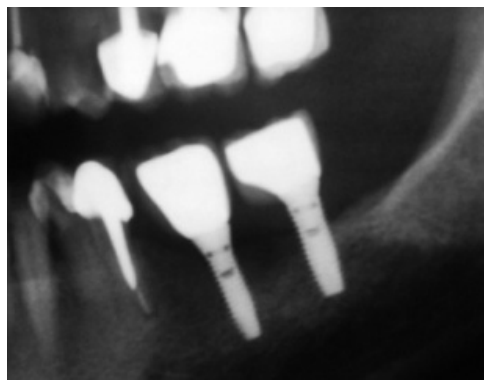


Fig 1. X-ray film show two separate implant

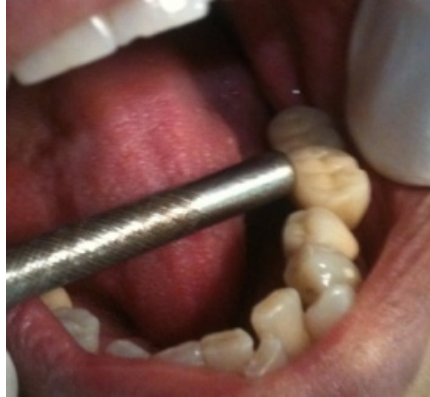

Fig 2. Mobility in the Implant

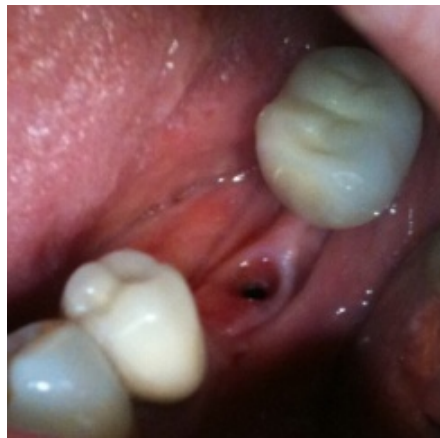

Fig 3

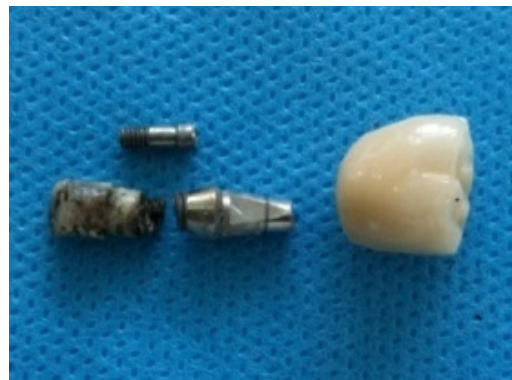

Fig 4,5. Removal of the broken implant

After the examination of the broken implant, it showed that the implant was small in diameter and the biting force concentration on the weakest part of implant uneven distribution of forces caused the fracture.

Case No 2: A 50 years old man also complained of broken implant in the UL6. The implant size was 4mm bone level, and the X-ray showed broken implant. After a careful assessment, the patient was found to had night bruxism and strong biting with fracture restoration. Hence, the increase para function and malocclusion in the jaws movement resulted to fracture after two years from the implant time. However, the fractures pieces were removed (Fig. 6-7).

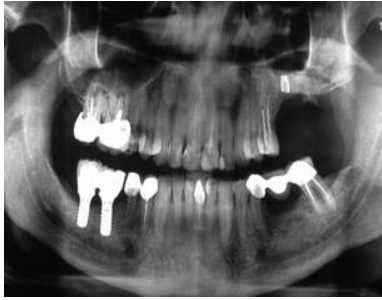

Fig 6. OPG showed broken implant in the UL6



Fig 7. The broken implant with a crown

The possible cause for the broken implant was the weakness of the implant size against the biting force and the bruxism. Vertical/horizontal biting movement also affected the implant stability.

Case No. 3: A 45 years old male patient came to our centre with complaints of mobility in his bridge at the upper right arch. The bridge supported implant was made for him seven years ago with four implants. The patient had severed grinding and hard biting. Nevertheless, clinical examination revealed mobility in the upper right 6 area implant. X-ray showed implant fracture (Fig 8-11).

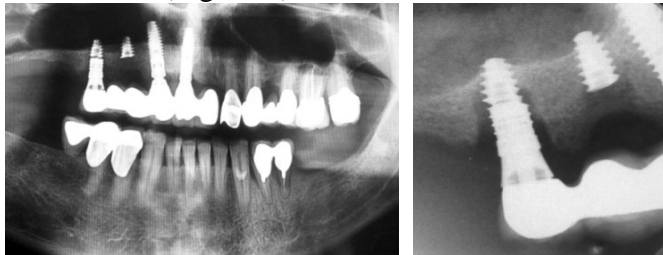

Fig 8, 9. Showed the broken implant



Fig 10. Removal of the broken implant and the other bridge support abutment and loss implant

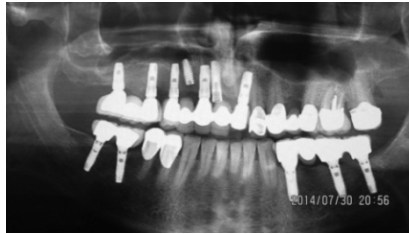

Fig 11. Implanted with a new implant with more support

Discussion

Despite implant therapy has been consolidated with high success rates as demonstrated in a study by Adell, problems may arise with this type of treatment. Despite its low incidence, consensus in the literature suggests that one of the possible complications that may occur with dental implants is fractured and treated (1-7). Therefore, treatment represents a serious challenge to clinicians (1,3,5,11). Implant diameter also has a direct influence on the occurrence of fracture, in that dental implants with small diameters have reduced resistance to fatigue. In several cases analysed, fracture took place in 4mm diameter in our case. Thus, we recommend the use of dental implants with large diameters whenever possible, especially in the mandibular and maxillary posterior regions, where most fractures takes place. Adequate prosthetic planning is fundamental to reduce dental implant fracture rates even further.

Biomechanical factor, besides achieving a passive fit of the prosthetic superstructure, must be taken into consideration from the moment implants are placed until prostheses are installed (3,9,11). Cantilevers act as crowbars, generating tension in the fixtures and making them susceptible to fracture, especially in the posterior regions of the mouth. In this situation, whenever possible, the number of implants must be increased, and their placement in a straight-line configuration must be avoided (3,5,11). Frequent loosening or fracture of the retaining screws and bone loss around the implant are characteristic signs that precede the fracture of implants (3,7,9,11). It was understood that bone resorption is a consequence of several adverse factors to which the implant/prosthesis system is exposed. However, bone loss will increase the cantilever effect with the consequent increase in tension forces, generating stress in the thread portion of the implant, where a hollow cylinder is normally found along with greater fragility. Thus, this results in metal fatigue (3,7,9,12).

In conclusion, the proper the choice of the implant size and the proper restoration with proper occlusal constriction, the softer the night guard will minimize the risk of the fracture.

References:

- 1- Mish CE. Dental implant prosthetics. 2nd ed. St Louis: Mosby; 2005.
- 2- Goodacre CJ, Bernal G, Rungcharassaeng K, Kan JY. Clinical complications with implants and implant prostheses. *J Prosthet Dent.* 2003 Aug;90(2):121-32.
- 3- Goodacre CJ, Kan JY, Rungcharassaeng K. Clinical complications of osseointegrated im-plants. *J Prosthet Dent.* 1999 May;81(5):537-52.
- 4- Gargallo Albiol J, Satorres-Nieto M, Puyuelo Capablo JL, Sánchez Garcés MA, Pi Urgell J, Gay Escoda C. Endosseous dental implant fractures: an analysis of 21 cases. *Med Oral Patol Oral Cir Bucal.* 2008 Feb 1;13(2):E124-8.
- 5- Eckert SE, Meraw SJ, Cal E, Ow RK. Analysis of incidence and associated factors with fractured implants: a retrospective study. *Int J Oral Maxillofac Implants.* 2000 Sep-Oct;15(5):662-7.
- 6- Muroff FI. Removal and replacement of a fractured dental implant: case report. *Implant Dent.* 2003;12:206–210
- 7- Velásquez-Plata D, Lutonsky J, Oshida Y, Jones R. A close-up look at an implant fracture: a case report *Int J Periodontics Restorative Dent.* 2002 Oct;22(5):483-91.
- 8- Tagger Green N, Machtei EE, Horwitz J, Peled M. Fracture of dental implants: literature review and report of a case *Implant Dent.* 2002;11(2):137-43.
- 9- Balshi TJ. An analysis and management of fractured implants: a clinical report. *Int J Oral Maxillofac Implants.* 1996 Sep-Oct; 11(5):660-6.
- 10- Dov M, Almog, Odalys Hector, Samuel Melcer, Kenneth Cheng. Implant fracture: A look at the physical mechanisms for failure. *Dental Tribune*, July 2010, 10A Clinical
- 11- Tagger-Green N, Horwitz J, Machtei EE, Peled M. Implant fracture: a complication of treatment with dental implants--review of the literature. *Refuat Hapeh Vehashinayim.* 2002 Oct;19(4):19-24, 68.
- 12- Eckert SE, Meraw SJ, Cal E, Ow RK. Analysis of incidence and associated factors with fractured implants: a retrospective study *Int J Oral Maxillofac Implants.* 2000 Sep-Oct;15(5):662-7.