

# COMPARATIVE HISTOPATHOLOGICAL STUDY BETWEEN AMIKACIN AND TOBRAMYCIN GIVEN ALONE AND IN COMBINATION WITH CALCIUM GLUCONATE IN RABBITS

*Nadia Abdulkarim Salih*

Department of Basic Sciences, Pharmacology, College of Veterinary  
Medicine, University of Sulaimani, Sulaimani, Iraq

*Karokh Hassan Salih*

Department of Pharmacology, College of Medicine,  
University of Sulaimani, Sulaimani, Iraq

*Duraïd Abdulhady Abbas*

Department of Pathology, College of Veterinary Medicine,  
University of Baghdad, Baghdad, Iraq

---

## Abstract

An experiment conducted to explore a histopathological comparison between tobramycin sulphate and amikacin sulphate, and to explore the role of calcium gluconate in antagonizing or reducing the main toxic side effects of tobramycin and amikacin like nephrotoxicity. The experiment was designed to study the effects of therapeutic and triple doses of tobramycin and amikacin alone, and with calcium gluconate in rabbits. This experiment lasted for one month and was divided into three periods (pretreatment period for 7 days, treatment period for 14 days and recovery period 7 days). The results showed that tobramycin and amikacin differ in their toxic effects potential at both therapeutic and triple doses. Tobramycin caused more pathological changes than that changes caused by amikacin, the main changes in renal tissue that caused by therapeutic dose of tobramycin are hydropic swelling of renal tubular epithelial cells, vascular congestion of glomeruli, while the triple dose of tobramycin caused shedding of renal tubular epithelial cells, formation of hyaline casts in tubular lumina, loss of brush border, hydropic swelling of renal tubular epithelial cells, foci of moderate to heavy mixed acute and chronic inflammatory cell infiltration (in form of neutrophils, lymphocytes, plasma cells and occasional eosinophil). Pretreatment with calcium significantly improved the study to the levels almost similar to that of control group for both drugs, and gave complete

protection from toxic effects of amikacin, and complete to partial protection with tobramycin accordingly with their doses.

---

**Keywords:** Renal histopathological changes of Amikacin and tobramycin, Nephrotoxicity effect of aminoglycoside

## **Introduction**

Aminoglycoside a group of antibacterial drugs derived from species of *Streptomyces*; they interfere with the function of bacterial ribosome. They contain an inositol moiety substituted with two amino or guanidine groups and with one or more sugars or amino sugars. (Chambers *et.al.*, 2007).

Low cost and high efficacy make aminoglycoside antibiotics a common choice for the treatment of gram negative bacterial infections.

Amikacin and tobramycin are effective in the treatment of many infections like urinary tract infection, burns, respiratory tract infection, gynecological infection, endocarditis and some mycobacterial infections. While these compounds are common and very widely used, they are not without serious clinical side effects such as nephrotoxicity, ototoxicity and neuromuscular blockade (Swan,1997).

Aminoglycosides are nephrotoxic because a sizable proportion of the administered dose is retained in the epithelial cells lining the S1 and S2 segments of the proximal tubules after glomerular filtration.

There are abundant evidences that repeated administration of all aminoglycoside such as amikacin and tobramycin to experimental animals results in increased urinary excretion of divalent cations. Hypercalciuria is the most frequently reported finding (Levison&Matthew,2009).

The aminoglycosides are bactericidal antibiotic that bind to 30S ribosome and inhibit bacterial protein synthesis. They are polycations, and their polarity is responsible of their pharmacokinetic properties shared by all members of this group

## **Material and Method**

The experiments were performed on healthy local male domestic rabbits intermediate buck (6 - 8 months) purchased from local market in Sulaimani. Their weights ranged between 1.5-1.9 kg. The animals were allocated one week prior to the experiment. They were reared at an optimal room temperature ranged between 22-25°C and were exposed to artificial light for 12 hrs/day.

**Experimental design:** -For this experiment, rabbits were divided randomly into nine groups, each group contain 3 rabbits (n=3).

**Group (1): G1** included rabbits treated with distilled water according to body weight and at a dose level of (0.1 ml/kg/B.wt./day) subcutaneously (S/C) throughout all the experimental period.

**Group (2): G2** all rabbits in this group were given therapeutic dose of tobramycin sulphate by intramuscular route (I/M) at a dose of (5 mg /kg / B.wt /day).

**Group (3): G3** each rabbit in this group was pretreated subcutaneously S/C with therapeutic dose of calcium gluconate, and then injected by I/M route a therapeutic dose of tobramycin sulphate which is (5 mg/kg/ B.wt /day)

**Group (4): G4** rabbits treated with triple dose of tobramycin sulphate at dose level of (15 mg/kg/B.wt /day) by I/M route.

**Group (5): G5** each rabbit in this group was pretreated subcutaneously S/C with therapeutic dose of calcium gluconate, and then injected by I/M route a triple dose of tobramycin sulphate which is (15 mg/kg/ B.wt /day)

**Group (6): G6** rabbits were injected by I/M route with therapeutic dose of amikacin sulphate (15 mg / kg/B.wt /day)/day.

**Group (7):G7** given therapeutic dose of amikacin sulphate at dose level of (15 mg/kg/ B.wt/day) by I/M injection in to rabbits pretreated with therapeutic dose of calcium gluconate (22.5 mg/kg/ B.wt/day).

**Group (8): G8** rabbits treated with triple dose of amikacin sulphate at dose level of (45 mg/kg/B.wt /day)by I/M route.

**Group (9):G9** given triple dose of amikacin sulphate at dose level of (45 mg/kg/ B.wt/day) by I/M injection in to rabbits pretreated with therapeutic dose of calcium gluconate (22.5 mg/kg/ B.wt/day).

### **This experiment consists of three periods:-**

**A. Pretreatment Period:** after the animals were allocated into the cages, they were kept for 7 days prior to begin the experiment for adaptation to the new environment.

**B. Treatment Period:**all the animals of antibiotic treated groups injected by I/M route for the period of 14 days, twice daily, once in the morning and another in the evening. Calcium gluconate was injected subcutaneously (S/C) at therapeutic dose in combination treatment groups about half hour before the antibiotic injection.

**C. Recovery Period:** during this period and after the stoppage of all treatments, the animals were scarified for preparation of histopathological slides from the kidneys in order to see the changes in renal tissues if present.

**Histopathological study: -**

Tissue samples (kidneys) from rabbits were removed. The organs were fixed in 10% NBF (100 ml formalin (40%), 4 g sodium phosphate monobasic, (6.5g) sodium phosphate dibasic and (900 ml D.W)and processed for paraffin embedding. The histopathological sections (4-6 Microns) were stained with haematoxylin eosin. The slides were coded and examined.(Luna, 1968)

**Result:**

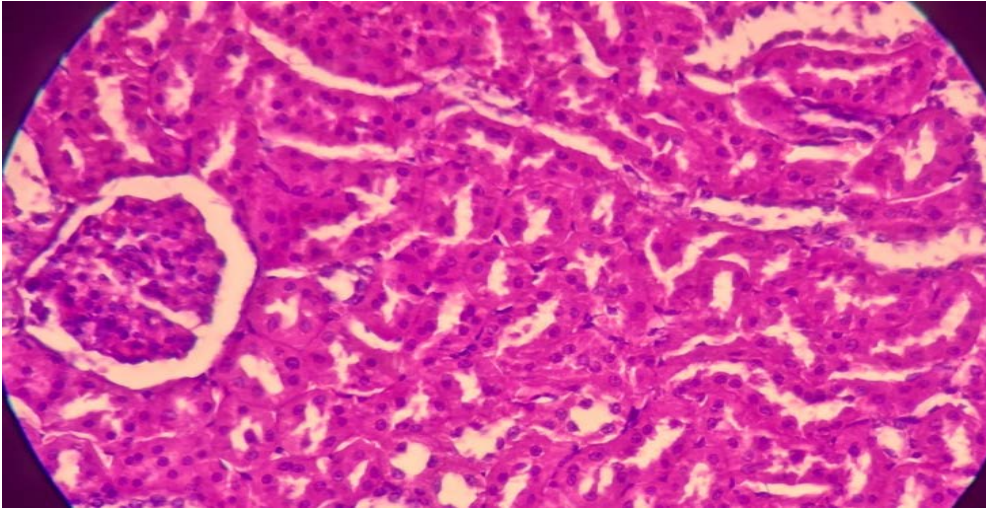


Figure (1) (Control group) (G1):-section of renal tissue from control shows adequate numbers of glomeruli and renal tubules, the renal glomeruli have normal capillary loops with no evidence of shrinkage or swelling, and the tubules are lined by cuboidal epithelial cells with nice brush borders and have normal lumina with no evidence of protein cast. The interstitial tissue is devoid of inflammatory cells.(H&E x40)

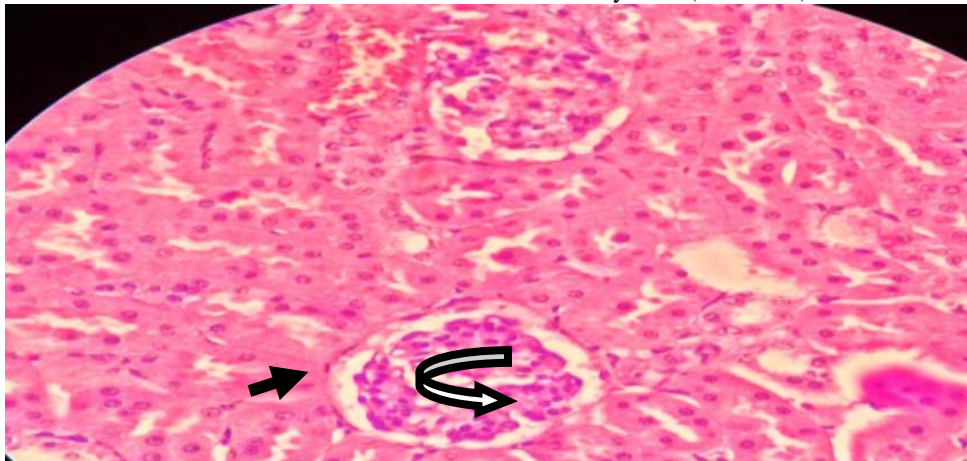


Figure 2 :- (Therapeutic dose of tobramycin) (G2):-The changes in renal tissue are noted as following: minimal hydropic swelling of renal tubular epithelial cells (black arrow), mild vascular congestion of glomeruli (curved arrow).(H&E x40)

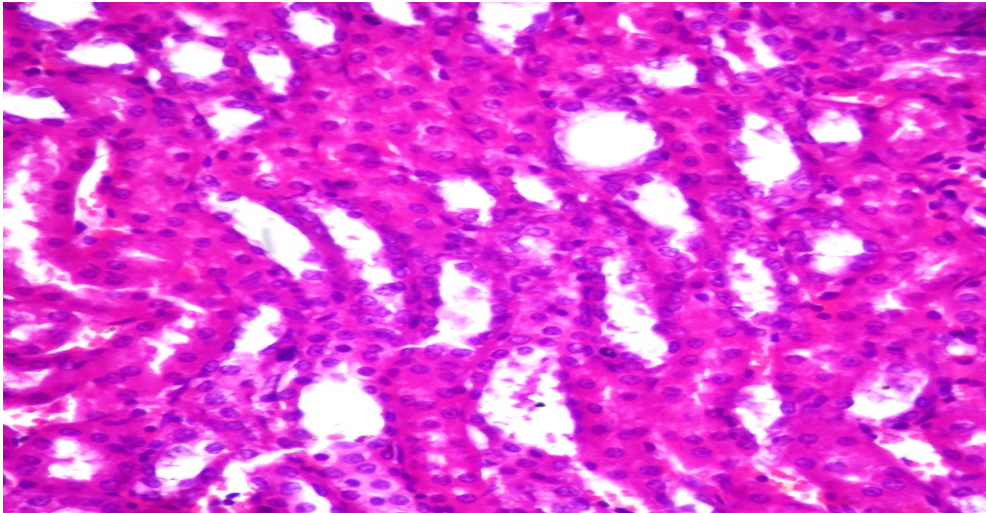


Figure (3)( Therapeutic dose of tobramycin and calcium) (G3):-the section shows renal tissue with histological features very close to renal tissue from controls.(H&E x40)

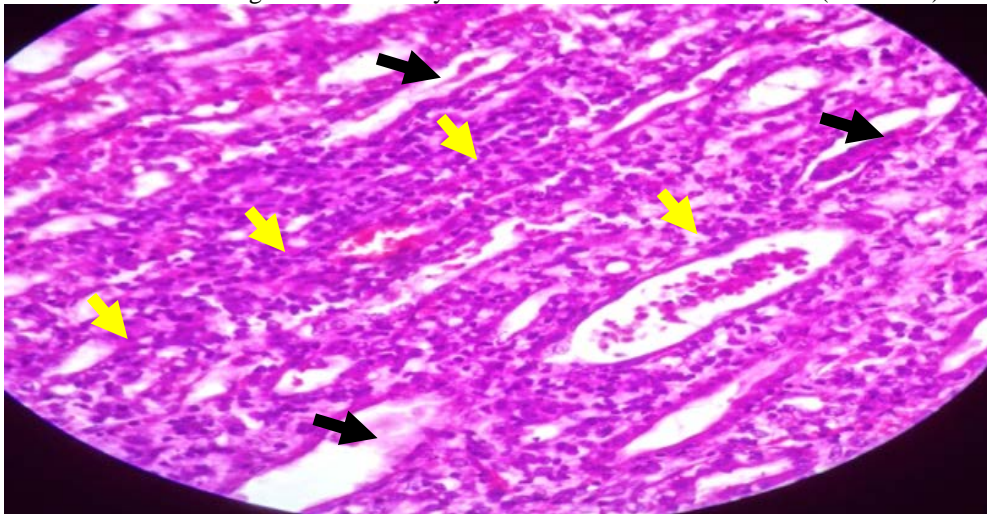


Figure 4:- (Triple dose of tobramycin) (G4)The changes are marked in renal tissue in form of shedding of renal tubular epithelial cells, formation of hyaline casts in tubular lumina(black arrows), loss of brush border, hydropic swelling of renal tubular epithelial cells, foci of moderate to heavy mixed acute and chronic inflammatory cell infiltration (in form of neutrophils, lymphocytes, plasma cells and occasional eosinophil) as indicated by yellow arrows.(H&E x40)

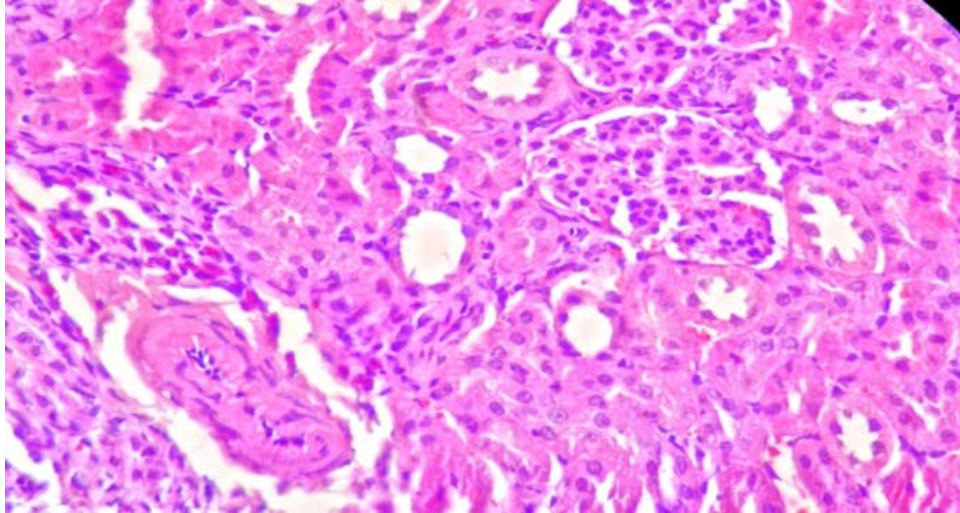


Figure 5:- triple dose of tobramycin and calcium (G5) tobramycin effect on renal tissue in rabbits treated with calcium and triple dose tobramycin, The sections of renal tissue is very much the same as the ones taken from control group (H&E x40).

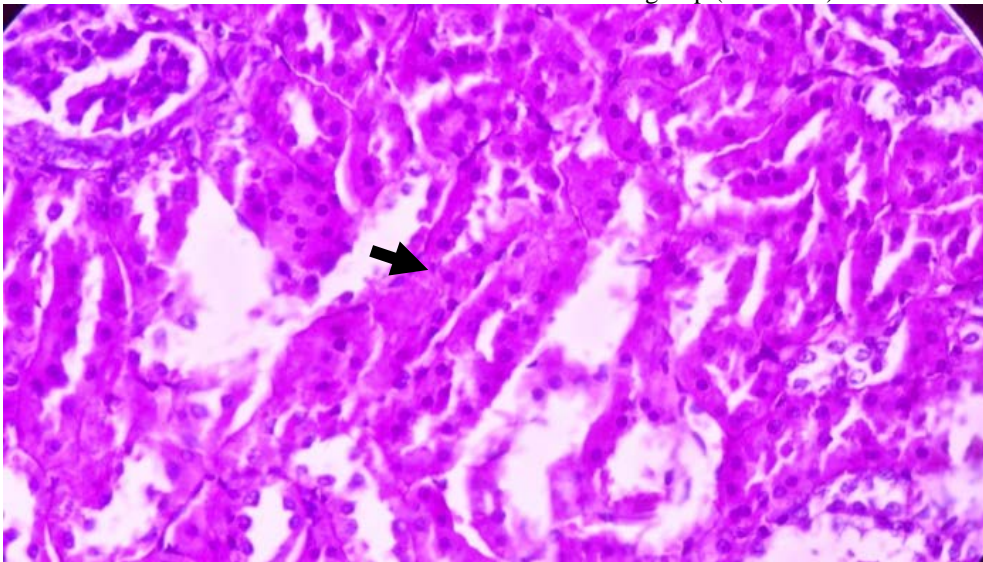


Figure 6:- Amikacin therapeutic dose (G6) section of renal tissue shows minimal and focal hydropic swelling of tubular epithelial cells (black arrow)(H&E x 40).

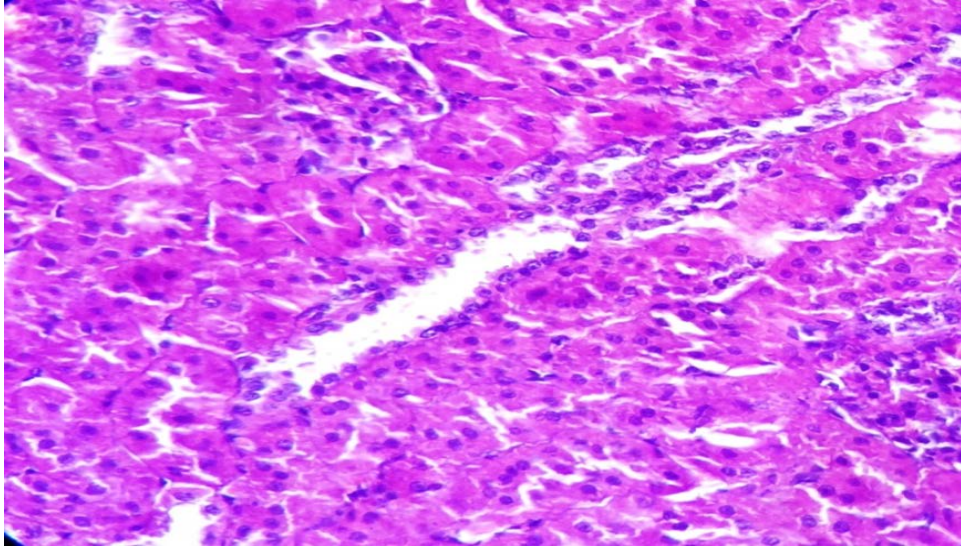


Figure 7:- Amikacin therapeutic dose with calcium (G7):-The sections look very much similar to those of control group which indicates protective effect of calcium in preventing harmful effects of Amikacin on renal tissue.(H&E x40)

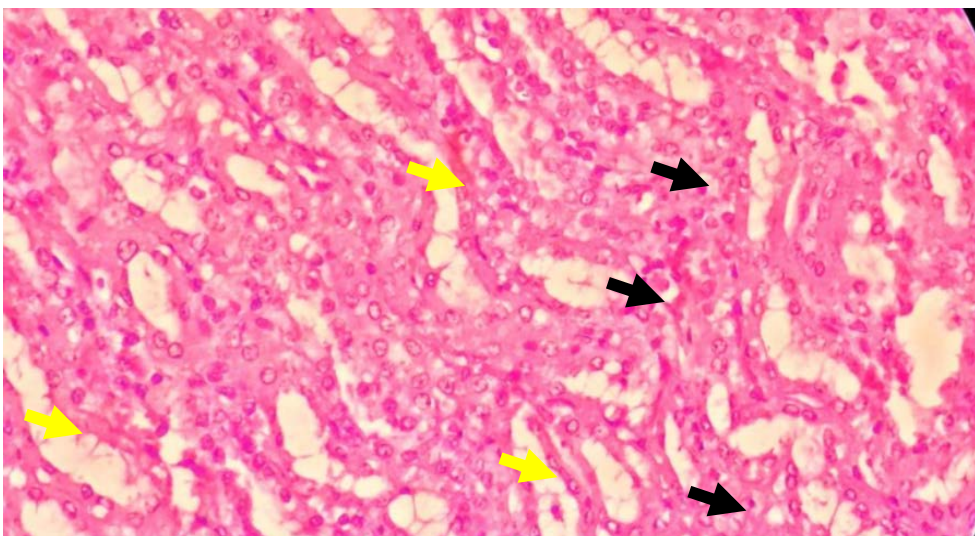


Figure 8:- Amikacin triple dose (G8):-the section shows vacuolar degeneration of renal tubular epithelial cells (black arrows), with few cells falling away into lumen and mild blurring of brush border (yellow arrows). The changes are milder than those of rabbits treated with similar doses of tobramycin(H&E x40).

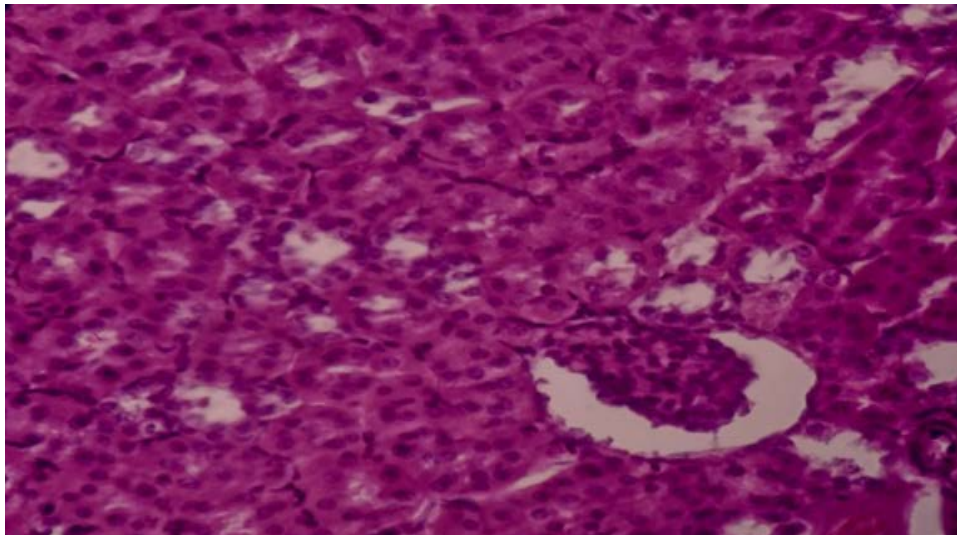


Figure 9:- Amikacin triple dose and Calcium (G9):-Renal tissue does not shows any of the changes that were seen in group treated with Amikacin alone. In fact the sections are very similar to those of control group (H&E x40).

## Discussion

The results showed that tobramycin and amikacin differ in their toxic effects potential at both therapeutic and triple doses. Tobramycin caused more pathological changes than that changes caused by amikacin. Pretreatment with calcium significantly improved the study to the levels almost similar to that of control group for both drugs, and gave complete protection from toxic effects of amikacin, and complete to partial protection with tobramycin accordingly with their doses. Our results were in agreement with other studies done by (AL-Hamiree, 1997&Obid, 1999)

In studies carried out by (Rose& Zalenzik, 1999) (Ali, 2003) Confirmed the ameliorate effect of oral  $\text{CaCO}_3$  (0.5 or 1.0 g/kg/B.wt) on the histological and biochemical changes induced by aminoglycosides nephrotoxicity in rats. It is suggested that high doses of tobramycin and amikacin cause calcium wasting and that calcium loading increased the delivery of ions to the kidney and prevented the binding of aminoglycoside to the brush border membrane, because it is suggested that the interaction between aminoglycoside and calcium in the kidney is due to the competition of these compounds for binding to nephrotic brush border membrane.

Recently, it has been suggested that the major pathway responsible for renal uptake and accumulation of aminoglycoside is via megalin (a specific endocytic receptor and it is expressed in the renal tubule epithelium and inner ear epithelium); it is possibly responsible for the selective uptake and toxicity of aminoglycoside by these cells, therefore it was proposed that megalin could be considered a unique target for the prevention of



nephrotoxicity, The ligands binding to Megalin represent a variety of classes including calcium (Giapros&Andronikou, 2004).

The administration of aminoglycosides may induce the increase in urinary excretion of endogenous megalin ligands like calcium due to calcium competition with aminoglycosides for the binding to megalin.(Weiner *et.al.*,1997)

When a drug is bound to megalin, the aminoglycoside – megalin complex is transported inside the cell and joins to lysosomes which are the main target, since it contains 10-27% acidic phospholipids (phosphatidylinositol) where it cause progressive deposition of polar lipid forming so called myeloid body. Additionally, several other changes occurred in the organelles and enzymes, resulting in a decrease in Na-K-ATPase, adenylcyclase, mitochondrial function, ATP production, protein synthesis, solute reabsorption and over all cellular function (March *et.al* ,1983).

Amikacin shows reduced levels of binding to megalin and acidic phospholipids with a lesser inhibitory potency toward lysosomal phospholipase, due to some modification in the structure of amikacin by substitution of the amino functional group with an acyl side chain. This feature had been proved to cause less renal changes.

In a study carried out by(Viotte*et.al.*,1983) they demonstrated that the number of cationic amino group (NH<sub>3</sub>) in the structure of aminoglycosides appear to be an important determinant of nephrotoxicity. Thus, neomycin has (6) molecule producing the most renal injury. Amikacin has (4) molecule, and so produces the least renal injury .Gentamicin and tobramycin have (5) molecule, therefore produce the intermediate level of changes in the renal tissues. These structural and kinetic differences may add to discuss differences in toxic potency between tobramycin and amikacin.

The structural differences and rate of renal paranchymal accumulation between amikacin and tobramycin may contribute to interpretate nephrotoxic effect according to the dose used.

In a study carried out (Yang *et.al*,1994) they used the erythrocyte membrane model to rank the capacity of the aminoglycosides to impair phosphoinositide metabolism as follows neomycin > gentamicin > tobramycin > amikacin. The low intrinsic nephrotoxicity of amikacin reported by(Brionet*et.al.*,1985) is in agreement with the results obtained by (Reynolds *et.al.*, 1997) who on the basis of the ultra-structural and biochemical alteration observed in rats, gave the following decreasing order of toxicity gentamicin >netilimicin>tobramycin >amikacin.(Giapros&Andronikou, 2004).suggested that aminoglycoside has an effect on the function of mitochondria and encourages the formation of reactive oxygen species and lipid peroxidation of the membrane lipid,

protein denaturation and DNA damage. The presence of evidence is linked to the fact that these agents inhibit the synthesis of phospholipase A2 and glutathione and some previously tested antioxidant agents like deferoxamine, Vitamin C, and Vitamin E. These agents can reduce renal injuries cause by AGs these approaches could not be translated in to clinical application due to a lack of efficacy and /or intrinsic toxicity.

From this study it appears that tobramycin is more potent as nephrotoxic accordingly with the dose and treatment periods in rabbits while pretreatments with calcium was successfully and completely or partly ameliorate those toxic effects of both drugs.

### References:

- AL-Hamiree, J. N. (1997): Role of calcium in gentamicin toxicity in laboratory animals. Master Thesis, Collage of Veterinary Medicine, University of Baghdad.
- Ali, B. H. (2003): Agents ameliorating or augmenting experimental gentamicin Nephrotoxicity: some recent research. Food and Chem.Toxicol. 42 (3):1447-1452.
- Brion, N.; Garoud, J. J.; Faurisson, F.; Lvey, J.C. and Debach, J. C. (1985): Renal disposition of gentamicin, dibekacin, tobramycin, netilmicin and amikacin in humans. Antimicrob. Agents Chemother. .27(4):520-524.
- Chambers, H. F.; Hadly, K. and Jawatz, E. (2007): Aminoglycoside and spectinomycin 'in Basic and clinical pharmacology. 8<sup>th</sup> Ed., Bertram G. Katzung. Stamford: Appleton and Lange pp: 784-792.
- Giapros, V. I.; and Andronikou, S. K. (2004): Acute effects of gentamicin on urinary electrolyte excretion in neonates. J. Pediatr. nephrol. 19 (3):322-325.
- Levison, Matthew E. (July 2009). "Aminoglycosides: Bacteria and Antibacterial Drugs". Merck Manual Professional.
- Luna LG (1968) Manual of histologic staining methods of thearmed forces institute of pathology, 3rd edn. McGraw-Hill, New York, NY.
- March, P.; Koutouzo, A. and Giard, A. (1983): Impairment of membrane phosphoinositide metabolism by aminoglycoside antibiotics, streptomycin, amikacin, kanamycin, dibekacine, gentamicin and neomycin. J. Pharmacol. Exp. Ther. 227:415-420
- Obid, K. A. (1999): The role of calcium in antagonizing side effects of gentamicin therapy for long period in laboratory animals, Master Thesis. Collage of Veterinary Medicine / University of Baghdad.
- Rose, B. D. ;andZalenzik, D. F. (1999): Pathogenesis and prevention of aminoglycoside nephrotoxicity and ototoxicity. Am. J. Med. 80 (6):119-124.
- Reynolds, A. V.; Hamilton-Miller, J. T. andBrumfitt, W. (1997): Newer aminoglycoside amikacin and tobramycin: an *in vitro* comparison with kanamycin and gentamicin. British Med. J. 8 (3):778-780.

- Swan, S. K. (1997): Aminoglycoside nephrotoxicity. *Semin. Nephrol.* Vol. 17, No. (1):27-33
- Viotte, G.; Olier, B.; Morin, J. P. and Godin, M. (1982): Modifications functional, histological, biochemical renal comparative study of dibekacine, gentamicin and tobramycin. *Nouv. Press. Med.* 11:3419-3425.
- Weiner, N. D.; Schach, J. and Au, S. (1997): Aminoglycoside antibiotics preferentially increase permeability in phosphoinositide containing membrane. *Biochem .Biophys.* 7(1):80-86
- Yang, C. L. and DU, X. H. (1994): Mechanism of gentamicin nephrotoxicity in rats and the protective effect of zink induced metallothionin synthesis. *Nephrol. Dial. Transplant.* 91(4):135-140.