

AN INTERESTING CASE OF MALIGNANT TRANSFORMATION OF MATURE CYSTIC TERATOMA

Dr. Saranya Ravindran, MBBS, MS OG, Post graduate Student

Dr. Usha Vishwanath, MD, Prof.

Department of Obstetrics and Gynaecology,
Sri Ramachandra University, Chennai, India

Abstract

Mature cystic teratomas are common benign tumors of the ovary. They are bilateral in about 10 % of cases. Carcinoma arising from mature cystic teratomas are quite rare and amounts to 0.17 – 2 %. Malignant transformation is most commonly seen in post-menopausal age group, and these carcinomas are treated with surgical excision and adjuvant chemotherapy. In this study, we present a case of a 70 year old lady with carcinoma arising from mature cystic teratoma. She was evaluated clinically, biochemically and with imaging studies, and was taken up for staging laparotomy, Total abdominal hysterectomy with bilateral salpingo oophorectomy. Post operatively chemotherapy was given to her. Hence, this rare type of malignant transformation should be kept in mind when faced with a dermoid cyst, especially in older patients, or in patients with larger than usual cysts.

Keywords: Germ cell tumour, mature cystic teratoma, malignant transformation, staging laparotomy, adjuvant chemotherapy

1. Introduction

Germ cell tumors account approximately for 30 % of all ovarian tumors. 95 % of all germ cell tumors are mature cystic teratomas, (MCT). MCT is composed of well differentiated cell layers (ectoderm, mesoderm, endoderm), and it accounts for 10 - 20 % of all ovarian tumors in females of reproductive age group. Malignant transformation in a MCT of the ovary is rare, accounting for about 0.17 – 2 %. Most common malignancy is squamous cell carcinoma (SCC) (75%), while other malignancies are adenocarcinoma and differentiated carcinoma, sarcoma and papillary carcinoma.

2. Case Report

A 70 year old lady, P5 L5, who is post-menopausal for 20 years, came with complaints of abdominal distention for 3 months. It was associated with abdominal pain, loss of weight and appetite for 1 month. She also complained of vomiting 2 – 3 episodes/day, but there were no complaints of white discharge per vaginum or post-menopausal bleeding. On examination, she was poorly nourished. No inguinal or supraclavicular nodes felt. Vitals were stable. On palpation, a mass was felt in the lower abdomen extending up to umbilicus. It was firm, non tender and the lower border was not made out. The mass moved with respiration. Per speculum – vulva and vagina were pale, rugosity absent and her cervix appeared healthy. Per vaginum – uterine size could not be made out. A firm 22 weeks size mass felt. Bilateral fornicial fullness was present. Grooves sign could not be elicited. P/R- rectal mucosa free.

3. Investigation

Ultrasound pelvis showed a complex adnexal mass with solid cystic components seen in the pelvis measuring 9 x 7 cms with internal septations. Vascularity was seen in the cyst wall and the septations. Thus, bilateral ovaries could not be visualised separately. Minimal ascites present.

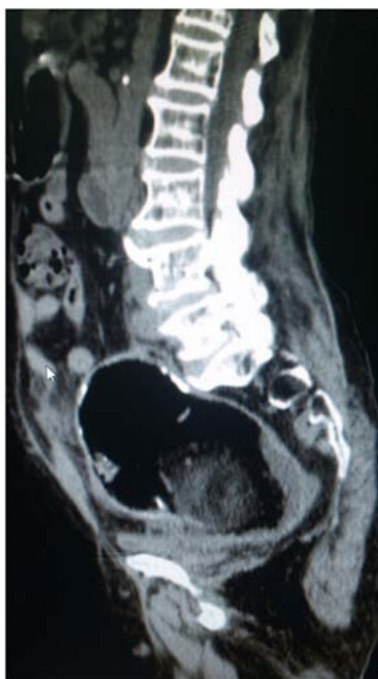

Fig 1
CT (sagittal section) of pelvis showing ovarian

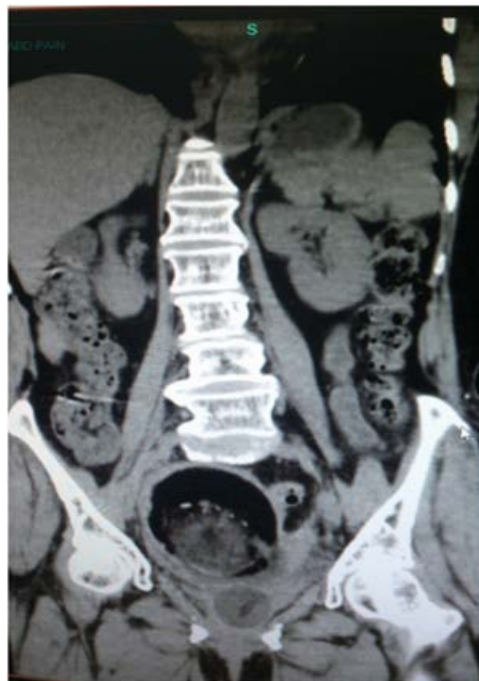

Fig 2
CT (coronal section) of Pelvis tumor

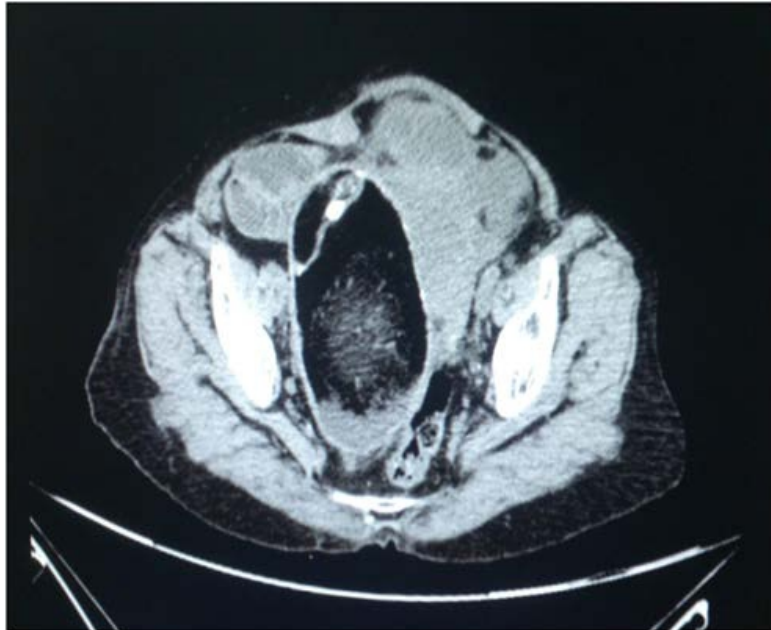

Fig 3 CT (transverse section) of pelvis.

CT pelvis showed a well differentiated thin walled lesion 10 x 7.2 x 13 cm with mixed fat and soft tissue density of 5 x 4 cm within it. These features suggest a right dermoid cyst. An ill differentiated lobulated lesion of 9 x 7 x 9 cm with solid and cystic components in the mid line of pelvis and which is slightly towards left side is seen. These features are suggestive of ovarian malignancy. (Fig 1,2,3)

Blood investigations showed normal Ca 125 value. Patient had increased BUN and creatinine values and hence diagnosed to have stage 2 CKD.

The patient was then taken up for staging laparotomy. Intraoperatively, a large dermoid cyst 10 x 10 cms with sebaceous material, hair and calcareous material was removed and was taken for frozen section. (Fig 4).Uterus was atrophic. In the left iliac region, a hard mass (3 x 4 cms) with omental adhesions was seen. It was removed and sent for frozen section. Omental biopsy was sent for histopathology. Frozen section showed features suggestive of malignancy. Hence, total abdominal hysterectomy with bilateral saphingoophorectomy was done, and the final histopathology report showed grade III T2b Nx Mo – poorly differentiated carcinoma in teratoma of ovary(Fig 5) with omental deposits and involvement of other adenexa. Oncology opinion was obtained and advised for six cycles of chemotherapy. The patient underwent only one cycle of chemotherapy with bleomycin and etoposide but did not follow up with us farther.

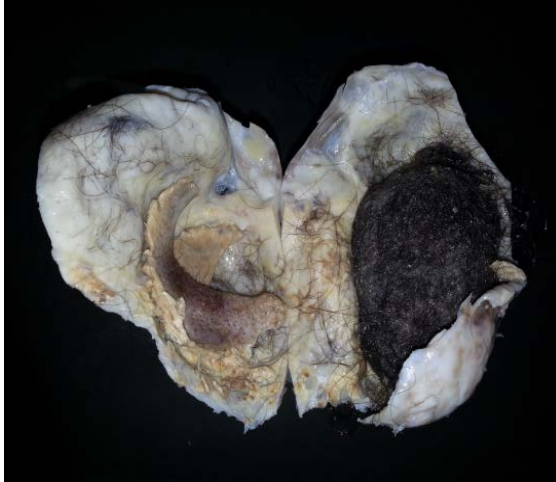

Fig 4
Gross appearance of the mature cystic teratoma showing hair and sebaceous material.

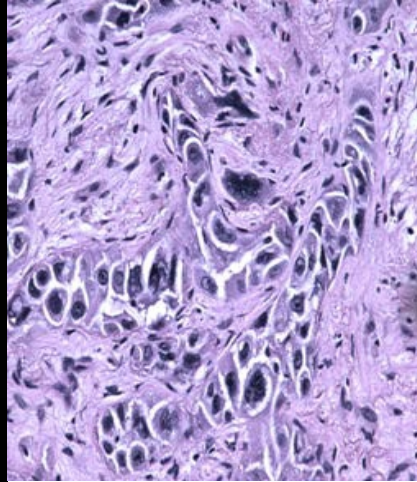


Fig 5
Microscopic appearance showing malignant cells in the tumor

4. Discussion

MCT accounts for 10–20 % of all ovarian tumors in women within the reproductive age [Kurman R.J et al 2002], while malignant transformation of mature teratoma is more common after the age of 50yrs .SCC arising from an MCT is a rare pathologic event and in most instances not diagnosed preoperatively. Thus, there are no particular signs or symptoms which are characteristic of malignancy arising in a dermoid cyst. The common symptom is abdominal pain followed by abdominal or pelvic mass, but the patients may be asymptomatic or have symptoms of abdominal distention or bloated abdomen, as those caused by benign cysts (Spannuth WA et al 2005). In some other cases, various symptoms due to invasion of nearby organs are the common complaints, and these include gastrointestinal symptoms of constipation or diarrhea, rectal bleeding, or urinary frequency (Tangjitgamol S et al 2003). Other non-specific signs of wasting disease such as weight loss or cachexia may be found in advanced cases.

Preoperative diagnosis of an MCT of the ovary is relatively easy due to the radiologic detection of bony tissues which includes teeth, bones, and cartilages.

However, preoperative diagnosis of malignant transformation is very difficult clinically, because this tumor cannot be readily differentiated from an uncomplicated MCT or other ovarian tumors (Kurman et al 2002). Since MCT is a common ovarian neoplasm and is increasingly diagnosed as an incidental finding in patients, there has been growing emphasis on preoperative risk assessment of these tumors in order to optimize surgical management. Also, there are evidence's for some risk factors for

malignancy in MCT which includes age, tumor size, and serum tumor markers.

SCC arising in an MCT has historically been observed in relatively older patients, particularly those after menopause; although, it has been sometimes reported in young patients who are around 30 years of age (Kurtz JE et al 1999, Wen KC et al 2006) or even younger (Rim SY et al 2006, Tseng CJ et al 1996). A couple of studies demonstrated the role of patient's age in differential diagnosis as it is prudent to maintain a higher suspicion of malignancy in MCTs occurring in patients over the age of 45 (Kikkawa F et al 1997).

Tumor size has also been noted to predict malignancy. Although MCT presents in a wide range of sizes, larger tumors correlate with an increased risk of malignant transformation. Kikkawa et al. reported that a tumor diameter of larger than 9.9 cm was 86% sensitive for malignancy in their series¹⁰. In general, it is recommended that a diameter equal or greater than 10 cm or a tumor arising in an ovarian MCT demonstrating rapid growth should prompt suspicion (Dos Santos et al 2007).

The prognosis for these tumors has been often reported to be very poor with a five-year survival rate of only 15 – 30%.¹ Prognostic indicators of survival have been attempted to be identified in various studies, but most of them agree that higher FIGO stages would carry a worse prognosis (Tseng et al 1996 , Kikkawa F et al 1997, Lee YC et al 1999 , Hirakawa T et al 1989).

The other potential predictors reported include rupture or spillage, (Mayer C et al 2002) tumor grade, vascular involvement, and the mode of tumor infiltration. (Kikkawa F et al 1997, Hirakawa T et al 1989).

In addition, better prognosis has been reported when the malignant element is an SCC compared with adenocarcinoma or sarcoma. The main therapeutic approach to an ovarian MCT with malignant transformation has been surgical. (Tseng et al 1996, Peterson WF et al 1957) Therefore, conservative unilateral oophorectomy without further post-operative treatment may be justified for early stage IA disease, especially for nulliparous and young patients who desire future fertility; however, in the post-menopausal women, total removal of the genital organs would seem to be the next line of action (Tseng CJ et al 1996). Post-operative treatments in the literature, includes single-agent or combination chemotherapy, radiotherapy, or a combination of these modalities. The results of these treatment regimens were variable and they have not been systemically evaluated in an adequate number. Therefore, the optimal adjuvant therapy for SCC arising from an MCT has not been yet established (Tangjitgamol S et al 2003).

5. Conclusion

In conclusion, clinicians should keep this rare type of tumour in mind when faced with a dermoid cyst, especially in older patients, or in patients with larger than usual cysts. Better prognosis has been reported in cases of SCC compared with adenocarcinoma or sarcoma [Kikkawa F et al 1998].

References:

- Curling ON, Potsides PN, Hudson CN. Malignant change in benign cystic teratoma of the ovary. *Br J Obstet Gynaecol.* 1979; 86: 399 – 402.
- Dos Santos L, Mok E, Iasonos A, Park K, Soslow RA, Aghajanian C, et al. Squamous cell carcinoma arising in mature cystic teratoma of the ovary: a case series and review of the literature. *Gynecol Oncol.* 2007; 105: 321 – 324.
- Hirakawa T, Tsuneyoshi M, Enjoji M. Squamous cell carcinoma arising in mature cystic teratoma of the ovary. Clinicopathologic and topographic analysis. *Am J Surg Pathol.* 1989; 13: 397 – 405
- Kashimura M, Shinohara M, Hirakawa T, Kamura T, Matsukuma K. Clinicopathologic study of squamous cell carcinoma of the ovary. *Gynecol Oncol.* 1989; 34: 75 – 79.
- Kikkawa F, Ishikawa H, Tamakoshi K, Nawa A, Suganuma N, Tomoda Y. Squamous cell carcinoma arising from mature cystic teratoma of the ovary: a clinicopathologic analysis. *Obstet Gynecol.* 1997; 89: 1017 – 1022.
- Kikkawa F, Nawa A, Tamakoshi K, Ishikawa H, Kuzuya K, Suganuma N, et al. Diagnosis of squamous cell carcinoma arising from mature cystic teratoma of the ovary. *Cancer.* 1998; 82: 2249 – 2255.
- Kurman R J. *Blaustein's Pathology of the Female Genital Tract.* 5th ed. New York: Springer Verlag; 2002.
- Kurtz JE, Jaeck D, Maloisel F, Jung GM, Chenard MP, Dufour P. Combined modality treatment for malignant transformation of a benign ovarian teratoma. *Gynecol Oncol.* 1999; 73: 319 – 321.
- Lee YC, Abulafia O, Montalto N, Holcomb K, Matthews R, Golub RW. Malignant transformation of an ovarian mature cystic teratoma presenting as a rectal mass. *Gynecol Oncol.* 1999; 75: 499 – 503.
- Mayer C, Miller DM, Ehlen TG. Peritoneal implantation S. Shariat-Torbaghan, M. Emami-Aleagha, S. Sedighi, et al. Archives of Iranian Medicine, Volume 12, Number 2, March 2009 189 of squamous cell carcinoma following rupture of a dermoid cyst during laparoscopic removal. *Gynecol Oncol.* 2002; 84: 180 – 183.
- Peterson WF. Malignant degradation of benign cystic teratomas of the ovary: a collective review of the literature. *Obstet Gynecol Surv.* 1957; 12: 793 – 820

- Rim SY, Kim SM, Choi HS. Malignant transformation of ovarian mature cystic teratoma. *Int J Gynecol Cancer*. 2006; 16: 140 – 144.
- Spannuth WA, Rocconi RP, Kirby TO, Huh WK, Conner MG. Gamma mode of infiltration associated with poor prognosis in malignant teratoma of the ovary: a case report. *Gynecol Oncol*. 2005; 98: 155 – 157.
- Tangjitgamol S, Manusirivithaya S, Sheanakul C, Leelahakorn S, Thawaramara T, Jesadapatarakul S. Squamous cell carcinoma arising from dermoid cyst: case report and review of the literature. *Int J Gynecol Cancer*. 2003; 13: 558 – 563.
- Tseng CJ, Chou HH, Huang KG, Chang TC, Liang CC, Lai CH, et al. Squamous cell carcinoma arising in mature cystic teratoma of the ovary. *Gynecol Oncol*. 1996; 63: 364 – 370.
- Wen KC, Hu WM, Twu NF, Chen P, Wang PH. Poor prognosis of intraoperative rupture of mature cystic teratoma with malignant transformation. *Taiwan J Obstet Gynecol*. 2006; 45: 253–256.