

*African Journal of Pharmacology and Therapeutics* Vol. 4 No. 3 Pages 112-117, 2015

Open Access to full text available at <http://journals.uonbi.ac.ke/ajpt>

## Research Article

# Influence of *Aspilia pluriseta* Schweinf (Asteraceae) on the healing of dermal excision wounds (mouse model) and skin sensitization activity (Guinea pig model)

James M. Kuria <sup>a,\*</sup>, James M. Mbaria <sup>b</sup>, Peter K. Gathumbi <sup>c</sup>, and Stephen G. Kiama <sup>d</sup>

<sup>a</sup> Centre for Traditional Medicine and Drug Research, Kenya Medical Research Institute, Kenya

<sup>b</sup> Department of Public Health, Pharmacology and Toxicology, University of Nairobi, Kenya

<sup>c</sup> Department of Veterinary Pathology, Microbiology and Parasitology, University of Nairobi, Kenya

<sup>d</sup> Wangari Maathai Institute for Peace and Environmental Studies, University of Nairobi

\* **Corresponding author:** Centre for Traditional Medicine and Drug Research, Kenya Medical Research Institute, P. O. Box 54840-00200, Nairobi, Kenya; **Tel:** +254-20-2722541; **Fax:** +254-20-2720030; **Email:** [jkuria@kemri.org](mailto:jkuria@kemri.org)

**Background:** The skin is highly predisposed to injury because of its direct contact with the environment. The aim of treating of wounds is to both hasten healing, and to minimise the occurrence of perturbations of the healing process. Many plants traditionally used to treat wounds have been proven to support the healing process using scientific models. *Aspilia pluriseta* has been used by a number of communities in East and Southern Africa to treat wounds.

**Objectives:** This study aimed at testing ethnomedical claims of wound healing activity of *A. pluriseta* using preclinical models.

**Methods:** Aerial parts of the plant were ground and incorporated into an ointment base (10% and 20% w/w) to evaluate the influence of the plant on the healing of acute excision wounds in mice compared to Silverex Cream<sup>®</sup> and Simple Ointment (B.P.). The 20% ointment was tested for skin sensitization in guinea pigs.

**Results:** The effects of the plant-based ointments on wound contraction and gross epithelialisation time were less than significantly different from the controls ( $p \geq 0.05$ ), but histopathologic examination revealed remarkable epithelialisation and collagen deposition in the wounds treated with the these ointments. The 20% *A. pluriseta*-based ointment induced moderate allergic contact dermatitis.

**Key words:** *Aspilia pluriseta*, wound healing, skin sensitization, excision wound model

**Received:** January, 2015

**Published:** September, 2015

## 1. Introduction

A wound is an injury that results from the disruption of the normal tissue anatomy and function. It may result in a break of the epithelium with or without loss of underlying connective tissue. Wounds may result from physical, chemical, microbial agents or immunological mechanisms (Raina et al, 2008). Wound healing is the process through which the wound tissue is restored as

closely as possible to its pre-injury state and is the result of interaction between cells, blood and connective tissue components directed by growth factors and cytokines. It is characterized by three major phases, inflammation, proliferation and remodelling which are distinct but overlap in time (Singer and Clark 1999). Cutaneous wounds primarily heal by three mechanisms: connective tissue matrix deposition, contraction and epithelialisation (Diegelmann and

Evans 2004). The primary objective in the treatment of wounds is to hasten wound closure and to achieve a functional and cosmetic scar (Singer and Clark 1999).

When a wound results, the possible outcomes are normal healing, excessive healing or deficient healing. Normal wound healing is the typical repair response, while excessive or deficient healing is considered a pathologic response (Diegelmann and Evans 2004). Dermal wounds primarily heal by deposition of a connective tissue matrix, contraction and epithelialisation (Diegelmann and Evans 2004). Wounds with regular margins, for instance surgically created wounds, whose margins are then brought in close apposition for example by use of staples or sutures, heal by primary intention. This involves the deposition of connective tissue ground substance and connective tissue matrix. Wounds that remain open heal by contraction. This is postulated to be the result of the activity of contractile fibroblasts (myo-fibroblasts) (Tomasek et al, 2002).

The primary goal in the treatment of wounds is to hasten their closure and to achieve a functional and aesthetically acceptable scar (Singer and Clark 1999). The 'ideal' wound healing agent should facilitate granulation, enhance immunity, aid in debridement, control infection, reduce pain and discomfort and promote angiogenesis and perfusion (Gilchrist 1994). It should also be affordable, easy to both apply and remove, and cause minimal patient discomfort (Nilesh Gupta 2010). The complexity of the wound healing process has acted as a hindrance to the development of modern pharmacological agents that augment healing (Pierce and Mustoe 1995). Some alternative therapies, particularly herbal products have been claimed to closely approximate the ideal wound healing agent (Nilesh Gupta 2010). In addition to this, herbal wound healing products are cheaper than conventional counterparts, purportedly safer and elicit fewer hypersensitivity reactions (Nilesh Gupta 2010). *In vivo* models of wound healing have been used to test and confirm the wound healing activity of many plants that are reported in ethnomedical/ethnobotanical surveys to have been used to treat wounds (Ayyanar and Ignacimuthu 2009).

*Aspilia pluriseta*, commonly known as *dwarf aspilia* is a perennial, woody herb with multiple branches from a woody rootstock and with yellow flower-heads. It is a plant of open woodland and grassland, especially areas with black cotton soils (Gachathi 2007). It is native to areas of East, Central and Southern Africa in an altitude range between 1360 and 1560 meters above sea level. The plant has a number of documented ethnomedical uses in Kenya, including the treatment of wounds and pimples (Gachathi 2007; Njoroge and Busmann 2007), coughing and otitis media (Njoroge and Busmann 2006), eye conditions (Gachathi 2007) and Diabetes Mellitus (Piero and N Joan 2011).

The primary objective of this study was informed by the need for pharmacological and toxicological testing of traditional remedies before recommending them for therapy (Nilesh Gupta 2010; Midiwo et al, 2001). We evaluated the effects of the ointment containing powdered aerial parts of *A. pluriseta* on selected

processes of excision wound healing and dermal safety, specifically allergy induction.

## 2. Materials and Methods

### 2.1 Plant material

*Aspilia pluriseta* aerial parts (stems, leaves and flower heads) were collected in Ruiru, Kiambu County in the month of January, 2012. The identity of the plant was confirmed by the East Africa Herbarium where a voucher specimen was deposited (Voucher no: Kuria/Asp/001). The plant material was cleaned with tap water and then dried in the shade for 10 days, then ground using an electric mill.

### 2.2 Preparation of the ointments

The powdered *A. pluriseta* was triturated into an ointment base (Simple Ointment B.P) to form a 10% and 20% (w/w) *A. pluriseta* ointment for testing.

### 2.3 Excision wound healing assay

Four month old, male, Swiss Albino mice were purchased from the Kenya Agricultural Research Institute (KARI) Trypanosomiasis Research Centre. The animals were allowed 7 days to acclimatize to conditions at the animal house in the Department of Public Health, Pharmacology and Toxicology, University of Nairobi. They were fed standard pelleted feed (Unga Mice Pencils, Unga Feeds) and water *ad libitum*.

The excision model was used to provide information on wound contraction, epithelialisation and histologic data. The backs of the mice were shaved using an electric clipper. The shaved area was disinfected using povidone iodine. A square area, approximately 100mm<sup>2</sup> was marked on the dorsum using a stencil. Full thickness excision wounds were created using thumb forceps and scissors along the edges of the marked areas (Yadav et al, 2014). The excision wounds were created with the mice under halothane anaesthesia. The mice were then randomly divided into four groups each having eight members. The first two groups were treated with the 10% and 20% *A. pluriseta* ointment. The third group was treated with the vehicle ointment (Simple Ointment B.P.) and acted as the negative control group. The fourth group was treated with a standard wound drug, Silverex Cream® (Ranbaxy) containing 1% silver sulfadiazine. The wounds were left open (Süntar et al, 2011) and treated once daily for 21 days. Before the application of the respective treatment, the wounds were cleaned with antiseptic solution. The wounds were observed daily over the test duration. Any hair growing over the wound area was trimmed to facilitate observation. The time it took for each wound to be fully covered by an epithelium (time when the scab fell off without leaving a raw area) was recorded for each animal. The wound margins were traced onto tracing paper for area determination after wound creation. Wound areas were estimated by the use of 1mm<sup>2</sup> graph paper (Yadav et al, 2014). Wound contraction was tracked by determining the wound area every three days until the wounds were fully re-epithelialised grossly. Wound contraction was calculated as percent reduction of wound area relative to the initial wound area on the day of wounding (initial wound area = 100%).

On the 7<sup>th</sup> and 14<sup>th</sup> days, a representative animal from each group was sacrificed and a biopsy of the wound harvested for histology. On the 21<sup>st</sup> day, all the animals were euthanized using halothane and histopathology samples were harvested from all the animals. The harvested samples were fixed in 10% formalin, processed routinely and blocked with paraffin wax. Serial sections, 5µm thick were cut with a microtome and then stained with Hematoxylin and Eosin and Masson's Trichrome (Nisbet et al, 2010). The stained sections were examined using a light microscope. The selected histologic parameters (neutrophil population, macrophage population, fibroblast population, collagen deposition, vascularisation and epithelialisation) were evaluated qualitatively and scored into three categories, +, ++ and +++, representing increasing magnitude of each respective parameter.

## 2.4 Skin sensitization assay

This was carried out along OECD Test Guideline 406 (Buehler Non-adjuvant test method) (OECD 1992) with modifications on the number of animals and the use of an occlusive patch. 3 female adult (3 months old) albino guinea pigs were used. A 4cm<sup>2</sup> square area was marked on the right posterior flank which was earlier shaved, about 1cm from the dorsal midline and a film of the 20% *A. pluriseta* ointment was applied on it. This application was repeated on the 7<sup>th</sup> and 14<sup>th</sup> days and constituted the induction phase of the trial. On the 28<sup>th</sup> day, the left side, equally shaved and marked was used for challenge phase.

Six hours after the application of the ointment on the new site, the residual ointment was wiped off using moist cotton wool. 24 hours later, the site was observed for a skin reaction, and the lesions scored. Challenge exposure was repeated again on the left side on the 35<sup>th</sup> day to confirm the observations made on after the first challenge exposure.

## 2.5 Data analysis

Means ( $\pm$ SEM) were computed for measures of wound contraction and epithelialisation times. The means for the four treatment groups were compared with each other using one-way Analysis of Variance (ANOVA). P values  $\leq 0.05$  were considered significant. The histology and skin sensitization data were not subjected to statistical analysis.

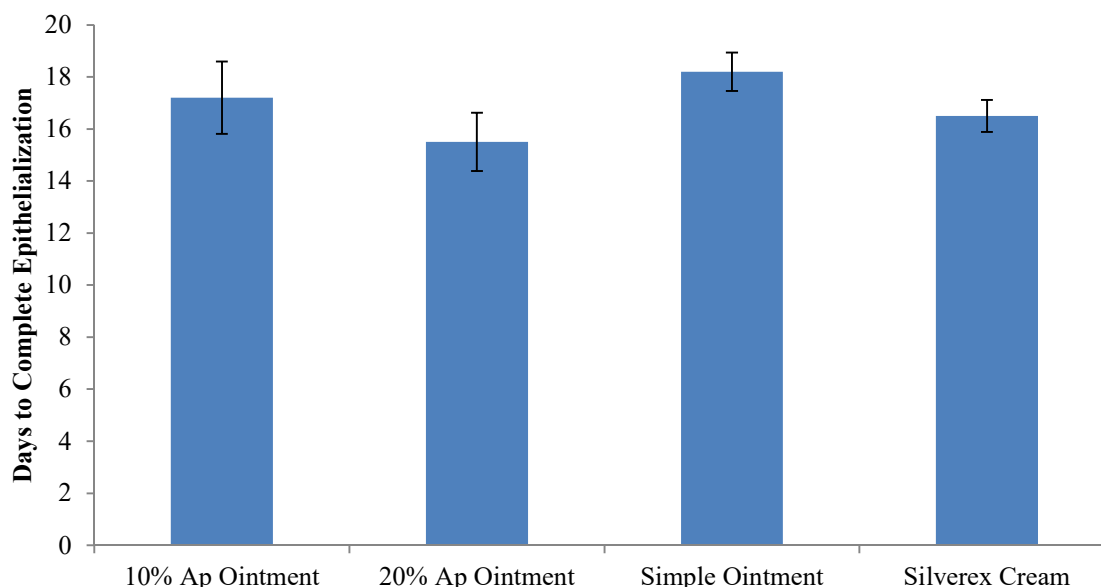
## 2.6 Ethical considerations

The animals used in these assays were handled humanely at all times in accordance with animal care and use guidelines of the University of Nairobi and other applicable guidelines and regulations.

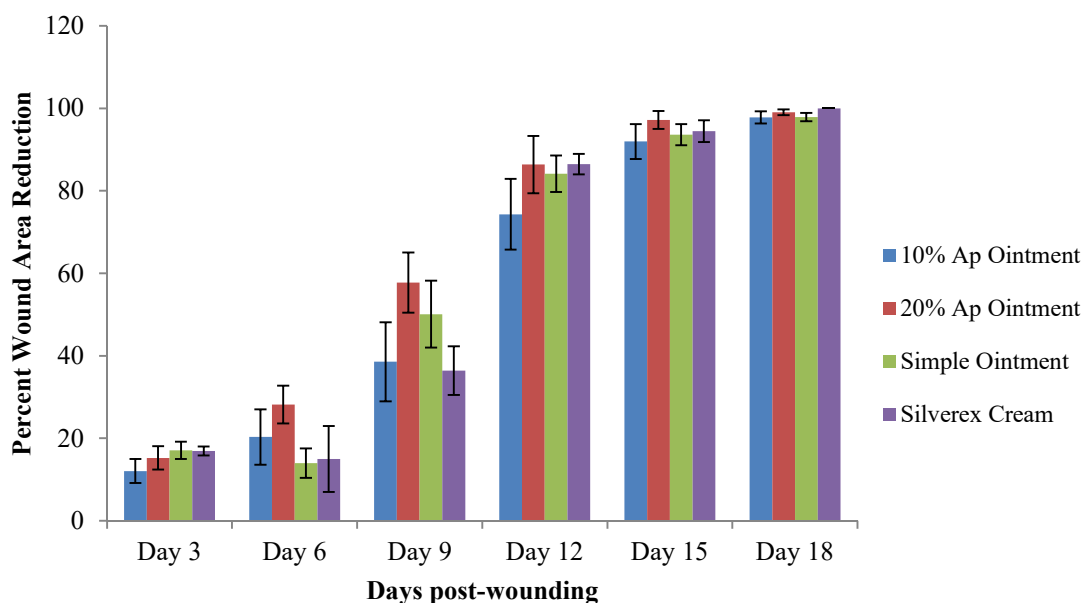
## 3. Results

### 3.1 Epithelialisation time

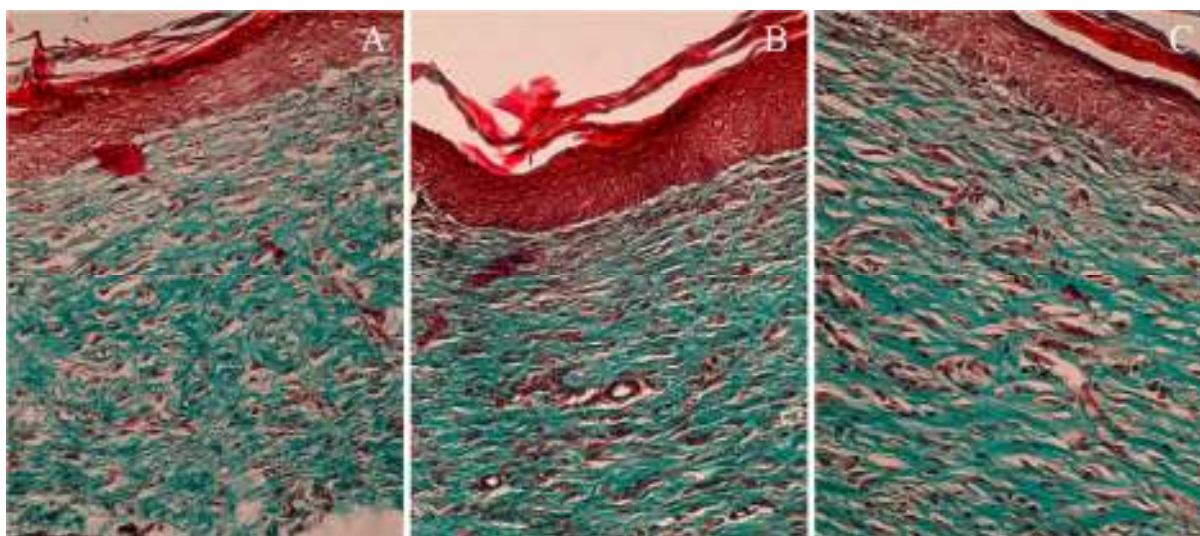
The 20% *A. pluriseta* treated group took less time than the other groups to fully epithelialise as shown in **Figure 1**. The difference in the mean epithelialisation time was however not statistically significant.



**Figure 1:** Graph showing the epithelialisation time (mean number of days  $\pm$  SEM (standard error of mean)) for the different treatments from left to right: 10% *A. pluriseta* ointment, 20% *A. pluriseta* ointment, Simple Ointment (negative control) and Silverex Cream (reference drug).



**Figure 2:** Graph showing the wound contraction rates for the different groups (percent wound area reduction  $\pm$  SEM)



The collagen (green in colour) in image A is sparse and disorganized; that in image B is densely laid down and oriented in a general direction, similar to but more than is seen in image C. Also, the neo-epidermis (red in colour) in image B is compact and there is little delineation between individual cells as opposed to images A and C.

**Figure 3:** Photomicrographs showing comparison of extent of collagen lay-down and epithelialisation between the Simple Ointment B.P. (negative control) (A), the 10% *Aspilia pluriseta* ointment (B) and the Silverex Cream® (standard drug) (C) groups (Day 21,  $\times 400$ , Masson's Trichrome stain).

### 3.2 Wound contraction

The 20% *A. pluriseta* ointment showed marginally higher contraction (assessed as percent wound area reduction) towards the end of the first week and during the second week of healing. However, the difference in wound contraction rates between the test and the control groups was not statistically significant. All the wounds were fully closed (100% wound area

reduction) on day 21. The wound contraction results are shown in **Figure 2**.

### 3.3 Histology

In the first week of healing, the wounds that were treated with the *A. pluriseta* ointments had intensive granulation as opposed to the negative control group which had thinly deposited granulation tissue. Also, the

*A. pluriseta* ointment and the standard drug treated wounds had more mature fibroblasts than the negative control group. On Day 14 of healing, all the wounds except those treated with the 20% *A. pluriseta* ointment had haemorrhage. The *A. pluriseta* ointment treated wounds had more collagen, comparable to the standard drug treated wounds and more than the negative control group. At the end of the experiment on the 21<sup>st</sup> day, the *A. pluriseta* ointment treated wounds had fully epithelialised. They also had abundant collagen and a diminished number of blood capillaries. The histology results are summarised in **Table 1** and **Figure 3**.

### 3.4 Skin sensitization

The 20% *A. pluriseta* ointment induced moderate allergic reaction after the challenge exposure on the 28<sup>th</sup> day which was indicated by a confluent erythema on the skin area used for challenge exposure. The erythema persisted for approximately 48 hours and then resolved on its own. This exposure was repeated 7 days later (35 days after the first application) to confirm the results obtained, and similar observations were made.

**Table 1:** Summary of the histological observations

Parameter	Group	Day/Score		
		Day 7	Day 14	Day 21
<b>Neutrophils</b>	10% <i>A pluriseta</i>	+++	+++	+
	20% <i>A pluriseta</i>	+++	++	+
	Simple ointment	+++	+++	+
	Silverex® Cream	++	+++	+
<b>Macrophages</b>	10% <i>A pluriseta</i>	+	++	++
	20% <i>A pluriseta</i>	+	++	+
	Simple ointment	+	++	++
	Silverex® Cream	++	++	++
<b>Fibroblasts</b>	10% <i>A pluriseta</i>	+	+	+++
	20% <i>A pluriseta</i>	+	++	+++
	Simple ointment	+	+	+
	Silverex® Cream	+	++	+++
<b>Collagen</b>	10% <i>A pluriseta</i>	+	+	++
	20% <i>A pluriseta</i>	+	++	+++
	Simple ointment	+	+	++
	Silverex® Cream	+	++	+++
<b>Vascularisation</b>	10% <i>A pluriseta</i>	+++	++	++
	20% <i>A pluriseta</i>	+++	++	+
	Simple ointment	++	++	+++
	Silverex® Cream	+++	+++	++
<b>Epithelialisation</b>	10% <i>A pluriseta</i>	+	+	++
	20% <i>A pluriseta</i>	+	+	+++
	Simple ointment	+	+	++
	Silverex® Cream	+	+	+++

## 4. Discussion

*Aspilia pluriseta* at 10% and 20% concentration in simple ointment was observed to have an effect on the contraction, granulation and epithelialisation of

excision wounds in a mouse model. It also induced allergic dermatitis in guinea pigs as evidenced by development of erythema on repeated application. The observed effects on the process of wound healing are in agreement with the observations made in similar

studies on the wound healing activity of plants (Yadav et al, 2014). The wound healing activity is similar to that reported by Okoli, Akah, and Okoli (2007) who reported enhancement of epithelialisation of excision wounds by the methanol extract of *Aspilia africana*, a member of the same genus as the test plant, *A. pluriseta*. The extent to which *Aspilia pluriseta* promoted wound contraction and gross epithelialisation was less than significantly different from the controls, as opposed to the measures of the same parameters in like studies. This observation may be explained by the fact that in this study, whole plant material was used as opposed to aqueous and organic solvent extracts from plant tissue in other studies. The allergy inducing activity is in agreement with the findings of other studies, that plants in family *Asteraceae* (formerly *Compositae*) readily induce allergic contact dermatitis due to sesquiterpene lactones in these plants' tissues (Jovanović and Poljacki 2003).

The observed activity of *Aspilia pluriseta* on wounds is in agreement with other studies on the effect of medicinal plants in the healing of wounds. The wound healing enhancement that was observed in this project is similar to that seen in other experiments on *in vivo* support of wound healing by plant extracts (Kumar et al, 2007).

The findings of this study point to a multi-pronged enhancement of healing by *A. pluriseta* ointments. The plant material supported early polymorphonuclear inflammation, while at the same time allowing the recruitment of wound macrophages. It also induced or supported an early intensive granulation with numerous and more mature fibroblasts. Moreover, the plant-based ointments seemed to enhance collagen synthesis and deposition. Sections from groups treated with the ointments were more fibrotic than those from the control groups. Also, the *A. pluriseta* ointments promoted more epidermal remodelling.

## 5. Conclusion

In view of these observations, we confirm the wound healing activity of *A. pluriseta* reported ethnomedically. Further research is needed to determine the exact mechanism of action of the plant in the healing process of wounds. Development of a drug for treating acute wounds from the plant should be explored. The allergenic potential of the plant should be borne in mind during use of the plant or products derived from it.

## Conflict of Interest declaration

The authors declare no conflict of interest.

## Acknowledgements

The authors are grateful to University of Nairobi and RISE-AFFNET, Carnegie Corporation for their support of this work.

## References

Ayyanar M and Ignacimuthu S (2009). Herbal Medicines for Wound Healing among Tribal People in Southern India: Ethnobotanical and Scientific Evidences. *Int. J. Appl. Res. Nat. Prod.* 2: 29-42.

Diegelmann RF and Evans MC (2004). Wound Healing: An Overview of Acute, Fibrotic and Delayed Healing. *Front. Biosci.* 9: 283-289.

Gachathi M (2007). *Kikuyu Botanical Dictionary*. Revised 2nd Edition. Tropical Botany.

Gilchrist B (1994). Treating Bacterial Wound Infection. *Nurs. Times* 90: 55-58.

Jovanović M and Poljacki M (2003). Compositae dermatitis. *Medicinski prehled* 56: 43-49.

Kumar B, Vijayakumar M, Govindarajan R and Pushpangadan P (2007). Ethnopharmacological Approaches to Wound Healing—exploring Medicinal Plants of India. *J. Ethnopharmacol.* 114: 103-113.

Midiwo JO, Yenesew A, Juma BF, Kerubo LO, Omosa IL, and Mutisya D. (2001). Phytochemical Evaluation of Some Kenyan Medicinal Plants. In *11th NAPRECA Symposium Book of Proceedings, Antananarivo, Madagascar*, 9-19. <http://www.napreca.net/publications/11symposium/pdf/B-9-19-Midiwo.pdf>.

Nilesh Gupta (2010). Prominent Wound Healing Properties of Indigenous Medicines. *J. Nat. Pharm.* 1: 2-13.

Njoroge GN and Bussmann RW (2006). Traditional Management of Ear, Nose and Throat (ENT) Diseases in Central Kenya. *J. Ethnobiol. Ethnomed.* 2: 54.

Njoroge GN and Bussmann RW (2007). Ethnotherapeutic Management of Skin Diseases among the Kikuyus of Central Kenya. *J. Ethnopharmacol.* 111: 303-307.

OECD. 1992. *Test No. 406: Skin Sensitisation*. Paris: Organisation for Economic Co-operation and Development. <http://www.oecd-ilibrary.org/content/book/9789264070660-en>.

Okoli CO, Akah PA, and Okoli AS. (2007). Potentials of Leaves of *Aspilia africana* (Compositae) in Wound Care: An Experimental Evaluation. *BMC Complement. Altern. Med.* 7: 24.

Nisbet O, Hatice, Nisbet C, Yarim M, Guler A, and Ozak A. (2010). Effects of Three Types of Honey on Cutaneous Wound Healing. *Wounds* 22: 275.

Pierce GF and Mustoe TA. (1995). Pharmacologic Enhancement of Wound Healing. *Annu. Rev. Med.* 46: 467-481.

Piero Ngugi M and Murugi NJ. (2011). Hypoglycemic Activity of Some Kenyan Plants Traditionally Used to Manage Diabetes Mellitus in Eastern Province. *J. Diabetes Metab.* 02. doi:10.4172/2155-6156.1000155.

Raina R, Parwez S, Verma PK and Pankaj NK. (2008). Medicinal Plants and Their Role in Wound Healing. *Online Vet. J.* 3: 21.

Singer AJ and Clark RAF (1999). Cutaneous Wound Healing. *New Engl. J. Med.* 341: 738-46.

Süntar I, Koca U, Keles H, and Küpeli Akkol E (2011). Wound Healing Activity of *Rubus Sanctus* Schreber (Rosaceae): Preclinical Study in Animal Models. *Evid. Based Complement. Alternat. Med.* 2011: 1-6.

Tomasek JJ, Gabbiani G, Hinz B, Chaponnier C and Brown RA (2002). Myofibroblasts and Mechano-Regulation of Connective Tissue Remodelling. *Nature Rev Mol. Cell Biol.* 3: 349-63.

Yadav KS, Yadav NP, Rawat B, Rai VK, Shanker K and Rao CV (2014). An Assessment of Wound Healing Potential of *Argyrea Speciosa* Leaves. *Sci. World J.* 2014: 1-6.