

African Journal of Pharmacology and Therapeutics Vol. 6 No. 2 Pages 88-95, 2017

Open Access to full text available at <http://www.uonbi.ac.ke/journals/kesobap/>

Research Article

Evaluation of hepatoprotective activity of methanol stem bark extract of *Haematostaphis barteri* Hook. F. against paracetamol and carbon tetrachloride-induced liver injury in rats

Nuhu Mohammed ^{a,*}, Abdullahi H. Yaro ^a, and Abdullahi B. Nazifi ^a

^a *Department of Pharmacology and Therapeutics, Bayero University, Kano, Nigeria*

* **Corresponding author:** Department of Pharmacology and Therapeutics, Bayero University, P.M.B. 3011, Kano, Nigeria; **Tel:** +234-806-9675540; **Email:** nuhumhd@yahoo.com

Background: The ethnomedical uses of *Haematostaphis barteri* commonly known as blood plum has been documented in literature. The efficacy of its stem bark extract in management of liver diseases is well acclaimed among communities of Northern Nigeria.

Objective: To evaluate the hepatoprotective activity of methanol stem bark extract of *Haematostaphis barteri* against paracetamol and carbon tetrachloride (CCl₄)-induced hepatotoxicity in Wistar rats.

Methodology: Phytochemical and acute toxicity studies were carried out. Liver damage was induced in different groups of Wistar rats using paracetamol (3 g/kg) and 1 ml/kg of CCl₄ (1:1 in olive oil). The effect of *Haematostaphis barteri* extract was tested for hepatoprotective activity by evaluating serum biochemical parameters and liver histology. The extract was also tested for antioxidant activity using *in-vitro* DPPH free radical scavenging method.

Results: Phytochemicals present include tannins, sterols, alkaloids, saponins, triterpenes, flavonoids and anthraquinones. Oral median lethal dose was estimated to be >5000 mg/kg. Pre-treatment with the extract (250, 500 and 1000 mg/kg) significantly ($p < 0.05$) reduced alanine aminotransferase and alkaline phosphatase levels compared to paracetamol and CCl₄ toxic groups respectively. These results were supported by the protection against hepatocellular necrosis in the extract treated groups as well as the DPPH radical scavenging activity.

Conclusion: The results obtained suggest the stem bark extract of *Haematostaphis barteri* possesses hepatoprotective activity.

Keywords: *Haematostaphis barteri*, Hepatoprotective, Paracetamol, Carbon tetrachloride

Received: March, 2017

Published: June, 2017

1. Introduction

The liver is the second largest organ in human body and has metabolic, secretory, synthetic, excretory and storage functions (Kandimalla et al, 2016). It is involved in the metabolism of drugs, toxins and food substances which makes it vulnerable to a wide variety of metabolic, toxic, microbial, circulatory and neoplastic insults (Crowford, 2004; Nirmala et al, 2012). Liver

disease is a major cause of morbidity and mortality among human population and has a worldwide distribution (Mnddrey, 2001). The dominant primary diseases of the liver are viral hepatitis, alcoholic liver disease, and hepatocellular carcinoma (Crowford, 2004; Nirmala et al, 2012). Treatment of liver diseases are associated with many problems; the conventional drugs used are not only inadequate but associated with serious adverse effects (Porceddu et al, 2012). In view

of the limited treatment options and significant adverse effects associated with the conventional drugs, novel prophylactic and therapeutic agents against liver diseases are urgently needed (Hong et al, 2015).

Medicinal plants have been widely used by urban and rural populations in treating various diseases including liver problems (Jordan et al, 2010, Wang et al, 2012). The World Health Organization has recognized the fact that about 80% of the population in developing countries rely on traditional medicine for their healthcare needs (WHO, 2013). This can be explained due to the fact that traditional medicine is more affordable, accessible and culturally acceptable in many parts of the world.

Haematostaphis barteri is a member of Anacardiaceae family, a perennial tree that grows up to 8 meters high by 65 cm girth. It is found in dry Savannah from Upper Volta to Nigeria and also in Cameroun and Sudan. It is commonly known as blood plum in English and the vernacular names include *Tsamiyar lamarudu* (in Hausa) and *Tursuhi* or *Tursahi* (in Fulfulde). It is used by communities of Northern Nigeria in the treatment of liver diseases (Burkill, 1985). Decoction of the stem bark is orally taken mostly by people of Northern Nigeria to cure diseases such as hepatitis and sleeping sickness (Abubakar et al, 2014; Boampong et al, 2015). Previous studies on *H. barteri* showed that the seeds contain unsaturated higher fatty acids (Eicosadienoic and Erucic acid) (Eromosele and Eromosele, 2002) as well as saturated fatty acids. The fruit extract of *H. barteri* was reported to cause an increase in haemoglobin concentration, packed cell volume and erythrocytes count in albino rats (Abubakar et al, 2014), while the aqueous stem bark extract possesses curative and prophylactic antimalarial activities as well as antioxidant properties (Boampong et al, 2015). To our knowledge, the hepatoprotective potentials of the stem bark extract has not been scientifically validated and therefore, this study was aimed at evaluating the hepatoprotective properties of the methanol stem bark extract of *H. barteri* against paracetamol and carbon tetrachloride (CCL₄)-induced liver damage in Wistar rats.

2. Materials and Methods

2.1 Drugs and Chemicals

Analar grade paracetamol powder (Sigma Chemicals Co, USA), Carbon tetrachloride (BDH Ltd Poole, England), Silymarin (Micro Labs Limited, India), Olive oil (Metaluni S.P.A., Italy), Normal saline (0.9% w/v NaCl Isotonic Solution) (Dana Pharmaceuticals Limited, Nigeria), 1,1-diphenyl-2-picrylhydrazyl radical (DPPH) powder (Sigma Chemicals Co, USA), Substrate and buffer solutions (Randox, UK)

2.2 Experimental animals

Wistar albino rats 180-220 g of either sex were obtained from the animal facility of Department of Pharmacology and Therapeutics, Bayero University, Kano. The rats were kept in plastic rat cages with metal coverlids and soft wood shavings as bedding material. They were placed on commercial rat feed (Vital feed®, Kano) and water *ad libitum* and maintained in well

ventilated room under natural light and dark cycle. All experiments performed on the laboratory animals were approved by the University Animal Ethics Committee.

2.3 Plant Material

Haematostaphis barteri stem bark was collected in July, 2014 from Hanwa area of Sabon Gari Local Government, Kaduna State. The plant was identified and authenticated by a taxonomist, Mr. Musa Muhammad of the Department of Biological Sciences, Ahmadu Bello University Zaria. A specimen number **2796** was assigned and a voucher specimen was deposited in the Herbarium section of the department for future reference.

2.4 Preparation of plant extract

The stem bark of *Haematostaphis barteri* was air dried under shade and then mechanically powdered using pestle and mortar. The methanol stem bark extract was prepared by subjecting 1280 g of the powdered bark to maceration using 10 liters of 70% v/v methanol (in 30% water) followed by intermittent stirring for 72 hrs. The macerate was filtered using Whatman filter paper (No. 1) and the filtrate obtained was concentrated over a water bath maintained at 50 °C until extraction solvent was completely dry. The extract was then stored in a desiccator until required in the main study.

2.5 Phytochemical screening

Basic phytochemical screening tests were carried out on the stem bark extract of *Haematostaphis barteri* using standard procedures to identify its phytochemical constituents (Evans, 2002).

2.6 Acute toxicity study

Oral acute toxicity testing of the extract was carried out in rats according to Lorke's method (1983). The study was in two phases; in the first phase, three groups of three rats each received 10, 100 and 1000 mg/kg of the extract. The rats were observed for signs of toxicity and death for 24 hrs. In the second phase, three rats were used and each was administered 1600, 2900 and 5000 mg/kg of the extract. The rats were also observed for signs of toxicity and death for 24 hrs. Thereafter, the oral median lethal dose (LD₅₀) was estimated as the geometric mean of the lowest lethal dose and the highest non-lethal dose.

2.7 Assessment of hepatoprotective activity

Paracetamol-induced hepatotoxicity

The method described by Ajith et al, (2007) was adapted with some modifications. In this study, thirty rats were divided into 6 groups of 5 rats each. Group I rats (Normal control) received normal saline, 1 ml/kg, *p.o.* for 5 days. Group II rats (Toxic control) received paracetamol (3 g/kg, *p.o.*) on the 4th day. Group III (Standard) was treated with standard drug silymarin (100 mg/kg *p.o.*) for 5 days and on the 4th day, paracetamol (3 g/kg, *p.o.*) was given 1 hour after the treatment with silymarin. Groups IV, V and VI were treated with the extract (at doses of 250, 500 and 1000 mg/kg respectively) *p.o.* daily for 5 days and on the 4th

day paracetamol (3 g/kg, *p.o.*) was given 1 hour after treatment with the extracts. All the animals were sacrificed 48 hours after the dose of paracetamol under mild chloroform anaesthesia. The blood samples were collected in plain sample bottles and then centrifuged at a speed of 4000 revolutions per minute to separate the serum. The serum samples were stored at -80°C . Biochemical parameters such as aspartate aminotransferase (AST), alanine aminotransferase (ALT), alkaline phosphatase (ALP), as well as serum determination of total bilirubin (TB) and conjugated bilirubin (CB) were then analyzed using spectrophotometer.

Carbon tetrachloride (CCl₄)-induced hepatotoxicity

The method described by Jain et al, (2006) was adapted with some modifications. Thirty rats were divided into six groups containing 5 rats each. Group I rats (Normal control) received Normal saline, 1 ml/kg, *p.o.* for 5 days. Group II rats (Toxic group) received 1 ml/kg of CCl₄ (1:1 in olive oil, *i.p.*), on the 3rd and 4th days. Group III rats (Standard) received silymarin (100 mg/kg *p.o.*) for 5 days and on the 3rd and 4th day, CCl₄ (1 ml/kg *i.p.*) was administered 1 hour after the treatment with silymarin. Group IV, V and VI rats received 250, 500 and 1000 mg/kg of the extract *p.o.* per day respectively for 5 days and on the 3rd and 4th days CCl₄ (1 ml/kg *i.p.*) was administered 1 hour after the treatment with the extract. The rats were also sacrificed 48 hours after the last injection of CCl₄ under mild chloroform anaesthesia. The blood samples were collected in plain sample bottles and then centrifuged at a speed of 4000 revolutions per minute to separate the serum. The samples were stored at -80°C and the biochemical parameters (AST, ALT, ALP, TB and CB) were also analysed.

2.8 Histopathological examination

Sections of tissue from liver were used for histopathological examination after dissecting the animals. Tissues were fixed in 10% buffered formalin (pH 7.2) and dehydrated through a series of ethanol solutions, embedded in paraffin and routinely processed for histological analysis. Sections of 5 μm thickness were cut and stained with haematoxylin-eosin for examination. The stained tissues were observed through a Leitz microscope at x250 magnification and photographed by a Scope tek DCM500 camera.

2.9 Antioxidant assay

The DPPH radical scavenging activity of the plant extracts was determined according to the method described by Chan et al, (2007). DPPH solution was prepared by dissolving 6 mg of DPPH in 100 ml of methanol. To 1 ml of various concentrations of the methanol stem bark of the extract (20, 40, 60, 80, 100 $\mu\text{g}/\text{ml}$), 2 ml of DPPH solution (0.1 mM) was added. An equal amount of methanol and DPPH served as control. The mixture was shaken vigorously after being kept for 30 minutes. The absorbance of the resulting solution was taken using ultraviolet (UV) spectrophotometer at 520 nm. The experiments were performed in triplicate and the percentage scavenging activity of the extract on DPPH radical was calculated.

2.10 Statistical analysis

Analysis of data was done using Minitab version 17. Differences between the mean biochemical parameters were analyzed using one way analysis of variance (ANOVA) followed by Dunnett's post-hoc test. The results were considered significant at *p*-value of <0.05 . Data were presented as Mean \pm Standard Error of the Mean (S.E.M.) in tables.

3. Results

Phytochemical analysis

Percentage yield of methanol stem bark extract of *Haematostaphis barteri* was 4.22% *w/w*. Preliminary phytochemical screening of the extract showed the presence of alkaloids, flavonoids, tannins, cardiac glycosides, triterpenes, saponins, anthraquinones and carbohydrates.

Acute toxicity study

No signs and symptoms of toxicity were observed in both phases of the acute toxicity study. Therefore, the oral LD₅₀ of the methanol stem bark extract of *Haematostaphis barteri* was estimated to be >5000 mg/kg body weight in rats.

Effect of methanol stem bark extract of *Haematostaphis barteri* on serum biochemical markers in paracetamol-induced hepatotoxic rats

Administration of paracetamol caused significant ($p<0.05$) increase in ALT and AST levels compared to normal saline control group. Pre-treatment with silymarin caused significant ($p<0.05$) decrease in ALT levels as compared with the paracetamol toxic group. Pre-treatment of the rats with *H. barteri* extract at all the doses tested also caused significant ($p<0.05$) decrease in ALT levels when compared with the toxic group. However, pre-treatment with the extract at all the doses tested did not show a significant decrease in serum AST, ALP and serum bilirubin levels as compared to paracetamol toxic group (**Table 1**).

Effect of methanol stem bark extract of *Haematostaphis barteri* on histopathological parameters in paracetamol-induced hepatotoxic rats

Liver sections of saline control group showed normal lobular architecture and normal hepatic cells (**Plate Ia**) while liver section from paracetamol toxic group showed hepatocellular necrosis with kupffer cell hyperplasia (**Plate Ib**). Liver section from silymarin treated group showed mild hepatocellular necrosis (**Plate Ic**). Histopathological study of the rats' liver treated with *H. barteri* at a dose of 250 mg/kg showed hydropic changes, slight necrosis of the hepatocytes and kupffer cell hyperplasia (**Plate Id**). Treatment with 500 mg/kg of *H. barteri* showed intense pyknosis with moderate hepatocellular necrosis of the liver (**Plate Ie**). Treatment with 1000 mg/kg of *H. barteri* showed mild vacuolation in the liver with lymphocyte hyperplasia (**Plate If**).

Table 1: Effect of methanol stem bark extract of *Haematostaphis barteri* against paracetamol-induced hepatotoxicity on enzyme and non-enzyme markers of liver damage in rats

Treatment (mg/kg)	ALT (U/L)	AST (U/L)	ALP (U/L)	CB (µmol/L)	TB (µmol/L)
NS	12.00±1.41	9.80±0.66	124.20±11.20	3.20±1.96	6.40±3.92
PCM	38.60±4.72**	48.20±8.28**	148.60±20.10	3.20±1.96	9.60±3.92
SLY+PCM	19.80±1.85*	22.20±5.87	203.80±55.20	1.60±1.60	6.40±3.92
HB(250)+PCM	17.40±0.93*	10.80±1.56	236.60±24.90	3.20±1.96	6.40±3.92
HB(500)+PCM	27.80±1.85*	55.40±14.90	273.40±37.90	4.80±1.96	13.00±6.15
HB(1000)+PCM	23.00±2.35*	50.20±16.00	271.20±87.50	3.20±1.96	9.80±6.50

Data presented as Mean ± S.E.M. * = $p < 0.05$ compared to PCM toxic group, ** = $p < 0.05$ compared with normal saline (NS) control group - One way ANOVA followed by Dunnett's test; n=5, ALT = Alanine transaminase, ALP = Alkaline phosphatase, AST = Aspartate transaminase, HB=*Haematostaphis barteri*, CB=Conjugated bilirubin, TB=Total bilirubin, PCM=Paracetamol, SLY = Silymarin

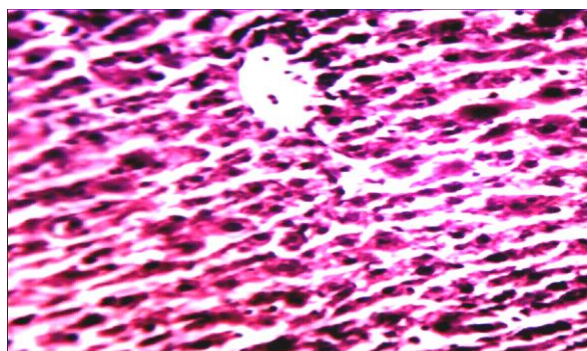


Plate Ia: Section of rat liver of administered normal saline showing normal hepatocytes

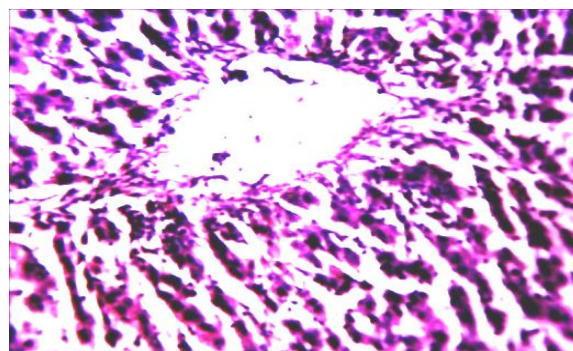


Plate Ib: Section of rat liver of paracetamol toxic group showing hepatocellular necrosis (A) with kupffer cell hyperplasia (B)

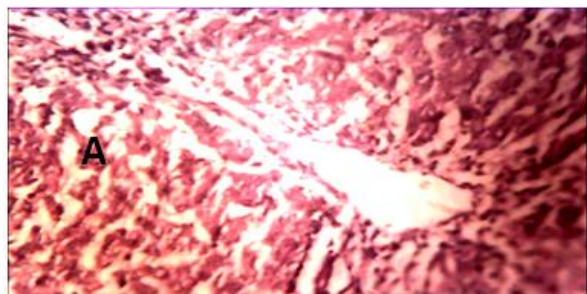

Plate Ic: Section of rat liver administered silymarin showing mild hepatocellular necrosis (A)

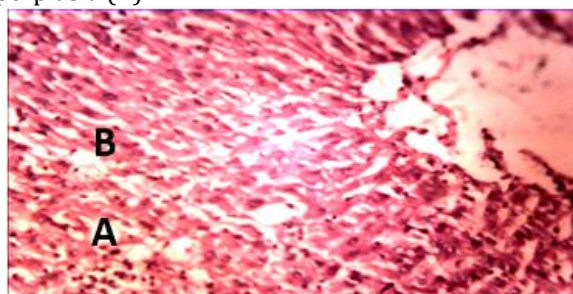


Plate Id: Section of rat liver administered *H. barteri* (250 mg/kg) showing slight necrosis of the hepatocytes (A) with kupffer cell hyperplasia (B)

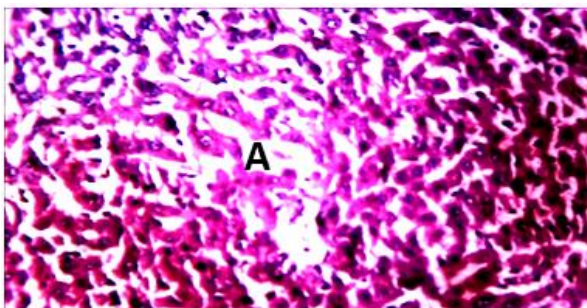


Plate Ie: Section of rat liver administered *H. barteri* (500 mg/kg) showing intense pyknosis with moderate hepatocellular necrosis (A)

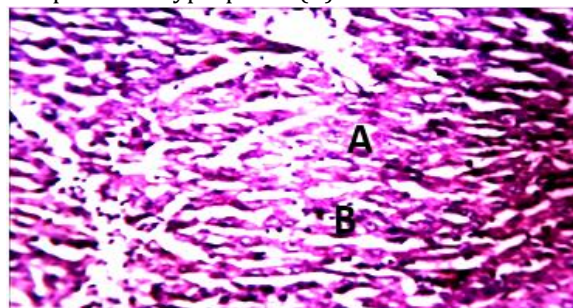


Plate If: Section of rat liver administered *H. barteri* (1000 mg/kg) showing mild vacuolation (A) with lymphocyte hyperplasia (B)

Plate I: Effects of methanol stem bark extract of *H. barteri* on histopathological changes in liver of rats in paracetamol-induced hepatotoxicity. Magnification (H and E ×250).

Effect of methanol stem bark extract of *Haematostaphis barteri* on serum biochemical markers in CCl₄-induced hepatotoxic rats

Administration of CCl₄ caused significant ($p < 0.05$) increase in ALT, AST and ALP levels when compared to normal saline control group. Treatment with silymarin caused significant ($p < 0.05$) reduction in serum ALT, AST and ALP when compared with CCl₄ toxic group. The extract at all the dose tested significantly ($p < 0.05$) reduced the mean serum ALP levels compared with CCl₄ toxic group. The reduction in serum AST was only significant ($p < 0.05$) at 500 mg/kg of the extract when compared to CCl₄ toxic group (Table 2). There was no significant ($p > 0.05$) reduction in serum bilirubin levels in the silymarin and *H. barteri* treated groups when compared with CCl₄ toxic group (Table 2).

Effect of methanol stem bark extract of *Haematostaphis barteri* on histopathological parameters in CCl₄-induced hepatotoxic rats

Liver section from saline control group showed normal lobular architecture and normal hepatic cells (Plate IIa). CCl₄ toxic group liver showed hepatocellular necrosis (Plate IIb). Liver from silymarin treated group showed moderate necrosis (Plate IIc). Liver section from *H. barteri* treated group at a dose of 250 mg/kg showed moderate hepatocellular necrosis with kupffer cell hyperplasia (Plate IId). Treatment of the rats with 500 mg/kg of *H. barteri* extract caused moderate hepatocellular necrosis of the liver (Plate IIE) while treatment with 1000 mg/kg of *H. barteri* showed intense hepatocellular necrosis of the liver tissue (Plate IIff).

3.4 DPPH radical scavenging activity

The DPPH scavenging activity of methanol stem bark extract of *Haematostaphis barteri* at different concentrations are presented in Table 3. The inhibition was not dose-dependent.

Table 2: Effect of methanol stem bark extract of *Haematostaphis barteri* on carbon tetrachloride-induced hepatotoxicity on enzyme and non-enzyme markers of liver damage in rats

Treatment (mg/kg)	ALT (U/L)	AST (U/L)	ALP (U/L)	CB (μmol/L)	TB (μmol/L)
NS	10.40±1.170	10.80±1.02	126.20±11.50	3.20±1.96	6.40±3.92
CCl ₄	29.20±1.39**	77.20±9.61**	545.00±151.00**	6.40±3.92	6.40±7.38
SLY+ CCl ₄	15.40±2.09*	13.80±0.58*	165.20±20.10*	3.20±1.96	6.40±3.92
HB(250)+ CCl ₄	25.40±3.66	66.60±9.45	204.80±18.40*	1.60±1.60	6.40±3.92
HB(500)+ CCl ₄	22.20±3.57	30.80±9.98*	245.40±29.00*	1.60±1.60	6.40±3.92
HB(1000)+ CCl ₄	28.80±1.39	62.40±15.10	154.20±5.30*	3.20±3.20	9.60±6.40

Data were presented as Mean ± S.E.M. *= $p < 0.05$ compared with PCM toxic group, **= $p < 0.05$ compared with normal saline (NS) control group - One way ANOVA followed by Dunnett's test, n = 5, HB = *Haematostaphis barteri*, ALT = Alanine transaminase, ALP=Alkaline phosphatase, AST=Aspartate transaminase, CB=Conjugated bilirubin, TB=Total bilirubin, CCl₄ = Carbon tetrachloride, SLY = Silymarin

Table 3: Quantitative DPPH assay of the stem bark extract of *Haematostaphis barteri*

S/N	Concentration (μg/ml)	AB	AE	% Inhibition
1	20	0.469	0.220	53.09
2	40	0.809	0.349	56.86
3	60	0.827	0.439	46.92
4	80	0.914	0.531	41.90
5	100	0.796	0.680	14.57

AB= absorbance of control, AE= absorbance of the Extract, Wavelength = 520 nm

4.0 Discussion

The biological actions produced by plant extracts are usually attributed to the presence of secondary metabolites in them (Kensa and Yasmin, 2011). The phytochemical constituents found present in the methanol stem bark extract of *H. barteri* in this study were largely corroborative of the findings of Tadzabia et al, (2013). Some of these constituents like flavonoids, triterpenes and tannins have been reported to exert

hepatoprotective activity (Shimoda *et al.*, 2008; Kandimalla *et al.*, 2016) and are thus suggested to contribute to the observed hepatoprotection of *H. barteri* stem bark extract. The oral median lethal dose of the methanol stem bark extract of *H. barteri* in rats was estimated to be >5000 mg/kg. According to Lu, (1996) classification of LD₅₀ values, it implies that the extract is practically non-toxic in rats when administered orally as no death was recorded in both phases of the study.

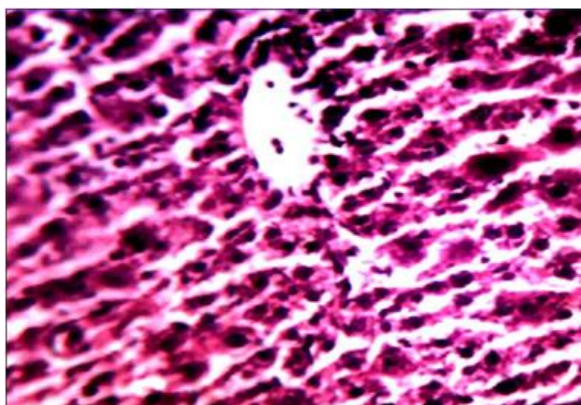


Plate IIa: Section of rat liver showing normal hepatocytes in normal saline control group

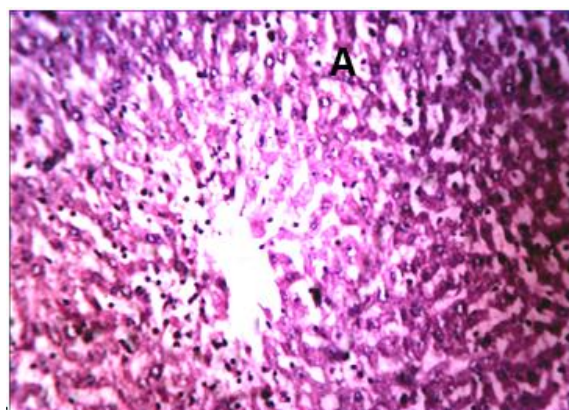


Plate IIb: Section of rat liver administered CCl₄ showing hepatocellular necrosis (A)

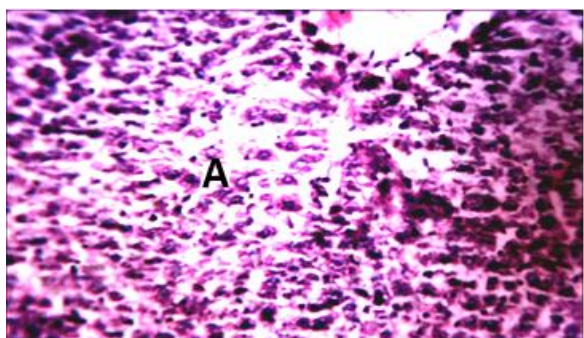


Plate IIc: Section of rat liver administered silymarin showing moderate hepatocellular necrosis (A)

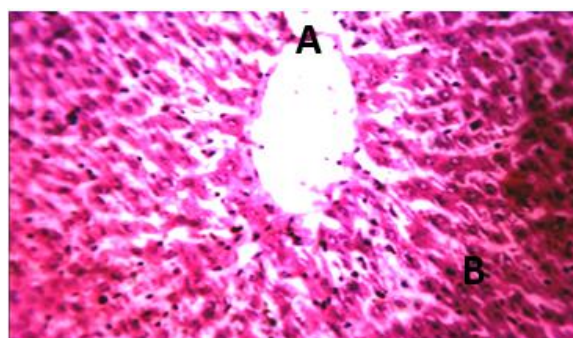


Plate IId: Section of rat liver administered *H. barteri* (250 mg/kg) showing moderate hepatocellular necrosis (A) with kupffer cell hyperplasia (B)

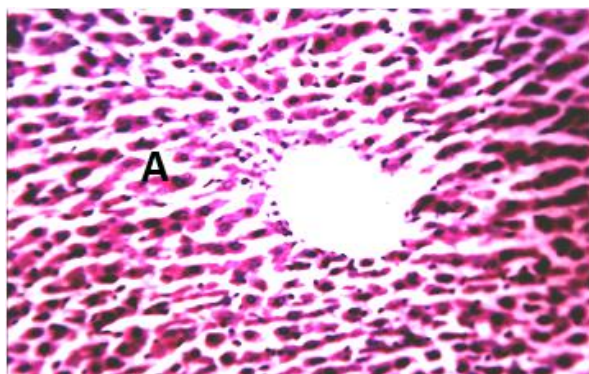


Plate IIe: Section of rat liver of administered *H. barteri* (500 mg/kg) showing moderate hepatocellular necrosis (A)

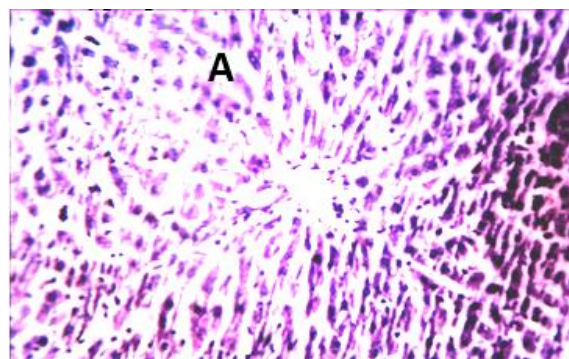


Plate IIff: Section of rat liver administered *H. barteri* (1000 mg/kg) showing intense hepatocellular necrosis (A)

Plate II: Effect of *H. barteri* on histopathological changes in liver of rats in CCl₄-induced hepatotoxicity. Magnification (H and E ×250)

Hepatocellular damage can lead to loss of functional integrity of parenchymal cells and leakage of liver enzymes resulting in their elevation in the serum (Daniel, 2015). In this study, administration of paracetamol (3 g/kg) resulted in hepatic damage and showed a significant serum elevation of enzyme and non-enzyme markers of liver damage (ALT, AST, ALP, conjugated and total bilirubin) as well as hepatocellular necrosis. Pre-treatment of the rats with silymarin and the stem bark extract of *H. barteri* protected the rats against the paracetamol-induced hepatic damage. The methanol extracts also protected the liver against

hepatocellular necrosis, pyknotic nuclei, vacuolation and kupffer cell hyperplasia caused by paracetamol in a dose-dependent manner, except for 500 mg/kg of HB which did not protect the hepatocytes against paracetamol-induced liver damage as evidenced by persistence of intense pyknotic nuclei and moderate hepatocellular necrosis even though there was significant reduction in the serum level of ALT. This may occur as a result of interactions among the constituents of *H. barteri* extract or between the plant extract and paracetamol.

The hepatotoxic effects of CCl₄ are largely due to bioactivation of CYP2E1 cytochrome enzyme, resulting in the formation of trichloromethyl free radicals and reactive oxygen species which initiate lipid peroxidation, protein oxidation and damage to hepatocellular membranes (Johnson and Kroening, 1998). The damage to the liver is associated with leakage of hepatic enzymes (especially ALT and AST) into serum resulting in elevation in their serum concentration. Serum ALP, bilirubin and total protein levels on other hand are related to the function of hepatic cell. Increase in serum level of ALP is due to increased synthesis, in presence of increasing biliary pressure. In this study, treatment with CCl₄ elicited a significant increase in serum ALT, AST and ALP levels but pre-treatment of the rats with silymarin protected the liver against CCl₄-induced hepatic damage as evidenced by significant reduction in their serum levels. Pre-treatment of the rats with *H. barteri* extract also reduced the serum levels of the ALT, AST and ALP levels. Histopathological examination of liver sections of *H. barteri* treated groups showed some levels of protection against CCl₄ intoxication which was evident by less hepatocellular necrosis.

Antioxidants appear to act against disease processes by increasing the levels of endogenous antioxidant enzymes and decreasing toxic products such as lipid peroxidation by-products. Free radicals are easily formed when a covalent molecular bond is broken and one electron remains with each newly formed atom. DPPH is a stable free radical which produces deep purple colour in methanol. The principle of this assay is based on the reduction of purple coloured methanolic DPPH solution in the presence of hydrogen donating antioxidants by the formation of yellow coloured diphenyl-picryl hydrazine. When DPPH accepts an electron donated by an antioxidant compound, the DPPH is decolorized, which can be quantitatively measured from the changes in absorbance (Saha et al, 2008). The DPPH studies on *H. barteri* stem bark extract has shown that it possesses antioxidant properties, which is further validated by previous reports on its high phenolic content (Boampong et al, 2015; Ezekiel et al, 2016). Typical phenolics that possess antioxidant activity are mainly phenolic acids and flavonoids; and studies have shown that hepatoprotective effects of plant extracts are associated with phytochemicals rich in natural antioxidants (Sharida et al, 2012). Based on this, it can be suggested that the observed hepatoprotection offered by *H. barteri* stem bark extract may be ascribed to its antioxidant property.

5.0 Conclusion

The results obtained showed that the methanol stem bark extract of *Haematostaphis barteri* possesses hepatoprotective activities. This lends further support on the ethnomedical rationale of its use in managing liver diseases.

Conflict of Interest declaration

The authors declare no conflict of interest.

References

- Abubakar E, Hussaini B and Friday I (2014). Changes in haematological parameters following oral administration of blood plump (*Haematostaphis barteri*) fruits extract in albino rats. *Extensive J. Appl. Sci.* **2**: 14-17.
- Ajith TA, Hema U and Aswathy MS (2007). *Zingiber officinale* Roscoe prevents acetaminophen-induced acute hepatotoxicity by enhancing hepatic antioxidant status. *Food Chem. Toxicol.* **45**: 2267-2272.
- Boampong JN, Karikari AA and Ameyau EO (2015). *In vivo* antiplasmodial and *in vitro* antioxidant properties of stem bark extracts of *Haematostaphis barteri*. *Asian J. Trop. Biomed.* **5**: 446-450.
- Burkill HM (1985). *The Useful Plants of West Tropical Africa*. Vol. 1, Royal Botanic Gardens, Kew.
- Chan EWC, Lim YY, Wong LF, Lianto FS, Wong SK, Lim KK, Joe CE and Lim T (2008). Antioxidant and tyrosinase inhibition properties of leaves and rhizomes of ginger species. *Food Chem.* **109**: 477-483.
- Crawford JM (2004). Liver and biliary tract. In: Robins and Cotran's *Pathologic Basis of Disease* 7th Ed. KumarV, Abbas A and Fausto N (eds). Philadelphia, Saunders. pp 877-937.
- Daniel SP (2015). Evaluation of Liver Function. In: *Harrison's Principles of Internal Medicine* 17th Ed. Fauci AS, Braunwald E, Kasper DL, Hauser SL, Longo DL, Jameson JL and Loscalzo J, (eds). The McGraw-Hill Companies, Inc. New York. pp 1995-1999.
- Eromosele IC and Eromosele CO (2002). Fatty acid compositions of seed oils of *Haematostaphis barteri* and *Ximenia americana*. *Biores. Tech.* **82**: 303-304.
- Evans WC (2002). *Trease and Evans Pharmacognosy*. 15th Ed. Saunders WR, London.
- Ezekiel JS, Adamu HM, Chindo IY and Garba IH (2016). Phytochemical Profile and Antioxidant Activities of Solvent-solvent Fractions of *Haematostaphis barteri* Hook F. (Anacardiaceae) Stem Bark Extracts. *Int. J. Pharmacog. Phytochem. Res.* **8**: 51-56.
- Hong M, Li S, Tan HY, Wang N, Tsao S and Feng Y (2015). Current Status of Herbal Medicines in Chronic Liver Disease Therapy: The Biological Effects, Molecular Targets and Future Prospects. *Int. J. Mol. Sci.* **16**: 28705-28745.
- Jain A, Singhai AK and Dixit VK (2006). A comparative study of ethanol extract of leaves of *Tephrosia purpurea* Pers and the flavonoid isolated for hepatoprotective activity. *Indian J. Pharm. Sci.* **68**: 740-743.
- Johnson DE and Kroening C (1998). Mechanism of early carbon tetrachloride toxicity in cultured rat hepatocytes. *Pharmacol. Toxicol.* **83**: 231-239.
- Jordan SA, Cunningham DG and Marles RJ (2010). Assessment of herbal medicinal products: challenges, and opportunities to increase the knowledge base for safety assessment. *Toxicol. Appl. Pharmacol.* **243**: 198-216.

- Kandimalla R, Kalita S, Saikia B, Choudhury B, Singh YP, Kalita K, Dash S and Kotoky J (2016). Antioxidant and hepatoprotective potentiality of *Randia dumetorum* Lam. leaf and bark via inhibition of oxidative stress and inflammatory cytokines. *Front. Pharmacol.* **7**: 1-8.
- Kensa VM and Yasmin S (2011). Phytochemical screening and antibacterial activity on *Ricinus communis* L. *Plant Sci. Feed.* **1**: 167-173.
- Lorke D (1983). A new approach to practical acute toxicity testing. *Arch. Toxicol.*, **54**: 275-287.
- Lu FC (1996). Conventional toxicity studies. In: Basic toxicology, Fundamentals, target organs and risk assessment. Taylor and Francis (ed). Raven press, USA. p. 80.
- Mnddrey WC (2001). Update in Hepatology. *Ann. Internal Med.* **134**: 216-23.
- Nirmala M, Girija K, Lakshman K, and Divya T. (2012). Hepatoprotective activity of *Musa paradisiaca* on experimental animal models. *Asian Pac. J. Trop. Biomed.* **10**:11-15.
- Porceddu M, Buron, N, Roussel C, Labbe G, Fromenty B and Borgne-Sanchez A (2012). Prediction of liver injury induced by chemicals in human with a multiparametric assay on isolated mouse liver mitochondria. *Toxicol. Sci.* **129**: 332-345.
- Saha MR, Hasan SMR, Akter R, Hossain MM, Alam MS, Alam MA and Mazumder MEH (2008). *In vitro* free radical scavenging activity of methanol extract of the leaves of *Mimusops elengi* Linn. *Bangl. J. Vet. Med.* **6**: 197-202.
- Sharida F, Syazana AS and Palanisamy A (2012). *Moringa oleifera* hydroethanolic extracts effectively alleviate acetaminophen-induced hepatotoxicity in experimental rats through their antioxidant nature. *Molecules.* **17**: 8334-8350.
- Shimoda H, Tanaka J, Kikuchi M, Fukuda T, Ito H, Hatano T and Yoshida T (2008). Walnut polyphenols prevent liver damage induced by carbontetrachloride and d-galactosamine: hepatoprotective hydrolyzable tannins in the kernel pellicles of walnut. *J. Agric Food Chem.* **56**: 4444-4449.
- Tadzabia K, Maina HM, Maitera ON and Ezekiel JS (2013). Evaluation of phytochemical and elemental contents of *Haematostaphis barteri* leaves and stem bark in Hong local government area of Adamawa State, Nigeria. *J. Chem. Pharm. Res.* **5**: 150-156.
- Wang XB, Feng Y, Wang N, Cheung F and Wong CW (2012). Recent progress on anti-liver fibrosis candidates in patents of herbal medicinal products. *Recent Patents Food Nutri. Agric.*, **4**: 91-106.
- WHO (2013). *WHO Traditional Medicine Strategy 2014-2023*, Geneva: WHO Press.