

Showa Univ J Med Sci 31(1), 63~71, March 2019

Original

Prevention of Suppurative Knee Arthritis after Knee Ligament Reconstructive Surgery —“Povidone-iodine Pickled” Reconstructed Ligament—

Eiji SHIOTANI^{*1,2)}, Setsuro KURIYAMA^{1,3)}, Hiroki ISHIKAWA^{1,3)},
Raita AMEMIYA¹⁾ and Katsunori INAGAKI¹⁾

Abstract : Despite many reports describing the surgical procedure for knee ligament reconstruction, especially the anterior cruciate ligament, there have been few reports on infection prevention and none on sterilizing reconstruction materials using povidone-iodine during surgery. Here we report our surgical techniques for infection prevention. The participants included 522 patients who underwent arthroscopic knee ligament reconstruction at our hospital from April 2001 to October 2005. Despite taking various measures after cases of infection in 2001, such as the selection of sutures and artificial ligaments, and the use of indwelling intra-articular drains, the infection rate was not reduced to zero. Recently, we felt that soaking reconstruction ligaments in povidone-iodine and then washing with saline (“povidone-iodine pickling”) immediately prior to burr-hole insertion may prevent bacterial infections caused by surgical instruments and the surgery. Therefore, in this study, we examined the effects of our techniques for intraoperative and postoperative infection prevention, including “povidone-iodine pickling”. Although there were 6 cases of infection out of 100 in 2001, 3 out of 112 in 2002, 2 out of 121 in 2003, and 1 out of 121 in 2004, there were no cases of infection from September 2004 to October 2005 when “povidone-iodine pickling” was positively carried out. According to a 2015 study on the use of povidone-iodine, immersing a graft dropped on the floor during surgery in a chlorhexidine gluconate or povidone-iodine solution significantly reduced contamination of the graft. While the use of povidone-iodine for infection prevention may produce cytotoxicity, it is essential to mitigate the risk of septic arthritis. Going forward, we need to understand the specific pathologic basis of any cytotoxicity caused by the use of povidone-iodine on reconstructed ligaments.

Key words : anterior cruciate ligament reconstruction, septic arthritis, povidone-iodine, infection, MRSA

Introduction

Despite there being many reports on the surgical procedure for knee ligament reconstruction,

¹⁾ Department of Orthopedic Surgery, Showa University School of Medicine, 1-5-8 Hatanodai, Shinagawa-ku, Tokyo 142-8555, Japan.

²⁾ Japan Community Health Care Organization (JCHO), Tokyo Takanawa Hospital, Department of Orthopedics.

³⁾ Department of Orthopedic Surgery, Nippon Koukan Hospital.

* To whom corresponding should be addressed.

especially the anterior cruciate ligament (determination of burr hole positions, selection of tendon grafts, and so on)¹⁻¹¹⁾, there have been few reports on infection prevention¹²⁻²²⁾ and no reports on the sterilization of reconstruction materials using povidone-iodine during the surgical procedure. We have previously reported on the surgical procedure and outcomes of knee ligament reconstruction²³⁾. In this study, we report on our novel techniques used during surgery for infection prevention.

Materials and methods

The participants included 522 patients who underwent arthroscopic knee ligament reconstruction at our hospital from April 2001 to October 2005. Despite taking various measures after a series of infections in 2001, the infection rate was not reduced to zero. These measures included suture selection, i.e., using sutures with a low foreign substance reaction and a low possibility of being a source of infection (monofilament, synthetic, absorbable sutures made of polydioxanone) and using sutures with a low possibility of becoming a source of infection (e.g., polyethylene) even in the event of selecting a multi-filament suture (e.g., yarn) due to tensile strength; the selection of artificial ligaments [the raw material of Telos (Aimedic, Tokyo, Japan) is polyethylene terephthalate and multi-filament]; and the use of indwelling intra-articular drains, where previously only extra-articular, subcutaneous drains were used. Recently, we felt that soaking the reconstructed ligaments in povidone-iodine for about 8-10 minutes and then washing them in saline (“povidone-iodine pickling”) immediately prior to burr-hole insertion may prevent bacterial infections caused by the surgical instruments and the operation itself. Thus, in this study, we conducted knee ligament reconstructions and examined the effects of intraoperative and postoperative infection prevention techniques, including “povidone-iodine pickling”, on the resulting infection rate.

Infection prevention at our hospital: “povidone-iodine pickling” of the reconstruction ligament

In principle, intravenous injection of 2 g of cefazolin sodium, a first generation cephem antibiotic drug, is administered for infection prevention for three days including the day of surgery. The anterior cruciate ligament reconstruction method aims for anatomical reconstruction. Two reconstruction ligaments (antero-medial bundle and postero-lateral bundle) are prepared. The reconstruction materials mainly used are hamstrings and artificial ligaments (Telos). The completed reconstruction ligament is soaked in an undiluted solution of 10% povidone-iodine for about 8-10 minutes, then washed with saline, immediately prior to burr-hole insertion (Fig. 1). Taking into consideration the increased infection susceptibility due to diseased limbs hanging from the operating table during arthroscopic surgery, we perform surgery with the diseased limbs lifted up onto the table.

Other infection prevention (1): indwelling intra-articular drain

Other measures for infection prevention include an intra-articular indwelling drain to reduce postoperative hemarthrosis. In order to reduce the duration of surgery, an irrigation cannula is

used to place the drain prior to drain fixation (Fig. 2).

Other infection prevention (2) : indwelling subcutaneous drain

A half-cut drain with needle is pierced below the knee in a safe direction (anteromedial) in which there are fewer saphenous nerve branches of the medial knee (such as the infrapatellar branch) (Fig. 3). As a result, there are two indwelling drains (intra-articular and subcutaneous drains).

Results

While there were 6 cases of infection out of 100 in 2001, 3 out of 112 in 2002, 2 out of 121 in 2003, and 1 out of 121 in 2004, however there were no cases of infection from September 2004 to October 2005 when “povidone-iodine pickling” was positively carried out. In this study, “infected cases” refers to patients who were culture-negative but had a severe local swelling and a feeling of heat (intra-articular /extra-articular) and exhibited increased white cells and high C-reactive protein levels in blood tests and required treatment.

Discussion

Although the incidence of septic arthritis after arthroscopic knee surgery is said to be low, its occurrence incurs a significant social and economic burden on the patient, in addition to putting

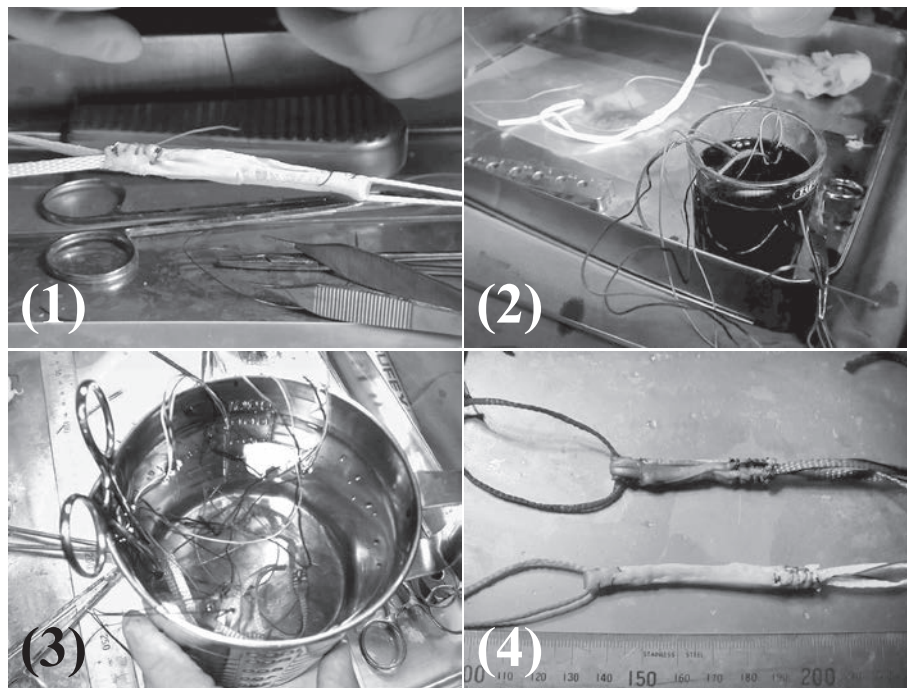


Fig. 1. Techniques used at our hospital : “povidone-iodine pickled” reconstructed ligament (1) Create multi-fold reconstruction ligaments of hamstrings, including artificial ligaments (Teros). (2) Soak in an undiluted solution of 10% povidone-iodine. (3) Irrigate with saline. (4) Conduct “povidone-iodine pickling” of the antero-medial bundle and postero-lateral bundle (the picture shows the postero-lateral bundle after “povidone-iodine pickling”).

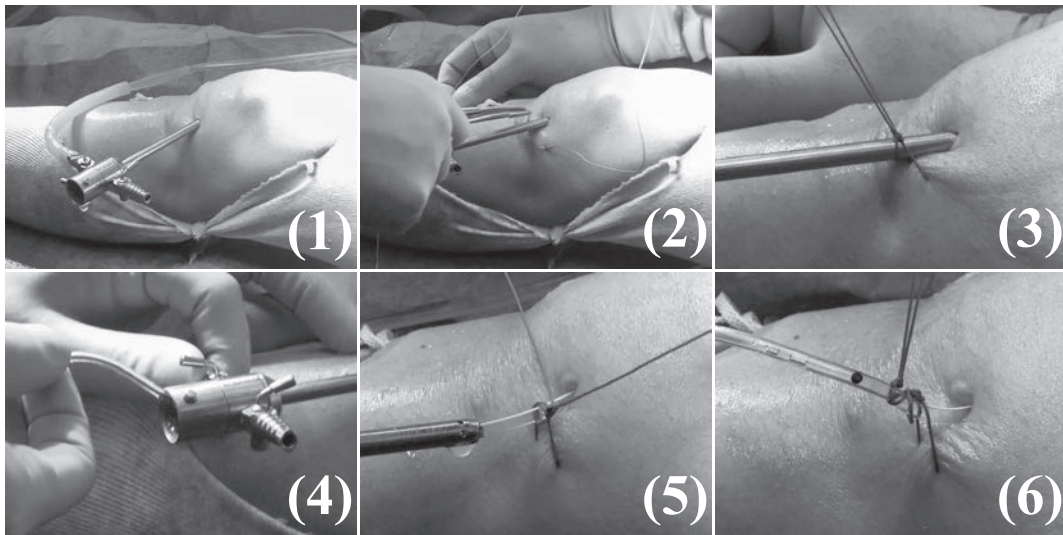


Fig. 2. Other means of infection prevention (1) : indwelling intra-articular drain

(1) Irrigate the inside of the joint well and leave the irrigation cannula in the suprapatellar pouch. (2) Place stitches for fixation. (3) Tie above the irrigation cannula. (4) Cut the drain in half, insert the end of the drain without the needle into the irrigation cannula, and insert the tip of the drain until it reaches the depth of the joint. (5) Pull out the irrigation cannula, keeping the drain inserted and fix the drain. (6) The drain insertion length is only for reference.

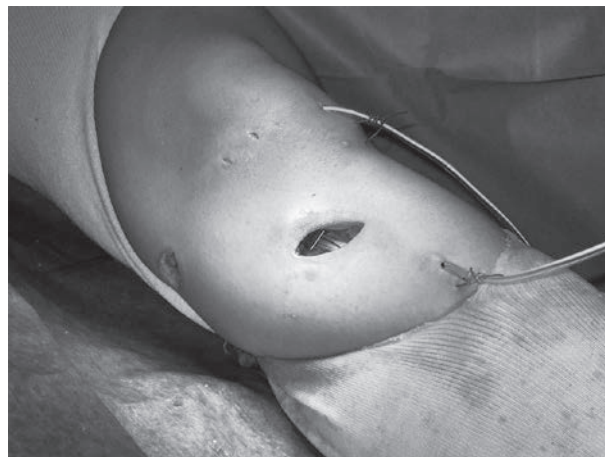

Fig. 3. Another means of infection prevention (2) :
indwelling subcutaneous drain

With the needle attached to the remaining half piece of drain tube, pierce the subcutaneous tissues of the knee in a safe direction (anteromedial) where there are fewer branches of the saphenous nerve on the medial side of the knee (such as the infrapatellar branch).

a great deal of mental stress on the medical staff. Septic arthritis remains the most serious postoperative complication of anterior cruciate ligament reconstruction. For infection prevention, we believe various factors produce synergistic effects²⁴⁾. As mentioned above, it goes without saying that indwelling drains themselves have preventive effects, such as the postoperative

reduction of hemarthrosis and the removal of subcutaneous hematomas (Fig. 4). Therefore, in particular, we examined the effectiveness of “povidone-iodine pickling” in this study.

The existence of an unapparent chronic infection focus cannot be ruled out, though no obvious infection source was found among the 12 patients with postoperative infections, excluding one patient with a past history of atopic dermatitis ; in addition, no obvious infection factors were found upon preoperative blood testing. However, the most important cause of septic arthritis associated with knee ligament reconstruction may be bacterial infection from the surgical instruments and the surgical operation itself. While Schollin-Borg *et al*²⁵⁾ pointed out the possibility of infections due to the equipment used for preparation of reconstruction ligaments, it is not easy to identify the source of infection. Therefore, the most important thing for infection prevention is for all medical staff to handle the surgical instruments in a sterile manner by washing their hands and maintaining sterility during the operation.

Addition of “povidone-iodine pickling”

We believe the use of povidone iodine may help achieve a sterile operation and contribute to the prevention of bacterial infection from new surgical operative procedures (longer exposure time due to reconstruction work such as the multiple folding of collected hamstrings). Povidone-iodine has advantages, such as its low cost as a sterilizer for external use, no bacterial resistance, and it is already used in the operating rooms of all facilities.

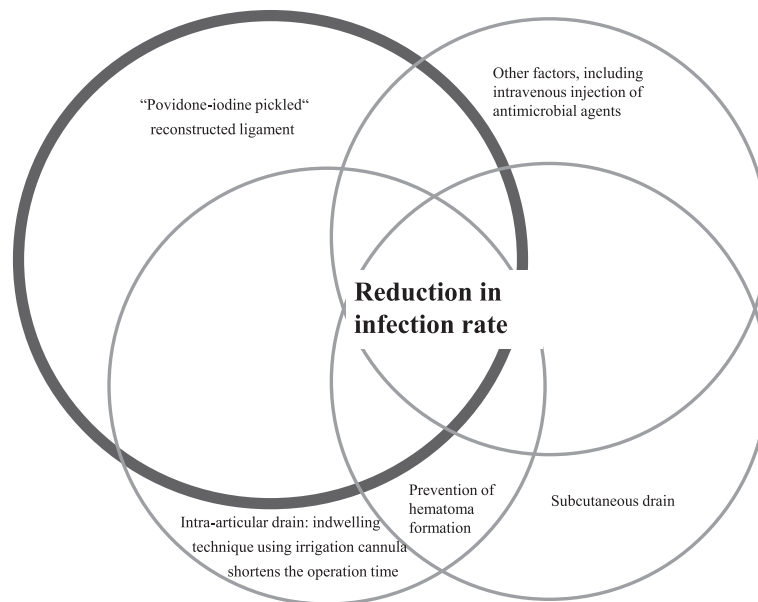


Fig. 4. Reduction in infection rate. For infection prevention, various factors yield synergistic effects.

Factors include : “povidone-iodine pickled” reconstructed ligament, intra-articular drain (indwelling technique using irrigation cannula shortens the operation time), subcutaneous drain, prevention of hematoma formation, and other factors, such as intravenous antimicrobial agents.

Current sterilizers

Sterilizers for external use currently used for infected wounds include povidone-iodine, Pyoktanin Blue, invert soap (Hyamine), and chlorhexidine (Hibitane). Pyoktanin exhibits selective sterilizing power only for gram-positive bacteria and it has been used prior to the use of antibiotic agents. It has low irritation to biotissues and exhibits strong sterilizing power against methicillin-resistant *Staphylococcus aureus* (MRSA). This agent is effective for skin lesions, such as burns and decubital ulcers, but it has strong colorability and thus cannot be used for continuous irrigation.

Povidone-iodine includes polyvinylpyrrolidone as an additive. Polyvinylpyrrolidone has been developed as a plasma substitute and maintains its sterilizing power by combining with iodide. Its toxicity is said to be only one-fourth or one-eighth that of tincture of iodine and Lugol's solution²⁶⁾. Povidone-iodine exhibits sterilizing power because its free iodine, the active ingredient in liquid form, is liberated from iodine, allowing sterilizing power over a wide range of microorganisms such as bacteria, fungi, and viruses.

Bactericidal effects against MRSA

In solution, the concentration of free iodine is highest at a 100-fold dilution. According to Haley *et al*²⁷⁾, povidone-iodine exhibits the most effective bactericidal effect against MRSA, compared to other sterilization agents. For 10% povidone-iodine, sterilization reportedly takes 30 seconds for a 10 to 1,000-fold dilution and 60 seconds for a 10,000-fold dilution (Table 1). Povidone-iodine has been used as a continuous irrigation agent for infected sites for a long time, and there have been many reports detailing its use in infections after thoracotomy for cardiac surgery. As either a sterilizing agent or irrigation agent, it has been reported to be effective without side effects²⁶⁾.

Problems

The use of sterilizing agents requires caution for pregnant women and patients with iodine hypersensitivity, kidney hypofunction or severe burns. However, cytotoxicity is not a problem with our “povidone-iodine pickling”, as the povidone-iodine on the surface of the reconstructed ligament is washed away with saline prior to insertion and it is also washed away by the irrigation liquid after insertion. In addition, the cells of the reconstructed ligament soon die and are replaced by normal cells, so the cells exposed to the toxicity of povidone-iodine are replaced with normal cells during the process.

Only one obvious postoperative infection was found while continuing to perform the same surgical procedure using “povidone-iodine pickling” for 3 years from December 2015 to November 2018. Furthermore, no issues were found regarding the tension or volume of the “povidone-iodine pickled” ligaments, when evaluating the reconstructed ligaments while performing pin extraction or re-arthroscopy, one to three years after the original arthroscopic knee ligament reconstruction.

According to a recent study on the use of povidone-iodine published in 2015, immersing a

Table 1. Effect of exposure time and concentration of antiseptic solution on survival of MRSA (Haley *et al.*, 1985)

Antiseptic and dilution	CFU of MRSA recovered / 0.1 ml after contact time of ^a				
	15s	30s	60s	120s	240s
Betadine (10% povidone-iodine)					
Stock	245	32	7	0	0
1 : 10	12	0	0	0	0
1 : 100	0	0	0	0	3
1 : 1,000	5	0	0	0	0
1 : 10,000	290	400	0	0	0
PhisoHex (3% hexachlorophene)					
Stock	591	157	54	31	22
1 : 10	≥ 1,000	977	940	854	760
1 : 100	≥ 1,000	≥ 1,000	≥ 1,000	927	645
1 : 1,000	≥ 1,000	≥ 1,000	≥ 1,000	≥ 1,000	≥ 1,000
Hibiclens (4% chlorhexidine gluconate)					
Stock	5	5	6	3	1
1 : 10	900	933	930	833	853
1 : 100	≥ 1,000	≥ 1,000	≥ 1,000	≥ 1,000	≥ 1,000
Acute-Kare (1% p-chloro-m-xyleneol)					
Stock	670	614	531	259	106
1 : 10	≥ 1,000	≥ 1,000	826	446	192
1 : 100	≥ 1,000	≥ 1,000	≥ 1,000	≥ 1,000	≥ 1,000

a : Survival of 100% = 10⁴ organisms. Numbers given represent means of multiple determinations with three separate strains of MRSA.

CFU, colony-forming units ; MRSA, methicillin-resistant *Staphylococcus aureus*

graft dropped on the floor during surgery in a chlorhexidine gluconate solution or povidone-iodine solution significantly reduced contamination of the graft. They concluded that soaking the hamstring autograft in one of these solutions is recommended in the case of inadvertent contamination²⁸⁾.

However, in the future, we need to understand the specific pathologic basis of any cytotoxicity caused by the use of povidone-iodine to reconstruction ligaments.

Conclusions

- In this study, we reported on “povidone-iodine pickling” of reconstructed ligaments for the prevention of septic arthritis associated with knee ligament reconstruction.
- The use of povidone-iodine for infection prevention may cause cytotoxicity, but it is essential to mitigate the risk of septic arthritis.
- Under the existing conditions, the clinical performance of this novel technique is good, thus we are planning to continue using it for surgery.

Finally, there are many triggers of infection and it is difficult to identify all the factors of the infection and gather it into scientific form. However, we believe that the “povidone-iodine pickling” described in this report is an intraoperative technique which is positively focused on infection prevention.

Acknowledgments

Part of this article was reported in “My Techniques”, a panel discussion at the 46th General Meeting of The Kanto Society of Orthopedics and Traumatology and was also reported in the Journal of The Showa Medical Association in Japanese.

In this paper, we report in English based on the latest literature, and will continue to consider additional reports in the future. I would like to express my sincere gratitude to everyone offered assistance.

Conflicts of interest

The authors declare that they have no conflict of interest.

References

- 1) Bigoni M, Zanchi N, Omeljaniuk RJ, *et al*. Role of interleukin-10 in the synovial fluid of the anterior cruciate ligament injured knee. *Eur Rev Med Pharmacol Sci*. 2019;**23**:932-940.
- 2) Albertoni LJB, Debieux P, Franciozi CEDS, *et al*. Assessment of the regeneration capacity of semitendinosus and gracilis tendons. *Acta Ortop Bras*. 2018;**26**:379-383.
- 3) Ithurburn MP, Longfellow MA, Thomas S, *et al*. Knee function, strength, and resumption of preinjury sports participation in young athletes following anterior cruciate ligament reconstruction. *J Orthop Sports Phys Ther*. 2019;**15**:1-9.
- 4) Krause M, Freudenthaler F, Frosch KH, *et al*. Operative versus conservative treatment of anterior cruciate ligament rupture. *Dtsch Arztebl Int*. 2018;**115**:855-862.
- 5) Chowdhury AZ, Ali MH, Faisal MA, *et al*. Anterior cruciate ligament reconstruction using autologous hamstring double bundle graft compared with single bundle graft procedures. *Mymensingh Med J*. 2019;**28**:126-136.
- 6) Buckthorpe M, La Rosa G, Villa FD. Restoring knee extensor strength after anterior cruciate ligament reconstruction: a clinical commentary. *Int J Sports Phys Ther*. 2019;**14**:159-172.
- 7) He Q, Zhuang L, An Z, *et al*. Effectiveness of a novel remnant-preserving anterior cruciate ligament reconstruction with bidirectional barbed suture. *Zhongguo Xiu Fu Chong Jian Wai Ke Za Zhi*. 2019;**33**:149-153. (in Chinese).
- 8) Soneru A, Sarwark JF. Survivorship of allograft ACL reconstruction in adolescent patients. *J Orthop*. 2018;**16**:11-13.
- 9) Murphy RF, Heyworth B, Kramer D, *et al*. Symptomatic venous thromboembolism after adolescent knee arthroscopy. *J Pediatr Orthop*. 2019;**39**:125-129.
- 10) Chiang ER, Chen KH, Chih-Chang Lin A, *et al*. Comparison of tunnel enlargement and clinical outcome between bioabsorbable interference screws and cortical button-post fixation in arthroscopic double-bundle anterior cruciate ligament reconstruction: a prospective, randomized study with a minimum follow-up of 2 years. *Arthroscopy*. 2019;**35**:544-551.
- 11) Yasuda K, Kondo E, Ichiyama H, *et al*. Anatomic reconstruction of the anteromedial and posterolateral bundles of the anterior cruciate ligament using hamstring tendon grafts. *Arthroscopy*. 2004;**20**:1015-1025.
- 12) Kurokouchi K, Takahashi S, Yamada T, *et al*. Methicillin-resistant *Staphylococcus aureus*-induced septic arthritis after anterior cruciate ligament reconstruction. *Arthroscopy*. 2008;**24**:615-617.
- 13) Felli L, Revello S, Burastero G, *et al*. Single intravenous administration of tranexamic acid in anterior cruciate liga-

- ment reconstruction to reduce postoperative hemarthrosis and increase functional outcomes in the early phase of postoperative rehabilitation: a randomized controlled trial. *Arthroscopy*. 2019;**35**:149–157.
- 14) Palazzolo A, Rosso F, Bonasia DE, *et al.* Uncommon complications after anterior cruciate ligament reconstruction. *Joints*. 2018;**6**:188–203.
 - 15) Willinger L, Imhoff AB, Schmitt A, *et al.* Fixation of bony avulsions of the posterior cruciate ligament by a suture-bridg(TM) technique. *Oper Orthop Traumatol*. 2019;**31**:3–11.
 - 16) Bohu Y, Klouche S, Herman S, *et al.* Professional athletes are not at a higher risk of infections after anterior cruciate ligament reconstruction: incidence of septic arthritis, additional costs, and clinical outcomes from the French prospective anterior cruciate ligament study (FAST) cohort. *Am J Sports Med*. 2019;**47**:104–111.
 - 17) Achtnich A, Schmitt A, Forkel P, *et al.* Acute injury of the posterior cruciate ligament with femoral avulsion: arthroscopic ligament repair and bracing. *Oper Orthop Traumatol*. 2019;**31**:12–19.
 - 18) Everhart JS, DiBartola AC, Dusane DH, *et al.* Bacterial deoxyribonucleic acid is often present in failed revision anterior cruciate ligament reconstructions. *Arthroscopy*. 2018;**34**:3046–3052.
 - 19) Smith ID, Irfan A, Huntley JS, *et al.* What is the best treatment for a child with an acute tear of the anterior cruciate ligament? *J Paediatr Child Health*. 2018;**54**:1037–1041.
 - 20) Gupta R, Sood M, Malhotra A, *et al.* Incidence, risk factors, and management of infection following anterior cruciate ligament reconstruction surgery. *Indian J Orthop*. 2018;**52**:399–405.
 - 21) Mishra P, Lal A, Mohindra M, *et al.* Incidence, management and outcome assessment of post operative infection following single bundle and double bundle acl reconstruction. *J Clin Orthop Trauma*. 2018;**9**:167–171.
 - 22) Kawata M, Sasabuchi Y, Taketomi S, *et al.* Atopic dermatitis is a novel demographic risk factor for surgical site infection after anterior cruciate ligament reconstruction. *Knee Surg Sports Traumatol Arthrosc*. 2018;**26**:3699–3705.
 - 23) Ishikawa H, Kuriyama S, Hoshida T, *et al.* Anterior cruciate ligament reconstruction using dialation system. *Orthop Surg*. 2002;**53**:1712–1716. (in Japanese).
 - 24) Shiotani E, Kuriyama S, Watanabe M, *et al.* Recent trends in ski and snowboard-related injuries in the Ishiuchimayama ski slope (part 2): characteristics of skiboard-related injuries and “air injuries (jumping injuries)”. *J Showa Med Assoc*. 2005;**65**:385–393. (in Japanese).
 - 25) Schollin-Borg M, Michaelsson K, Rahme H. Presentation, outcome, and cause of septic arthritis after anterior cruciate ligament reconstruction: a case control study. *Arthroscopy*. 2003;**19**:941–947.
 - 26) Hamano K. Kansensho ni kansuru Q&A pobidonyodo nado shodokuzai ni yoru jizoku senjo ryoho no koka to mochiikataha? *OS NOW*. 1993;**11**:178–179. (in Japanese).
 - 27) Haley CE, Marling-Cason M, Smith JW, *et al.* Bactericidal activity of antiseptics against methicillin resistant *Staphylococcus aureus*. *J Clin Microbiol*. 1985;**21**:991–992.
 - 28) Barbier O, Danis J, Versier G, *et al.* When the tendon autograft is dropped accidentally on the floor: a study about bacterial contamination and antiseptic efficacy. *Knee*. 2015;**22**:380–383.

[The publication of this paper was given a priority date]