

## Case Report

# Treatment of a Patient with Class I Malocclusion and Severe Tooth Crowding Using Invisalign and Fixed Appliances

Yumiko OGURA, Wakana YANAGISAWA, Mami SUGIURA, Yuko FUJITA,  
Tetsutaro YAMAGUCHI and Koutaro MAKI

*Department of Orthodontics, Showa University School of Dentistry  
2-1-1 Kitasenzoku, Ohta-ku, Tokyo, 145-8515 Japan*

**Abstract:** The Invisalign system is widely used to treat mild to moderate tooth crowding. Recently, Invisalign appliances have been used in orthodontic patients with increasingly complex malocclusions. When using an Invisalign appliance to correct severe tooth crowding, root positions must be carefully controlled during extraction space closure. We report our treatment of a 34-year-old man who presented with a Class I relationship, a midline deviation, severe overjet, and severe tooth crowding in the maxillary and mandibular anterior regions. The treatment plan involved extraction of the maxillary and mandibular first premolars on both sides. We treated this patient with severe anterior tooth crowding using an Invisalign appliance combined with a fixed appliance with power arms and elastics. Treatment by Invisalign as an application of computational calculated result, especially in extraction cases, doctors should have professional skill and experience as an orthodontist.

**Key words:** Invisalign, bowing effect, attachment, elastics, power arm.

Align Technology first introduced Invisalign<sup>1)</sup> to the market in 1999. The Invisalign system has been used successfully to treat mild to moderate tooth crowding,<sup>2,3)</sup> and recently has been used in cases of more severe crowding involving extractions.<sup>4,5)</sup> When using the Invisalign appliance to correct severe crowding, root positions must be carefully controlled during extraction space closure, and the aligners must properly grip all teeth to be moved.<sup>6)</sup> Tipping was a common problem in premolar extraction cases during the early years of Invisalign use,<sup>7)</sup> and longitudinal clinical trials have confirmed the potential limitations of Invisalign in terms of tooth movement, with tipping movements being the most predictable.<sup>8)</sup> Several previous reports have also discussed the limited ability of thermoplastic appliances to control root-tipping movements and to establish root control comparable to that provided by fixed appliances.<sup>9~11)</sup> This article describes our treatment of a patient with severe tooth crowding and Class I malocclusion using an Invisalign appliance combined with a fixed appliance, power arms, and elastics.

## Case Report

A 34-year-old man presented with a Class I relationship showing a midline deviation, severe overjet, and severe tooth crowding in the maxillary and mandibular anterior regions (Figs. 1, 2). His chief complaint was anterior crowding, therefore we treated for the purpose of improvement of crowding and establishment of molar relationship. The treatment plan included bilateral extraction of the maxillary and mandibular first premolars, and fixation using an Invisalign appliance combined with direct-bonded attachments on the maxillary and mandibular molars. Fifty aligners were used for the maxillary and mandibular arches. The vertical rectangular attachments were fixed to the maxillary canines and second premolars on both sides, to the maxillary left canine, and to the mandibular canines and second premolars on both sides (Fig. 3). Invisalign ClinCheck software<sup>1)</sup> (computational tooth movement simulation software which applied on internet.) can be used for diagnosis, visualization of treatment results,

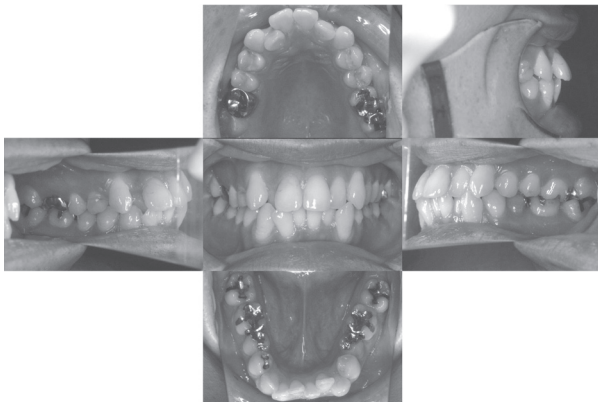


Fig. 1 Pre-treatment. Class I malocclusion on both sides with a midline deviation, severe overjet, and tooth crowding in the maxillary and mandibular anterior regions.

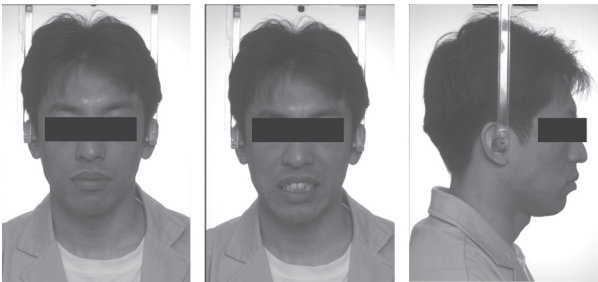


Fig. 2 Pre-treatment facial.

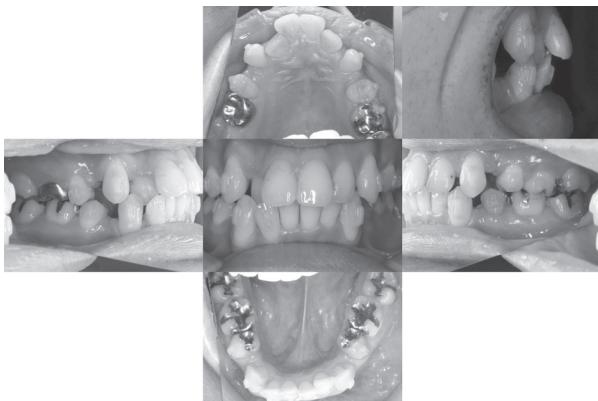


Fig. 3 Attachments fixed to the maxillary canine and second premolar on both sides, the left maxillary canine, and the mandibular canine and second premolar on both sides. All were rectangular attachments and longer than they were wide.

and sharing of information with the patient and dental colleagues throughout treatment. Initially, Class I molar relationship was kept during canine retraction and lingual movement of anterior in ClinCheck planning (Fig. 4).

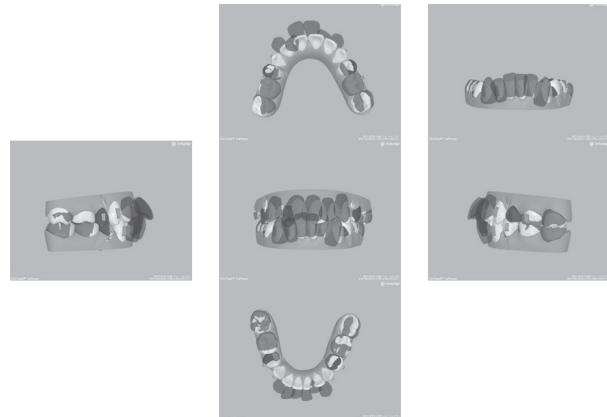


Fig. 4 The Invisalign ClinCheck system was used to execute maxillary and mandibular canine retraction on both sides, and anterior tooth retraction, with the aim of relieving crowding of the maxillary and mandibular anterior teeth, and of reducing the overjet.

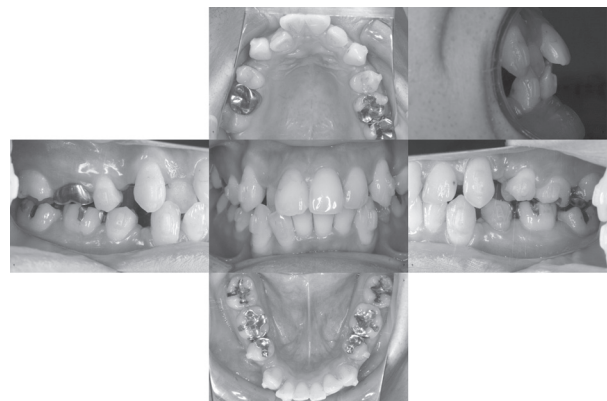


Fig. 5 Unexpected distal inclination of the maxillary and mandibular canines on the right side, and mesial inclination of the upper and lower second premolars and first molars (bowing effect).

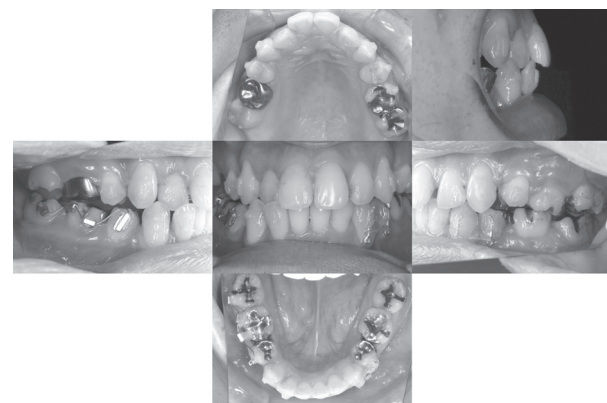


Fig. 6 Fixed appliance with power arms and elastics.

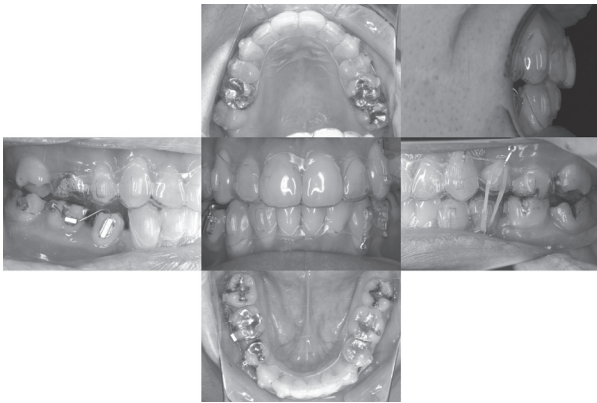


Fig. 7 Extrusion of the maxillary and mandibular second premolars on the left side using elastics.

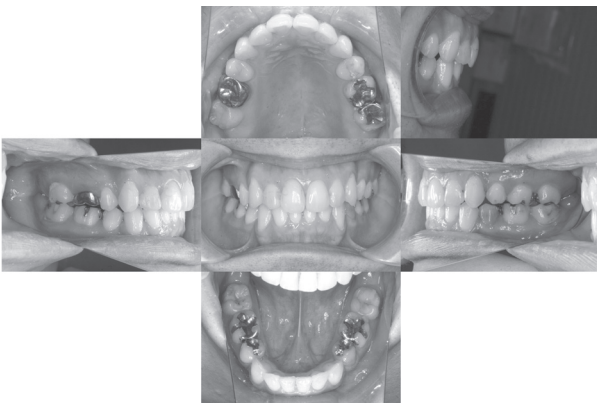


Fig. 8 Treatment results.

To relieve this situation, tubes (power arms) were bonded to the right mandibular premolars, first molar, and second molar. Power arms were also attached to the left mandibular canine and second premolar to further alleviate the bowing effect. Subsequently, we started the elastic-combined Invisalign treatment (Fig. 6).

After 45 aligners, space closing was almost complete for the maxillary and mandibular first premolars on both sides. However, mesial movement of the second premolar and first molar was still required to close the space between these teeth. Consequently, power arms were bonded to the left maxillary canine and second premolar, and the left maxillary and mandibular second premolars were extruded using elastics (Fig. 7). After these treatments, acceptable occlusion was established (Figs. 8, 9). The patient wore aligners for retention, and the results remained stable during maintenance.

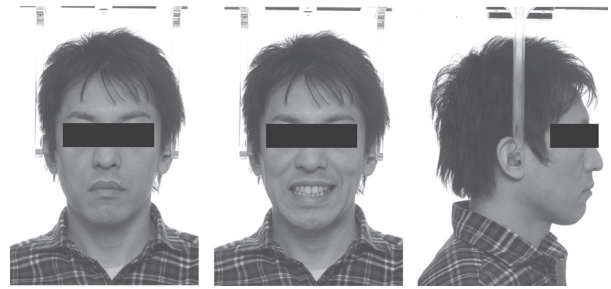


Fig. 9 Post-treatment facial.

## Discussion

We treated severe tooth crowding using the Invisalign ClinCheck system. During the anterior retraction stage, we encountered unexpected tooth movement, especially in the molar mandibular region. Acceptable occlusion was eventually achieved by applying a fixed appliance with power arms and elastics in combination with the Invisalign aligners.

Appropriate case selection is important in cases similar to the one reported here to ensure optimal results.<sup>12)</sup> Align Technology provides guidelines for the types of malocclusion that can be successfully treated with Invisalign. That indicated mild to moderate crowding (discrepancy:  $-1.0$  to  $-6.0$  mm), and/or spacing ( $+1.0$  to  $+6.0$  mm), non-skeletal constricted arches, and relapse after fixed appliance therapy.<sup>13)</sup> In the present case, to improve the labial inclination of upper and lower incisors, large space were required by four premolar extraction. Cases for which Invisalign is indicated include mild to moderate crowding (1–6 mm), mild to moderate spacing (1–6 mm), non-skeletal constricted arches, and relapse after fixed appliance therapy.<sup>13)</sup> In the present case, labial inclination of the upper and lower incisors needed improvement after the initial treatment, requiring additional space which was generated by extraction of all four first premolars. However, Invisalign has been used successfully in other cases of severe crowding involving extractions.<sup>14, 15)</sup>

Recent advances in Invisalign treatment include attachment designs that improve three-dimensional control of tooth movement.<sup>14)</sup> The attachments are

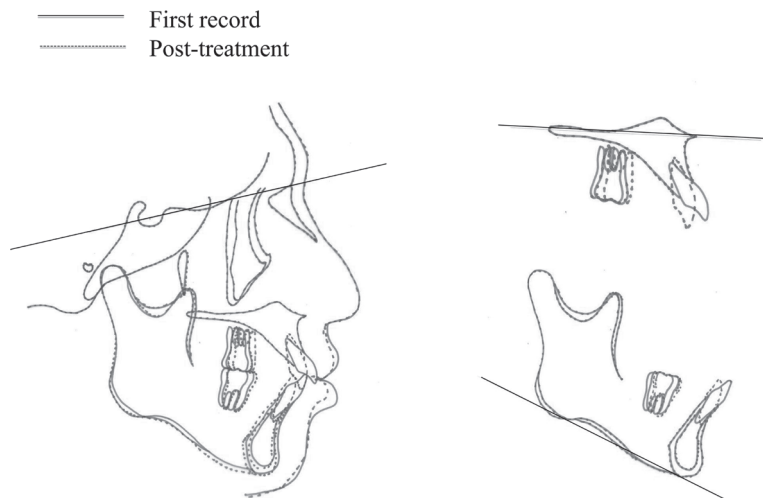


Fig. 10 Cephalometric superimposition.

bonded to the teeth to provide a mechanical lock and to allow several intrusions. Such attachments are critical in extraction cases.<sup>15)</sup>

In the present case, we used approximately 30 aligners to complete retraction of the anterior teeth. However, the unexpected distal tipping of the canines and mesial tipping of the second premolars and first molars caused a bowing effect. Power arms were successfully used to relieve this condition by preventing canine tipping and posterior mesial tipping. In this case, the power arm comprised 0.016×0.016 in stainless steel wire. Metal power arms were covered by composite resin and used as attachment and cantilever for eliminating the tipping movement.

This approach was used to improve the bowing effect and unfit aligners. Additionally, the patient wore Class II elastics (3/16 in medium, 4 oz) that extended from the mesial aspect of the maxillary and mandibular molars to a fixed partial lower appliance with power arms. Elastic hooks were also bonded to the maxillary left second premolar and mandibular left second premolar (Fig. 7). By intermaxillary elastics with power arms, effective extrusions of second premolars were demonstrated. From cephalometric analysis, Labial inclinations of upper and lower incisors were totally improved. Though maximum anchorage settled in initial ClinCheck, mesial tipping of upper and lower molars were observed (Fig. 10, Table 1).

Table 1 Cephalometric analysis.

Angular (°)	Norm	First Record 34Y5M	Post-Treatment 41Y8M
SNA	81.8	81.7	79.4
SNB	78.6	76.3	74.0
ANB	3.3	5.5	5.4
Gonial angle	116.3	120.6	119.8
Ramus inclination	87.4	85.8	87.4
Occlusal plane angle	9.5	9.6	13.8
U-1 FH plane angle	108.9	121.9	103.4
FMA	26.3	26.4	27.2
IMPA	94.7	104.3	89.8
FMIA	59.0	49.3	62.9

This report demonstrates that in patients with severe tooth crowding requiring extraction, combining Invisalign with fixed appliances, power arms, and elastics can be a reasonable treatment option.

Even though treatment by Invisalign as an application of computational calculated result, especially in extraction cases, treatment by Invisalign is still in need of orthodontists' skill and experience.

## References

- 1) Registered trademark of Align Technology, Inc., 881 Martin Ave, Santa Clara, CA 95050: [www.aligntech.com](http://www.aligntech.com).
- 2) Boyd RL, Miller RJ, Vlaskalic V: The Invisalign system in adult orthodontics: Mild crowding and space closure cases. *J Clin Orthod*, **34**: 203–212, 2000
- 3) Vlaskalic V, Boyd RL: Orthodontic treatment of a mildly crowded malocclusion using the Invisalign system. *Austral Orthod J*, **17**: 41–46, 2001

- 4) Womack WR: Four-premolar extraction treatment with Invisalign. *J Clin Orthod*, **40**: 493–500, 2006
- 5) Hönn M, Göz G: A premolar extraction case using the Invisalign system. *J Orofac Orthop*, **67**: 385–394, 2006
- 6) Giancotti A, Di Girolamo R: Treatment of severe maxillary crowding using Invisalign and fixed appliances. *J Clin Orthod*, **43**: 583–589, 2009
- 7) Boyd RL: Complex orthodontic treatment using a new protocol for the invisalign appliance. *J Clin Orthod*, **41**: 525–547, 2007
- 8) Bollen AM, Huang G, King G, Hujoel P, Ma T: Activation time and material stiffness of sequential removable orthodontic appliances, Part I: Ability to complete treatment. *Am J Orthod*, **124**: 496–501, 2003
- 9) Hahn W, Zapf A, Dathe H, Fialka-Fricke J, Fricke-Zech S, Gruber R, Kubein-Meesenburg D, Sadat-Khonsari R: Torquing an upper central incisor with aligners—acting forces and biomechanical principles. *Eur J Orthod*, **32**: 607–613, 2010
- 10) Brezniak N: The clear plastic appliance: A biomechanical point of view. *Angle Orthod*, **78**: 381–382, 2008
- 11) Baldwin DK, King G, Ramsay DS, Huang G, Bollen AM: Activation time and material stiffness of sequential removable orthodontic appliances, Part 3: Premolar extraction patients. *Am J Orthod*, **133**: 837–845, 2008
- 12) Crosby D, Lee J: A patient-classification system for invisalign cases. *J Clin Orthod*, **43**: 502–506, 2009
- 13) McNamara JA, Brudon WL: *Orthodontics and Dentofacial Orthopedics*. Ann Arbor, MI, USA, 2001, Needham Press
- 14) Marcuzzi E, Galassini G, Procopio O, Castaldo A, Contardo L: Surgical-invisalign treatment of a patient with class III malocclusion and multiple missing teeth. *J Clin Orthod*, **44**: 377–384, 2010
- 15) Womack WR: Four-premolar extraction treatment with invisalign. *J Clin Orthod*, **40**: 493–500, 2006