

Showa Univ J Med Sci 22(1), 69~72, March 2010

## Case Report

# Solitary Peutz-Jeghers Type Colorectal Polyp with Hamartoma-adenoma-carcinoma Sequence in a Non-Peutz-Jeghers Syndrome Patient

Shuei ARIMA, Toshiaki KUNIMURA, Kai MATSUO,  
Takahiro HOB0, Koji NOGAKI, Kaoru KATO,  
Hisashi HOSAKA, Koji SAITO, Tomoko SUGIYAMA  
and Toshio MOROHOSHI

**Abstract:** Peutz-Jeghers (P-J) syndrome is an inherited disorder characterized by multiple hamartomatous gastrointestinal polyps, mucocutaneous pigmentation, and an increased risk of both digestive tract and non-digestive tract cancers. P-J type polyps are characteristic of P-J syndrome but rarely present as solitary polyps. Though cancerous lesions frequently develop from polyposis in P-J syndrome, reports of malignancy in solitary colorectal P-J type polyps are rare; our literature search identified only two examples. This report describes a non-Peutz-Jeghers syndrome patient with a solitary P-J type polyp showing the hamartoma-adenoma-carcinoma sequence.

**Key words:** Peutz-Jeghers type polyp, hamartoma-adenoma-carcinoma sequence, non-Peutz-Jeghers syndrome patient, hyperplasia of the lamina muscularis mucosa, desmin

## Introduction

A Peutz-Jeghers (P-J) type polyp is a hamartomatous polyp that occurs in patients with P-J syndrome, but is rarely found as a solitary polyp in non-P-J syndrome patients<sup>1)</sup>. There have been some reports of polyposis and cancerous transformation in patients with P-J syndrome, but few reports of solitary P-J type polyps containing cancer foci<sup>2,3)</sup>. We report here a rare case of a colorectal P-J type polyp showing the hamartoma-adenoma-carcinoma sequence in a non-Peutz-Jeghers syndrome patient.

## Case Report

A 48-year-old woman was admitted to our hospital for medical examination. Colonoscopy revealed a solitary pedunculated polyp, 10×10×8 mm in size, in the sigmoid colon, and polypectomy was performed. No abdominal symptoms were present, and carcinomatous

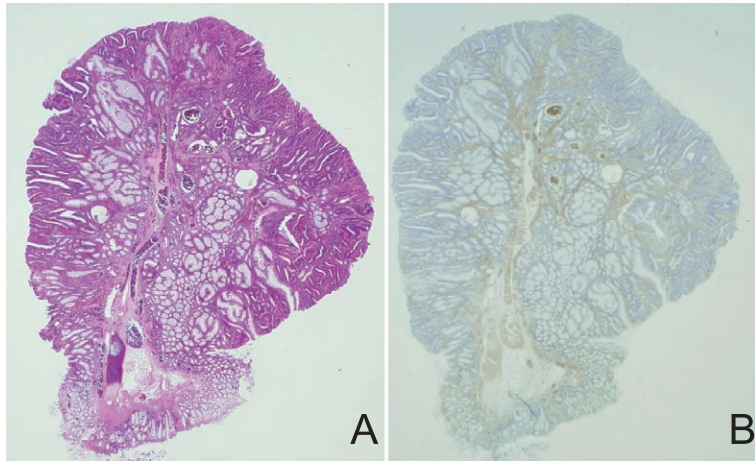


Fig. 1. Low-power view of the polyp (original magnification,  $\times 1.25$ )  
 A: The polyp showed hyperplasia of the hamartomatous gland supported by hyperplasia of the lamina muscularis mucosa.  
 B: The lamina muscularis mucosa was immunohistochemically positive for desmin.

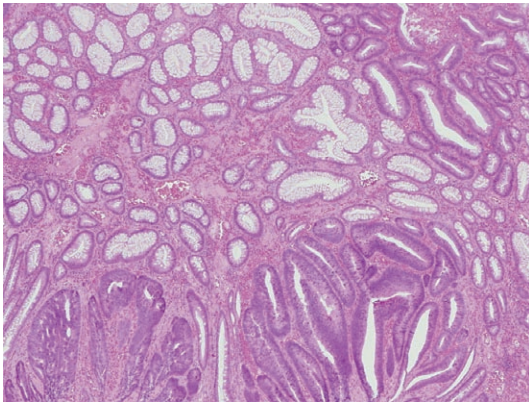


Fig. 2. Medium-power view of the polyp (original magnification,  $\times 10$ )  
 Adenoma component (right upper part) and adenocarcinoma component (lower part) are shown in the hamartomatous glands.

merger of other organs was not found in other parts of the alimentary canal. There was no unusual mucocutaneous pigmentation. The patient had been healthy, but a uterine leiomyoma had been detected at 36 years of age. No hereditary disease was identified in her family.

Histopathologically, the polyp showed hyperplasia of a hamartomatous gland supported by hyperplasia of the lamina muscularis mucosa, which was immunohistochemically positive for desmin (Fig. 1). In addition, hyperplasia of the low grade adenomatous gland was observed around the cupular part of the polyp. Furthermore, the polyp contained well-differentiated adenocarcinoma-like foci, but the cancer cells remained in the mucosa without further invasion. We diagnosed the polyp as a well-differentiated tubular adenocarcinoma within adenoma within hamartoma (Fig. 2).

The postoperative course was good and the patient was discharged from the hospital on the next day. Curative resection of the polyp was performed endoscopically and the lesion required no further treatment the patient was monitored as an outpatient.

## Discussion

In P-J syndrome, gastrointestinal polyposis and excessive deposition of mucosal melanin in the skin are pathognomonic. However, for the solitary P-J type polyp, in the alimentary canal is rare, though the small intestine is the favored location for polyps in general, as well as in P-J syndrome. Only 27 previous case reports of solitary P-J type polyps were found. In the reports of Lantz *et al*<sup>1)</sup>, Oncel *et al*<sup>2)</sup> and Sone *et al*<sup>4)</sup>, 16 males and 11 females were discussed. One polyp was located in the stomach, 21 were in the small intestine, and five were found in the large intestine. Only two cases of cancerous transformation in a solitary P-J-type polyp have been reported to date. One is the case of Ichiyoshi *et al* in which the polyp was located in the duodenum<sup>3)</sup>, and the other is the report of a colorectal P-J polyp by Oncel *et al*<sup>2)</sup>. The present case is the 2nd case report of cancerous transformation in a colorectal Peutz-Jeghers-type polyp.

P-J syndrome is an autosomal dominant disorder characterized by pigmentation of skin mucosa and alimentary canal polyposis with an increased risk of cancerous transformation<sup>5)</sup>. In the P-J syndrome cases of Narita *et al*, 52 polyps were examined, and the incidence of the neoplastic changes, such as the development of adenomas or carcinomas, was about 6%<sup>6)</sup>. Perzin and Bridge reported an examination of more than 100 P-J syndrome polyps and the incidence was about 3%<sup>7)</sup>. In non-P-J syndrome, the risk of cancer development from a P-J type polyp is not well understood. Solitary P-J type polyps are histologically similar to those observed in P-J syndrome, but the hereditary element is absent, and their malignant potential is unclear.

In Cronkhite-Canada syndrome, juvenile polyposis and Cowden syndrome, adenomatous and carcinomatous changes are also seen on the luminal surface. Nonomura *et al* found that eight of 54 patients had gastrointestinal carcinoma (about 15%) in Cronkhite-Canada syndrome<sup>8)</sup>. Another study examined ninety-nine juvenile polyposis patients who underwent 138 gastrointestinal operations, and the incidence of a gastrointestinal carcinoma was about 17%<sup>9)</sup>. However, in Cowden syndrome, the risk of malignant transformation in gastrointestinal polyps is still unclear<sup>10)</sup>.

The hypothesis of hamartoma-adenoma-carcinoma sequence has been suggested for cancerous transformation in hamartomatous polyps<sup>11)</sup>. In our present case, the tumor component was predominantly tubular adenoma, containing foci of adenocarcinoma. This suggests that the cancer-causing mechanism in our case is not only similar to usual carcinogenic process in colorectal cancer (namely the adenoma-carcinoma sequence<sup>12)</sup>), but seems to support the hypothesis of the hamartoma-adenoma-carcinoma sequence.

**References**

- 1) Lantz H, Doos WG and Affi A: Peutz-Jeghers-type hamartomatous polyp in a patient without Peutz-Jeghers syndrome. *Gastrointest Endosc* **60** : 316-317 (2004)
- 2) Oncel M, Remzi FH, Church JM, Goldblum JR, Zutshi M and Fazio VW: Course and follow-up of solitary Peutz-Jeghers polyps : a case series. *Int J Colorectal Dis* **18** : 33-35 (2003)
- 3) Ichiyoshi Y, Yao T, Nagasaki S and Sugimachi K: Solitary Peutz-Jeghers type polyp of the duodenum containing a focus of adenocarcinoma. *Ital J Gastroenterol* **28** : 95-97 (1996)
- 4) Sone Y, Nakano S, Takeda I and Kumada T: Solitary hamartomatous polyp of Peutz-Jeghers type in the jejunum resected endoscopically. *Gastrointest Endosc* **51** : 620-622 (2000)
- 5) Kazuoki H, Mitsuo I, Takayuki M, Kohrogi N, Kinoshita H, Yao T and Fujishima M: Cancer in Peutz-Jeghers syndrome. *Cancer* **72** : 2777-2781 (1993)
- 6) Narita T, Eto T and Ito T: Peutz-Jeghers syndrome with adenomas and adenocarcinomas in colonic polyps. *Am J Surg Pathol* **11** : 76-81 (1987)
- 7) Perzin KH and Bridge MF: Adenomatous and carcinomatous changes in hamartomatous polyps of the small intestine (Peutz-Jeghers syndrome) : report of case and review of the literature. *Cancer* **49** : 971-983 (1982)
- 8) Nonomura A, Ohta G, Ibata T, Shinozaki K and Nishino T: Cronkhite-Canada syndrome associated with sigmoid cancer. *Acta Pathol Jpn* **30** : 825-845 (1980)
- 9) Coburn MC, Pricolo VE, DeLuca FG and Bland KI: Malignant potential in intestinal juvenile polyposis syndrome. *Ann Surg Oncol* **2** : 386-391 (1995)
- 10) Bosserhoff AK, Grussendorf-Conen EI, Rübber A, Rudnik-Schöneborn S, Zerres K, Buettner R and Merkelbach-Bruse S: Multiple colon carcinomas in a patient with Cowden syndrome. *Int J Mol Med* **18** : 643-647 (2006)
- 11) Bosman FT: The hamartoma-adenoma-carcinoma-sequence. *J Pathol* **188** : 9-13 (1999)
- 12) Muto T, Bussey HJ and Morson BC: The evolution of cancer of the colon and rectum. *Cancer* **36** : 2251-2270 (1975)

[Received December 24, 2009 : Accepted January 14, 2010]