

Showa Univ J Med Sci 22(2), 143~149, June 2010

## Case Report

# Mandibular Deviation and Unilateral Posterior Crossbite Treated with Intraoral Vertical Ramus Osteotomy and Sagittal Split Ramus Osteotomy

Tetsutaro YAMAGUCHI and Koutaro MAKI

**Abstract :** Adult patients with severe mandibular asymmetry are often treated with a combination of surgery and orthodontic treatment to improve facial esthetics and occlusion. Intraoral vertical ramus osteotomy is a useful surgical procedure for mandibular setback in patients with mandibular prognathism or mandibular asymmetry. A 17-year-old woman presented with a Class III malocclusion with facial asymmetry and a unilateral posterior crossbite. The patient was treated orthodontically with edgewise appliances and surgically with intraoral vertical ramus osteotomy and sagittal split ramus osteotomy. The combined surgical-orthodontic treatment resulted in facial symmetry and optimal occlusion.

**Key words :** mandibular asymmetry, intraoral vertical ramus osteotomy, orthodontic treatment

## Introduction

Compared with sagittal split ramus osteotomy (SSRO), intraoral vertical ramus osteotomy (IVRO) with modified condylotomy results in a lower incidence of inferior alveolar nerve damage<sup>1,2)</sup>, requires a shorter operation time<sup>3)</sup>, and frequently affords a favorable relationship between the condyle and articular disc thereby increasing the chance of improved temporomandibular joint (TMJ) symptoms<sup>4-6)</sup>. IVRO is a suitable method for achieving stable mandibular results in cases of severe asymmetry<sup>7,8)</sup>. This case report demonstrates the clinical value of a combination treatment using unilateral IVRO and SSRO in a patient with facial asymmetry.

## Case Report

A 17-year-old woman presented with midline deviation of her upper and lower incisors. She had esthetic concerns about her mandibular asymmetry (Fig. 1). The patient had received regular dental care and had undergone minimal restorative dentistry. She had no history of trauma or serious illness, and no family history of disturbed tooth eruption or mandibular asymmetry.

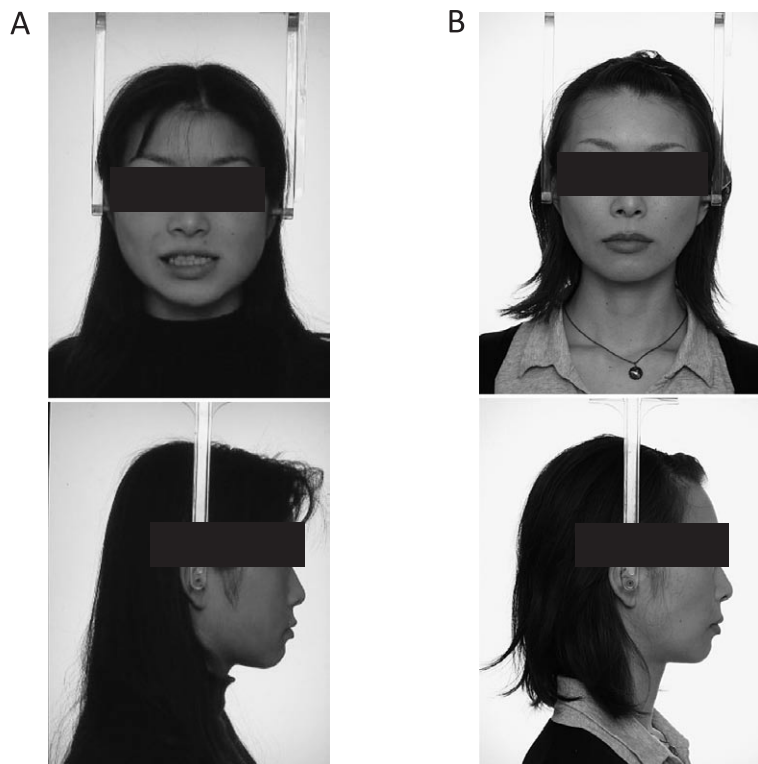


Fig. 1. Facial photographs  
A : Pre-treatment (age : 17y10mo). B : Post-treatment (age : 27y0mo).

Table 1. Cephalometric analysis

Angular measurements (°)	Normal	Pre-Treatment 17y10mo	Post-Treatment 27y0mo
SNA	82.3	81.0	81.7
SNB	78.9	79.9	77.6
ANB	3.4	1.1	4.1
Gonial angle	121.2	118.1	118.8
Ramus inclination	87.1	86.4	87.7
Occlusal plane angle	11.4	6.5	13.6
U-1 FH plane angle	111.1	118.9	111.4
FMA	28.8	24.5	26.5
IMPA	96.3	94.7	107.2
FMIA	54.6	60.9	46.3
Linear measurements (mm)			
A'-Ptm'	48.3	46.9	48.8
Gn-Cd	119.3	118.7	117.7
Pog'-Go	77.2	78.9	77.4
Cd-Go	62.4	62.6	63.0

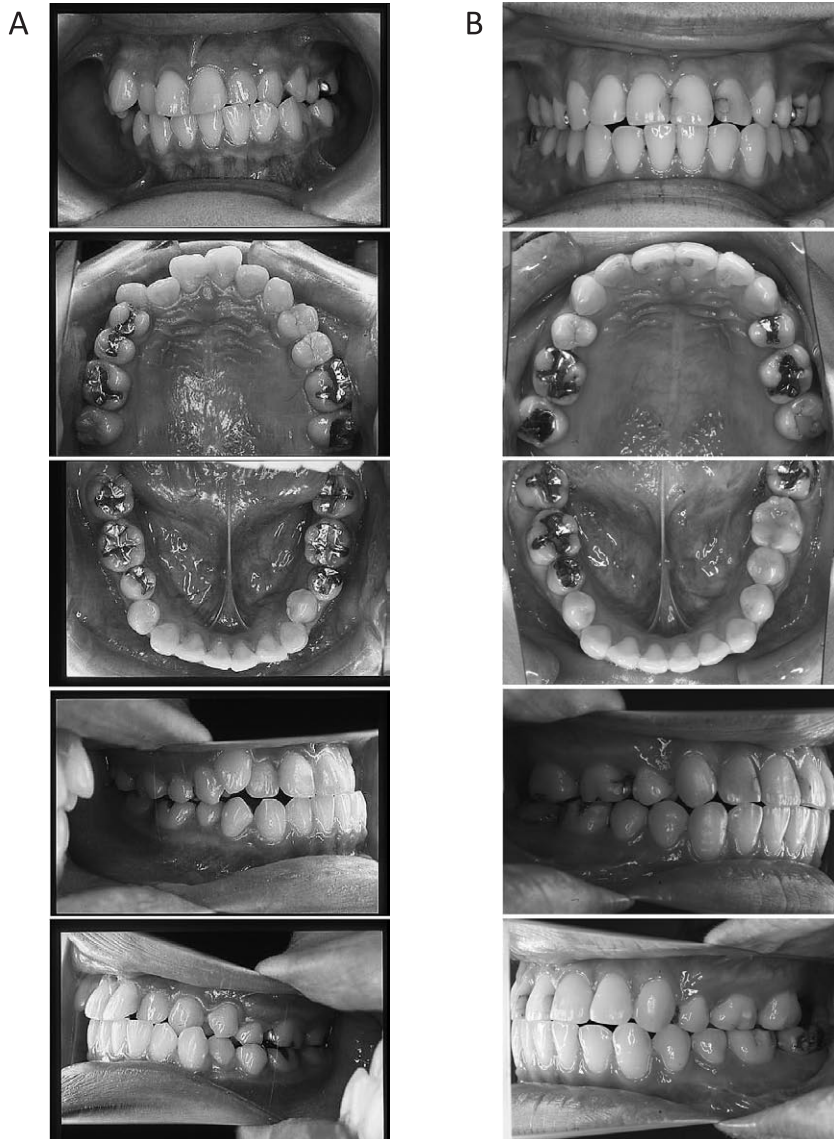


Fig. 2. Intraoral photographs  
 A : Pre-treatment (age : 17y10mo). B : Post-treatment (age : 27y0mo).

The patient was diagnosed with a Class III skeletal malocclusion with overgrowth of the mandible (SNB: Sella turcica- Nasion- Point B,  $79.9^\circ$ , ANB: Point A- Nasion- Point B,  $+1.1^\circ$ ) (Table 1). The normal values in Table 1 were obtained from Iizuka and Ishikawa (3). A Class III occlusion was present on the right side and a Class II occlusion on the left side (Fig. 2). Severe crowding of the maxillary arch was evident and the patient had a unilateral posterior crossbite (Fig. 2). The upper dental midline was 4.0 mm to the right of the facial midline, and the lower dental midline was 3.5 mm to the left of the facial midline

(Fig. 2). The patient had normal jaw movement and no significant symptoms of temporomandibular joint disorder (TMD).

The treatment objectives were to 1) establish a Class II molar relationship through extraction of the upper first-premolar tooth on both sides, 2) obtain proper interdigitation, a Class I canine relationship, and an ideal overbite and overjet, and 3) correct the mandibular deviation and facial asymmetry.

Before the start of orthodontic treatment, an occlusal splint was placed in the maxilla to establish a stable mandibular position (July 1998). Lower teeth were fitted with conventional fixed appliances using 0.014-inch stainless steel edgewise arch brackets (October 1998). Upper teeth were fitted with conventional fixed appliances using 0.014-inch stainless steel edgewise arch brackets (January 1999). The mandibular left third molar and mandibular left first molar were extracted (August 2001). SSRO and IVRO of the mandible were then performed to correct the anteroposterior occlusion and facial asymmetry (March 2002). The mandible was set back 7.0 mm on the right side by the SSRO and 1.0 mm on the left side by the IVRO. After a 1-week period of intermaxillary fixation, orthodontic treatment was resumed. After release of fixation, the patient underwent neuromuscular and occlusal rehabilitation for 3 months using elastic tractions. The force vectors for the elastic tractions were vertical or light Class III. After final arch coordination and minimal occlusion equilibration were accomplished, all fixed appliances were removed and the patient was given removable maxillary and mandibular retainers (September 2008).

Overall facial esthetics were improved by the mandibular setback (Fig. 1). The occlusal result was excellent (Fig. 2), finishing with a Class I canine relationship. A Class II molar relationship was accomplished on both sides following extraction of the upper first-premolar teeth (Fig. 2). The final overbite and overjet relationships were ideal (Fig. 2), and the posterior crossbite on the left side was improved. Maxillary and mandibular dental midlines were rendered coincident with the facial midline. The mandible was moved 5 mm posteriorly (Fig. 3). Cephalometric improvements included an increase in the ANB angle from  $1.1^\circ$  to  $4.1^\circ$ , and a reduction in the upper incisal edge to Frankfurt horizontal plane angle from  $118.9^\circ$  to  $111.4^\circ$  (Table 1).

## Discussion

Orthognathic surgery is designed to correct skeletal imbalances in the craniofacial region and to improve the functional maxillomandibular relationship<sup>8)</sup>. IVRO has previously achieved stable mandibular results in cases of severe mandibular asymmetry<sup>9,10)</sup>. In this case study, a combination of orthodontic treatment and unilateral IVRO and SSRO improved both the occlusion and facial appearance.

Few studies have addressed postoperative stability following an IVRO procedure. In animal studies, an anterior open bite was found in all monkeys on release of the intermaxillary fixation after IVRO, which may be related to "condylar sag" associated with the IVRO<sup>11)</sup>.

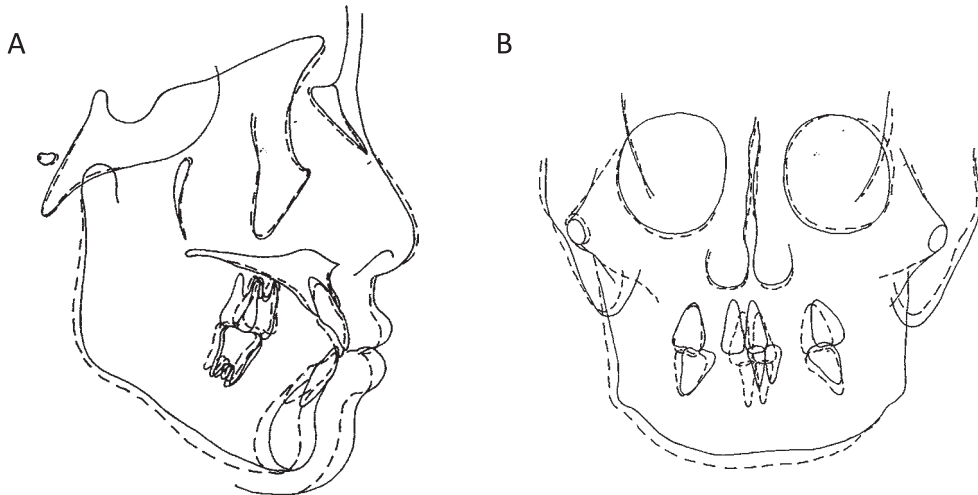


Fig. 3. Cephalometric superimposition (A: S-N at S, B: ZL-ZR line). Black line: pre-treatment (age: 17y10mo) and dotted line: post-treatment (age: 27y0mo).

Although IVRO procedures are thought to favor the TMJ because of anterior-inferior repositioning of the condyle, marked changes in backward rotation at the landmarks point B, Pogonion, and Menton have been reported after release of the maxillomandibular fixation, compared with cases undergoing SSRO<sup>12)</sup>. Patients with asymmetric Class III malocclusion are more prone to horizontal relapse of the mandible, due to the difference in right and left setback, and to mediolateral displacement in the posterior margin of the distal bone segment while rotating the mandibular dentition to correct its deviation<sup>13-15)</sup>. Elastic tractions play an important role in stability after IVRO and release of the maxillomandibular fixation, and these devices should be used for at least 3 months after surgery to functionally control the postsurgical mandibular positions<sup>16)</sup>.

Beyer and Lindauer<sup>17)</sup> suggested a maximum esthetically acceptable dental midline deviation of 2.2 mm, with larger deviations easily detectable by most individuals. Similarly, Lai and colleagues<sup>13)</sup> only included patients with mandibular midline deviations larger than 2 mm when studying the stability of one-jaw surgery. The present case underwent successful mandible rotation to correct the facial asymmetry with midline deviation, resulting in alignment of the maxillary and mandibular dental midlines with the facial midline.

Fortunately, this patient did not have TMD symptoms. Although the prevalence of TMD has increased in general and orthodontic adult patients, the relationship between TMD and dentofacial morphology remains controversial. Orthodontic patients with internal derangement of the TMJ often have vertical mandibular asymmetry<sup>18)</sup>, and a group of patients with mandibular deviation greater than 4 mm showed a high incidence of severe TMD and facial deviation<sup>19)</sup>. Skeletal open bite or overjet greater than 6 to 7 mm, retruded cuspal position / intercuspal position, occlusal slides greater than 4 mm, unilateral posterior crossbite, and

5 or more missing posterior teeth might also be associated with TMD<sup>20</sup>).

In this case study, a patient with a Class III malocclusion, facial asymmetry, and a unilateral posterior crossbite was successfully treated with a combination of surgical (IVRO and SSRO) and orthodontic procedures, resulting in facial symmetry and optimal occlusion.

## References

- 1) Hall HD, Chase DC and Payor LG : Evaluation and refinement of the intraoral vertical subcondylar osteotomy. *J Oral Surg* **33** : 333-341 (1975)
- 2) Hall HD : Mandibular prognathism. In : *Modern Practice in Orthognathic and Reconstructive Surgery*, Bell WH (ed), Saunders, Philadelphia, pp 2111-2137 (1992)
- 3) Ghali GE and Sikers JW Jr : Intraoral vertical ramus osteotomy as the preferred treatment for mandibular prognathism. *J Oral Maxillofac Surg* **58** : 313-315 (2000)
- 4) Hall HD, Navarro EZ and Gibbs SJ : One- and three-year prospective outcome study of modified condylotomy for treatment of reducing disc displacement. *J Oral Maxillofac Surg* **58** : 7-17 (2000)
- 5) Hall HD, Navarro EZ and Gibbs SJ : Prospective study of modified condylotomy for treatment of nonreducing disk displacement. *Oral Surg Oral Med Oral Pathol Oral Radiol Endod* **89** : 147-158 (2000)
- 6) Choi YS, Yun KI and Kim SG : Long-term results of different condylotomy designs for the management of temporomandibular joint disorders. *Oral Surg Oral Med Oral Pathol Oral Radiol Endod* **93** : 132-137 (2002)
- 7) Iizuka T and Ishikawa H : Normal standards for various cephalometric analysis in Japanese adults. *J Jpn Orthod Soc* **16** : 4-12 (1957) (in Japanese)
- 8) Bell WH, Proffit WR and White RP : Surgical ramus osteotomy. In : *Surgical Correction of Dentofacial Deformities*. vol. 2, Saunders, Philadelphia, pp 890-895 (1980)
- 9) Nwoku AL, Palomero-Rodriguez R and Horch HH : The problems of correction of asymmetric mandibular prognathism. *Int J Oral Surg* **3** : 229-233 (1974)
- 10) Lai SS, Tseng YC, Huang IY, Yang YH, Shen YS and Chen CM : Skeletal changes after modified intraoral vertical ramus osteotomy for correction of mandibular prognathism. *J Plast Reconstr Aesthet Surg* **60** : 139-145 (2007)
- 11) Zhao Q, Hu J, Wang D and Zhu S : Changes in the temporomandibular joint after mandibular setback surgery in monkeys : intraoral vertical versus sagittal split ramus osteotomy. *Oral Surg Oral Med Oral Pathol Oral Radiol Endod* **104** : 329-337 (2007)
- 12) Kitahara T, Nakasima A, Kurahara S and Shiratsuchi Y : Hard and soft tissue stability of orthognathic surgery. *Angle Orthod* **79** : 158-165 (2009)
- 13) Lai W, Yamada K, Hanada K, Ali IM, Takagi R, Kobayashi T and Hayashi T : Postoperative mandibular stability after orthognathic surgery in patients with mandibular protrusion and mandibular deviation. *Int J Adult Orthodon Orthognath Surg* **17** : 13-22 (2002)
- 14) Harada K, Ono J, Okada Y, Nagura H and Enomoto S : Postoperative stability after sagittal split ramus osteotomy with condylar-positioning appliance and screw fixation : asymmetric versus symmetric cases. *Oral Surg Oral Med Oral Pathol Oral Radiol Endod* **83** : 532-536 (1997)
- 15) Al-Gunaid T, Yamada K, Takagi R, Saito C and Saito I : Postoperative stability of bimaxillary surgery in Class III patients with mandibular protrusion and mandibular deviation : a frontal cephalometric study. *Int J Oral Maxillofac Surg* **37** : 992-998 (2008)
- 16) Yoshioka I, Khanal A, Tominaga K, Horie A, Furuta N and Fukuda J : Vertical ramus versus sagittal split osteotomies : comparison of stability after mandibular setback. *J Oral Maxillofac Surg* **66** : 1138-1144 (2008)
- 17) Beyer W and Lindauer SJ : Evaluation of dental midline position. *Semin Orthod* **4** : 146-152 (1998)
- 18) Wada K, Matsushita K, Shimazaki S, Miwa Y, Hasuike Y and Susami R : An evaluation of a new case analysis of a lateral cephalometric roentgenogram. *J Kanazawa Med Univ* **6** : 60-70 (1981) (in Japanese)
- 19) Maeda Y, Bandai H, Sugawara J and Mitani H : Relationship between the temporomandibular joint conditions

and the facial pattern – with emphasis on the facial asymmetry. *Orthod Waves* **60** : 25–34 (2001)

- 20) McNamara JA Jr, Seligman DA and Okeson JP: Occlusion, orthodontic treatment, and temporomandibular disorders : a review. *J Orofac Pain* **9** : 73–90 (1995)

[Received February 26, 2010 : Accepted March 18 2010]