

Showa Univ J Med Sci 24(3), 247~251, September 2012

Case Report

A Case of Intestinal Obstruction Secondary to a Strangulated Obturator Hernia in an Elderly Woman

Takahiro UMEMOTO, Ryuichi SEKINE, Hiroki MIZUKAMI,
Mitsuo SAITO, Gaku KIGAWA, Hiroshi NEMOTO
and Kenji HIBI

Abstract: In this report, we present a case of intestinal obstruction secondary to a strangulated obturator hernia in an elderly woman. An 88-year-old woman was admitted to our hospital because she had been experiencing abdominal pain and vomiting for 24 h. Her abdomen was distended, and bowel sounds indicating obstruction were heard on auscultation. Diffuse abdominal tenderness was present, but no palpable masses were apparent. The diagnosis of an obturator hernia was confirmed preoperatively by computed tomography. During the emergency laparotomy, the incarcerated intestine was reduced and removed. The obturator foramen was repaired using a simple suture. The patient recovered completely and was discharged seven days after the surgical procedure because no postoperative complications occurred. An early diagnosis and prompt surgical treatment are important to reduce the morbidity and mortality associated with an obturator hernia.

Key words: obturator hernia, intestinal obstruction

Introduction

An obturator hernia (OH) is a rare condition that is difficult to diagnose. Although only 0.073% of all hernias are of this type, the mortality rate of patients with this condition can be as high as 70%¹⁻⁴⁾. Most cases of intestinal obstruction in emaciated elderly women occur because of OH. In OH, the hernial sac passes through the obturator foramen, following the path of the obturator nerves and muscles.

Case Report

An 88-year-old woman was referred to our emergency department because she had been experiencing abdominal pain and vomiting for two days. The colicky pain was worsening and was accompanied by nausea and vomiting for 24 h, which were associated with diffuse abdominal pain. She had no relevant medical history. The patient was considered petite because her weight and height were 38 kg and 145 cm, respectively. Examination of

Department of Gastroenterological Surgery, Showa University Fujigaoka Hospital, 1-30 Fujigaoka, Aoba-ku, Yokohama 227-8501, Japan.

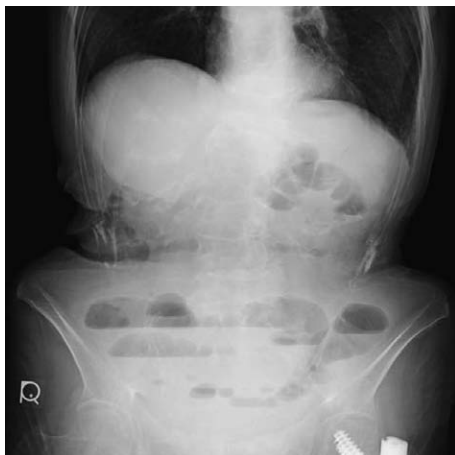

Fig. 1. Plain radiograph
Plain radiograph of the abdomen showing dilated small bowel loops with air fluid levels suggestive of an intestinal obstruction.

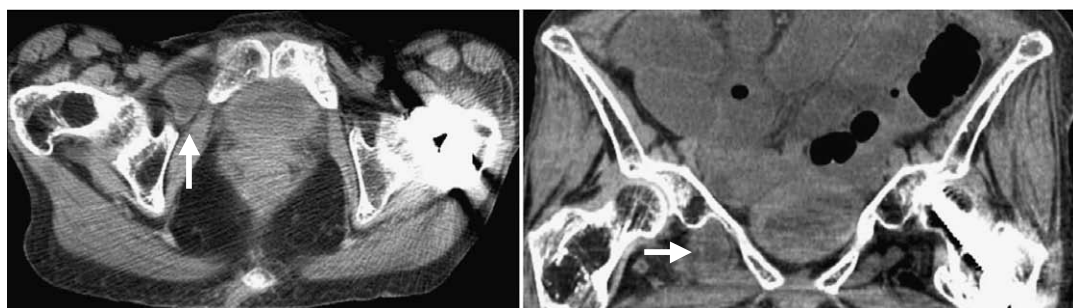


Fig. 2. Computed tomography (CT)
Plain CT images showing the presence of a strangulated intestinal obstruction within the obturator foramen with edema of the intestinal wall (arrows).

her vital signs indicated a blood pressure of 100/74 mmHg, a pulse rate of 83 beats/min, a respiration rate of 16 breaths/min and a body temperature of 36.6°C. A distended abdomen was noted during a physical examination, although tenderness and muscle guarding were absent. Bowel sounds were either absent or weak. No mass was palpated on either side of the groin, and the Howship-Romberg and Hannington-Kiff signs were negative. Laboratory studies showed that the patient had a white blood cell count of 11,700 cells/ μ L and a serum C-reactive protein level of 0.48 mg/dL. The results of all other laboratory studies, including serum electrolyte level, were within normal limits. A plain radiograph of the abdomen showed dilated small bowel loops with air fluid levels consistent with intestinal obstruction (Fig. 1). A strangulated intestinal obstruction with a low-density mass in the right obturator canal area was observed on plain computed tomography (CT) images (Fig. 2). Therefore, a diagnosis of right OH was confirmed.

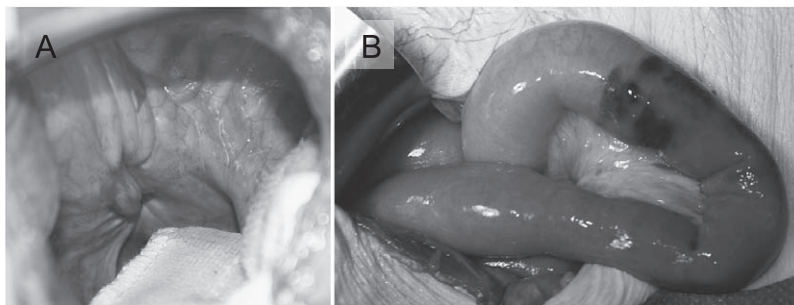


Fig. 3. Exploring the intra-abdominal cavity
(A) A right obturator foramen observed during the operation.
(B) A congested small intestine in the right lower abdomen.

After initial fluid resuscitation, the patient was transferred to the operation room for surgery, and an emergency laparotomy was performed. The incarcerated intestine was reduced and congested. The right obturator foramen and congested small intestine were observed in the right lower abdomen (Fig. 3). In addition, a slightly dilated proximal intestine was noted. Simple suture closure of the obturator foramen was performed without an intestinal segmentectomy. The patient recovered uneventfully without postoperative complications. She passed flatus on postoperative day (POD) 1, was able to receive fluids orally on POD 2 and was discharged on POD 7.

Discussion

Ronsil first described OH in 1724⁵⁾. The incidence of OH is nearly 1% of all hernia types⁶⁾. Occasionally, OH is referred to as “little old ladies’ hernia” as it usually occurs in multiparous and elderly emaciated women because these women have a wider pelvis and an enlarged obturator canal. Other risk factors include chronic obstructive pulmonary disease and chronic constipation and ascites. The prime clinical symptom is acute intestinal obstruction, and the pain experienced by our patient originated in the lower abdomen and radiated to the anterior thigh, which is a characteristic of this condition. The Howship-Romberg sign is frequently used to confirm the diagnosis of an OH; it describes the worsening of pain with extension, adduction and internal rotation movements of the affected extremity due to compression of the obturator nerve⁷⁾. Another classic Hannington-Kiff sign is the absence of the adductor reflex and the presence of a patellar reflex, which is a more specific but rare clinical sign of an OH^{1,8-12)}. The results from the physical examination of our patient were not significantly suggestive of an OH.

The mortality rate of OH is almost 70%^{4,7,13)}. This is owing to delayed diagnoses, the high incidence of intestinal ischemia and perforation, and the affected demographics. However, an early diagnosis is challenging because many of the symptoms and signs of OH are nonspecific. Various imaging examinations have been used to establish the diagnosis, includ-

ing ultrasonography, herniorrhaphy, and CT; of these, CT has the greatest sensitivity and accuracy⁹⁾. In our case, CT showed the presence of small bowel loops within the obturator foramen with edema of the intestinal wall. Therefore, a preoperative diagnosis of OH was confirmed, and an emergency operation was performed. Thus, CT is an important additional diagnostic tool for managing intestinal obstruction.

Surgical repair is mandatory for treatment of virtually all cases of OH and traditionally involves exploratory laparotomy¹⁾. There is a variety of operative approaches that may be used to treat an OH, including inguinal, retropubic and transperitoneal approaches^{14,15)}. We conducted a laparotomy via a low midline incision because, compared with other techniques, this procedure provides better exposure and facilitates bowel resection when necessary. Recently, laparoscopic surgery was described to be an alternative approach for the removal of an OH¹⁶⁾. The surgical methods of repair include simple suture closure, closure of the obturator with adjacent tissue and mesh replacement during laparotomy¹⁷⁾. Previously, in patients requiring bowel resection, many authors have performed a simple closure of the hernial defect with one or more interrupted sutures^{14,16)}. In this case, a simple suture was used, and the outcome was satisfactory.

In conclusion, an OH should be included in the differential diagnosis of an intestinal obstruction. Early diagnosis using CT and prompt surgical intervention can improve the prognosis.

References

- 1) Bjork KJ, Mucha P Jr and Cahill DR: Obturator hernia. *Surg Gynecol Obstet* **167** : 217-222 (1988)
- 2) Shapiro K, Patel S, Choy C, Chaudry G, Khalil S and Ferzli G: Totally extraperitoneal repair of obturator hernia. *Surg Endosc* **18** : 954-956 (2004)
- 3) Bryant TL and Umstot RK Jr: Laparoscopic repair of an incarcerated obturator hernia. *Surg Endosc* **10** : 437-438 (1996)
- 4) Rodriguez-Hermosa JI, Codina-Cazador A, Maroto-Genover A, Puig-Alcantara JM, Sirvent-Calvera JM, Garsot-Savall E and Roig-Garcia J: Obturator hernia : clinical analysis of 16 cases and algorithm for its diagnosis and treatment. *Hernia* **12** : 289-297 (2008)
- 5) Ziegler DW and Rhoads JE Jr: Obturator hernia needs a laparotomy, not a diagnosis. *Am J Surg* **170** : 67-68 (1995)
- 6) Lo CY, Lorentz TG and Lau PW: Obturator hernia presenting as small bowel obstruction. *Am J Surg* **167** : 396-398 (1994)
- 7) Losanoff JE, Richman BW and Jones JW: Obturator hernia. *J Am Coll Surg* **194** : 657-663 (2002)
- 8) Bryant TL and Umstot RK Jr: Laparoscopic repair of an incarcerated obturator hernia. *Surg Endosc* **10** : 437-438 (1996)
- 9) Kammori M, Mafune K, Hirashima T, Kawahara M, Hashimoto M, Ogawa T, Ohta H, Hashimoto H and Kaminishi M: Forty-three cases of obturator hernia. *Am J Surg* **187** : 549-552 (2004)
- 10) Kim JJ, Jung H, Oh SJ, Lee KH, Park SM and Kim YH: Laparoscopic transabdominal preperitoneal hernioplasty of bilateral obturator hernia. *Surg Laparosc Endosc Percutan Tech* **15** : 106-109 (2005)
- 11) Hunt L, Morrison C, Lengyel J and Sagar P: Laparoscopic management of an obstructed obturator hernia : should laparoscopic assessment be the default option? *Hernia* **13** : 313-315 (2009)
- 12) Yip AW, AhChong AK and Lam KH: Obturator hernia : a continuing diagnostic challenge. *Surgery* **113** : 266-

269 (1993)

- 13) Haraguchi M, Matsuo S, Kanetaka K, Tokai H, Azuma T, Yamaguchi S and Kanematsu T: Obturator hernia in an ageing society. *Ann Acad Med Singapore* **36** : 413-415 (2007)
- 14) Shipkov CD, Uchikov AP and Grigoriadis E: The obturator hernia : difficult to diagnose, easy to repair. *Hernia* **8** : 155-157 (2004)
- 15) Shapiro K, Patel S, Choy C, Chaudry G, Khalil S and Ferzli G: Totally extraperitoneal repair of obturator hernia. *Surg Endosc* **18** : 954-956 (2004)
- 16) Yau KK, Siu WT, Fung KH and Li MK: Small-bowel obstruction secondary to incarcerated obturator hernia. *Am J Surg* **192** : 207-208 (2006)
- 17) Pandey R, Maqbool A and Jayachandran N: Obturator hernia : a diagnostic challenge. *Hernia* **13** : 97-99 (2009)

[Received June 25, 2012 : Accepted August 7, 2012]