

Case Report

Ulcerative Colitis after Multidisciplinary Treatment for Colorectal Cancer with Multiple Liver Metastases : A Case Report

Kodai TOMIOKA^{*1,2)}, Noriyuki MURAI¹⁾, Motohiko FUKUSHIMA¹⁾,
Hideo YOKOKAWA¹⁾, Tatsuya YAMAZAKI^{1,2)}, Kazuhiro MATSUDA²⁾,
Tomotake KOIZUMI²⁾, Satoru GOTO²⁾, Akira FUJIMORI²⁾,
Yuta ENAMI²⁾, Koji OTSUKA²⁾, Makoto WATANABE²⁾,
Takeshi AOKI²⁾ and Masahiko MURAKAMI²⁾

Abstract : Herein we report on an extremely rare case of ulcerative colitis (UC) with onset after chemotherapy and colorectal resection, and discuss three previously reported cases. A 61-year-old man presented with fecal occult blood and no subjective symptoms. The diagnosis was rectal cancer with multiple liver metastases. Following chemotherapy, the patient underwent laparoscopy-assisted super-low anterior resection, liver resection. On Day 35 following closure of the ileostomy, the patient was referred to Totsuka Kyoritsu Dai-1 Hospital because of diarrhea, bloody stools. Colonoscopy and pathological examination revealed UC. To the best of our knowledge, only three cases of UC following colorectal cancer resection have been described previously. In conclusion, when encountering intractable diarrhea after chemotherapy or surgery, UC should be one of the bowel diseases considered, with prompt systemic examination recommended.

Key words : ulcerative colitis, resection, colorectal cancer

Introduction

Ulcerative colitis (UC) is generally thought to result from a genetic predisposition and environmental factors. However, its causes and pathogenesis are not well understood. Since the first report of UC with colorectal cancer by Crohn and Rosenberg¹⁾, numerous other cases have been described. Conversely, there are few reports of UC developing after the resection of colorectal cancer^{2, 3)}. Herein, we describe a case of rapidly developing UC with symptoms of refractory diarrhea and bloody stools that developed 12 months after neoadjuvant chemotherapy and 6 months after laparoscopic-assisted rectal resection with liver resection for rectal cancer and liver metastasis.

Case report

A 61-year-old man was referred to Totsuka Kyoritsu Dai-1 Hospital for evaluation of fecal

¹⁾ Department of Surgery, Totsuka Kyoritsu Dai-1 Hospital, 116 Totsuka, Yokohama, Kanagawa 244-0003, Japan.

²⁾ Department of Surgery, Division of Gastroenterological and General Surgery, Showa University Hospital.

* To whom corresponding should be addressed.

occult blood detected by colon cancer screening. The patient had no subjective symptoms. Laboratory tests revealed almost normal levels of most markers, except for carcinoembryonic antigen (6,124 ng/ml) and CA19-9 (415 U/ml). Colonoscopy revealed a Type 2 rectal tumor located 3 cm from the anal verge. The tumor was diagnosed histologically as a well-differentiated adenocarcinoma (Group V; Fig. 1a); other mucosal changes were not observed. Enhanced computed tomography (CT) of the abdomen showed irregular wall thickening and surrounding lymph node enlargement with contrast effects in the rectum, as well as multiple masses with contrast effects in the left lobe and posterior segment of the right lobe of the liver (Fig. 1b, c). A diagnosis of rectal cancer with multiple liver metastases was made and the patient underwent chemotherapy with mFOLFOX6 plus bevacizumab. The patient was then scheduled for radical surgery at Showa University Hospital. Adhesiolysis of the liver, diaphragm, and right adrenal gland proved to be slightly difficult, and the surgical stress was thought to be greater than expected. Consequently, the liver resection was switched intraoperatively to a two-stage resection procedure. The first procedure was cholecystectomy, laparoscopy-assisted super-low anterior resection (five ports), and hepatectomy of S4 and the posterior segment. The duration of the procedure was 550 min, and blood loss was 610 g. The rectal and liver pathological diagnoses were moderately differentiated adenocarcinoma (tub2 > tub1), T3 (A), INFb, int, ly2 (D2-40), v2, pN2 (4/29) and metastatic adenocarcinoma of the liver resulting from rectal cancer (Fig. 2). Intraperitoneal drainage and ileostomy were performed on Day 2 postoperatively. Because of postoperative suture failure, left hepatic lobe resection was delayed until Day 20 after the first procedure. The lobectomy required 510 min, and blood loss was 940 g. The pathological diagnosis was hepatic metastasis of colorectal cancer. The patient was discharged on Day 47 following the first surgery, and the ileostomy was closed on Day 135. On Day 35 after closure of the ileostomy (170 days after the first surgery), the patient presented to the outpatient clinic with diarrhea and occasionally bloody stools. Although antifatulence medication was prescribed, the patient's symptoms worsened, with prolonged fever and symptoms of infectious enteritis. The patient was admitted for medical treatment 200 days after the first surgery with episodes of diarrhea about twice a day. Blood and fecal cultures were negative, and a course of antibiotics (cefmetazole) did not improve the symptoms. Abdominal enhanced CT revealed edematous thickening of the descending colon (Fig. 3a), and colonoscopy revealed diffuse edematous hyperemia with discrete ulcerations and formation of mucosal bridges between the rectum and descending colon (Fig. 3b, c, d). Histological examination of colon tissue showed a disturbance of crypt morphology with erosion and a reduction in the number of epithelial goblet cells (Fig. 3e, f). Because there were no inflammation-specific findings, ischemic colitis did not seem likely and the patient was diagnosed with UC and started on 5-aminosalicylic acid (3,600 mg/day) and prednisolone (40 mg/day). At the same time, he was further treated with six courses of leukocytapheresis. The symptoms improved, and the patient was discharged 285 days after the first surgery and is now followed-up as an outpatient (Fig. 4).

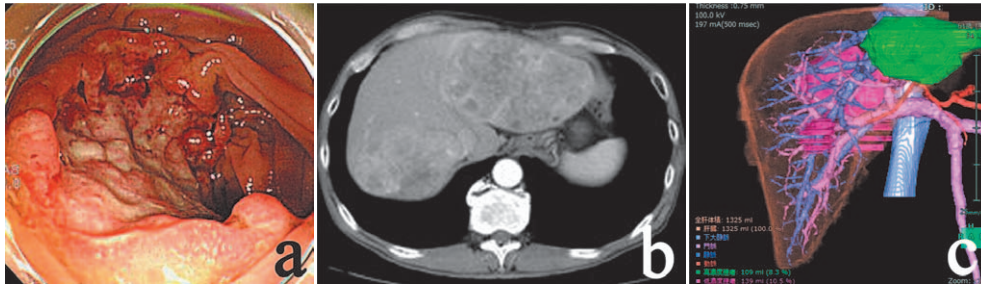


Fig. 1. (a) Colonoscopy before operation.
 (b) Computed tomography of the abdomen revealed liver metastases.
 (c) Preoperative simulation of the liver.

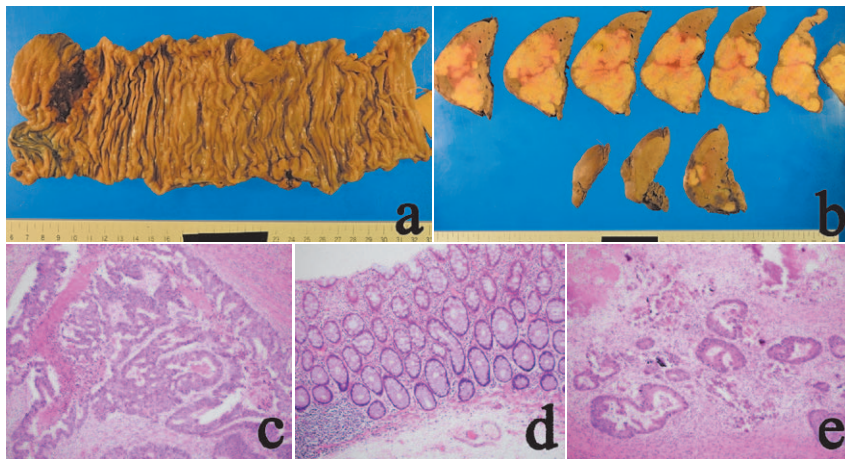


Fig. 2. (a, b) Macroscopic imaging of the rectum (a) and liver (b).
 (c-e) Hematoxylin–eosin staining showing well-differentiated adenocarcinoma of the rectum (c), normal rectal mucosa (d), and liver metastasis (e).

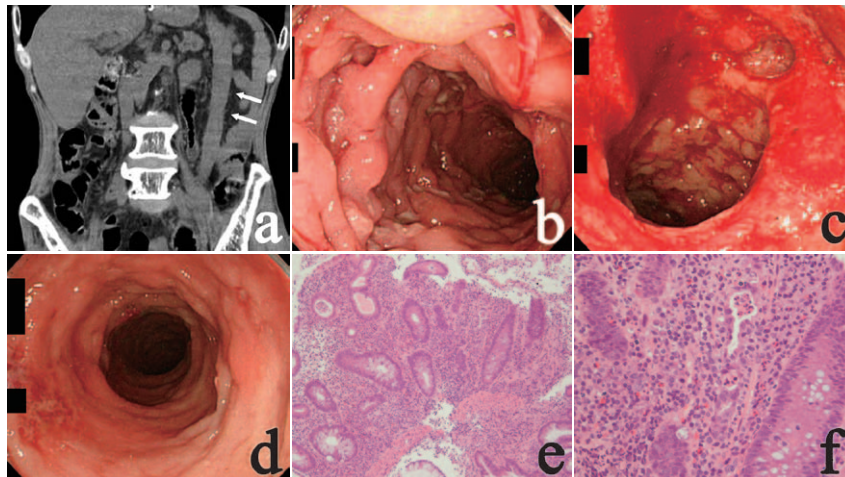


Fig. 3. (a) Abdominal computed tomography showing changes in the descending colon (white arrows).
 (b) Colonoscopy showing mucosal bridges.
 (c) Bleeding of the colon mucosa.
 (d) Multiple discrete ulcerations and diffuse edematous hyperemia in the rectum.
 (e, f) Biopsy specimen showing severe mucosal inflammation, crypt abscess, and crypt distortion (hematoxylin–eosin; original magnification $\times 100$ [e] and $\times 400$ [f]).

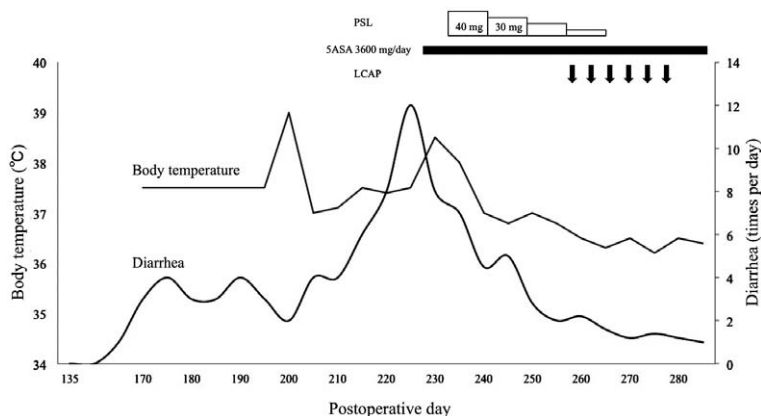


Fig. 4. Patient's clinical course. PSL, prednisolone ; 5ASA, 5-aminosalicylic acid ; LCAP, leukocytapheresis.

Table 1. Previously described cases of ulcerative colitis (UC) following resection for colorectal cancer

Reference	Patient age (years)	Gender	Country	Preoperative diagnosis	Surgical procedure	Time interval from surgery to UC	Treatment
Lim <i>et al</i> ²⁾	60	M	UK	Neuropathy due to DM	Sigmoidectomy	4 months	5ASA + PSL
	16	M	UK	Inperforate anus	Ileostomy	6 months	SASP + PSL
Takamura <i>et al</i> ³⁾	44	M	Japan	Sigmoid colon cancer	Sigmoidectomy	2 weeks	Surgery
Present study	61	M	Japan	Rectal cancer	LAC-LAR/ileostomy closure	6 months/1 month	5ASA + PSL

DM, diabetes mellitus ; LAC, laparoscopic-assisted colectomy ; LAR, low anterior resection ; PSL, prednisolone ; SASP, salazosulfapyridine ; 5ASA, 5-aminosalicylic acid.

Discussion

In this patient, the onset of UC was after rectal and liver resection with neoadjuvant chemotherapy. Typical findings suggestive of UC were not recognized during the preoperative examination. At 170 days after the first surgery, diarrhea and bloody stool had appeared. Retrospectively, these symptoms were highly suggestive of the initial symptoms of UC. When the symptoms did not improve, UC was diagnosed by colonoscopy.

To the best of our knowledge, there are only two reports of three patients with UC that developed after colorectal surgery in the literature^{2, 3)}. The interval between surgery and UC onset was 4–6 months in two patients and 2 weeks in one patient. In two patients, the first symptoms were bloody stools and fever, whereas in the third patient the first symptoms were intractable diarrhea and bloody stool (Table 1). Lim *et al*²⁾ concluded that diversion colitis was a possible reason for the onset of UC after colorectal resection, whereas Takakura *et al*³⁾ suggested two possible causes, namely rapid development of pre-existing UC after surgery and the possible conversion of pre-existing non-specific colitis to UC after surgery, with the latter being more likely. In the present case, findings of enterocolitis were not observed clinically at

the time of the first surgery. In addition, non-specific enteritis was not observed, even in surgical specimens. Furthermore, temporal ischemic changes in the remaining intestinal tract because of changes in blood flow associated with lymph node dissection and vascular changes may affect the development of UC^{3,4}. There is no study reporting on an obvious link between chemotherapy and the onset of UC. In the present case, UC developed 12 months after the FOLFOX regimen. The possibility that chemotherapy and surgical stress contribute to the pathogenesis of UC needs to be considered. The possibility of an increase in the number of cases of UC developing after surgery and chemotherapy is a concern; hence, it will be important to study this aspect in the future.

We believe that four factors may be responsible for the abrupt onset of UC and may affect its severity: (i) chemotherapy; (ii) colorectal operative stress; (iii) changes in blood circulation because of surgery; and (iv) mental stress. A lack of other reports regarding the onset of UC after colorectal resection makes it difficult to determine the cause of UC in the present patient. When encountering intractable diarrhea after chemotherapy or colorectal surgery, a differential diagnosis of bowel diseases, including UC, should be considered as a long-term postoperative complication. Prompt systemic evaluations, including colonoscopy or CT, are recommended. UC after colorectal resection is an extremely rare occurrence, but more cases are expected.

Acknowledgment

The authors thank the patient for allowing them to publish this case.

Conflict of interest disclosure

The authors declare that they have no conflict of interest regarding the publication of this paper.

References

- 1) Crohn BB, Rosenberg H. The sigmoidoscopic picture of chronic ulcerative colitis (nonspecific). *Am J Med Sci.* 1925;**170**:220–228.
- 2) Lim AG, Langmead FL, Feakins RM, *et al.* Diversion colitis: a trigger for ulcerative colitis in the in-stream colon? *Gut.* 1999;**44**:279–282.
- 3) Takakura M, Mochizuki N, Yamauchi K, *et al.* Acute onset of ulcerative colitis following an operation for sigmoid colon cancer. *J Gastroenterol.* 2006;**41**:77–82.
- 4) Theis MK, Boyko EJ. Patient perceptions of cause of inflammatory bowel disease. *Am J Gastroenterol.* 1994;**89**:1920.

[Received March 10, 2017 : Accepted April 7, 2017]