

Case Report

Single-Incision Laparoscopic Cholecystectomy Using a Dome-Down Approach for a Patient with Left-Sided Gallbladder

Yasuhiro ISHIYAMA*, Yuta ENAMI, Kenta NAKAHARA,
Chiyo MAEDA, Shunpei MUKAI, Naruhiko SAWADA,
Eiji HIDAHA, Fumio ISHIDA and Shin-ei KUDO

Abstract: True left-sided gallbladder (sinistroposition) is a rare anatomic anomaly in which the gallbladder is found to the left of the falciform ligament under the left lobe of the liver. Though uncommon, it is important for the surgeon to identify this anomaly because the ductal anatomy is unique and the surgery is technically challenging. Multiple case reports have documented safe management of sinistroposition encountered during conventional laparoscopic cholecystectomy. We present a case of sinistroposition encountered during a single-incision laparoscopic cholecystectomy. We conclude that this single-site laparoscopic technique is not only safe when sinistroposition is encountered, but it may actually provide certain ergonomic benefits for surgeons.

Key words: single-incision laparoscopic cholecystectomy, single-incision laparoscopic surgery, left-sided gallbladder, dome-down approach

Introduction

Single-incision laparoscopy is currently a popular form of minimally invasive surgery. In particular, previous case reports have shown single-incision laparoscopy to be safe and effective for cholecystectomy^{1,2)}. A previous systematic review and meta-analysis study reported that single-incision laparoscopic cholecystectomy (SILC) provided clear advantages over conventional laparoscopic cholecystectomy, with less postoperative pain and improved cosmesis³⁾. Furthermore, standard multi-port laparoscopic cholecystectomy in situs inversus totalis poses some technical difficulties for right-handed surgeons operating on left-sided gallbladders⁴⁾. This is not a problem with single incision laparoscopic surgery (SILS). However, despite its growing popularity, there are very few reports on SILC for left-sided gallbladder⁵⁾. Hence, we present our case and discuss some technical aspects of SILC in a patient with left-sided gallbladder.

Case presentation

A 36-year-old man with no medical or surgical history presented to our outpatient clinic with abdominal pain. Ultrasonography identified multiple gallstones that were millimetric in size, a

Digestive Disease Center, Showa University Northern Yokohama Hospital, 35-1 Chigasaki-Chuo Tsuzuki, Yokohama 224-8503, Japan.

* To whom corresponding should be addressed.

common bile duct of normal diameter, and his liver and gallbladder in the right hypochondrium. A computed tomography scan confirmed the presence of gallstones. Magnetic resonance cholangiopancreatography was also performed, and, together with the computed tomography scans, showed the gallbladder to the left of the falciform ligament. However, we could not diagnose left-sided gallbladder preoperatively. Laboratory studies were normal. The patient gave permission for his data to be used in future analyses; after providing informed consent, the patient underwent SILC. Review board approval was obtained from Showa University prior to the commencement of this study.

Surgical procedure

Under general anesthesia, the patient was placed in the anti-Trendelenburg position. A monitor was placed at the head of the operating table. The lead surgeon was positioned on the patient's left side and the assistant holding the camera was positioned on the left side behind the lead surgeon. First, a Lap Protector Mini (Hakko Co., Ltd. Medical Device Division, Nagano, Japan) was inserted through a 2.0 cm transumbilical incision so the wound was protected. Next, an EZ Access (Hakko Co., Ltd.) was mounted on the Lap Protector and three 5 mm ports were placed in the EZ Access. Almost all the procedures were performed with usual laparoscopic instruments such as the SonoSurg (Olympus Medical Systems Corp., Tokyo, Japan), and the operative procedures were much the same as in conventional laparoscopic cholecystectomy using a flexible 5 mm scope. The abdomen was insufflated to 8 mm Hg at which time a laparoscope was placed through the trocar. The gallbladder was normal in color and not inflamed. However, the gallbladder was not in the normal anatomic location. It was positioned to the left of the falciform ligament (Fig. 1). Because the traditional port placement in the epigastrium location would have been less than optimal, the decision was made to proceed with a single-incision technique. At first we separated the gallbladder fundus using a dome-down approach (Fig. 2). This allowed us to manipulate the gallbladder in such a way as to expose the triangle of Calot. The peritoneum was stripped, exposing the cystic duct and artery. Both were dissect-

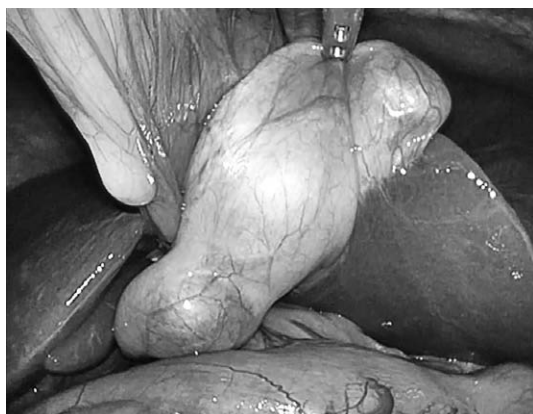

Fig. 1. Intra-operative photograph shows the gall bladder covered with adhesions on the left of the ligamentum teres

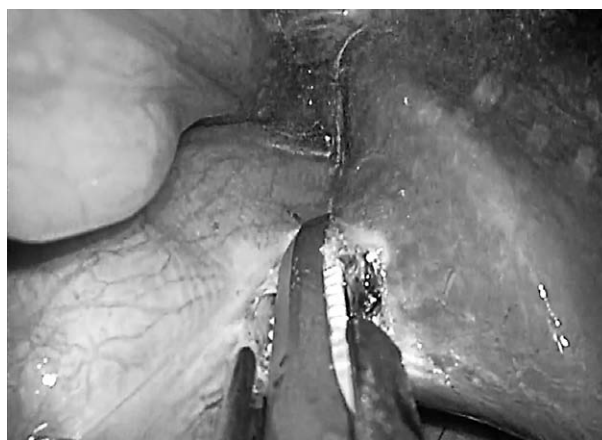


Fig. 2. Dome-down technique

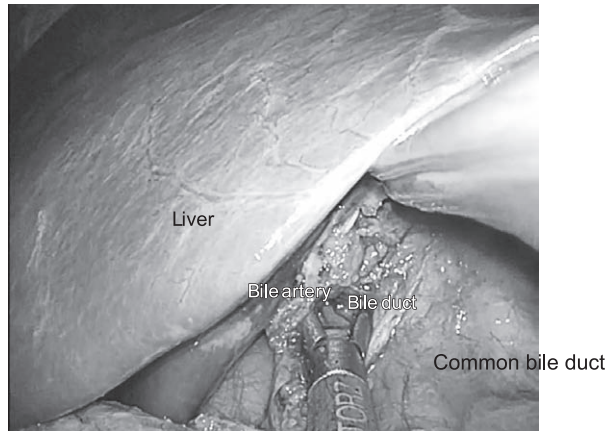


Fig. 3. Isolation of the cystic duct by forceps for articulated dissection

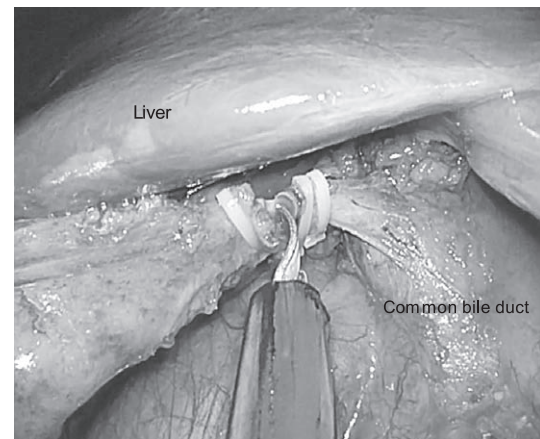


Fig. 4. Section of the clipped cystic duct

ed circumferentially, and the liver edge was exposed, allowing us to obtain a true “critical view” of the patient’s anatomy (Fig. 3). As shown in Figure 3, we found that the ductal anatomy in this patient with left-sided gallbladder held true because the cystic duct entered the hepatic duct from the right side. The cystic duct and artery were then clipped and transected (Fig. 4). The operation was then completed without incident and the total duration of surgery was 86 minutes. The patient recovered uneventfully and was discharged from our hospital on postoperative day 3.

Discussion

First described in 1886 by Hochstetter, left-sided gallbladder remains a rare anomaly⁶. In a multicenter series of laparoscopic cholecystectomies completed in Hungary, its prevalence was found to be 0.3%⁷. Left-sided gallbladder is confirmed when the gallbladder is found to the left of the falciform ligament under the left lobe of the liver. It is located between segments III and IV or on segment III of the liver.

Both ductal anatomy and ergonomics pose challenges when left-sided gallbladder is encountered laparoscopically. Recent studies have reported the safe removal of the gallbladder by means of conventional laparoscopic cholecystectomy when left-sided gallbladder was encountered^{6,8}. However, these reports stress proper identification of unanticipated ductal anatomy as the key to safe completion of the operation^{6,8,9}. In addition to the unexpected ductal anatomy, port placement and ergonomics also provide a challenge when sinistroposition is encountered.

Recently, rapid developments in laparoscopic surgery have occurred. Additionally, the procedure does not take very long to learn¹⁰⁻¹². In fact, one previous dry-box study reported that although SILS is difficult, experienced laparoscopic surgeons were able to adapt their training and experience in order to perform this new technique quite easily¹³. One previous article reported that even for surgeons who have not performed SILC before, this technique may become the standard for benign gallbladder disease as it does not require the use of articulating devices or additional trocars¹⁴.

Although a single-incision technique does not entirely remove the difficulty faced by right-handed surgeons operating on a left-sided gallbladder, it does simplify port placement and ergonomics⁵). We suggest that SILS is a safe alternative for laparoscopic cholecystectomy in patients with left-sided gallbladder. Though, we usually expose the triangle of Calot first, when left-sided gallbladder is encountered in our institution, we perform the dome-down procedure first because this procedure restores normal positioning. After the dome-down procedure, surgeons can then perform the surgery as per normal.

Previous articles have reported that the dome-down approach is easy to learn for surgeons. Dome-down laparoscopic cholecystectomy with the LCS-5 harmonic scalpel decreases the potential for misidentification of ductal anatomy, has minimal complications, and eliminates electrocautery risks¹⁵). Conversion is related to poor visualization of anatomy due to inflammation and adhesions^{16,17}). We also believe that a dome-down procedure is the simplest technique to use with SILS, but we only use conventional instruments. Tacchino *et al*¹⁸) reported that improved instrumentation and the use of crossed-over articulating graspers and dissectors can achieve triangulation, but this requires adjustments that may translate to longer operative times for safe and precise dissection^{2,9}).

Several authors have shown that SILS is more expensive than conventional multi-incision laparoscopic cholecystectomy given the higher operating room costs and anesthesia costs associated with longer operative times, as well as the use of improved instruments¹⁹). Though, a previous case report indicated a median operative time of 143.5 min, in our case the operative time was 86 min (Table 1)²⁰⁻²³). Thus, we suggest that it is possible to shorten the operative time. Nevertheless, we performed SILC with the dome-down procedure using conventional instruments and found it to be a safe and feasible technique.

Conclusion

We conclude that SILC is an effective and safe procedure with improved cosmesis for cholecystectomy when left-sided gallbladder is encountered. Surgeons should be aware that there may be cases where additional ports are required and should not hesitate to insert additional ports when needed.

Table 1. Literature review of previously reported case of left-sided gallbladders undergoing Single Incision Laparoscopic cholecystectomy

Author	Year	Clinical presentation	Diagnosis made pre-op?	Surgical treatment	Operative times	comments
T. Kusano ²⁰)	2011	Epigastric pain	No	Rotecular insurument	143	SILSport
J. Hiroyoshi ²¹)	2011	Right sided pain	Yes	ICG, Miniloop retractor	144	SILSport
T. Hanamoto ²²)	2014	Epigastric pain	Yes	Needlescopic surgery	167	Lap protector mini
S.R. Bonomo ²³)	2014	Epigastric pain	Yes	Suture retraction technique	-	Lap protector mini
Our case	2017	Abdominal pain	No	Dome-down technique	86	EZ Access
					143.5 (86-167)	

Conflict of interest disclosure

The authors declare that there are no conflicts of interest.

References

- 1) Chow A, Purkayastha S, Aziz O, *et al.* Single-incision laparoscopic surgery for cholecystectomy: a retrospective comparison with 4-port laparoscopic cholecystectomy. *Arch Surg.* 2010;**145**:1187–1191.
- 2) Markar SR, Karthikesalingam A, Thrumurthy S, *et al.* Single-incision laparoscopic surgery (SILS) vs. conventional multiport cholecystectomy: systematic review and meta-analysis. *Surg Endosc.* 2012;**26**:1205–1213.
- 3) Evers L, Bouvy N, Branje D, *et al.* Single-incision laparoscopic cholecystectomy versus conventional four-port laparoscopic cholecystectomy: a systematic review and meta-analysis. *Surg Endosc.* 2016 Dec 30. (accessed 2016 Nov 27) Available from: <http://link.springer.com/content/pdf/10.1007%2Fs00464-016-5381-0.pdf>
- 4) Uludag M, Yetkin G, Kartal A. Single-incision laparoscopic cholecystectomy in situs inversus totalis. *JLS.* 2011;**15**:239–243.
- 5) Bonomo SR, Veenstra BR, Komar TM, *et al.* Single-incision cholecystectomy for left-sided gallbladder. *JLS.* 2014;**18**:338–341.
- 6) Dhulkotia A, Kumar S, Kabra V, *et al.* Aberrant gallbladder situated beneath the left lobe of liver. *HPB (Oxford).* 2002;**4**:39–42.
- 7) Reddy PK, Subramanian RV, Yuvaraja S. Laparoscopic cholecystectomy for left-sided gallbladder (sinistroposition). *JLS.* 2005;**9**:356–357.
- 8) Chrungoo RK, Kachroo SL, Sharma AK, *et al.* Left-sided gall bladder: report of two cases. *J Minim Access Surg.* 2007;**3**:108–110.
- 9) Qureshi I, Awad Z. Aberrant presentation of the gallbladder during laparoscopic cholecystectomy. *JLS.* 2009;**13**:605–607.
- 10) Chow A, Purkayastha S, Aziz O, *et al.* Single-incision laparoscopic surgery for cholecystectomy: an evolving technique. *Surg Endosc.* 2010;**24**:709–714.
- 11) Hodgett SE, Hernandez JM, Morton CA, *et al.* Laparoendoscopic single site (LESS) cholecystectomy. *J Gastrointest Surg.* 2009;**13**:188–192.
- 12) Zhu JF, Hu H, Ma YZ, *et al.* Totally transumbilical endoscopic cholecystectomy without visible abdominal scar using improved instruments. *Surg Endosc.* 2009;**23**:1781–1784.
- 13) Ishiyama Y, Inaki N, Bando H, *et al.* Assessment of intracorporeal suturing in single-port surgery using an experimental suturing model. *Indian J Surg.* 2017;**79**:137–142.
- 14) Yamamoto M, Zaima M, Kida Y, *et al.* A novel procedure for single-incision laparoscopic cholecystectomy: the teres hanging technique combined with fundus-first, dome-down separation. *J Laparoendosc Adv Surg Tech A.* 2016;**26**:1003–1009.
- 15) Fullum TM, Kim S, Dan D, *et al.* Laparoscopic “dome-down” cholecystectomy with the LCS-5 harmonic scalpel. *JLS.* 2005;**9**:51–57.
- 16) Alley JR Jr, Stucky CC, Moncure M. Teaching surgical residents dome-down laparoscopic cholecystectomy in an academic medical center. *JLS.* 2008;**12**:368–371.
- 17) Rosenberg J, Leinskold T. Dome down laparoscopic cholecystectomy. *Scand J Surg.* 2004;**93**:48–51.
- 18) Tacchino R, Greco F, Matera D. Single-incision laparoscopic cholecystectomy: surgery without a visible scar. *Surg Endosc.* 2009;**23**:896–899.
- 19) Leung D, Yetasook AK, Carbray J, *et al.* Single-incision surgery has higher cost with equivalent pain and quality-of-life scores compared with multiple-incision laparoscopic cholecystectomy: a prospective randomized blinded comparison. *J Am Coll Surg.* 2012;**215**:702–708.

- 20) Bonomo SR, Veenstra BR, Komar TM, *et al*. Single-incision cholecystectomy for left-sided gallbladder. *JSLS*. 2014;**18**:338-341.
- 21) Kusano T, Iwashita Y, Yasuda K, *et al*. Single port laparoscopic cholecystectomy for patient with right-sided round ligament/left-sided gallbladder: a case report. *J Jpn Soc Endosc Surg*. 2011;**16**:569-573. (in Japanese).
- 22) Hiroyoshi J, Ishizawa T, Shindoh J, *et al*. Single-incision laparoscopic cholecystectomy in a case of right-sided round ligament utilizing indocyanine-green fluorescent cholangiography. *J Jpn Surg Assoc*. 2011;**72**:1499-1502. (in Japanese).
- 23) Hanamoto T, Ishiguro Y, Takahashi S, *et al*. A case of single port laparoscopic cholecystectomy for a patient with left-sided gallbladder. *Surgery*. 2014;**76**:448-451. (in Japanese).

[Received April 17, 2017 : Accepted July 5, 2017]