



# Spinal epidural angioliipoma causing spinal cord compression. A case report

A. Khelifa<sup>1</sup>, I. Assoumane<sup>2</sup>, S. Bachir<sup>3</sup>, L. Berchiche<sup>1</sup>,  
A. Morsli<sup>1</sup>

<sup>1</sup> Neurosurgical Department of BEO University Hospital, Algiers,  
ALGERIA

<sup>2</sup> National Hospital of Niamey, NIGER

<sup>3</sup> Neurosurgical Department of Laghouat Hospital, Laghouat, ALGERIA

## ABSTRACT

**Background.** Spinal angioliipoma (SAL) is a rare tumour with double component mature adipose tissue and proliferating abnormal blood vessels, which result in spinal cord compression requiring an urgent surgical removal. We report a case of woman with spinal angioliipoma.

**Case presentation.** The patient is a 26 years old woman with past medical history of a low grade urothelial bladder carcinoma removed 4 months before she consults at our department, 2 months later the patient presented a lower limbs weakness. The clinical exam at the admission found a patient with paraparesis, hypoesthesia at the level of Th4 and urinary urgency. The spinal MRI objectified a spinal cord compression by a lesion located at the epidural space from Th2 to Th4. The patient was operated and a fatty well vascularized tumour distinct from the epidural fat was removed through a Th2 to Th4 laminectomy. The pathology study was in favour of an angioliipoma. Days after the operation the patient recovered totally, the weakness and the urinary urgency disappeared. The patient is flowed since 24 months she got pregnant.

**Conclusion.** Spinal angioliipoma is a rare tumour with a clinic of spinal cord compression, MRI is the gold standard in diagnosis it shows a fatty lesion with a large enhancement, surgery is the perfect treatment with good outcome and exceptional recurrence.

## INTRODUCTION

Spinal angioliipoma (SAL) is a rare tumour with double component mature adipose tissue and proliferating abnormal blood vessels, which result in spinal cord compression requiring an urgent surgical removal. We report a case of woman with spinal angioliipoma.

## CASE PRESENTATION

The patient is a 26 years old woman with past medical history of a low grade urothelial bladder carcinoma removed 4 months before she consults at our department, 2 months later the patient presented a lower limbs weakness. The clinical exam at the admission found a patient with paraparesis, hypoesthesia at the level of Th4 and urinary urgency. The spinal MRI objectified a spinal cord compression by a lesion located at the epidural space from Th2 to Th4 fusiform measuring 83 x 12

Keywords  
angioliipoma,  
epidural tumour,  
spinal cord compression



Corresponding author:  
Khelifa Adel

Neurosurgical Department of BEO  
University Hospital, Algiers,  
Algeria

[drkhelifaadel@gmail.com](mailto:drkhelifaadel@gmail.com)

**Copyright and usage.** This is an Open Access article, distributed under the terms of the Creative Commons Attribution Non-Commercial No Derivatives License (<https://creativecommons.org/licenses/by-nc-nd/4.0/>) which permits non-commercial re-use, distribution, and reproduction in any medium, provided the original work is unaltered and is properly cited.

The written permission of the Romanian Society of Neurosurgery must be obtained for commercial re-use or in order to create a derivative work.

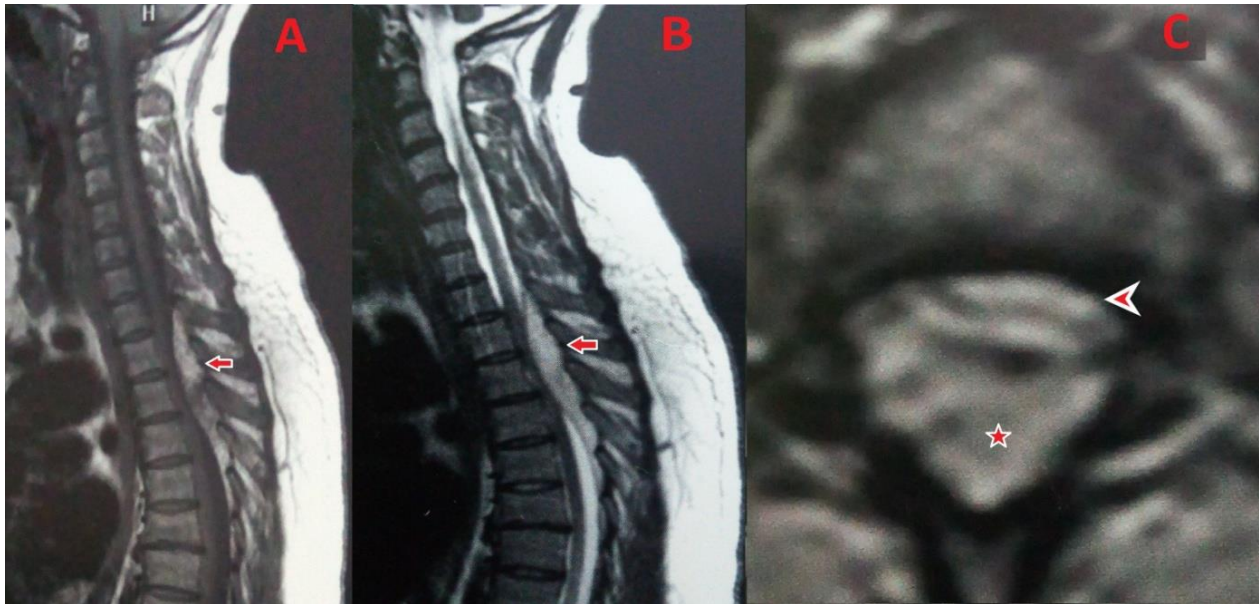
ISSN online 2344-4959  
© Romanian Society of  
Neurosurgery



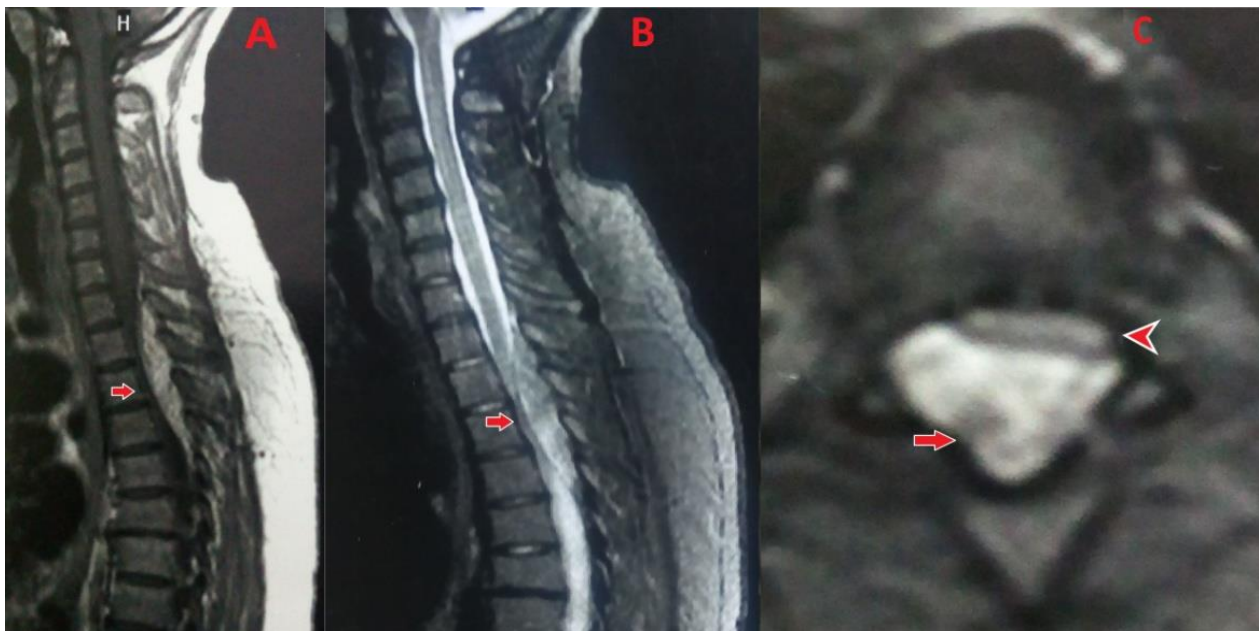
First published  
September 2019 by  
London Academic Publishing  
[www.lapub.co.uk](http://www.lapub.co.uk)

mm, hyper intense on T1 and T2 weighted images (Figure 1) there was a homogenous enhancement after gadolinium injection with persistence of the signal on T1 SPIR injected and in STIR sequences (Figure 2). The patient was operated and a fatty well vascularized tumour distinct from the epidural fat was

removed through a Th2 to Th4 laminectomy. The pathology study was in favour of an angioliipoma. Days after the operation the patient recovered totally, the weakness and the urinary urgency disappeared. The patient is flowed since 24 months she got pregnant.



**Figure 1.** Spinal MRI. A: sagittal T1 weighted image; B: sagittal T2 weighted image; C: axial T2 weighted image; showing hyperintense T1 and T2 lesion (arrows and the star) causing spinal cord compression (head of the arrow).



**FIGURE 2.** Spinal MRI. A: sagittal injected sequence; B: sagittal STIR sequence; C: STIR injected sequence; showing a homogenous enhancement of the lesion after gadolinium injection with persistence of the signal after the suppression of the fat signal (the arrows). The head of the arrow shows the situation of the spinal cord.

## DISCUSSION

SAL are tumours with double component mature adipose tissue and proliferating abnormal blood vessels (1,2,3,4,5,6,7,8), they are rare, 177 cases are found in the literature from 1890 where the first case was reported by Berenbruch to June 2015 (2). Some studies suggest that it represent 0.04% to 1.2% of spinal tumours, 2% to 3% of epidural spinal tumors (1,3,5,6,8) and 16 % to 35 % of spinal lipomas (5,8). It has a female predominance (1,2,3,4,5,7,8) with a sex ratio of 3/2 (8), with an average age between 40 and 60 years (2,3,4,7) and mostly located in thoracic spine (1,2,3,4,5,6,7,8) in 78 % of cases (8), mostly between Th2 and Th5 (6), other location are less common, it occurs in 10 % in the lumbar spine and in 1 % in the cervical spine (8). SAL can be infiltrating or non-infiltrating, In the majority of cases it is non infiltrating encapsulated and limited in the epidural space (3,7,8). The clinical presentation include back pain and signs of spinal cord compression (1,2,3,4,5,6,7,8), although the symptoms evolves slowly some cases of acute paraplegia were described (4). MRI is the imaging of choice for SAL diagnosis (1,2,3,4,5,6,7,8), commonly the tumour has a fusiform shape located in the posterior epidural space (2,4,5), the signal of the lesion is the reflect of its two components: lipomatose and angiomatose, so SAL is usually hyperintense in T1 and T2 weighted images with loss of the signal in fat suppression sequences which could be regained after injection of gadolinium (1,2,3,6,8). Surgery is the reasonable treatment modality (1,2,3,4,6,7,8), usually the lesion is reached by a posterior approach through a suitable laminectomy, total resection is possible for the non-infiltrating lesions with good outcome and exceptional cases of recurrence are reported (1,2,3,4,5,8,7).

## CONCLUSION

Spinal angioliopoma is a rare tumour with a clinical presentation of spinal cord compression, MRI is the

gold standard in diagnosis it shows a fatty lesion with a large enhancement, surgery is the perfect treatment with good outcome and exceptional recurrence.

## REFERENCES

1. Carrasco Moro R, Gutiérrez Cierco JA, Martínez San Millán JS, Pian H, Martínez Rodrigo MA.
2. Spinal extradural angioliopomas: 7 new cases and review of the literature. *Neurología*. 2019;34:98—104.
3. FeiFei Wang, Song Wang, Wen HuaXue and Jing Liang Cheng.
4. Epidural spinal angioliopoma: a case Series. Wang et al. *BMC Res Notes* (2017) 10:128.
5. DOI 10.1186/s13104-017-2432-0.
6. Yang X, Richard SA, Lei C, Liu J, Huang S.
7. Spinal extradural angioliopoma: a report of two cases and review of literature. *J Spine Surg* 2018;4(2):490-495.
8. DOI: 10.21037/jss.2018.06.11.
9. Enrique Gonzalo Bovier, Emiliano Gardino, Lucas Nicolás Chemes, Federico Nogueira, Verónica Diana Romero.
10. Acute Paraplegia by spinal Angioliopoma. Case report and literature review. *Coluna/Columna*. 2014; 13(2):147-9. DOI.org/10.1590/S1808-18512014130200403.
11. Marcel Hungs, MD, PhD<sup>1</sup>; Laura S. Pare<sup>2</sup>, MD, FRCSC.
12. Spinal Angioliopoma: Case Report and Literature Review. *J Spinal Cord Med*. 2008;31:315–318.
13. Shweikeh F, Sangtani A, Steinmetz MP, Zahos P, Chopko B.
14. Spinal angioliopomas: A puzzling case and review of a rare entity. *J Craniovert Jun Spine* 2017;8:91-6.
15. DOI: 10.4103/jcvjs.JCVJS\_23\_17.
16. Rajesh K Ghanta, Kalyan Koti, and Srinivas Dandamudi.
17. Spinal epidural angioliopoma: A rare cause of spinal cord compression. *J Neurosci Rural Pract*. 2012 Sep-Dec; 3(3): 341–343.
18. DOI: 10.4103/0976-3147.102617.
19. Mouna Rkhamia, Mohamed Ali Kedousb, Sameh Achourac, Alia Zehani, Kamel Bahria, Ihsen Zammela.
20. Epidural angioliopoma: A rare cause of spinal cord compression. *International Journal of Surgery Case Reports* 45 (2018) 72–76. DOI.org/10.1016/j.ijscr.2018.03.005