

DOI: 10.2478/romneu-2018-0060  
Article

# A single institute five-year surgical experience with Chronic Subdural Hematoma: Analysis of 270 consecutive patients at a Tertiary Care Centre

Gaurav Jaiswal, Vivek Kankane, Ashok Kumar, Pavan Kumar, Tarun Kumar Gupta  
INDIA

## **A single institute five-year surgical experience with Chronic Subdural Hematoma: Analysis of 270 consecutive patients at a Tertiary Care Centre**

**Gaurav Jaiswal, Vivek Kankane, Ashok Kumar, Pavan Kumar, Tarun Kumar Gupta**

Department of Neurosurgery, Rabindra Nath Tagore Medical College, Udaipur, Rajasthan, INDIA

**Abstract:** Chronic subdural hematoma (CSDH) is one of the very common surgically treatable neurosurgical entities. Still there is lack of uniformity in the management of CSDH amongst surgeons in terms of various treatment strategies and protocols. Burr-hole drainage is the treatment modality of choice for an uncomplicated CSDH. Some recent trials support the use of drain to lessen the rate of recurrence. Twist drill craniostomy and craniotomy do also play a role in the management of CSDH. The current study is a retrospective analysis of 270 surgically treated patients with chronic subdural hematoma at a tertiary care center over a span of five years. The present study highlighted on rate of recurrence, re-surgery, mortality and morbidity.

**Key words:** Burr hole, Chronic subdural hematoma, CSDH, Subdural hematoma

### **Introduction**

The annual incidence of chronic subdural hematoma is about 1-5.3 cases per 100,000 populations. The incidence is increasing due to rise in the life expectancy, associated medical diseases in elderly patients such as hemodialysis, use of antiplatelet drugs and anticoagulant therapy. [1,2]

Closed head injury has been frequently contemplated for the development of CSDH, especially in the elderly patients, which primarily seems trivial, may be the trigger for the genesis of CSDH. [3] Most of patients with CSDH, presenting with clinical symptoms and

signs, should be intervened for the removal of CSDH. The techniques can be performed with an array starting from twist drill craniostomy to craniotomy and membranectomy. [4]

Burr-hole drainage is one of the easier and very efficient surgical procedures, which can be done for removal of uncomplicated CSDH. [5] However, it has been stated that the recurrence rate range from 9.2% to 26.5% when this procedure is contemplated for surgical evacuation. [6] However, there are few other studies that have reported recurrence rates, which vary from 2.3% to 37%. [3]

This particular study at our center

retrospectively analyzed the results a single burr hole in consecutive 270 patients with CSDH.

### **Materials and Methods**

This is a retrospective study of 270 patients with chronic subdural hematoma treated in Department of Neurosurgery, RNT Medical College, Udaipur, Rajasthan, India from July 2012 to July 2017. Either computed tomography (CT) scan or magnetic resonance (MR) of brain was performed to diagnose the condition in all the patients. A surgical evacuation was done depending upon clinical status and thickness of hematoma.

The patients, who were neurologically preserved and were on anticoagulant therapy for their medical condition, anticoagulants were withheld, till the control of international normalized ratio (INR). Patients on anticoagulants or with coagulopathies who came in emergency with altered sensorium, vitamin-K injections were given for reversal of anticoagulant status with and they were taken up for surgery under the cover of fresh frozen plasma.

All the patients were operated by single burr hole technique. The burr-hole was planned at the site of the maximal hematoma thickness in these patients. The patients were analyzed for age, gender, symptomology, Glasgow Coma Scale (GCS), laterality, duration of hospitalization, Glasgow Outcome Scale (GOS) at discharge, recurrence rate and mortality.

### **Result**

A total of 270 consecutive patients were included in this retrospective study over a

three-year duration. The mean age of the patients with CSDH was 63.5 years whereas the range distribution was from 7 to 91 years.

Among these 270 patients, chronic subdural hematoma was predominant in males with 213 cases (78.9%) whereas 57 patients were female (21.1%), and male to female ratio was 3.7:1 (Table 1). Hematoma was located on the right side in 113 patients (41.8 %), on the left side in 105 patients (38.9%), whereas bilateral hematomas were present in 52 patients (19.3%) (Table 2).

Clear history of trauma was evident in 181 patients (67 %) while 89 patients (33%) didn't reveal specific history of trauma to head (Table 3).

There were various presenting symptoms and signs of patients with CSDH. Headache was the widespread symptom occurring in 176 patients (65.2%), followed by contralateral hemiparesis in 140 patients (51.8%), speech disturbance in 71 patients (26.3%), and altered behavior in 62 patients (23%). Other symptoms include urinary incontinence (6.3%), paraparesis (4.1%) and seizure (3.7%) (Table 4).

The diagnosis of chronic subdural hematoma was confirmed on computed tomography (CT head) in 229 (84.8%) patients, while 41 (15.2%) patients were confirmed under magnetic resonance imaging (MRI brain). Mean operative time was 44 minutes. The length of hospitalization ranged from 1 to 35 days, with a mean stay of 4.7 days.

The mean GCS (Glasgow Coma Score) at admission was 13.3. Out of 270 patients, 172 patients (63.7%) had GCS of 15-14, 68 patients (25.2%) had GCS of 13-9 and remaining 30 patients (11.1%) had GCS of 8-3 points (Table 5).

At the time of discharge, general outcome were assessed using GOS (Glasgow Outcome Scale) with range of 1-5. Out of 270 patients, 225 (83.3%) had favorable outcome (GOS 4-5), 38 patients (14.1%) (GOS 3-2) had poor outcome. Death occurred in seven patients (2.6%) (Table 6).

A recurrence rate of 11.1% (30 patients) was seen in this study. All the patients with symptomatic recurrences were taken-up for surgery again. ((Re-exploration of same burr hole, expansion of same burr hole, making another burr hole, craniotomy and craniectomy were the procedure for the recurrence).

**TABLE 1**

Demography (gender wise) of patients of chronic subdural hematoma: (N=270)

Gender	No. of patients(n-270)	Percentage
Male	213	78.9
Female	57	21.1
Total	270	100

**TABLE 2**

Location of chronic subdural hematoma: (N=270)

Location	No. of patients(n-270)	Percentage
Right	113	41.8
Left	105	38.9
Bilateral	52	19.3
Total	270	100

**TABLE 3**

Etiology of chronic subdural hematoma: (N=270)

Etiology	No. of patients(n-270)	Percentage
History of head trauma	181	67
Without any history of head trauma	89	33
Total	270	100

**TABLE 4**

Symptomatology of patients of chronic subdural hematoma

Symptomatology	No. of patients (n-270)	Percentage
Headache	176	65.2
Hemiparesis	140	51.8

Speech disturbance	71	26.3
Altered behavior	62	23
Urinary incontinence	17	6.3
Parapareis	11	4.1
Seizure	10	3.7

**TABLE 5**

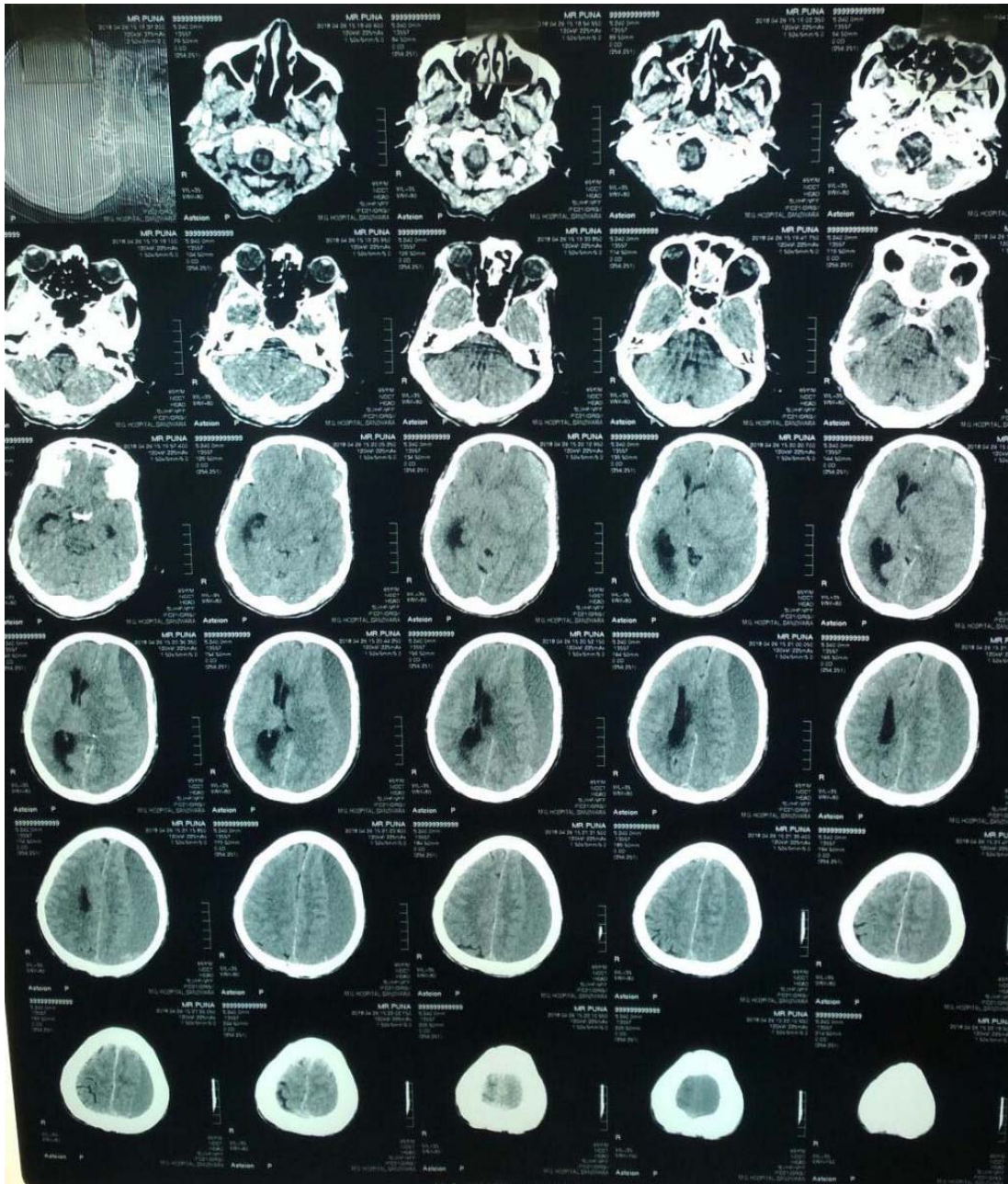
GCS at presentation (N=270)

<b>Symptomatology</b>	<b>No. of patients (n-270)</b>	<b>Percentage</b>
GCS 15-14	172	63.7
GCS 13-9	68	25.2
GCS 8-3	30	11.1
Total	270	100

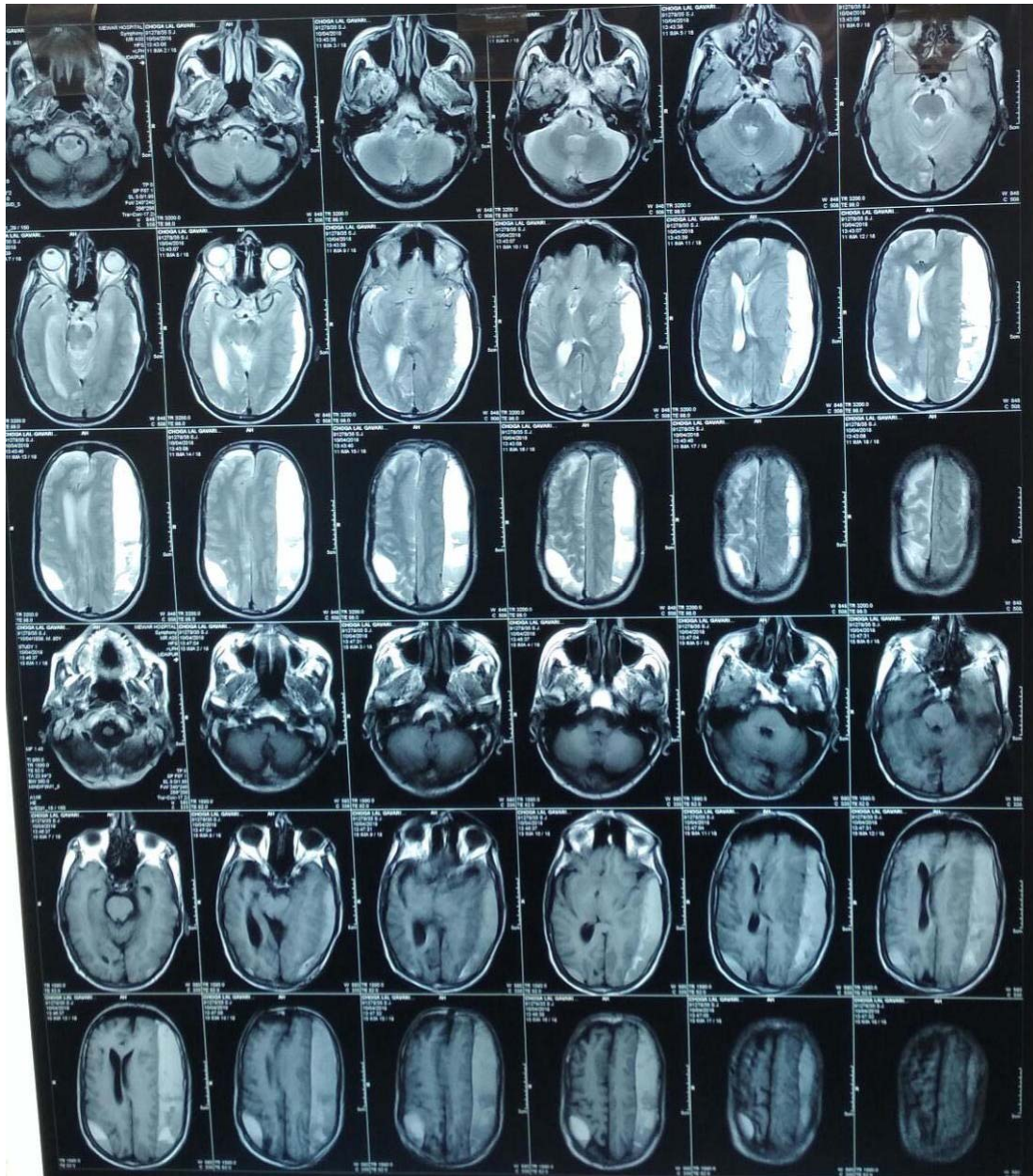
**TABLE 6**

GOS (Glasgow Outcome Scale) at the time of discharge (N=270)

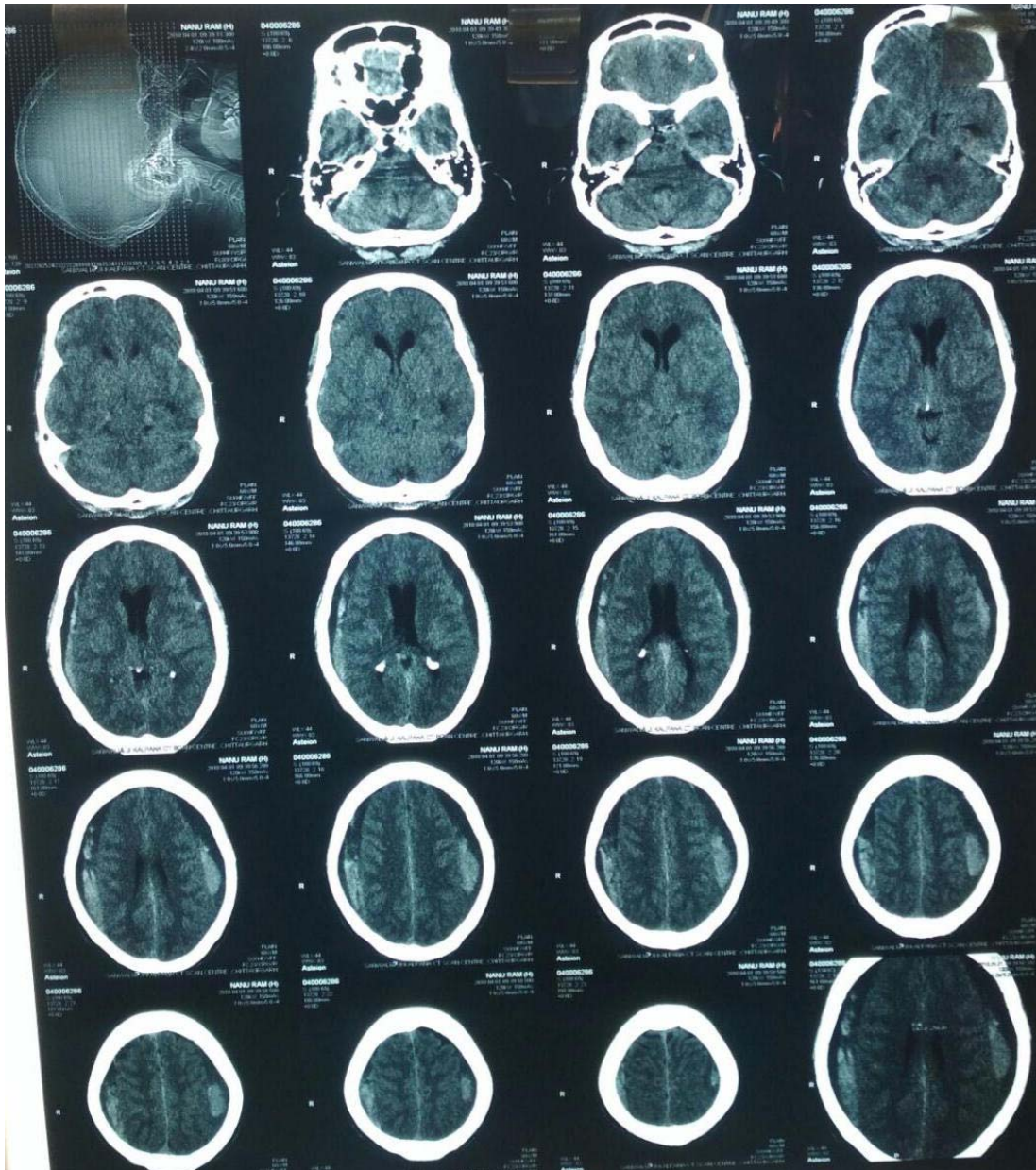
<b>Symptomatology</b>	<b>No. of patients (n-270)</b>	<b>Percentage</b>
Favorable outcome (GOS 4-5)	225	83.3
Poor outcome (GOS 3-2)	38	14.1
Death	7	2.6
Total	270	100



**Figure 1** - Left sided hemispheric iso to hypodense lesion (Chronic subdural hematoma) producing mass effect, midline shift to the right, dilatation of contralateral temporal horn

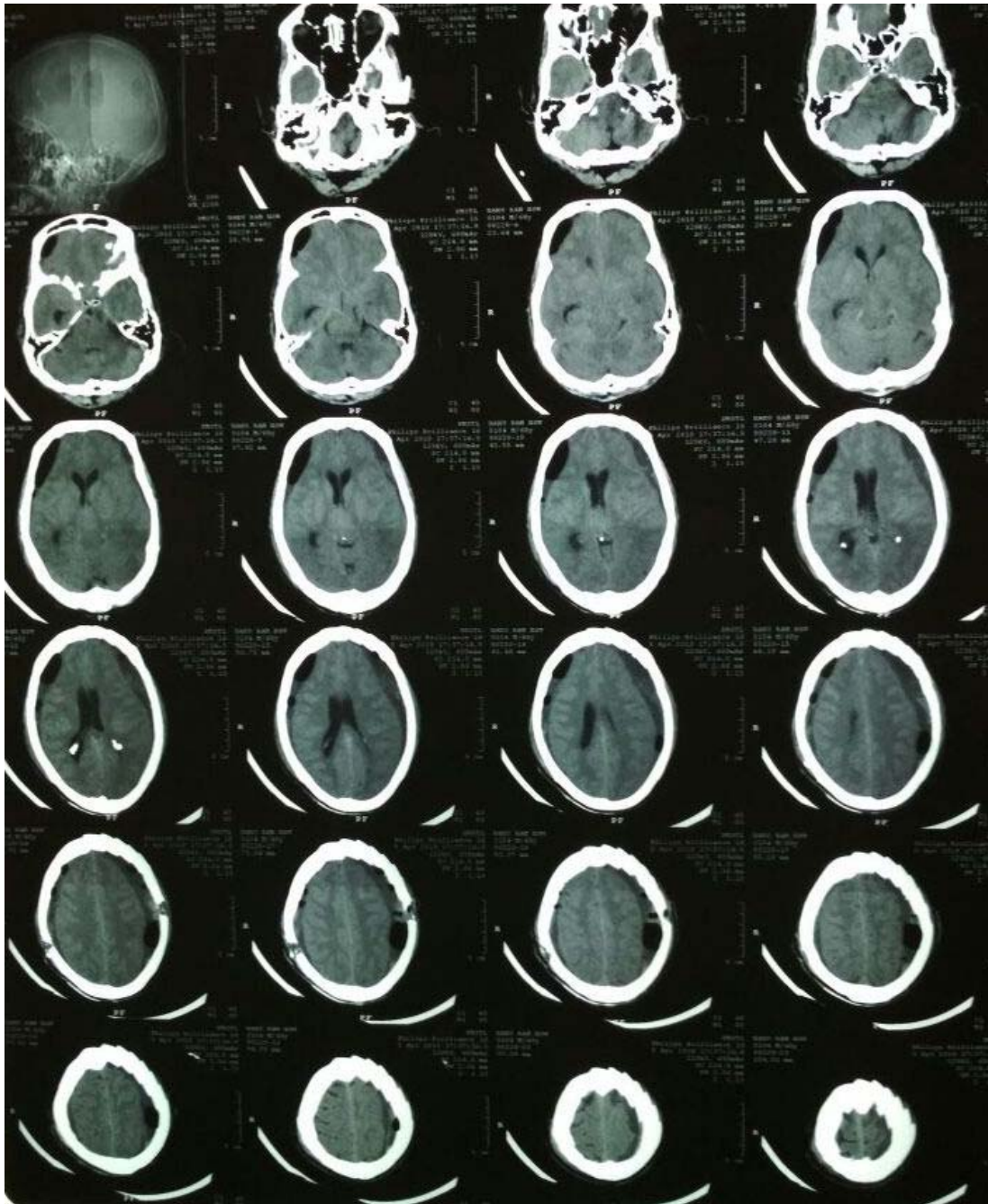


**Figure 2** - MRI of patient showing extra-axial collection on left side, hyperintense on T2WI as well on T1WI representing free Met-Hb which further is suggestive of late subacute/ chronic subdural hematoma



**Figure 3** - NCCT head of a patient with mixed density bilateral lesions suggestive of bilateral chronic subdural hematoma with acute component within





**Figure 4** - Post-operative NCCT head of the same patient (as in figure 3) bilateral pneumocephalus with bilateral burr hole in parietal region

## Discussion

Chronic subdural hematoma is quite routine in neurosurgical practice, [7] with a lot of etiological factors; foremost among them are numerous traumatic factors. However, the etiology of CSDH is not completely understood until now. [8]

As per literature, CSDH is pathologic condition, which is mostly present in older people from 50 to 70 years. The average age of our patients (63.5 years) in this study was comparable to the series by Agon et al (62.85 years) [9] but much younger than the average age stated by authors Gastone et al. (76.4 years). [10]

The ratio of male to female in our patients is 3.7:1 is much higher than the ratio found by Gastone et al. and Gelabert-Gonzales et al. 1.68:1[7], [10]. Other authors also found the higher frequency of CSDH in males in comparison to females. [11], [12], [13]

As per our results, head trauma was the most frequent cause for CSDH in 181 patients (67%), while 89 patients (33%) didn't have certain history of head trauma. Our results about the incidence of head trauma (67%) as a causative factor for CSDH are comparable to those of other authors, which report that head trauma is accountable for CSDH in 35-75% of patients. [13], [14], [15]

Clinically, CSDH is presented with a lot of symptoms. In our study the foremost symptom was headache (65.2%), followed by contralateral hemiparesis (51.8%) and speech disturbances (26.3%). The likewise symptoms and with comparable frequency were narrated

by Gelabert-Gonzalez et al., Mori and Maeda, and Sousa et al. [7], [8], [16]

We have found CSDH on the right side in (41.8%), on the left side (38.9%), and bilateral CSDH in (19.3%) of the cases. Other authors have described the higher frequency of the CSDH on the left side though not much of difference was seen. [17], [18]

All the patients were treated surgically with single burr hole evacuation primarily. Some authors approve that the optimal surgical treatment of patients with CSDH can be accomplished with one burr-hole trepanation with a closed drainage system. [11], [19]

We have used single burr hole as a primary procedure in all of our 270 patients. Although the view of the other authors is dissimilar, they consider that extended craniotomy allows better exposure of CSDH with thicker components. [20], [21]

The data from literature show that irrespective of surgical procedures, the procedure is accompanied by recurrence rates of 4% to 26%. [7], [8], [22] The recurrence rate in our series was 11.1% and is comparable to the series of the other authors. [4], [11], [19]

Seven patients (2.6%) of our series have died in the post-operative period, in comparison to 2.7% mortality reported in few other studies. [8], [19] However, some authors state mortality rate ranging from 0% to 13%. [23]

## Conclusion

Chronic SDH is mainly disease of elderly. Single burr hole evacuation is one of the most effective methods of treating uncomplicated CSDH.

### Correspondence

Dr. Gaurav Jaiswal

Address for correspondence: Dr. Gaurav Jaiswal,  
Department of Neurosurgery RNT, Medical College,  
Udaipur, Rajasthan, India

Email: drgauravjaiswal@gmail.com

### References

1. Karibe H, Kameyama M, Kawase M, Hirano T, Kawaguchi T, Tominaga T. Epidemiology of chronic subdural hematoma. *No Shinkei Geka*. 2011;39:1149-53.
2. Krupa M. Chronic subdural hematoma: A review of the literature. Part 1. *Ann Acad Med Stetin*. 2009;55:47-52.
3. Soto-Granados M. Treatment of chronic subdural hematoma through a burr hole. *Cir Cir* 2010;78:203-7
4. Hamilton MG, Frizell JB, Tranmer BI. Chronic subdural hematoma: The role for craniotomy reevaluated. *Neurosurgery* 1993;33:67-72
5. Yadav YR, Yadav S, Parihar VS. Modified twist drill technique in the management of chronic subdural hematoma. *Turk Neurosurg* 2013;23:50-4.
6. Krupp WF, Jans PJ. Treatment of chronic subdural hematoma with burr-hole craniostomy and closed drainage. *Br J Neurosurg* 1995;9:619-27.
7. Gelabert-González M, Iglesias-Pais M, García-Allut A, Martínez-Rumbo R. Chronic subdural hematoma: Surgical treatment and outcome in 1000 cases. *Clin Neurol Neurosurg* 2005;107:223-9.
8. Mori K, Maeda M. Surgical treatment of chronic subdural hematoma in 500 consecutive cases: Clinical characteristics, surgical outcome, complications, and recurrence rate. *Neurol Med chir (Tokyo)* 2001;41:371-81.
9. Mekaj AY, Morina AA, Mekaj YH, Manxhuka-Kerliu S, Miftari EI, Duci SB, Hamza AR, Gashi MM, Gjelij MR, Kelmendi FM, Sh. Morina Q. Surgical treatment of 137 cases with chronic subdural hematoma at the university clinical center of Kosovo during the period 2008-2012. *J Neurosci Rural Pract* 2015;6:186-90.
10. Gastone P, Fabrizia C, Homere M, Cacciola F, Alberto M, Nicola DL. Chronic subdural hematoma: Results of a homogeneous series of 159 patients operated on by residents. *Neurol India* 2004;52:475-7.
11. Ernestus RI, Beldzinski P, Lanfermann H, Klug N. Chronic subdural hematoma: Surgical treatment and outcome in 104 patients. *Surg Neurol* 1997;48:220-5.
12. Nakaguchi H, Tanishima T, Yoshimasu N. Factors in the natural history of chronic subdural hematomas that influence their post-operative recurrence. *J Neurosurg* 2001;95:256-62.
13. Robinson RG. Chronic subdural hematoma: Surgical management in 133 patients. *J Neurosurg* 1984;61:263-8.
14. McKissock W, Richardson A, Bloom WH. Subdural hematoma: A review of 389 cases. *Lancet* 1960;1:1365-9.
15. El-Kadi H, Miele VJ, Kaufman HH. Prognosis of chronic subdural hematomas. *Neurosurg Clin N Am* 2000;11:553-67.
16. Sousa EB, Brandão LF, Tavares CB, Borges IB, Neto NG, Kessler IM. Epidemiological characteristics of 778 patients who underwent surgical drainage of chronic subdural hematomas in Brasilia, Brazil. *BMC Surgery* 2013;13:5.
17. de Araújo Silva DO, Matis GK, Costa LF, Kitamura MA, de Carvalho Junior EV, de Moura Silva M, et al. Chronic subdural hematomas and the elderly: Surgical results from series of 125 cases: Old "horses" are not to be shot! *Surg Neurol Int* 2012;3:150.
18. MacFarlane MR, Weerakkody Y, Kathiravel Y. Chronic subdural hematomas are more common on the left on the right. *J Clin Neurosci* 2009;16:642-4
19. Kotvica Z, Brezeniski J. Chronic subdural hematoma treated by burr holes and closed system drainage: Personal experience in 131 patients. *Br J Neurosurg* 1991;5:461-5.
20. Putnam JJ, Cushing H. Chronic subdural hematoma: Its pathology, its relation to pachymeningitis hemorrhagica, and its surgical treatment. *Arch Surg* 1925;11:329-93.
21. Tyson G, Strachan WE, Newman P, Winn HR, Butler A, Jane J. The role of craniectomy in the treatment chronic subdural hematomas. *J Neurosurg* 1980;52:776-81.
22. Baechli H, Nordmann A, Bucher HC, Gratzl O. Demographics and prevalent risk factors of chronic subdural hematoma: Result of a large single-center cohort study. *Neurosurg Rev* 2004;27:263-6.
23. Santarius T, Lawton R, Kirkpatrick PJ, Hutchinson PJ. The management of primary chronic subdural hematoma: A questionnaire survey of practice in the United Kingdom and the Republic of Ireland. *Br J Neurosurg* 2008;22:529-34.