

Article

Conus intramedullary pyogenic abscess in a 4years old child: a rare case report and review of literature

Prajapati Hanuman Prasad, Singh Deepak Kumar, Singh Rakesh Kumar, Ahmad Faran
INDIA



DOI: 10.1515/romneu-2017-0090

Conus intramedullary pyogenic abscess in a 4years old child: a rare case report and review of literature

Prajapati Hanuman Prasad, Singh Deepak Kumar, Singh Rakesh Kumar, Ahmad Faran

Department of Neurosurgery, Dr RML IMS Lucknow Uttar Pradesh, INDIA

Abstract: Intramedullary pyogenic abscess in the conus medullaris in a young child is an extremely rare condition. It had never been reported in literature. It should be differentiated from other more common pathology like tubercular abscess, dermal sinus, epidermoid and dermoid tumour. Early diagnosis and prompt surgical evacuation may lead to good neurological recovery from this rare benign pathology.

Key words: conus medullaris, intramedullary, pyogenic abscess, children

Introduction

Intramedullary abscess especially in conus region is an extremely rare condition, only few cases reported in the literature. Most of the reported cases shows that these abscess are mainly due to tubercular pathology [1, 2, 3, 4, 5, 6]. Some of the reported cases shows that congenital dermal sinus and epidermoid cyst also causes abscess in this region. We report that what we believe to be the first instance of its occurrence within the conus medullaris in a young child. This case study shows the salient clinical, etiopathogenesis, and radiologic features. We also discuss management of this rare entity and review the pertinent literature to the best of the authors' knowledge, an intramedullary conus pyogenic abscess especially in young child had never been reported in literature.

Case Report

A 4 years old female child presented to us with complain of weakness of both lower limb from last 4month and urinary incontinence, difficulty in walking and intermittent fever from last 1month. Patient was taking antibiotic for last 15 days. On examination patient was conscious and oriented. Bulk was normal and tone was increased in both lower limb. Her power was 3/5 at hip, knee and ankle joint bilaterally. Knee and ankle reflex was +3 and there was no clonus. Her sensation was diminished in both lower limb below L1 dermatome. There was no any cutaneous stigmata of spinal dysraphism. Patient was evaluated with contrast MRI dorsolumbar spine with screening of whole spine. On MRI T2WI shows well circumscribed, hyperintense, cystic mass at D11 to L1 region. Contrast MRI shows

peripheral enhancement of the lesion. Patient was planned for surgery. In surgery D11 to L1 laminectomy was done. There was no any dural adhesion or arachnoiditis. A small midline myelotomy done at most bulged part of cord. On myelotomy frank creamy colour pus was coming out. Suction irrigation of the cavity was done. Pus was sent for AFB staining, culture sensitivity and for TB PCR. AFB and TB PCR was negative for tuberculosis and no any organism was found on culture. Post operatively patient was given antibiotic for 4 weeks. Patient improve gradually and she can stand and walk with support.

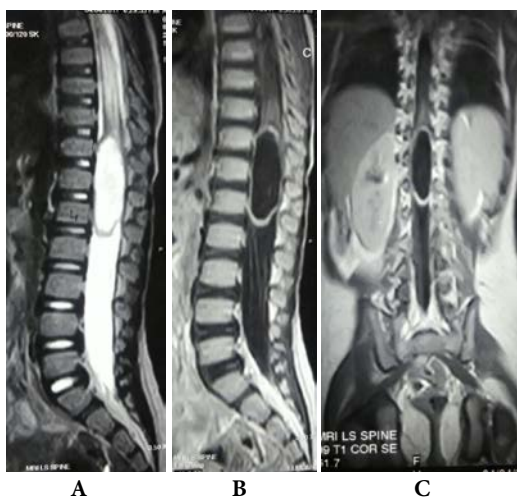


Figure 1A - MRI T2WI of dorsolumbosacral spine, sagittal section showing wellcircumscribed, hyperintense lesion at D11-L1

Figure 1B - Contrast MRI of dorsolumbosacral spine, sagittal section showing peripheral enhancement of the lesion

Figure 1C - Contrast MRI of dorsolumbosacral spine, coronal section showing peripheral enhancement of the lesion

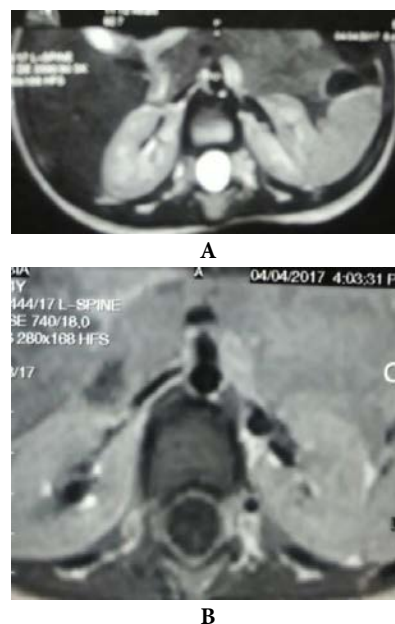


Figure 2A - MRI T2WI of dorsolumbosacral spine, axial section showing wellcircumscribed, hyperintense, cystic lesion

Figure 2B - Contrast MRI of dorsolumbosacral spine, axial section showing peripheral enhancement of the lesion

Discussion

Intramedullary spinal cord pyogenic abscess at young age is extremely rare. On reviewing the literature we found that no case of intramedullary pyogenic abscess in conus medullaris was reported in children. Only two such case of intramedullary pyogenic abscess in conus medullaris was reported in adult [7,8]. Most of the other reported cases of intramedullary abscess in conus medullaris was mostly a tuberculoma or a tuberculous abscess.

Intramedullary abscess in conus medullaris may be due to bacterial infection, tuberculosis, dermal sinus and or due to

dermoid and epidermoid cyst. There was no history of any tubercular contact, any focus of tuberculosis in the body. Intraoperatively there was absolute lack of either dural or arachnoidal adhesions around the conus. This was at variance with the findings of dense arachnoidal adhesions surrounding the involved intramedullary segment noted by most authors reporting an intramedullary tuberculous abscess [1,6]. On pathological examination TB PCR was negative and no acid fast bacilli was seen on AFB staining. So we have ruled out a tubercular abscess in our case. In our case there was no any dermal sinus or dermoid and epidermoid tumour. No history of cutaneous stigmata of spinal dysraphism. Intraoperatively frank pus of cream colour was found which suggest pyogenic etiology. Although no microorganism was detected on culture sensitivity test. Most likely it was due to use of preoperative antibiotics.

Although the pathogenesis of this primary conus abscess was unknown. A complex sequence of events may have led to the genesis of conus pyogenic abscess. Hematogenous spread of bacteria (which was present in subclinical state) obstructed an end artery in the cord substance causing ischemic necrosis. Further expansion of the liquid content occurred through osmosis via the Virchow Robinson spaces within the cord producing the pyogenic abscess.

Although the conus intramedullary abscess was a rare entity. Most of the reported cases of conus intramedullary abscess was due to tuberculosis. Conus intramedullary pyogenic abscess was extremely rare condition, only two such case was reported in adult. No such case

was reported in children. Other pathology causing intramedullary abscess in conus medullaris were also reported in literature. M.F. Hassan et al. [7] reported intramedullary pyogenic abscess in the conus medullaris in adult. J Lee et al [8] reported *Nocardia cyriacigeorgica* abscess of the conus medullaris in an immunocompetent host. BS Koppel et al [9] reported intramedullary abscess in conus medullaris due to dermal sinus. RS Maurice-williams et al. [10] reported intramedullary abscess in conus medullaris due to epidermoid cyst.

Conclusion

To the best of our knowledge, an intramedullary pyogenic abscess located within the conus medullaris in a young child are extremely rare. No such case was reported in the literature. Early diagnosis and treatment leads to improved recovery of this rare benign pathology.

Correspondence

Dr. Hanuman Prasad Prajapati

Address: Department of Neurosurgery, Dr RML

IMS Lucknow Uttar Pradesh (India)

Mobile No.: 07727934104

Email: pushpa84.dhp@gmail.com

References

1. Cheng KM, Ma MW, Chan CM, Leung CL: Tuberculous intramedullary spinal cord abscess. *Acta Neurochir (Wien)* 139:1189-1190, 1997.
2. Courson B, Brunel M, Petit M, Tondut A: Intramedullary tubercular abscess. *Bull Soc Med Afr Noire Lang Fr* 13:500-503, 1968.
3. Devi BI, Chandra S, Mongia S, Chandramouli BA, Sastry KV, Shankar SK: Spinal intramedullary

tuberculoma and abscess: a rare cause of paraparesis. *Neurol India* 50:494-496, 2002.

4. Hanci M, Sarioglu AC, Uzan M, Işlak C, Kaynar MY, Oz B: Intramedullary tuberculous abscess: a case report. *Spine (Phila Pa 1976)* 21:766-769, 1996.

5. Hoda MF, Prasad R, Singh VP, Maurya P, Singh K, Sharma V: Spinal intramedullary tubercular abscess. *Indian J Tuberc* 52:211-214, 2005.

6. Tacconi L, Arulampalam T, Johnston FG, Thomas DG: Intramedullary spinal cord abscess: case report. *Neurosurgery* 37:817-819, 1995.

7. Hasan MF, Mohamed MB, Kalsi P, Sinar EJ, Bradey N: Intramedullary pyogenic abscess in the conus medullaris. *Br J Neurosurg*. 2012 Feb;26(1):118-9.

8. Lee J, Whitby M, Hall BI: *Nocardia cyriacigeorgica* abscess of the conus medullaris in an immunocompetent host. *J Clin Neurosci*. 2010 Sep;17(9):1194-5.

9. Koppel BS, Daras M, Duffy KR: Intramedullary spinal cord abscess. *Neurosurgery* 1990;26:145-6.

10. Maurice-williams RS, Pamphilon D, Coakham HB. Intramedullary abscess-a rare complication of spinal dysraphism. *J Neurol Neurosurg Psych* 1980;43:1045-8.