

Article

Extracranial internal carotid artery aneurysm: case illustration

Marco Zenteno, Liliana Escobar, Angel Lee, Hernando Raphael Alvis-Miranda, Willem Guillermo Calderon-Miranda,
Luis Rafael Moscote-Salazar
MEXICO, COLOMBIA



DE GRUYTER
OPEN

DOI: 10.1515/romneu-2017-0079

Extracranial internal carotid artery aneurysm: case illustration

Marco Zenteno¹, Liliana Escobar¹, Angel Lee¹, Hernando Raphael Alvis-Miranda², Willem Guillermo Calderon-Miranda³, Luis Rafael Moscote-Salazar²

¹National Institute of Neurology and Neurosurgery “Dr. Manuel Velasco Suarez” Mexico City, MEXICO

²Department of Neurosurgery, University of Cartagena, Cartagena de Indias, COLOMBIA

³National Autonomous University of Mexico, Mexico City, MEXICO

Abstract: Extracranial internal carotid artery aneurysms (EICAA) are uncommon lesion. These aneurysms can be classified as true or false aneurysms, atherosclerotic, dysplastic, infectious, posttraumatic and iatrogenic aneurysms. The most common presentation is central neurologic dysfunction, either a stroke or a transient ischemic attack. The rupture of these aneurysms can lead to severely impairment and can affect the quality of life of the patients or even may lead to death. Management of these lesions is required in most cases to prevent complications, however there is no treatment guideline or expert consensus for the management. We present a case of an unusual EICAA, associated with kinking of the affected vessel and review the literature.

Key words: Extracranial internal carotid artery; cerebral aneurysm; carotid kinking; endovascular therapy

Introduction

Extracranial carotid artery aneurysms are rare, with estimated incidence between 0.1%-2% of all angiographical diagnostic procedures in large series; and up to 3.7% of all carotid procedures; and between 0.4 – 4% of all peripheral artery aneurysms.(1) A review of the literature conducted by the Vascular Group of the Cleveland Clinic Foundation identified only 12 total reported

cases, including 8 at their own facility, over a 17-year period. They can be classified according to their physiopathology as true or false aneurysms, according to their etiology in atherosclerotic, dysplastic, infectious, posttraumatic and iatrogenic aneurysms. Extracranial internal carotid artery aneurysms (EICAA) generally are asymptomatic, but neurological symptoms are the most frequent. Despite its rarity, these

aneurysms are of interest because of their diverse etiology, and the need for correct choices of diagnostic and therapeutic strategies. They can severely affect the quality of life of the patients or even may lead to death if they are not recognized and treated. (2) It can give rise to serious complications like haemorrhage due to rupture, stroke and thromboembolism. We present the case of a patient with angiographical diagnostic compatible with an unusual EICAA.

Case Report

A 40-years-old female patient was admitted to the emergency department with presence of a pulsatile mass located in the right lateral cervical region. The mass was not associated with any pain, there was no history of trauma. Occasionally she had complains of dysphagia. Auscultation does not reveal any pathological murmur. Cerebral and cervical vessels panangiography showed presence of one aneurysm of 20mm x 20mm, located in the right cervical internal carotid artery, in the bulbar portion, immediately distal to a severe kinking. (Fig 1,2 3). The A1 portion of the ipsilateral anterior cerebral artery was hypoplastic, and the pressure sequence is negative, being discarded collaterals. The left internal carotid artery was completely normal. The medical board decided to perform endovascular therapy. Maneuvers of microcatheter, guides, microguides, and stent navigation were performed with the road mapping.

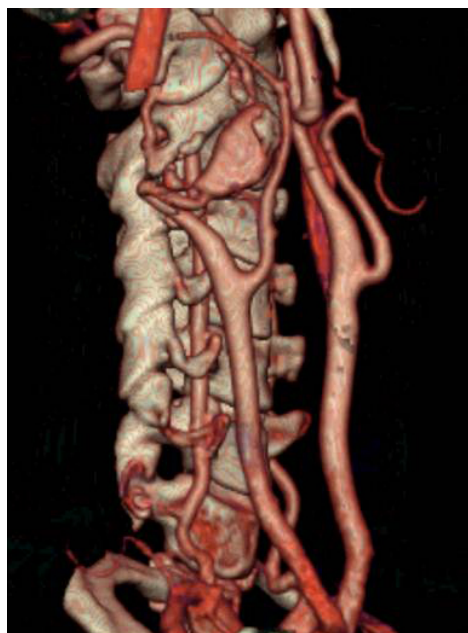


Figure 1 - 3D Angio- CT Scan: Lateral View of the right carotid axis

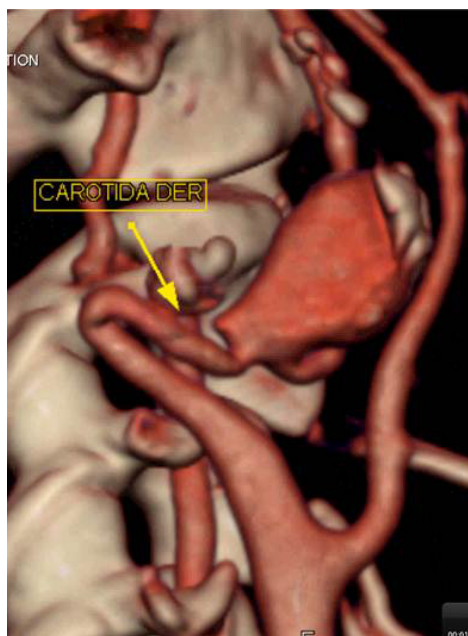


Figure 2 - 3D Angio- CT Scan: Lateral View of the right carotid axis

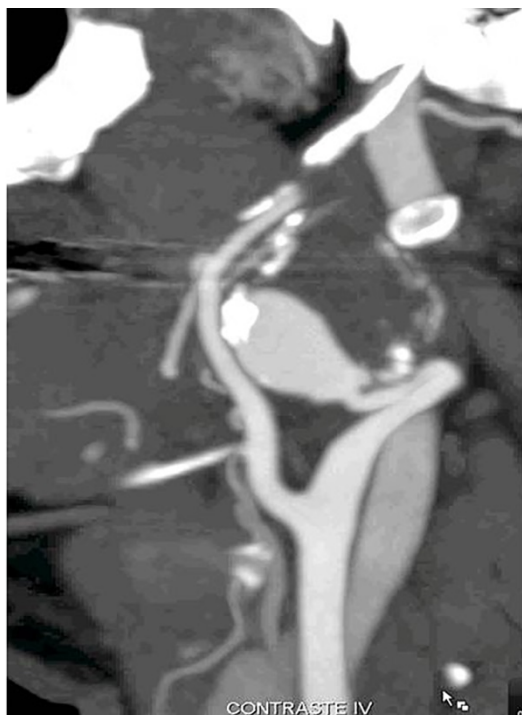

Figure 3 - Angio- CT Scan: Lateral View of the right carotid axis

The initial planning was to perform embolization through exclusive stent application, thus, a guide is navigated distal to the lesion, trying repeatedly to navigate the stent in the vessel and coating the aneurysm ostium. Kinking rectification maneuvers (cervical hyperextension, cephalic limb contralateral rotation, apnea in maximum inspiration, buddy wire technique with guide 0.014, and hydrophilic Terumo® guide) were failed. Because of the risk of dissection secondary a forced maneuver in a patient without collateral circulation, it was decided to engage the maneuver and proceed to the coils placement. The coils were deployed according to the usual technique, covering the entire aneurysm sac without complications. A

marked diminution in the filling of the aneurysm was observed immediately. The selective catheterization of the left vertebral artery (LVA), produced a dissection in the V1-V2 union, which was not feasible to correct, because the microguide not able to navigate distal to the dissected portion. The collaterals from the right vertebral artery were satisfactory, taking both vertebral territories, renouncing to perform angioplasty. In controls was observed that LVA was never completely occluded. Full-dose antiplatelet is maintained, turning to orally antiplatelet posteriorly. The patient was discharged without any complications.

Discussion

EICAA are rare vascular problems with a great potential for lethal thromboembolic episodes.(5) Associated kinking of the artery is further rare. The most frequent cause is atherosclerosis (46%–70%), followed by fibromuscular dysplasia, trauma, iatrogenic lesions, congenital defects, irradiation arteritis, or infection of the parapharyngeal space extending to the vessel wall. Some authors suggest that it is of great importance to distinguish the etiology of the aneurysms because atherosclerotic EICAA might have a greater risk of early complications than dysplastic ones.

It is important to establish if there is associated kinking of the artery. Ilic et al suggest that degenerative aneurysms usually are associated with tortuosity of the artery unlike dysplastic aneurysms, which can usually be mistaken for a kinked artery. (5) Due to enlargement of the saccular aneurysm,

concomitant kinking of the ICA may be present, as in our patient, adding further risk of cerebral events. Furthermore, dysplastic aneurysms are localized below the kinked artery and are much complicated for surgical reconstruction as a result of its fragile and thin wall.(5) Just for remember isolated major abnormalities in the cervical segment of the ICA occur near of its origin or at the distal portion, at level of the atlas or axis. Weibel after performing 1438 angiographies of neck vessels, found that 75% of ICA kinks were placed at 2-4 cm of the carotid bifurcation.

These aneurysms may be asymptomatic or present as a cervical pulsatile mass and provoke symptoms of adjacent neurovascular structure compression. The most common presentation is central neurologic dysfunction, either a stroke or a transient ischemic attack. (3) Extracranial carotid aneurysm is equivocally diagnosed by palpation and visual inspection; however, CT scans and MRI are useful diagnostic methods, but they cannot always be performed immediately. For the diagnosis, color Doppler ultrasonography is very useful because real-time pictures of the aneurysm can be obtained noninvasively. There is no treatment guideline or expert consensus for the management of EICAA till today, but management is required in most cases to prevent complications. The therapy includes resection of the aneurysm and restoration of flow with venous, arterial, or prosthetic graft or endovascular stenting or end to end primary anastomose, depending on the size, location, and anatomic relation to surrounding structures. (4)

Diverse surgical procedures have been reported: aneurysmectomy with end-to-end anastomosis, vein graft or Dacron interposition, anastomosis between the external and internal carotid artery, or even arterial ligation in emergency cases of aneurysm rupture. Endovascular interventions require conductive anatomy and a skilled provider armed with the correct equipment to facilitate successful treatment via this modality. Using this approach one must also be concerned with the possibility that the vessel of the patient may continue to undergo age-related growth or dilation around the inserted device. It should be considered the fact that there exists no significant experience with the use of endovascular techniques in the treatment of this kind of aneurysms.

Recent experience suggests that endovascular stenting is an emerging alternative treatment with promising results and a revolution from operative to endovascular intervention. Due to paucity of data and lack of large series, limited knowledge of its safety and efficacy is available, as mentioned previously. Other authors consider that endovascular stenting is technically feasible with high procedure success and relatively low complication rate in patients with EICAA, with both short- and mid-term outcomes appearing to be favorable. It is necessary when deciding in favour of endovascular therapy to evaluate for some circumstance that difficult the choice of endovascular repair such as fragile wall and narrow lumina of the altered artery. (5).

Conclusion

EICAA is a very rare occurrence that needs urgent management, the advanced imaging and surgical techniques used in the treatment of this patient avoided potential negative outcomes. Regard endovascular therapy there exists no significant experience in the treatment of this kind of aneurysms, but in selected patients, can be an excellent option, with satisfactory outcomes.

References

1. Welleweerd JC, Moll FL, de Borst GJ. Technical options for the treatment of extracranial carotid aneurysms. *Expert Rev Cardiovasc Ther* [Internet]. 2012 Jul [cited 2013 Nov 2];10(7):925–31. Available from: <http://www.ncbi.nlm.nih.gov/pubmed/22908925>
2. Garg K, Rockman CB, Lee V, Maldonado TS, Jacobowitz GR, Adelman MA, et al. Presentation and management of carotid artery aneurysms and

- pseudoaneurysms. *J Vasc Surg* [Internet]. 2012 Jun;55(6):1618–22. Available from: <http://www.sciencedirect.com/science/article/pii/S0741521411031028>
3. Yoneyama T, Kawashima A, Sugiura M, Yamaguchi K, Itou K, Namioka A, et al. Technical options for the surgical management of extracranial carotid artery aneurysms. Three case reports. *Neurol Med Chir* [Internet]. 2012 Jan [cited 2013 Nov 1];52(4):208–12. Available from: <http://www.ncbi.nlm.nih.gov/pubmed/22522332>
 4. Rosset E, Albertini JN, Magnan PE, Ede B, Thomassin JM, Branchereau A. Surgical treatment of extracranial internal carotid artery aneurysms. *J Vasc Surg* [Internet]. 2000 Apr [cited 2013 Nov 2];31(4):713–23. Available from: <http://www.ncbi.nlm.nih.gov/pubmed/10753279>
 5. Ilic N, Koncar I, Dragas M, Markovic M, Kostic D, Davidovic L. Aneurysm of the Kinked Extracranial Internal Carotid Artery: Extraordinary Union. [Internet]. *Am. Surg.* 2010. p. E214–E215. Available from: <http://ezproxy.unicartagena.edu.co:2048/login?url=http://search.ebscohost.com/login.aspx?direct=true&db=a9h&AN=64471265&lang=es&site=ehost-live>