

Article

Anterior communicating artery aneurysm clipping versus coiling: a comparative study of 50 cases

Pradeep Kumar, Shashi K. Jain, Virendra D. Sinha, Trilochan Srivastava
INDIA



DE GRUYTER
OPEN

DOI: 10.1515/romneu-2017-0060

Anterior communicating artery aneurysm clipping versus coiling: a comparative study of 50 cases

Pradeep Kumar, Shashi K. Jain, Virendra D. Sinha, Trilochan Srivastava

Sawai Man Singh Medical College, Jaipur, INDIA

Abstract: *Introduction:* Aneurysmal Subarachnoid Hemorrhage (aSAH) remains a devastating and often fatal form of stroke. The aneurysm is targeted for obliteration to prevent re-bleeding and to manage the possible complications from the event. Endovascular coiling has emerged as a less invasive alternative to conventional surgical clipping to treat aneurysms. *Patients and methods:* This study was done in 50 cases of anterior communicating (Acomm) aneurysm presented in the department of neurosurgery, SMS medical college, Jaipur from November 2015 to August 2016 to evaluate the outcome of both modalities used in the treatment of ruptured Acomm aneurysm. 50 patients with Hunt and Hess (H&H) grade I, II or III were classified into two groups of microsurgical clipping and endovascular coiling. *Results:* Mortality rate was comparable in both groups that were 21. 21% in the clipping group and 23. 52% in the coiling group. Good Glasgow outcome score (GOS) were found in 60. 60% of clipping and 58. 58% of coiling group. All the complications found to be more in clipping group but that were not statistically significant except for hyponatremia which was significantly higher in clipping group (P=0. 007). *Conclusion:* There was no statistically significant difference in GOS at 6 month of follow up between the two groups. We recommend further interventional studies with larger sample sizes and longer follow up for better evaluation of the modalities.

Key words: Acomm aneurysm, clipping, coiling, GOS

Introduction

Aneurysmal subarachnoid hemorrhage (aSAH) is a very disastrous and fatal emergency requiring immediate intervention as approximately 12% of patients die before receiving medical supports, 33% within 48 hours and 50% within 30 days of aSAH and 50% of survivors suffer from permanent

disability and dependency. [1] The Acomm aneurysm is the most common location of cerebral aneurysms and it accounts for about 36% of aneurysms. [2] Among patients admitted to hospital in good clinical status for the treatment of ruptured Acomm aneurysm, about 80% have achieved favourable outcome. [3] About 46% of

survivors after SAH may have cognitive impairment. [2, 4] Endovascular coiling has increasingly become an alternative procedure for surgical clipping in both ruptured and unruptured aneurysms in last few decades. [5, 6] However, there are some risks and complications such as thromboembolism, aneurysm rupture, patent artery occlusion, coil migration and vasospasm in endovascular therapy. [7] Both modalities have their own advantages and disadvantages which make them as complementary rather than competitive. [6] The most prominent advantage of surgical clipping is long term durability which is controversial in endovascular coiling. Long-term follow up performed by intracranial subarachnoid aneurysm trial (ISAT) showed that coiling had higher risk of rebleeding than clipping. [7, 8, 9] The disadvantage of surgical clipping is that it requires open surgery which is accompanied with more morbidity in elderly patients. [10] So, durability of endovascular coiling is not a major concern in the old age group of patients. [9] The advantages of endovascular coiling are less invasiveness, easy access to vertebrobasilar system and multiple aneurysms in different areas. [6] However, coiling is not useful in all aneurysms as it cannot remove intracerebral hemorrhage or mass effect of giant aneurysms. [11]

This paper will evaluate the outcome of microsurgical clipping versus endovascular coiling in the treatment of 50 patients with ruptured Acommm artery aneurysm performed in the department of neurosurgery, SMS medical college, Jaipur, India to provide the best protocol of management for this condition.

Patients and methods

This study was done in 50 cases of Acommm aneurysm presented in the department of neurosurgery, SMS medical college, Jaipur from November 2015 to August 2016 and an ethical clearance taken from the ethical committee of the institute (reference Number 2187 MC/EC/2016).

All patients were divided into two groups depending upon the therapeutic intervention performed-

- (a) Microsurgical clipping (33)
- (b) Endovascular coiling (17)

All patients included must fulfil the following inclusion criteria-

1. Diagnosed cases of Acommm aneurysm by CT angiography or digital subtraction angiography (DSA)
2. Hunt and Hess grade I, II & III

Exclusion criterias:

1. H & H grade IV & V
2. Other than Acommm aneurysm
3. Multiple aneurysms

All the patients were examined first by neurologist or neurosurgeon. The benefits and complication associated with both procedures were thoroughly explained to the patients and their relatives and they had a choice to choose one of the procedure. There was a proforma which was filled for all patients at the time of admission including demography, risk factors, H & H grade, characteristics of aneurysm, the procedure performed including complications and Glasgow Outcome Scale (GOS) recorded during at least 6 months of follow up after intervention.

Extracted data were analysed with SPSS

(version22, SPSS Inc., Chicago, IL, USA). Chi-square, fisher exact, independent-t, paired-t and Mann-Whitney U tests were used and considered as statistically significant at $P < 0.050$.

Results

Seventeen patients underwent endovascular coiling and thirty three patients underwent surgical clipping. There were 22 females (44%) and 28 males (56%) as shown in table 1. Mean age of patients allocated to surgical treatment was 49.75 years and mean age of patients allocated to endovascular therapy was 52.17 years ($P = 0.5080$). The risk factors associated were featured in table 2.

The above table 2 revealed that there was no significant difference between the two groups with regards to associated risk factors as P-values were >0.05 although hypertension (78%), smoking(34%) and hyperlipidemia (30%) were present in aSAH. There were 2 (4%) patients who had no any known risk factors.

The main presenting complaints of the patients were severe headache 48 (96%), focal neurological deficits 23 (46%), vertigo 12 (24%) and asymptomatic or mild headache in 2 (4%).

The difference in mean H & H grade of clipping and coiling group were not statistically significant as the independent sample t test revealed that $t(48) = 1.115$, $P = 0.271$ as shown in table 3.

But, Mann-Whitney U Test reveals that there is no statistically significant difference between these two groups as $P\text{-value} = 0.265$ as in table 4.

There were 27(54%) aneurysm present at right Acommm-anterior cerebral artery (ACA) complex with dome size of 3mm-14mm and mean neck size of 3.05mm in clipping and 2.69mm in coiling group. The difference in mean neck size of clipping and coiling group was not statistically significant as the independent sample t test revealed that $t(48) = 0.596$, $P = 0.554$. Therefore, there was no difference in these two groups. Hypoplastic A1 branch of ACA was found in 7(14%) with one bilateral P1 hypoplastic artery. Only two (4%) had bilobed aneurysm. The direction of projection of fundus of aneurysm based on CT angiography or DSA coronal and saggital images was as shown in table 5.

The mean duration of operation for surgical clipping was 2.9697 hours and for endovascular coiling was 2.1971 hours. At $t(48) = 6.555$, $P = 0.0001$, reveals that mean duration of operation was significantly higher in clipping than coiling. The mean duration of hospital stay was 10.0741 days and 8.2308 days in clipping and coiling group respectively. The difference in mean days of hospital stay of live patients was not statistically significant as $t(38) = 0.831$, $P = 0.411$. The following complications were found in the follow up of 6 months durations as shown in table 6.

As far the GOS was concerned there was no significant difference between the two groups at 6 months of follow up. The patients were categorized as good outcome (grade 4 & grade 5) and poor outcome (grade 2 & grade 3) as shown in table 7.

TABLE 1

Showing sex distribution between the two groups

Type of operation	CASES		TOTAL
	male	Female	
Clip	17(51.5%)	16(48.5%)	33(100%)
Coil	11(64.7%)	6(35.3%)	17(100%)
	28(56%)	22(44%)	50(100%)

TABLE 2

Risk factors associated with Acommm aneurysm

Risk factor	Clipping n(%)	Coiling n (%)	P-value
hypertension	24 (72.7%)	10 (58.8%)	0.318
Smoking	10 (30.3%)	7 (41.2%)	0.442
hyperlipedemia	9 (27.3%)	6 (35.3%)	0.558
Alcohol	1 (3%)	3 (17.6%)	1.04
Diabetes	1 (3%)	1 (5.9%)	1.00
Cocaine	0%	1 (5.9%)	0.34

TABLE 3

Distribution of patients according to H & H grade

H & H grade	Clip	Coil
I	1 (2%)	1 (2%)
II	15 (30%)	9 (18%)
III	17 (34%)	7 (14%)
	33 (66%)	17 (34%)

TABLE 4

Group statistics according to H & H grade

H&H grade	Type of operation	N	Mean	Std. Deviation	Std. Error Mean
	CLIP	33	2.4848	.56575	.09848
COIL	17	2.2941	.58787	.14258	

TABLE 5

Projections of Acommm aneurysm fundus

	Clip	Coil	TOTAL(%)
superior	13	5	18 (36%)
anterior	8	4	12 (24%)
posterior	3	6	9 (18%)
inferior	5	2	7 (14%)
complex	4	0	4 (8%)
	33	17	50 (100%)

TABLE 6

Complications associated with clipping and coiling groups

Complications	Clip	Coil	P-value(Chi-square)
intraoperative rupture	1	2	0.218
Vasospasm	11	3	0.242
Infarct	9	4	0.775
Ich/IVH	4	1	0.486
Hydrocephalos	1	0	0.468
Hyponatremia	11	2	0.007
Cognitive impairment	10	2	0.146
Death	7	4	0.520

Table 7

GOS at 6 months of follow up

Group	Poor GOS n (%) [GOS- 2 & 3]	Good GOS n (%) [GOS-4 & 5]
Clip	6 (18.18%)	20 (60.60%)
Coil	3 (17.64%)	10 (58.58%)

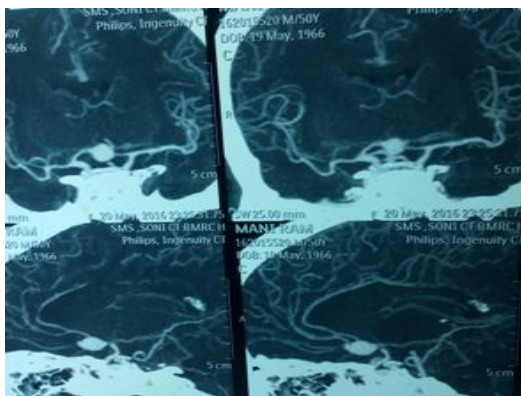


Figure 1 - CT Angiography shows Acomm aneurysm projecting anteroinferiorly

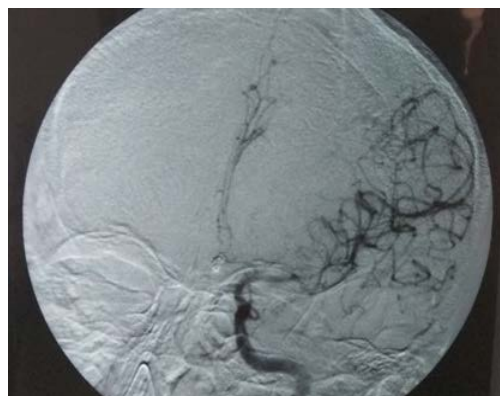


Figure 4 - DSA shows coils in situ with complete obliteration of sac with patent bilateral ACA

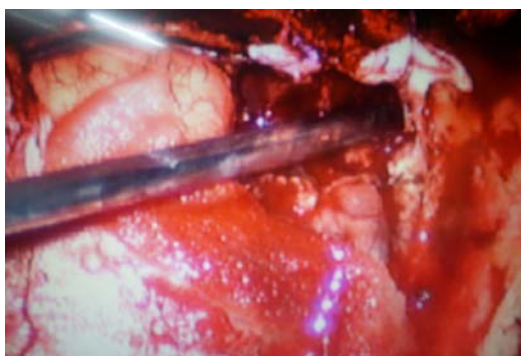

Figure 2 - intraoperative image showing sac of aneurysm

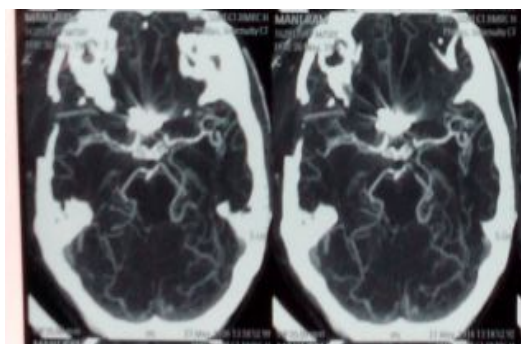


Figure 3 - Post operative CT Angiography shows patent bilateral ACA with clip in situ

Discussion

This study had been done to compare the surgical clipping with endovascular coiling in treatment of aSAH due to ruptured Acomm aneurysms in terms of risk factors, preprocedural clinical findings of the patients, the aneurysmal characteristics, procedural complications and 6 months follow up disability status based on GOS. The endovascular coiling had been introduced as the brain aneurysm treatment since 1990s and approved as a relatively minimal invasive method. [7] Few studies have focused on the comparison of the coiling and clipping in the treatment of disease. It is thought that about 6% of the international population harbor intracranial aneurysms with a greater prevalence in the Asian and Finnish populations (4–9%). [12] Risk factors associated with the presence and rupture of intracranial aneurysms have included high blood pressure, smoking, hyperlipidemia, genetic and ethnic related factors. However, the prevalence of lesions is still thought to be approximately 2% in those without any known

risk factors [12]. The annual risk of rupture is being reported to be between 0.1% and 8%, depending on variable lesion characteristics [12].

The International Study of Unruptured Intracranial Aneurysms (ISUIA) reported in two recent publications that the risk of aneurysm rupture was substantially lower than previously thought, that is, approximately 2% in anterior circulation aneurysms in those less than 7 mm. [13,14] The patients who experience subarachnoid hemorrhage (SAH) after aneurysmal rupture, approximately one third return to a functional life, one third have a significant morbidity, and one third do not survive. [12,14,15] The greatest risk after the initial aneurysmal rupture is re-rupture. After securing the aneurysm either operatively or by endovascular treatment, the risks are of cerebral vasospasm leading to ischemic complications and of developing hydrocephalus from such an event, thereby underlying the importance of early intervention and close monitoring in the post-rupture period. [16]

In 1996, Moret et al. reported the results of endovascular treatment in 36 Acommm aneurysms. The treatment was failed in seven of these cases (20%). The reason of failure can be explained because the technical armamentarium in the mid-1990s was not as advanced and sophisticated as it is today. Of the 29 treated aneurysms, a complete occlusion was possible in 23 cases (79%) and partial occlusion with neck remnant in the remaining 6 cases (21%). These investigators found a post-procedural temporary neurological deficit in two cases, and the

procedure-related permanent morbidity was 3.5% (1 case). There was no procedure-related death. [17]

In 2002 Kazekawa et al. published the clinical and angiographic evaluation in nineteen patients with Acommm aneurysms who were treated with coils. Complete obliteration was obtained in 68% of cases, with a neck remnant was seen in 32% of cases. Regarding the clinical outcome, 3 patients (15%) who were originally categorized in H & H Grades IV and V died, 1 (5%) was moderately disabled, and 15 (80%) had a good recovery. [18] With recent technical advancements, such as rotational angiography, new microcatheters and micro-guidewires, small and super-soft coils, and compliant balloons for the balloon assisted technique, the failure rate of coiling of Acommm aneurysms is diminishing.

In 2009 Guglielmi et al. in their large endovascular series on 306 ruptured Acommm aneurysms treated by coiling reported a complete occlusion achieved in 139 cases (45.5%). A neck remnant was detected in 145 aneurysms (47.5%), and in 22 cases (7%) a residual filling of the aneurysm was observed. Regarding the overall clinical neurological outcome, 280 patients (91.5%) remained neurologically intact, improved, or unchanged from their initial clinical status. Two large, wide-necked, subtotally occluded aneurysms ruptured 3–7 months after the procedure, with subsequent death of the patients. The procedure-related morbidity and mortality rates were 3.5% (11 cases) and 1% (3 cases), respectively. [19] Guglielmi et al. observed a 16% rate of recanalization of the

aneurysms on the follow-up angiograms. The important factors related to the aneurysm recanalization were the use of soft and smaller coils, large size of the aneurysm, large size of the neck of the aneurysm and packing density. Another factor that predisposes to recanalization is the spatial direction of the Acomm aneurysm. The lesions that point upward and posteriorly are more difficult to treat. In this type of aneurysm there is difficulty of safe catheterization. It is important to steam-shape the microcatheter properly to improve its positioning and anchoring. A second session of embolization was performed in the majority of recanalized aneurysms, with a very low rate of iatrogenic complications. In our study, 2 out of 17 cases (11.76%) had recanalization in the follow up angiogram done after 6 months, recanalization occurred in the two cases were due to a small neck remnant with no filling of sac, hence left as such.

In the study of A. Z Ahmed and his colleagues in the year 2010-2011, 15 cases underwent endovascular coiling with Hunt and Hess grade I-III total occlusion was achieved in 13 cases (86.6%) with neck remnant left in 1 case (6.7%) and failure in one case (6.7%) due to a thrombotic event which was overcome by antiplatelets. The patient was coiled in a second session. The outcome measured on GOS was good in 12 (80%), poor in 2 cases (13.3%) and mortality in 1 case (6.7%). [20]

In the study of MP Cheria et al. in 2011, 103 patients undergone endovascular coiling. Total occlusion achieved in 94% with neck remanants seen in 5.8%. There were 14 (13.

59%) mortality with 85 (82.44%) had good outcome. [21] In our study, 17 cases underwent endovascular coiling with Hunt and Hess grade I-III. Total occlusion was achieved in 14 cases (82.35%) with neck remnant left in 2 cases (11.76%) and 2 cases with intraoperative rupture of the aneurysm sac (11.76%). The outcome measured on GOS was good in 10 cases (58.82%), poor in 3 cases (17.64%) and mortality in 4 (23.52%).

The initial results of the International Subarachnoid Aneurysm Trial (ISAT): of neurosurgical clipping versus endovascular coiling in 2143 patients with ruptured intracranial aneurysms were originally published in 2002, and were conducted to establish comparative outcomes in a prospective randomized fashion in patients equally suitable for either endovascular or surgical treatment. [22] For such patients, the absolute reduction in death and morbidity was 6.9% and the relative risk reduction was 23%. [23] A complete analysis at 1 year revealed that the absolute and relative risk reductions had increased to 7.4 and 24%, respectively [22].

The presence of symptomatic moderate or severe vasospasm is not a contraindication of the coiling of Acomm aneurysms. It is possible to perform pharmacological manipulation of the spasm before coiling. The immediate occlusion of the aneurysm allows intense medical or endovascular therapy for the arterial vasospasm. A significant advantage over surgery is that there is no need for any kind of manipulation or resection of an "angry swollen" brain to reach the aneurysm. [19]

In our study, all the patients received Triple H therapy (hypertension, hypervolaemia and

hemodilution) after securing the ruptured aneurysm either surgically or by coiling to counter vasospasm, despite this protocol, 28% of the total number of cases included in the study suffered from vasospasm either clinically or radiologically. However, we could not relate the vasospasm to the line of management used either in surgery or endovascularly, but as sequelae of SAH as reported in the literature. Rupture alone or surgical repair of Acommm aneurysm may result in cognitive deficits such as memory impairment and personality changes, which are referred to as "Acommm syndrome". [24,25] Even patients with a postoperative Glasgow Outcome Scale score of 4 or 5 may have significant cognitive deficits. [25] The only study that compares the cognitive outcome between surgically and endovascular treated patients was published by Chan et al. on 18 patients with ruptured Acommm aneurysm. [26] Half of them had undergone surgical clipping and the other half had endovascular embolization. Endovascular treatment showed significantly fewer severe cognitive deficits than those with surgical clipping. [24] In our study 10 (30. 30%) patients of clipping and 2 (11. 76%) of coiling developed cognitive impairment which showed that surgical clipping had more chance to injury of perforators supplying the hypothalamus and thalamus leading to more chance of cognitive impairment.

Suzuki et al. reported on the post-surgical overall clinical outcome in 603 patients with Acommm aneurysm. Of these patients, 367 (61%) had an excellent outcome, 107 (18%) had a good outcome, 99 (16%) had poor outcome, and 30(5%) died. Of the 264 patients

who presented in H & H Grades I–III, 86% had an excellent or good outcome. [27]

Fukushima et al. reported on the overall clinical outcome post-surgery in 138 patients with Acommm aneurysm. In 119 cases (86%) the outcome was excellent or good, and 8 (6%) died. Of the 83 patients presenting in Hunt and Hess Grades I–III, 92% had an excellent or good outcome. [28]

In the study of A. Z Ahmed and his colleagues in the year 2010-2011, 15 cases underwent surgical clipping with Hunt and Hess grade I–III the outcome measured on GOS was 5 in 8 cases (53. 3%), 4 in 1 case (6. 7%), 3 in 2 cases (13. 3%) and 1 in 4 cases (26. 7%)(20). In our study of 33 cases undergone for surgical clipping the GOS were excellent or good in 20(60. 60%) and poor in 6(18. 18%) and grade 1 in 7(21. 21%). As far as different complications associated with surgical clipping and coiling were concerned there were no statistically significant difference between the two groups except for electrolyte imbalance especially hyponatremia which was significantly(P=0. 007) more in clipping group as shown in table number 7. In our surgical limb we did not have any method for intra-operative assessment of residual aneurysm or a follow up angiogram schedule.

One important point in large scale comparison of two procedures is the cost analysis. Of course, the total final cost also depends to the initial situation of the patients regarding the aneurysm rupture. The patients could be discharged to home, short term facilities, long term facilities or could be dead. These situations are associated with different costs. There is no any comprehensive cost

analysis study in our country comparing the clipping versus coiling, but it seems regardless of physician payment, the most part of cost in clipping treatment relates to hospital stay while in coiling, it relates to the coil preparation. Surgical clipping seems to be more economical than coiling in the government institutions like our institute where most of facilities are provided on free of cost. The scenario would be completely different in private hospitals which need further study and analysis to reach any conclusion regarding cost of treatment between the two groups. Hoh et al in a study of NIS in 2002-2006 found that the clipping patients experienced significantly higher hospital stay and total hospital costs than coiling among patients with ruptured aneurysms. [29]

In our surgical limb we did not have any method for intra-operative assessment of residual aneurysm or a follow up angiogram schedule. However, a further study of a larger number of cases and introduction of intraoperative indocyanine green (ICG) angiography are mandatory to exclude residual aneurysm after microsurgical clipping.

Conclusion

At the centre where well experienced neurosurgeons and neurointerventionist are available, there is no overall difference in the clinical outcomes, complications and mortalities in both the groups. However, the selection of the patient should be done based on clinical status and radiological characteristic of aneurysm because there are some groups of patients having severe brain

oedema or large hematoma in which surgical clipping would be preferable which give opportunity to not only secure the aneurysm but also to deal with the mass effect. Otherwise both modalities have their own advantages and disadvantages which make them as complementary rather than competitive.

Correspondence

Dr. Pradeep Kumar

Department of Neurosurgery, SMS Medical College, Jaipur, India

Email: dr. pradeepk28@gmail. com

Phone number: +91 9828929366

References

1. Sehba FA, Hou J, Pluta RM, Zhang JH. The importance of early brain injury after subarachnoid hemorrhage. *Prog Neurobiol*2012; 97(1): 14-37.
2. Brisman JL, Song JK, Newell DW. Cerebral aneurysms. *N Engl J Med* 2006;355:928–39, 10. 1056/NEJMra052760
3. Proust F, Debono B, Hannequin D, Gerardin E, Clavier E, Langlois O, et al. Treatment of anterior communicating artery aneurysms: complementary aspects of microsurgical and endovascular procedures. *J Neurosurg* 2003;99:3–14.
4. Suarez JI, Tarr RW, Selman WR. Aneurysmal subarachnoid hemorrhage. *N Engl J Med* 2006;354:387–96, 10. 1056/NEJMra052732
5. Ryttefors M, Enblad P, Kerr RS, Molyneux AJ. International subarachnoid aneurysm trial of neurosurgical clipping versus endovascular coiling: subgroup analysis of 278 elderly patients. *Stroke* 2008; 39(10): 2720-6.
6. Hwang JS, Hyun MK, Lee HJ, Choi JE, Kim JH, Lee NR, et al. Endovascular coiling versus neurosurgical clipping in patients with unruptured intracranial aneurysm: a systematic review. *BMC Neurol* 2012; 12: 99.
7. Seibert B, Tummala RP, Chow R, Faridar A, Mousavi SA, Divani AA. Intracranial aneurysms: review of current treatment options and outcomes. *Front Neurol* 2011; 2: 45.
8. Molyneux A, Kerr R, Stratton I, Sandercock P, Clarke M, Shrimpton J, et al. International Subarachnoid Aneurysm Trial (ISAT) of neurosurgical clipping versus endovascular coiling in 2143 patients with ruptured

- intracranial aneurysms: a randomised trial. *Lancet* 2002; 360(9342): 1267-74.
9. Campi A, Ramzi N, Molyneux AJ, Summers PE, Kerr RS, Sneade M, et al. Retreatment of ruptured cerebral aneurysms in patients randomized by coiling or clipping in the International Subarachnoid Aneurysm Trial (ISAT). *Stroke* 2007; 38(5): 1538-44.
10. Zhang QR, Zhang X, Wu Q, Shi JX, Wang HD, Hang CH, et al. The impact of microsurgical clipping and endovascular coiling on the outcome of cerebral aneurysms in patients over 60 years of age. *J Clin Neurosci* 2012; 19(8): 1115-8.
11. Mason AM, Cawley CM, Barrow DL. Surgical management of intracranial aneurysms in the endovascular era: review article. *J Korean Neurosurg Soc* 2009;45(3): 133-42.
12. Weir B. Unruptured intracranial aneurysms: a review. *J Neurosurg* 2002;96:3-42, 10. 3171/jns. 2002. 96. 1. 0003
13. Unruptured intracranial aneurysms—risk of rupture and risks of surgical intervention, International Study of Unruptured Intracranial Aneurysms Investigators. *N Engl J Med* 339:1725–1733,1998, 10. 1056/NEJM199812103392401.
14. Wiebers DO, Whisnant JP, Huston 3rd J, Meissner I, Brown Jr RD, Piepgras DG, et al. Unruptured intracranial aneurysms:natural history, clinical outcome, and risks of surgical and endovascular treatment. *Lancet* 2003;362:103–10.
15. Woo D, Khoury J, Haverbusch MM, Sekar P, Flaherty ML, Kleindorfer DO, et al. Smoking and family history and risk of aneurysmal subarachnoid hemorrhage. *Neurology* 2009;72:69–72,10. 1212/01. wnl. 0000338567. 90260. 46.
16. Diringer MN. Management of aneurysmal subarachnoid hemorrhage. *Crit Care Med* 2009;37:432–40, 10. 1097/CCM. 0b013e318195865a
17. Moret J, Pierot L, Boulin A, Castaings L, Rey A. Endovascular treatment of anterior communicating artery aneurysms using Guglielmi detachable coils. *Neuroradiology* 1996;38:800–5.
18. Kazekawa K, Tsutsumi M, Aikawa H, Iko M, Tanaka A, Go Y, et al. Endovascular treatment of anterior cerebral artery aneurysms using Guglielmi detachable coils: mid-term clinical evaluation. *Radiat Med* 2002;20:291–7.
19. Guglielmi G, Vinuela F, Duckwiler G, Jahan R, Cotroneo E, Gigli R. Endovascular treatment of 306 anterior communicating artery aneurysms: overall, perioperative results. *J Neurosurg* 2009;110:874–9.
20. Ahmed A. Z, Zohdi Ahmed M, Zaghoul Mohamed S, ElSamman Amar K. Endovascular coiling versus surgical clipping in the treatment of ruptured anterior communicating artery aneurysm in Cairo University Hospitals. *The Egyptian Journal of Radiology and Nuclear Medicine* (2013) 44, 523–530.
21. Cherian MP, Praneh M B, Mehta P, Vijayan K, Bhaskar P, Kalyanpur TM, Narsinghpura KS. Outcomes of endovascular coiling of anterior communicating artery aneurysms in the early postrupture period: A prospective analysis. *Neurol India* 2011;59:218-23
22. Molyneux A, Kerr R, Stratton I, Sandercock P, Clarke M, Shrimpton J, et al. International Subarachnoid Aneurysm Trial (ISAT) of neurosurgical clipping versus endovascular coiling in 2143 patients with ruptured intracranial aneurysms: a randomised trial. *Lancet* 2002;360:1267–74.
23. Raymond J, Guilbert F, Weill A, Georganos SA, Juravsky L, Lambert A, et al. Long-term angiographic recurrences after selective endovascular treatment of aneurysms with detachable coils. *Stroke* 2003;34:1398–403, 10. 1161/01. STR. 0000073841. 88563. E9.
24. Alexander MP, Freedman M. Amnesia after anterior communicating artery aneurysm rupture. *Neurology* 1984;34, 752–752.
25. Mavaddat N, Sahakian BJ, Hutchinson PJ, Kirkpatrick PJ. Cognition following subarachnoid hemorrhage from anterior communicating artery aneurysm: relation to timing of surgery. *J Neurosurg* 1999;91:402–7, 10. 3171/jns. 1999. 91. 3. 0402
26. Chan A, Ho S, Poon WS. Neuropsychological sequelae of patients treated with microsurgical clipping or endovascular embolization for anterior communicating artery aneurysm. *Eur Neurol* 2002;47:37–44.
27. Suzuki J, Mizoi K, Yoshimoto T. Bifrontal interhemispheric approach to aneurysms of the anterior communicating artery. *J Neurosurg* 1986;64:183–90, 10. 3171/jns. 1986. 64. 2. 0183.
28. Fukushima T, Miyazaki S, Takusagawa Y, Reichman M. Unilateral interhemispheric keyhole approach for anterior cerebral artery aneurysms. *Acta Neurochir Suppl (Wien)* 1991;53:42–7.
29. Hoh BL, Chi YY, Dermott MA, Lipori PJ, Lewis SB. The effect of coiling versus clipping of ruptured and unruptured cerebral aneurysms on length of stay, hospital cost, hospital reimbursement, and surgeon reimbursement at the University of Florida. *Neurosurgery* 2009; 64(4):614-9.