

Article

Intracranial actinomyces: case report and review of literature

Alfonso Pacheco-Hernandez, Jorque Aquino-Matus, Willem Guillermo Calderon-Miranda, Jean Carlos Pinto-Angarita, Ronsangela Ramirez-Barranco, Katherine Gomez-Barragan, Ernesto Jose Rocha-Reyes, Marco Antonio Blancas-Rivera, Zyanya Patricia Carbajal Menes, Paulo Cesar Puac Polanco, Guru Dutta Satyarthee, Luis Rafael Moscote-Salazar
COLOMBIA, MEXICO, USA, INDIA



DE GRUYTER
OPEN

DOI: 10.1515/romneu-2017-0042

Intracranial actinomycosis: case report and review of literature

Alfonso Pacheco-Hernandez¹, Jorque Aquino-Matus², Willem Guillermo Calderon-Miranda², Jean Carlos Pinto-Angarita¹, Ronsangela Ramirez-Barranco¹, Katherine Gomez-Barragan¹, Ernesto Jose Rocha-Reyes¹, Marco Antonio Blancas-Rivera², Zyanya Patricia Carbajal Menes³, Paulo Cesar Puac Polanco⁴, Guru Dutta Satyarthee⁵, Luis Rafael Moscote-Salazar¹

¹Universidad de Cartagena, Cartagena de Indias, COLOMBIA

²Universidad Nacional Autonoma de Mexico, Mexico City, MEXICO

³Hospital General Dr. Manuel Gea González; National Autonomous University of Mexico School of Medicine, Mexico City, MEXICO

⁴Neuroradiology section, Department of Radiology, University of North Carolina School of Medicine, USA

⁵Department of Neurosurgery, Neurosciences Centre, All India Institute of Medical Sciences, New Delhi, INDIA

Abstract: Actinomycosis infection is a slow progressing disease, in which involvement of the central nervous system by *Actinomyces israelii* is uncommon (less than 5%). Clinical picture is non-specific and is often misdiagnosed with neoplasia; some clinical clues may arouse suspicion. The case of a 59 year-old female is reported who presented headache and focal neurologic signs and in whom a out-of the hospital diagnosis of a neuroepithelial dysembryoplastic tumor was made; nonetheless after careful interview and physical exploration, a spectroscopy magnetic resonance of the brain and histopathological description of the lesion was made and yielded the definitive diagnosis of intracranial actinomyces infection. Treatment and progression were uneventful.

Key words: actinomycosis, intracranial, infection, brain, abscess, tumor

Introduction

Actinomycosis is a slow progression infection caused by filamentous microaerophilic anaerobic Gram positive bacteria from the family Actinomycetaceae

(1). It has been supposed to be similar to fungi for the similarity in ramification and the formation of a mycelial net; nonetheless the presence of muramic acid in the cellular wall and the absence of a nuclei attached to the

cellular membrane, clearly differentiate them into prokaryotic bacteria (schizomycetes) closely related to mycobacteria. (2). The most common species from the Actinomycetes gender are: *Nocardia*, *Streptomyces* and *Actinomyces*; being *A. israelii* the common among them. (3)

Actinomycosis is a relatively rare infection that occurs 1 in 300,000 persons per year. Men are affected three times more than women (3). The clinical picture and radiologic findings are unspecific, and are similar to any pyogenic abscess (4).

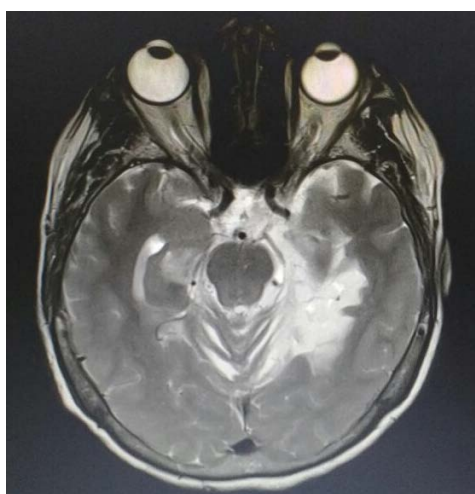
Actinomycosis infection to the Central Nervous System is generally secondary to hematogenous dissemination from the primary infection in the lung, abdomen, pelvis or by continuity in a cervical, oral or facial infection, since it is closely related to mycobacteria in the mouth and gastrointestinal tract (5-9). Since infection to the CNS is not common, it may be misdiagnosed with a cerebral neoplasia (1). Therefore, we report the case of a 59 years-old female with CSN actinomycosis in the National Institute of High Technology at Monteria, Colombia.

Case presentation

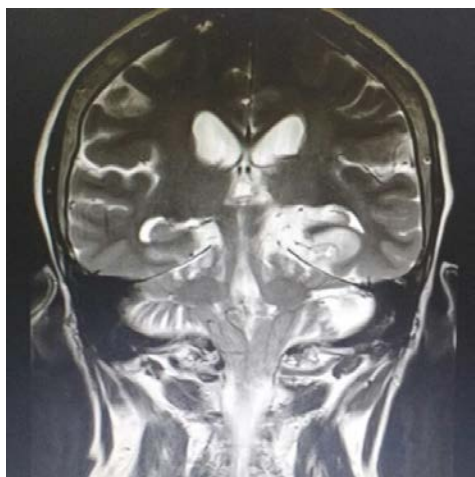A 59 years-old female with past medical history of Hypertension under treatment with Losartan, Type 2 Diabetes Mellitus under treatment with homeopathy, and previously heavy smoker who had been admitted in the past 6 months with holocraneal headache resistant to analgesics and associated with nausea, vomiting, and loss of vision in the left eye, temporospatial disorientation and blurred speech. She was admitted on May 2016 with an

occupying lesion in the brain and a Gadolinium-enhanced Magnetic Resonance Imaging (MRI) suggested a dysembryonic neuroepithelial tumor (DNET). (Figures 1 A and B). A Spectroscopy MRI reported a low-signal poorly defined lesion in T1 sequence and high-signal in T2 sequence compromising the amygdala, hippocampus, uncus, left thalamus in its posterior portion and extending to the left occipitotemporal and inferior temporal gyrus. Additionally, some contrast enhanced nodular foci were seen. Spectroscopy study reported high levels of choline, creatine and low levels of N-acetylaspartate. She underwent a craniectomy with resection of the 100% of the lesion by a left partial temporal lobectomy. Postoperative head CT scan reported a hypodensity in the surgical bed with a small left pericapsular hematoma and no mass effect. She persisted disoriented but with no neurological deficit. She was discharged at the 6th day after surgery. Nonetheless, she was readmitted and in the ER she was found with a CGS 9 points (E2 V2 M5), reactive pupils, right hemiparesis and ipsilateral pyramidal syndrome. Brain CT scan was unremarkable and histopathological studies from previous surgery resection were obtained and reported reactive inflammatory changes in glia, mononuclear infiltrate in the perivascular space, mononuclear infiltrate and neuropil edema with presence of filamentous structures compatible with chronic encephalitis corresponding to cerebral actinomycosis. Laboratory workup reported leukocytes in $15.8 \times 10^9/L$ and sodium in 125 mEq/L, which explained neurological deficit that recovered after sodium IV reposition over the next 48 hours. Antibiotic therapy was

initiated with Penicillin G 2 million IV QID for 10 days followed by Penicillin VK 2 grams PO/day for 6 months. Evolution was uneventful but persisted with temporo-spatial disorientation.



A



B

Figures 1 A and B - Brain IRM showing a low-signal poorly defined lesion in T1 sequence and high-signal in T2 sequence compromising the amygdala, hippocampus, uncus, left thalamus in its posterior portion and extending to the left occipitotemporal and inferior temporal gyrus

Discussion

Actinomycosis is an infrequent and slow progression infection which originates partially from the normal buccal flora. A crucial step in the development of the infection is the loss of the mucosal barrier. (10) Actinomycosis usually produces acute purulent infections which confluent foci may form cavities and cause chronic abscesses. Metastasis seldom occurs and it is favored by hematogenous dissemination. (11) Sites of infection are in the head and neck (50%), abdomen (20%), thorax (15%), pelvis, heart and brain (15%). Central nervous system infection is rare and it occurs in less than 5% of cases. Pathogenesis is believed to occur as a direct invasion from head and neck tissues, as well as lower mandible, ears and paranasal sinus, through the fascia and extending through the skull base and meninges. Other mechanisms postulated are the perineural extension through the intervertebral spaces and hematogenous dissemination. (3)

In cerebral actinomycosis, common clinical features are headache and focal neurological signs (12), and symptoms may be present for a long time and fever may not occur. Infection present as brain abscess (67%), meningitis and meningoencephalitis (13%), actinomycoma (7%), epidural or subdural space infection (7%) (13).

A distinctive characteristic of cerebral actinomycosis is a chronic indolent phase with presence of solitary or multiple lesions. Therefore, diagnosis requires a high clinical suspicion, relying on the chronicity, slow progression, characteristic features on brain

imaging and refractory/recurrent natural history. (11) Nonetheless, actinomyces are underestimated bacteria as cause of infections, and therefore are underdiagnosed. (11)

CNS actinomycosis must be suspected in patients with previous history of actinomycosis in other sites and presenting with long duration of neurologic symptoms with or without fever. Common risk factors include HIV infection, AIDS, dental procedures, history of head, gastrointestinal, otorhinolaryngologic surgery, cyanotic congenital heart disease and use of intrauterine devices. (6, 13, 14)

Brain imaging is not helpful into differentiate among other infectious and non-infectious diseases; CT scan or MRI may report a irregular or nodular ring-shaped thick wall lesion. (15) CT scan identifies cerebral and cerebellum abscesses which are generally solitary but may be multiple (in combination with a granulomas) and present homogeneous enhancement with a thick wall and perilesional edema (16). MRI identifies better lesion in the subdural space, cavernous sinus and inner ear canal in patients with acute purulent meningitis. Spectroscopy may reveal elevation in amino acids, acetate and succinate. (17)

There is no serologic or skin test available. Microbiologic identification of actinomyces may take up to 3 weeks and has low insensibility. (18) In cases where culture is positive, the most commonly found associated with CNS infection is *A. israelii*; other species found are *A. naeslundii* which may cause subdural empyema and *A. viscosus* (10-21). Therefore, diagnosis is usually made with

histopathological studies.

Actinomyces is identified by an outer zone of granulation tissue, a purulent core with azurophilic granules measuring 1-2 mm (associated with a calcium phosphate compounds), and fibrotic walls surrounding a neutrophilic infiltrate. (17). Differential diagnosis includes tuberculosis, fungi, nocardiosis, other germs and neoplasia. (11)

Successful treatment requires drainage of the primary abscess followed by systemic antibiotics. Surgical debridement should be aggressive with complete resection of the capsule. (11) Penicillin remains the drug of choice but at high doses and during a long course (6 to 12 months). (22). Penicillin G (18-24 mIU/day divided in 6 doses) for 4 to 6 weeks is followed by Penicillin VK (1-2 grams/day divided in 4 doses); alternatively, Amoxicilin (1.5 grams/day divided in 3 doses for 6 to 12 months) may be used. Individualized treatment is always mandatory. Other antibiotics that have showed efficacy but with limited experience are Imipenem, Ceftriaxone, and Ciprofloxacin. Antibiotics as Metronidazole, Thrimetoprim-Sulfametoxazole, Ceftazidime, Oxacilin, aminoglycosides and fluoroquinolones are not effective but may be used in polymicrobial infections according to antibiotic sensitivity tests. (22)

A long course of antibiotic therapy must be completed to assure eradication of infection. Treatment must be individualized and if extended beyond clinical remission, risk of recurrence is minimized. CT and MRI should be used to monitor treatment response. (22)

References

1. Bello Y. E, Ojeda P, Mosquera O. A, Martínez F, Lozano A. J. Actinomycosis del sistema nervioso central: presentación de caso. *Rev Colomb Radiol.* 2013; 24(4): 3827-31.
2. Tsai MS, Tarn JJ, Liu KS, Chou YL, Shen CL. Multiple actinomyces brain abscesses: case report. *J Clin Neurosci Off J Neurosurg Soc Australas.* 2001 Mar;8(2):183-6.
3. Van Dellen JR. Actinomycosis: an ancient disease difficult to diagnose. *World Neurosurg.* 2010 Sep;74(2-3):263-4.
4. Riesgo P, Orozco M, Piquer J, Cortés F, Botella C, Navarro J, Cabanes J. Absceso cerebral actinornicótico: caso clínico. *Neurocirugía* 1996; 7: 230-234.
5. Ewald C, Kuhn S, Kalf R: Pyogenic infections of the central nervous system secondary to dental affections. A report of six cases. *Neurosurg Rev* 29:163- 167, 2006.
6. Nithyanandam S, D'Souza O, Rao SS, Battu RR, George S: Rhinoorbitocerebral actinomycosis. *Ophthalm Plast Reconstr Surg* 17:134-136, 2001.
7. Salvati M, Ciappetta P, Raco A, Artico M, Artizzu S. Primary intracranial actinomycosis. Report of a case and review of the literature. *Zentralblatt Für Neurochir.* 1991;52(2):95-8.
8. Corbin D, Solaro L, Flint G, Williams AC: Actinomycotic brain abscess following abdominal suppuration. *J Neurol Neurosurg Psychiatry* 50:1705-1706, 1987.
9. Trutnovsky G, Tamussino K, Reich O: Short-term antibiotic treatment of pelvic actinomycosis. *Int J Gynaecol Obstet* 101:203-204, 2008.
10. Roth J, Ram Z. Intracranial infections caused by Actinomyces species. *World Neurosurg.* 2010 Sep;74(2-3):261-2.
11. Akhaddar A, Elouennass M, Baallal H, Boucetta M. Focal intracranial infections due to Actinomyces species in immunocompetent patients: diagnostic and therapeutic challenges. *World Neurosurg.* 2010 Sep;74(2-3):346-50.
12. Akhaddar A, Elmostarchid B, Boucetta M. Primary subdural empyema after spontaneous vaginal delivery. *Surg Infect.* 2009 Aug;10(4):363-4.
13. Smego RA, Jr: Actinomycosis of the central nervous system. *Rev Infect Dis* 9:855-865, 1987.
14. Olah E, Berger C, Boltshauser E, Nadal D. Cerebral actinomycosis before adolescence. *Neuropediatrics.* 2004 Aug;35(4):239-41.
15. Soto-Hernández JL, Morales VA, Lara Giron JC, Balderrama Bañares J: Cranial epidural empyema with osteomyelitis caused by Actinomyces, CT, and MRI appearance. *Clin Imaging* 23:209-214, 1999.
16. Adeyemi OA, Gottardi-Littell N, Muro K, Kane K, Flaherty JP. Multiple brain abscesses due to Actinomyces species. *Clin Neurol Neurosurg.* 2008 Sep;110(8):847-9.
17. Wang S, Wolf RL, Woo JH, Wang J, O'Rourke DM, Roy S, et al. Actinomycotic brain infection: registered diffusion, perfusion MR imaging and MR spectroscopy. *Neuroradiology.* 2006 May;48(5):346-50.
18. Desai A, Lollis SS, Missios S, Radwan T, Zuaro DE, Schwarzman JD, Duhaime AC: How long should cerebrospinal fluid cultures be held to detect shunt infections?. Clinical article. *J Neurosurg Pediatr* 4:184-189, 2009.
19. Bebrova E, Lochmann O, Tichy M, Nyc O: Actinomyces viscosus in subdural empyema. *Epidemiol Mikrobiol Imunol* 43:21-22, 1994.
20. Jamjoom AB, Jamjoom ZAB, Al-Hedaithy SS: Actinomycotic brain abscess successfully treated by burr hole aspiration and short course antimicrobial therapy. *Br J Neurosurg* 8:545-550, 1994.
21. Hirai T, Nunoya T, Azuma R: Actinomycosis of the brain and temporal bone in a goat. *J Vet Med Sci* 69:641-643, 2007.
22. Brook I. Actinomycosis: diagnosis and management. *South Med J.* 2008 Oct;101(10):1019-23.